

# UC Davis

## UC Davis Previously Published Works

### Title

Primary sclerosing cholangitis: A review and update

### Permalink

<https://escholarship.org/uc/item/35t5g441>

### Journal

Liver Research, 1(4)

### ISSN

2542-5684

### Authors

Tabibian, James H  
Bowlus, Christopher L

### Publication Date

2017-12-01

### DOI

10.1016/j.livres.2017.12.002

### Copyright Information

This work is made available under the terms of a Creative Commons Attribution-NonCommercial-NoDerivatives License, available at <https://creativecommons.org/licenses/by-nc-nd/4.0/>

Peer reviewed



Published in final edited form as:

*Liver Res.* 2017 December ; 1(4): 221–230. doi:10.1016/j.livres.2017.12.002.

## Primary sclerosing cholangitis: A review and update

James H. Tabibian<sup>a,b</sup> and Christopher L. Bowlus<sup>a,\*</sup>

<sup>a</sup>Division of Gastroenterology and Hepatology, University of California Davis, Sacramento, CA, USA

<sup>b</sup>Division of Gastroenterology, Olive View-UCLA Medical Center, Sylmar, CA, USA

### Abstract

Primary sclerosing cholangitis (PSC) is a rare, chronic, cholestatic liver disease of uncertain etiology characterized biochemically by cholestasis and histologically and cholangiographically by fibro-obliterative inflammation of the bile ducts. In a clinically significant proportion of patients, PSC progresses to cirrhosis, end-stage liver disease, and/or hepatobiliary cancer, though the disease course can be highly variable. Despite clinical trials of numerous pharmacotherapies over several decades, safe and effective medical therapy remains to be established. Liver transplantation is an option for select patients with severe complications of PSC, and its outcomes are generally favorable. Periodic surveillance testing for pre- as well as post-transplant patients is a cornerstone of preventive care and health maintenance. Here we provide an overview of PSC including its epidemiology, etiopathogenesis, clinical features, associated disorders, surveillance, and emerging potential therapies.

### Keywords

Bile duct diseases; Primary sclerosing cholangitis (PSC); Cholestasis; Cholangiocarcinoma; Magnetic resonance imaging; Cholangiography; Natural history

## 1. Introduction

Primary sclerosing cholangitis (PSC) is a chronic, idiopathic, cholestatic liver disease characterized by peribiliary inflammation and fibrosis. It is a highly heterogeneous but generally progressive disorder which can lead to end-stage cirrhosis, constitutes a risk factor for hepatobiliary and colonic malignancies, and carries a median liver transplant (LT)-free survival time of approximately 15 years.<sup>1–4</sup> As the etiopathogenesis of PSC remains poorly understood, effective pharmacotherapy for PSC has yet to be established.<sup>5,6</sup> Although a relatively rare disorder, PSC is the 5<sup>th</sup> most common indication for LT in the United States

\*Corresponding author: Division of Gastroenterology and Hepatology, University of California Davis, Sacramento, CA, USA. clbowlus@ucdavis.edu (C. L. Bowlus).

### Conflict of interest

The authors declare that they have no conflict of interest.

**Publisher's Disclaimer:** This is a PDF file of an unedited manuscript that has been accepted for publication. As a service to our customers we are providing this early version of the manuscript. The manuscript will undergo copyediting, typesetting, and review of the resulting proof before it is published in its final citable form. Please note that during the production process errors may be discovered which could affect the content, and all legal disclaimers that apply to the journal pertain.

(US)<sup>7</sup> and the leading indication in several other countries worldwide.<sup>3,8</sup> LT is the only life-extending therapy for patients with advanced PSC but is an option only in select cases, and even suitable candidates can experience recurrent PSC or hepatobiliary malignancy after LT.<sup>9,10</sup> In this review, we provide a concise overview of PSC, including its epidemiology, clinical features, associated disorders, complications, surveillance, and treatment.

## 2. Epidemiology

PSC can be diagnosed at essentially any age but is most commonly diagnosed in the fourth decade of life and in males twice as frequently as females.<sup>11</sup> In the US, the annual incidence of PSC is approximately 0.5–1.3 per 100,000 individuals, and prevalence is estimated at 5–16.2 per 100,000 individuals, thus amounting to approximately 30,000 cases in the US.<sup>12,13</sup> Limited data suggest that African Americans are affected with PSC at similar rates but tend to be younger and have higher model for end-stage liver disease (MELD) scores at the time of LT listing, suggesting a more aggressive disease phenotype.<sup>14</sup> In contrast, there were no cases of PSC in a large study of Alaskan native patients with liver disease.<sup>15</sup>

Outside the USA, comparable incidence and prevalence rates have been reported in Canada,<sup>16</sup> Northern Europe,<sup>17,18</sup> and New Zealand,<sup>19</sup> and recent data suggest that these rates are rising (at least in North American and European countries).<sup>20</sup> In Japan and Singapore, the available published data suggest that PSC is rare.<sup>21,22</sup> The epidemiology and geographic distribution of PSC remains poorly defined in most other countries.

Of interest is the strong association of PSC with inflammatory bowel disease (IBD). Approximately 70% of Western patients with PSC are co-diagnosed with IBD;<sup>23–27</sup> conversely, only approximately 3%–5% of patients with IBD have PSC. The significance of this association may hold pathophysiological importance and is a subject of ongoing research. It is worth noting that in far Eastern cohorts, only approximately 25% of patients with PSC have concomitant IBD; this discrepancy is not well understood but may be attributable to genetic and/or environmental factors.<sup>28</sup> IBD in PSC is discussed further in subsection 10.1.

## 3. Clinical presentation

The initial presentation of PSC is highly variable, depending in part on disease stage and age.<sup>29,30</sup> Approximately 15%–40% of PSC cases are incidentally diagnosed after blood work (*e.g.*, pre-employment physical) reveals a cholestatic laboratory pattern.<sup>31</sup> At the other end of the spectrum is the example of a patient who presents with jaundice and already has advanced liver disease and/or concomitant cholangiocarcinoma (CCA). Pediatric patients with PSC can present similarly to adults but more frequently have overlapping features of autoimmune hepatitis (AIH),<sup>32,33</sup> as discussed later.

The most common symptoms of PSC at the time of diagnosis are abdominal pain (20%–37%), pruritus (10%–30%), diarrhea (8%), jaundice (6%–30%), fatigue (6%), and fever (4%–17%),<sup>16,34</sup> though nearly half of the patients will not have any symptoms at initial presentation, and considerable variation can be seen among different cohorts.<sup>29,34</sup> Physical

examination may reveal jaundice, hepatomegaly, splenomegaly, ascites, pitting edema, and/or excoriations, or in many cases, no abnormalities.<sup>29</sup>

#### 4. Diagnosis

The diagnosis of PSC is based on: (i) a chronically cholestatic serum biochemical profile, (ii) cholangiography demonstrating multifocal intrahepatic and/or extrahepatic biliary strictures and segmental dilations, and (iii) compatible features (*e.g.*, chronic cholangitis, periductal fibrosis) on liver biopsy.<sup>6,35,36</sup> In the proper clinical context (*e.g.*, a young male with IBD and cholestatic biochemical profile), characteristic cholangiographic findings can obviate the need for a biopsy. Indeed, the major role of liver biopsy in PSC, when performed, is to: (i) exclude other diseases (Table 1), (ii) diagnose small-duct PSC, and (iii) determine the stage.<sup>37–39</sup>

A small proportion of patients with PSC present with normal serum alkaline phosphatase (ALP);<sup>40</sup> therefore, normal ALP should not exclude the diagnosis of PSC or discourage further investigation if other clinical data suggest it. In addition, a subset of patients who present with elevated ALP will experience spontaneous normalization over time; this subgroup of patients appears to have a more favorable long-term prognosis.<sup>5,41–45</sup>

#### 5. Additional serologic abnormalities

Aminotransferase levels are often increased, albeit to a lesser degree than ALP, and typically less than three times the upper limit of normal.<sup>46</sup> Markedly elevated aminotransferase levels may indicate concomitant or variant liver disease, such as PSC-AIH overlap syndrome,<sup>47</sup> as discussed in subsection 10.3.

Bilirubin levels are normal in 60% of patients at diagnosis but tend to rise over time.<sup>31</sup> An abrupt, sustained increase in bilirubin may herald a dominant biliary stricture, bile duct stone, or development of CCA,<sup>48</sup> and therefore, should prompt additional investigation. Increases in unconjugated bilirubin with normal direct bilirubin may suggest Gilbert's disease.

Various autoantibodies have been described in PSC, but it is unclear if any are of pathogenic significance. Antineutrophil cytoplasmic antibodies, anticardiolipin antibodies, and antinuclear antibodies can be detected in 84%, 66%, and 53% of patients with PSC, respectively.<sup>49</sup> Antimitochondrial antibodies and anti-smooth muscle antibodies are rare in patients with PSC and suggest an alternative diagnosis or overlap syndrome, respectively.

Elevated serum immunoglobulin (Ig)M, IgE, IgG, and total IgA levels have been reported in approximately 45%, 40%, 25%, and 10% of patients with PSC, respectively.<sup>50–53</sup> Patients with an increase in one immunoglobulin isotype will generally also have elevations of other isotypes.<sup>53</sup> The significance of hyperglobulinemias in PSC remains unclear. In a study of Japanese patients with PSC, high serum IgE levels were negatively associated with developing CCA;<sup>51</sup> this finding was not replicated, however, in a US-based cohort.<sup>53</sup>

## 6. Imaging features

Typical cholangiographic findings of PSC include multifocal ductal stricturing and beading representing alternating regions of constrictive fibrosis and dilation (Fig. 1). Classically, both the intrahepatic and extrahepatic biliary tree are involved, but phenotypic variations of PSC exist (Table 2), and involvement may become more extensive over time.<sup>30</sup> In addition to location, strictures can also vary in length and diameter. Some strictures may also harbour malignancy, and distinguishing between benign and malignant dominant strictures in PSC represents a major clinical challenge,<sup>1,54</sup> as discussed later.

Endoscopic retrograde cholangiography (ERC) has historically been the gold standard for cholangiography, but it is invasive. Patients with PSC have a higher incidence of cholangitis compared with those without PSC undergoing ERC and may require longer procedure times, though the incidence of pancreatitis, perforation, and bleeding appears to be comparable.<sup>55</sup> Due to these and other drawbacks, magnetic resonance cholangiopancreatography (MRCP) has emerged as a noninvasive substitute. MRCP has diagnostic accuracy comparable to ERC and yields cost savings when used as the initial modality.<sup>56,57</sup> MRCP also lends itself to elastography to assess liver fibrosis.<sup>58</sup>

Abdominal ultrasonography and computed tomography (CT) are helpful in evaluating for biliary stones, hepatobiliary malignancy, and other complications once the diagnosis of PSC has been made.<sup>48</sup> Use of these modalities may be interchangeable with MRCP, depending on clinical considerations and local expertise. Percutaneous cholangiography (PTC) is useful when access to the biliary tree is needed but not technically feasible by ERC.

## 7. Histopathology

Liver biopsy findings include paucicellular non-suppurative cholangitis (with or without ductopenia), cholestasis, ductular proliferation, and peri-ductal fibrosis which classically acquires an “onion skin” appearance.<sup>59</sup> This classic finding is nearly pathognomonic but is seen in fewer than 10% of PSC liver biopsies (more frequently in surgical specimens).<sup>60</sup>

Fibro-obliterative cholangitis similar to that seen in PSC can occur in other conditions, including IgG4-associated cholangiopathy, ductopenic rejection following LT, and acquired immune deficiency syndrome cholangiopathy.<sup>59</sup> Therefore, histology alone is rarely sufficient to establish the diagnosis of PSC. Along these lines, the presence of granulomas, a feature classically seen in PBC, is found in nearly 5% of liver biopsies from patients with PSC,<sup>61</sup> hence underscoring the need for additional clinical data.

PSC is usually scored histologically from stage 1 (portal inflammation) to stage 4 (biliary cirrhosis), though various grading/staging conventions exist.<sup>62</sup>

## 8. Etiopathogenesis

To date, the etiopathogenesis of PSC remains unclear, though it is now generally appreciated to be a heterogeneous, complex disorder with environmental, immunobiologic, and genetic components.<sup>2,5,6,39,63</sup> Moreover, it is believed that cholangiocytes, the epithelial cells lining

the bile ducts, are not only the target of injury, but may also be actively involved in the pathogenesis of PSC.<sup>64</sup> Indeed, cholangiocytes are a morphologically, biochemically, and functionally heterogeneous and dynamic population of biologically active cells.<sup>64,65</sup> Various hypotheses regarding the etiopathogenesis of PSC have been proposed, as recently reviewed elsewhere.<sup>63,66–69</sup>

Regarding the role of environmental factors, a growing body of evidence suggests that a potentially central and modifiable component in the etiopathogenesis of PSC is the enteric microbiome and, by extension, the enterohepatic circulation (of microbial metabolites, derivatives, and a variety of signaling molecules and effectors, *e.g.*, lipopolysaccharide (LPS), lipoteichoic acid, and peptidoglycan).<sup>2,5,70,71</sup> In addition to the well-recognized relationship between PSC and IBD,<sup>24,34,72</sup> a condition which itself is associated with enteric microbial dysbiosis,<sup>73</sup> the potential etiopathogenic link between PSC and the enteric microbiome is supported by several observations, (i) patients with PSC exhibit portal bacteremia and bacterobilia;<sup>74–77</sup> (ii) cholangiocytes are immunobiologically active cells that express multiple pathogen recognition receptors, including all known toll-like receptors (TLRs);<sup>78</sup> (iii) TLR ligands (*e.g.*, LPS) are present in bioactive form in bile,<sup>79,80</sup> accumulate in, and modify signaling in PSC cholangiocytes;<sup>64,81,82</sup> (iv) PSC cholangiocytes exhibit persistent hypersensitivity to LPS *in vitro*;<sup>83</sup> and lastly, (v) animal models of microbial dysbiosis demonstrate various PSC-like hepatobiliary lesions.<sup>84,85</sup> In addition, small case series and early clinical trials increasingly suggest that select oral antibiotics may render a number of therapeutic effects in PSC, including improvements in serum ALP and the Mayo PSC survival estimation model.<sup>35,42,43,68,86–89</sup> Collectively, these translational and clinical observations form the basis of the “leaky gut” and “PSC-microbiota” hypotheses.<sup>2,5,68,89</sup>

Regarding the role of genetic factors in PSC, several lines of evidence support this: First, the risk of PSC is significantly increased in first degree relatives of patients with PSC (hazard ratio of approximately 11).<sup>90,91</sup> Second, genome-wide association studies indicate that the human leukocyte antigen (HLA) gene family, both class 1 and class 2, is the strongest risk locus associated with PSC.<sup>92–95</sup> Moreover, variations in the major histocompatibility complex class I-related sequence A (MICA) gene family have a role in PSC predisposition.<sup>39,96</sup> Third, various non-HLA genes have been associated with PSC susceptibility or disease modification, including but not limited to stromelysin-1 (*i.e.*, matrix metalloproteinase 3), intracellular adhesion molecule 1, and fucosyltransferase 2.<sup>97–100</sup>

Numerous animal models have been developed to study PSC, but given the uncertainties regarding its etiopathogenesis. It is not surprising that no single model has fully recapitulated its multi-faceted features. For example, the *mdr2* (ABCB4) knockout mouse,<sup>101</sup> the most widely studied model, exhibits biochemical,<sup>102–104</sup> histologic,<sup>104</sup> and cholangiographic features of human PSC;<sup>105</sup> however, there is no male predominance (as seen in human PSC—in fact, disease severity appears to be greater in female mice), there is no association with IBD or CCA,<sup>102,104</sup> and the mechanism of injury is not representative. Thus, there is no consensus regarding the optimal model, which has consequently hindered the development of new therapies.<sup>99</sup>

## 9. Natural history

PSC generally progresses to end-stage liver disease, often in an insidious manner.<sup>106</sup> Without LT, the median survival from the time of PSC diagnosis is approximately 15 years.<sup>2–4,107,108</sup> Patients with small-duct PSC (Table 2) appear to have longer survival and lower CCA risk than those with large-duct (*i.e.*, classic) PSC, although a quarter will ultimately progress to classic PSC.<sup>109,110</sup> LT-free survival in children with PSC, although not well characterized, appears to be similar to that in adults.<sup>111</sup>

Prognostic models have been developed to predict survival in PSC,<sup>34,88,107,112</sup> perhaps the most widely used of which is the revised natural history (Mayo) model for PSC, which utilizes patient age, serum bilirubin, albumin, aspartate aminotransferase, and history of variceal bleeding.<sup>88</sup> The limitations of current prognostic models are several, including their inaccuracy in predicting development of CCA or symptom severity. Therefore, while useful for research purposes, their clinical utility is unclear.<sup>6</sup> More recently, the MELD score was developed to identify patients (PSC and non-PSC) at highest mortality risk and determine organ allocation priority;<sup>113</sup> though capable of estimating survival,<sup>53</sup> as with the Mayo model, its clinical use (aside from planning potential LT) is limited. Recently, serum ALP improvement or normalization has been shown to be associated with decreased risk of major adverse PSC-related events and is under continued investigation as a potential prognostic biomarker.<sup>42–45</sup>

## 10. Associated diseases

A variety of diseases are associated with PSC (Fig. 2). The two most prominent of these are discussed below.

### 10.1. Inflammatory bowel disease

The diagnosis of IBD typically precedes that of PSC by 8–10 years, although there is no clear temporal association, and IBD may be diagnosed years after the diagnosis of PSC.<sup>50,114,115</sup> The classic teaching is that there is no relationship between the severity of bowel disease and the severity of liver disease. While this may be true, it is not to say that one has no influence on the other, as illustrated by the following examples: (i) the presence of IBD (irrespective of severity) has been associated with greater PSC-related morbidity and mortality;<sup>19,70</sup> (ii) having IBD and an intact colon before LT appears to be a predictor of recurrent PSC post-LT;<sup>116</sup> (iii) patients with PSC-IBD typically demonstrate a unique phenotype of IBD characterized by pancolitis with rectal sparing and backwash ileitis (and a greater risk of post-colectomy pouchitis);<sup>115,117</sup> (iv) PSC does not appear to be associated with small bowel-only Crohn's disease;<sup>118,119</sup> and (v) colitis is usually milder (even if more extensive) in patients with PSC-IBD compared to those with IBD alone.<sup>120</sup>

### 10.2. Colorectal cancer

PSC-IBD (with colitis) confers nearly a 5-fold increased risk of colorectal cancer (CRC) compared to IBD alone.<sup>121,122</sup> The absolute cumulative risk of developing colorectal dysplasia or carcinoma in a large cohort of Swedish patients with PSC and ulcerative colitis (UC) was 9%, 31%, and 50% after 10, 20, and 25 years of disease duration, respectively, as



compared to 2%, 5%, and 10%, respectively, in patients with UC alone.<sup>122</sup> Subsequent studies have shown similar findings in other PSC-IBD cohorts.<sup>25,121,123,124</sup> It is worth mentioning that the risk of CRC in PSC alone has not been well characterized, but is believed to be between that of the PSC-IBD and the general populations. With the above in mind, societal guidelines recommend that colonoscopic surveillance be performed at 1–2 year intervals from the time of PSC diagnosis in patients with PSC-IBD and approximately every five years in patients with PSC alone.<sup>6,125,126</sup>

With respect to CRC prevention in PSC-IBD, limited data suggest that ursodeoxycholic acid (UDCA) may play a chemopreventive role.<sup>127,128</sup> Until additional studies can confirm these benefits, the use of UDCA for this indication should only be considered in select patients (*e.g.*, those with a strong family history of colon cancer).<sup>6</sup>

### 10.3. Autoimmune hepatitis

PSC-AIH overlap syndrome is seen in up to 35% of pediatric patients and 5% of adult patients with PSC and may develop years after the initial PSC diagnosis.<sup>111,129,130</sup> PSC-AIH overlap syndrome cases typically fulfill criteria (serologic, histologic, and cholangiographic) for both diseases. A clinical scenario suggesting this syndrome would be: (i) a patient with AIH who does not respond entirely to immunosuppressive therapy and subsequently develops a cholestatic serum liver profile or (ii) a patient with features of PSC but also aminotransferase levels that are elevated >3-fold the upper limit of normal. Patients with suspected PSC-AIH overlap syndrome, particularly those in whom AIH seems to be the “dominant” disease, should be treated with immunosuppressive therapy.<sup>6</sup>

## 11. Complications

Clinical complications of PSC include cholelithiasis, choledocholithiasis, dominant biliary strictures, recurrent acute bacterial cholangitis, and CCA. Other complications and symptoms in patients with PSC include those associated with: (i) chronic cholestasis, *e.g.*, fat-soluble vitamin (A, D, E, K) and other micronutrient and mineral (*e.g.*, vitamin B12, zinc) deficiency, hepatic osteodystrophy, and pruritus,<sup>39,131</sup> and (ii) cirrhosis, *e.g.*, portal hypertension, varices, ascites, and hepatocellular carcinoma, which are managed similarly to patients with non-PSC related cirrhosis.<sup>132–134</sup> Several of these complications are discussed further below.

### 11.1. Gallbladder disorders and choledocholithiasis

The spectrum of gallbladder disorders in PSC includes stones,<sup>135</sup> acalculous cholecystitis,<sup>136</sup> gallbladder polyps, and gallbladder carcinoma.<sup>137</sup> Recent case series have found that adenocarcinomas of the gallbladder can be harbored in polyps <1 cm in size;<sup>138</sup> thus for gallbladder lesions in PSC, regardless of symptoms or size (and especially if >1 cm), the general recommendation is cholecystectomy.<sup>137</sup>

Choledocholithiasis is present in approximately 8% of patients with PSC based on radiologic series.<sup>139</sup> This constitutes an indication for ERCP<sup>140</sup> together with prophylactic peri-procedural antibiotics (*e.g.*, ciprofloxacin for 3–7 days).<sup>141,142</sup>



## 11.2. Dominant strictures

Approximately 45% of patients with PSC will develop a dominant stricture, typically presenting with progressive jaundice, pruritus, bacterial cholangitis, and/or right upper quadrant pain. A “dominant stricture” is loosely defined as a stenosis with a diameter  $\leq$  1.5 mm in the common bile duct or  $\leq$  1 mm in the hepatic duct. ERC is indicated for therapeutic dilation and biliary sampling (*e.g.*, brushings or biopsies to rule out dysplasia).<sup>143–146</sup> Stenting may be additionally performed, but the latter alone may be sufficient and may incur fewer complications.<sup>147–149</sup>

## 11.3. Cholangiocarcinoma

The most ominous neoplastic complication of PSC is CCA, which has an estimated annual incidence of 1% and lifetime occurrence of 15% in patients with PSC.<sup>23–25,124</sup> Many of the signs and symptoms of CCA are similar to those of PSC itself, and robust predictors are lacking, thus making early detection challenging.<sup>1,150</sup> CCA surveillance is therefore recommended in patients with PSC (Fig. 3).<sup>1,6</sup>

Early diagnosis of CCA is hindered by the poor performance characteristics of existing diagnostic techniques.<sup>1,151</sup> With respect to serologic tests, carbohydrate antigen 19-9 is the primary biomarker, although its sensitivity is suboptimal and varies depending on the cutoff used.<sup>48,152</sup> Other limitations to serum CA19-9 include the facts that it: (i) can also be elevated in pancreatic malignancies, acute cholangitis, non-malignant pancreatobiliary obstruction, and active smokers and (ii) is not synthesized in individuals negative for Lewis<sup>a</sup> blood antigen, which corresponds to 6% and 22% of US Whites and Blacks, respectively.<sup>6,153</sup> Non-serologic techniques include biliary brush cytology and epithelial biopsies, which are a mainstay of diagnostic testing but only 30–40% sensitive, in part due to the desmoplastic nature of PSC.<sup>54</sup> Fluorescence *in situ* hybridization (FISH) can be additionally performed on biliary brush cytology specimens, which improves sensitivity over conventional cytology by approximately 20%.<sup>154–156</sup> Newer techniques have also been described,<sup>54</sup> with cholangioscopy-based methods seeming to be particularly promising.<sup>157</sup>

Treatment of CCA is discussed in subsection 12.2.

## 11.4. Cirrhosis and portal hypertension

Patients with PSC who progress to cirrhosis may experience complications of portal hypertension similar to patients with other etiologies of cirrhosis. Such complications include development of esophageal (and other) varices, ascites, and hepatocellular carcinoma, and their manifestations, surveillance, and treatment are similar to those of patients with non-PSC related cirrhosis.<sup>132–134</sup>

## 11.5. Peristomal varices and pouchitis following proctocolectomy

The decision of whether to pursue end ileostomy versus ileal pouch–anal anastomosis (IPAA) after colectomy (*e.g.*, for medically refractory UC or colonic dysplasia/CRC) is influenced by the presence of PSC. In a study of patients with PSC-UC who underwent colectomy, 8 of 31 patients (26%) with ileostomy developed peristomal varices and subsequent bleeding, whereas none of the 40 patients who underwent IPAA developed

perianastomotic varices or bleeding.<sup>158</sup> Therefore, and because bleeding peristomal varices may be life-threatening and have few treatment options, IPAA is typically recommended over ileostomy in patients with PSC who require colectomy.<sup>6,24,158,159</sup> The disadvantage of IPAA in patients with PSC-UC compared to those with UC alone is the higher risk of acute and chronic pouchitis.<sup>160,161</sup>

## 12. Treatment of PSC

### 12.1. Pharmacotherapy

Targeted medical therapy for PSC has yet to be established despite clinical trials of numerous pharmacologic agents.<sup>35,63,68</sup> The most extensively investigated drug in PSC is UDCA, a hydrophilic bile acid.<sup>162</sup> Though some studies have found beneficial effects with UDCA in PSC, societal guidelines recommend against it or offer no specific recommendation regarding its use in PSC.<sup>6,163</sup> However, given the limitations of the existing trials and the suggestion of clinical benefits in some patients,<sup>164</sup> a therapeutic trial of intermediate-dose UDCA in select patients has been proposed as new therapies are awaited.<sup>44</sup> Other pharmacotherapies currently under investigation for PSC, including but not limited to obeticholic acid, have been recently reviewed elsewhere.<sup>165,166</sup>

### 12.2. Surgical therapy

For biliary complications such as dominant strictures, post-transplant leaks and strictures, and acute cholangitis, endoscopic management (coupled with supportive medical care such as antibiotics to cover bacterial microflora (*e.g.*, ciprofloxacin, metronidazole, piperacillin-tazobactam, ertapenem)) has largely replaced surgical intervention.<sup>140,167–170</sup> Currently, the two main hepatobiliary surgical interventions for PSC or associated CCA are hepatic resection and LT.

**12.2.1. Resection of cholangiocarcinoma**—Resection of CCA in the context of PSC is discouraged for several reasons, including the potential for multifocal CCA (*i.e.*, field defect) and underlying hepatic dysfunction. Nevertheless, if a patient presents with a CCA that is surgically resectable, does not have advanced hepatic fibrosis, and is not a candidate for LT, an attempt at surgical resection should be considered, although median 5-year survival is at best only 25%.<sup>171,172</sup>

**12.2.2. Orthotopic liver transplantation**—LT is the only potentially curative treatment for end-stage PSC and has 1- and 5-year survival rates surpassing 90% and 80%, respectively.<sup>173</sup> Recurrent PSC remains a problem after LT and can occur in up to 34% of deceased donor and 67% of living-related donor LTs.<sup>174–176</sup> Median survival without redo-LT has not been well-studied but is estimated to be approximately 4 years.<sup>177</sup> Risk factors for recurrent PSC include IBD with intact colon, prolonged ischemic time, acute cellular rejection, cytomegalovirus infection, and lymphocytotoxic cross match.<sup>9,178,179</sup>

LT for hilar CCA merits additional discussion. Historically, CCA was regarded as a contraindication to LT. However, specialized centers have shown favorable outcomes for patients with stage I or II hilar CCA (with or without PSC) using a protocol of neoadjuvant

radiosensitizing chemotherapy, external beam radiotherapy, and ERC-delivered transluminal brachytherapy followed by oral capecitabine up to the time of staging laparotomy (performed immediately prior to LT to re-confirm candidacy).<sup>180,181</sup> Based on a 12 LT center study, 5-year recurrence-free survival was 65% after excluding the 12% of patients who dropped out pre-LT (*e.g.*, could not tolerate regimen).<sup>182</sup> Notably, incidental CCA (tumor <1 cm in diameter discovered during sectioning of the explant) does not appear to significantly decrease survival.<sup>183</sup>

### 13. Conclusion

PSC is a chronic, cholestatic, premalignant, progressive cholangiopathy of unknown etiopathogenesis. Patients with PSC may develop various disease-related symptoms and complications over the course of illness. Management can be challenging and often requires a multi-disciplinary approach. Pharmacotherapy to halt the progression of PSC has yet to be established, but LT is an option in selected patients with PSC-associated hepatic failure or hepatobiliary malignancy. More studies are needed to better understand the etiopathogenesis of this disease and identify safe and effective treatment.

### Acknowledgments

This work was supported by US NIH grants R21DK100897 (to Dr. C. L. Bowlus).

### References

1. Tabibian JH, Lindor KD. Challenges of cholangiocarcinoma detection in patients with primary sclerosing cholangitis. *J Anal Oncol.* 2012; 1:50–55.
2. Weismüller TJ, Wedemeyer J, Kubicka S, Strassburg CP, Manns MP. The challenges in primary sclerosing cholangitis--aetiopathogenesis, autoimmunity, management and malignancy. *J Hepatol.* 2008; 48(Suppl 1):S38–S57. [PubMed: 18304683]
3. Karlsen TH, Schrumpf E, Boberg KM. Update on primary sclerosing cholangitis. *Dig Liver Dis.* 2010; 42:390–400. [PubMed: 20172772]
4. Jussila A, Virta LJ, Pukkala E, Färkkilä MA. Malignancies in patients with inflammatory bowel disease: a nationwide register study in Finland. *Scand J Gastroenterol.* 2013; 48:1405–1413. [PubMed: 24131389]
5. Tabibian JH, Lindor KD. Primary sclerosing cholangitis: a review and update on therapeutic developments. *Expert Rev Gastroenterol Hepatol.* 2013; 7:103–114. [PubMed: 23363260]
6. Chapman R, Fevery J, Kalloo A, et al. Diagnosis and management of primary sclerosing cholangitis. *Hepatology.* 2010; 51:660–678. [PubMed: 20101749]
7. United Network for Organ Sharing. Liver transplants performed for recipients age 18+ at time of transplant in the US from January 1, 2005 to October 31, 2014 by primary diagnosis at time of transplant and year of transplant. Data Report Request. Jan 15.2015 2015
8. Bjørø K, Brandsaeter B, Foss A, Schrumpf E. Liver transplantation in primary sclerosing cholangitis. *Semin Liver Dis.* 2006; 26:69–79. [PubMed: 16496235]
9. Alabraba E, Nightingale P, Gunson B, et al. A re-evaluation of the risk factors for the recurrence of primary sclerosing cholangitis in liver allografts. *Liver Transpl.* 2009; 15:330–340. [PubMed: 19243003]
10. Landaverde C, Ng V, Sato A, Tabibian J, Durazo F, Busuttil R. De-novo cholangiocarcinoma in native common bile duct remnant following OLT for primary sclerosing cholangitis. *Ann Hepatol.* 2009; 8:379–383. [PubMed: 20009140]
11. Angulo P, Lindor KD. Primary sclerosing cholangitis. *Hepatology.* 1999; 30:325–332. [PubMed: 10385674]

12. Bambha K, Kim WR, Talwalkar J, et al. Incidence, clinical spectrum, and outcomes of primary sclerosing cholangitis in a United States community. *Gastroenterology*. 2003; 125:1364–1369. [PubMed: 14598252]
13. Toy E, Balasubramanian S, Selmi C, Li CS, Bowlus CL. The prevalence, incidence and natural history of primary sclerosing cholangitis in an ethnically diverse population. *BMC Gastroenterol*. 2011; 11:83. [PubMed: 21767410]
14. Bowlus CL, Li CS, Karlsen TH, Lie BA, Selmi C. Primary sclerosing cholangitis in genetically diverse populations listed for liver transplantation: unique clinical and human leukocyte antigen associations. *Liver Transpl*. 2010; 16:1324–1330. [PubMed: 21031548]
15. Hurlburt KJ, McMahon BJ, Deubner H, et al. Prevalence of autoimmune liver disease in Alaska Natives. *Am J Gastroenterol*. 2002; 97:2402–2407. [PubMed: 12358264]
16. Kaplan GG, Laupland KB, Butzner D, Urbanski SJ, Lee SS. The burden of large and small duct primary sclerosing cholangitis in adults and children: a population-based analysis. *Am J Gastroenterol*. 2007; 102:1042–1049. [PubMed: 17313496]
17. Card TR, Solaymani-Dodaran M, West J. Incidence and mortality of primary sclerosing cholangitis in the UK: a population-based cohort study. *J Hepatol*. 2008; 48:939–944. [PubMed: 18433916]
18. Boonstra K, Weersma RK, van Erpecum KJ, et al. Population-based epidemiology, malignancy risk, and outcome of primary sclerosing cholangitis. *Hepatology*. 2013; 58:2045–2055. [PubMed: 23775876]
19. Ngu JH, Gearry RB, Wright AJ, Stedman CA. Inflammatory bowel disease is associated with poor outcomes of patients with primary sclerosing cholangitis. *Clin Gastroenterol Hepatol*. 2011; 9:1092–1097. [PubMed: 21893134]
20. Molodecky NA, Kareemi H, Parab R, et al. Incidence of primary sclerosing cholangitis: a systematic review and meta-analysis. *Hepatology*. 2011; 53:1590–1599. [PubMed: 21351115]
21. Ang TL, Fock KM, Ng TM, Teo EK, Chua TS, Tan JY. Clinical profile of primary sclerosing cholangitis in Singapore. *J Gastroenterol Hepatol*. 2002; 17:908–913. [PubMed: 12164967]
22. Tanaka A, Takikawa H. Geoepidemiology of primary sclerosing cholangitis: a critical review. *J Autoimmun*. 2013; 46:35–40. [PubMed: 23932346]
23. Boberg KM, Bergquist A, Mitchell S, et al. Cholangiocarcinoma in primary sclerosing cholangitis: risk factors and clinical presentation. *Scand J Gastroenterol*. 2002; 37:1205–1211. [PubMed: 12408527]
24. Wiesner RH, Grambsch PM, Dickson ER, et al. Primary sclerosing cholangitis: natural history, prognostic factors and survival analysis. *Hepatology*. 1989; 10:430–436. [PubMed: 2777204]
25. Claessen MM, Vleggaar FP, Tytgat KM, Siersema PD, van Buuren HR. High lifetime risk of cancer in primary sclerosing cholangitis. *J Hepatol*. 2009; 50:158–164. [PubMed: 19012991]
26. Fausa O, Schruppf E, Elgjo K. Relationship of inflammatory bowel disease and primary sclerosing cholangitis. *Semin Liver Dis*. 1991; 11:31–39. [PubMed: 2047887]
27. Boonstra K, van Erpecum KJ, van Nieuwkerk KM, et al. Primary sclerosing cholangitis is associated with a distinct phenotype of inflammatory bowel disease. *Inflamm Bowel Dis*. 2012; 18:2270–2276. [PubMed: 22407885]
28. Shorbagi A, Bayraktar Y. Primary sclerosing cholangitis--what is the difference between east and west? *World J Gastroenterol*. 2008; 14:3974–3981. [PubMed: 18609680]
29. Wiesner RH, LaRusso NF. Clinicopathologic features of the syndrome of primary sclerosing cholangitis. *Gastroenterology*. 1980; 79:200–206. [PubMed: 7399227]
30. MacCarty RL, LaRusso NF, Wiesner RH, Ludwig J. Primary sclerosing cholangitis: findings on cholangiography and pancreatography. *Radiology*. 1983; 149:39–44. [PubMed: 6412283]
31. Talwalkar JA, Lindor KD. Primary sclerosing cholangitis. *Inflamm Bowel Dis*. 2005; 11:62–72. [PubMed: 15674115]
32. el-Shabrawi M, Wilkinson ML, Portmann B, et al. Primary sclerosing cholangitis in childhood. *Gastroenterology*. 1987; 92:1226–1235. [PubMed: 3493939]
33. Wilschanski M, Chait P, Wade JA, et al. Primary sclerosing cholangitis in 32 children: clinical, laboratory, and radiographic features, with survival analysis. *Hepatology*. 1995; 22:1415–1422. [PubMed: 7590657]

34. Broomé U, Olsson R, Lööf L, et al. Natural history and prognostic factors in 305 Swedish patients with primary sclerosing cholangitis. *Gut*. 1996; 38:610–615. [PubMed: 8707097]
35. Tabibian JH, Weeding E, Jorgensen RA, et al. Randomised clinical trial: vancomycin or metronidazole in patients with primary sclerosing cholangitis - a pilot study. *Aliment Pharmacol Ther*. 2013; 37:604–612. [PubMed: 23384404]
36. Holubitsky IB, McKenzie AD. Primary sclerosing cholangitis of the extrahepatic bile ducts. *Can J Surg*. 1964; 7:277–283. [PubMed: 14176974]
37. Burak KW, Angulo P, Lindor KD. Is there a role for liver biopsy in primary sclerosing cholangitis? *Am J Gastroenterol*. 2003; 98:1155–1158. [PubMed: 12809842]
38. Lazaridis KN, Strazzabosco M, Lorusso NF. The cholangiopathies: disorders of biliary epithelia. *Gastroenterology*. 2004; 127:1565–1577. [PubMed: 15521023]
39. Tabibian, JH., Lazaridis, KN., LaRusso, NF. Primary Sclerosing Cholangitis. In: Jarnigan, editor. *Blumgart's Surgery of the Liver, Biliary Tract and Pancreas*. 6. Vol. 1. Philadelphia, PA: Saunders; 2017.
40. Balasubramaniam K, Wiesner RH, LaRusso NF. Primary sclerosing cholangitis with normal serum alkaline phosphatase activity. *Gastroenterology*. 1988; 95:1395–1398. [PubMed: 3169503]
41. Al Mamari S, Djordjevic J, Halliday JS, Chapman RW. Improvement of serum alkaline phosphatase to <1.5 upper limit of normal predicts better outcome and reduced risk of cholangiocarcinoma in primary sclerosing cholangitis. *J Hepatol*. 2013; 58:329–334. [PubMed: 23085647]
42. Lindström L, Hultcrantz R, Boberg KM, Friis-Liby I, Bergquist A. Association between reduced levels of alkaline phosphatase and survival times of patients with primary sclerosing cholangitis. *Clin Gastroenterol Hepatol*. 2013; 11:841–846. [PubMed: 23353641]
43. Stanich PP, Björnsson E, Gossard AA, Enders F, Jorgensen R, Lindor KD. Alkaline phosphatase normalization is associated with better prognosis in primary sclerosing cholangitis. *Dig Liver Dis*. 2011; 43:309–313. [PubMed: 21251891]
44. Tabibian JH, Lindor KD. Ursodeoxycholic acid in primary sclerosing cholangitis: if withdrawal is bad, then administration is good (right?). *Hepatology*. 2014; 60:785–788. [PubMed: 24752961]
45. Hilscher M, Enders FB, Carey EJ, Lindor KD, Tabibian JH. Alkaline phosphatase normalization is a biomarker of improved survival in primary sclerosing cholangitis. *Ann Hepatol*. 2016; 15:246–253. [PubMed: 26845602]
46. Lee YM, Kaplan MM. Primary sclerosing cholangitis. *N Engl J Med*. 1995; 332:924–933. [PubMed: 7877651]
47. Czaja AJ. Frequency and nature of the variant syndromes of autoimmune liver disease. *Hepatology*. 1998; 28:360–365. [PubMed: 9695997]
48. Charatcharoenwithaya P, Enders FB, Halling KC, Lindor KD. Utility of serum tumor markers, imaging, and biliary cytology for detecting cholangiocarcinoma in primary sclerosing cholangitis. *Hepatology*. 2008; 48:1106–1117. [PubMed: 18785620]
49. Angulo P, Peter JB, Gershwin ME, et al. Serum autoantibodies in patients with primary sclerosing cholangitis. *J Hepatol*. 2000; 32:182–187. [PubMed: 10707856]
50. Chapman RW, Arborgh BA, Rhodes JM, et al. Primary sclerosing cholangitis: a review of its clinical features, cholangiography, and hepatic histology. *Gut*. 1980; 21:870–877. [PubMed: 7439807]
51. Hirano K, Tada M, Mizuno S, et al. Lower incidence of biliary carcinoma in patients with primary sclerosing cholangitis and high serum levels of immunoglobulin E. *Clin Gastroenterol Hepatol*. 2012; 10:79–83. [PubMed: 21963955]
52. Navaneethan U, Venkatesh PG, Kiran RP. Immunoglobulin E level and its significance in patients with primary sclerosing cholangitis. *Clin Gastroenterol Hepatol*. 2012; 10:563. author reply 563–564. [PubMed: 22289874]
53. Tabibian JH, Enders F, Imam MH, et al. Association between serum IgE level and adverse clinical endpoints in primary sclerosing cholangitis. *Ann Hepatol*. 2014; 13:384–389. [PubMed: 24756015]
54. Tabibian JH, Visrodia KH, Levy MJ, Gostout CJ. Advanced endoscopic imaging of indeterminate biliary strictures. *World J Gastrointest Endosc*. 2015; 7:1268–1278. [PubMed: 26675379]

55. Bangarulingam SY, Gossard AA, Petersen BT, Ott BJ, Lindor KD. Complications of endoscopic retrograde cholangiopancreatography in primary sclerosing cholangitis. *Am J Gastroenterol.* 2009; 104:855–860. [PubMed: 19259076]
56. Dave M, Elmunzer BJ, Dwamena BA, Higgins PD. Primary sclerosing cholangitis: meta-analysis of diagnostic performance of MR cholangiopancreatography. *Radiology.* 2010; 256:387–396. [PubMed: 20656832]
57. Vitellas KM, El-Dieb A, Vaswani KK, et al. MR cholangiopancreatography in patients with primary sclerosing cholangitis: interobserver variability and comparison with endoscopic retrograde cholangiopancreatography. *AJR Am J Roentgenol.* 2002; 179:399–407. [PubMed: 12130441]
58. Rouvière O, Yin M, Dresner MA, et al. MR elastography of the liver: preliminary results. *Radiology.* 2006; 240:440–448. [PubMed: 16864671]
59. Scheuer PJ. Ludwig Symposium on biliary disorders--part II. Pathologic features and evolution of primary biliary cirrhosis and primary sclerosing cholangitis. *Mayo Clin Proc.* 1998; 73:179–183. [PubMed: 9473003]
60. Ludwig J, Barham SS, LaRusso NF, et al. Morphologic features of chronic hepatitis associated with primary sclerosing cholangitis and chronic ulcerative colitis. *Hepatology.* 1981; 1:632–640. [PubMed: 7308996]
61. Ludwig J, Colina F, Poterucha JJ. Granulomas in primary sclerosing cholangitis. *Liver.* 1995; 15:307–312. [PubMed: 8609810]
62. de Vries EM, Verheij J, Hubscher SG, et al. Applicability and prognostic value of histologic scoring systems in primary sclerosing cholangitis. *J Hepatol.* 2015; 63:1212–1219. [PubMed: 26095184]
63. Tabibian JH, O'Hara SP, Lindor KD. Primary sclerosing cholangitis and the microbiota: current knowledge and perspectives on etiopathogenesis and emerging therapies. *Scand J Gastroenterol.* 2014; 49:901–908. [PubMed: 24990660]
64. O'Hara SP, Tabibian JH, Splinter PL, Larusso NF. The dynamic biliary epithelia: Molecules, pathways, and disease. *J Hepatol.* 2013; 58:575–582. [PubMed: 23085249]
65. Tabibian JH, Masyuk AI, Masyuk TV, O'Hara SP, LaRusso NF. Physiology of cholangiocytes. *Compr Physiol.* 2013; 3:541–565. [PubMed: 23720296]
66. Pollheimer MJ, Halilbasic E, Fickert P, Trauner M. Pathogenesis of primary sclerosing cholangitis. *Best Pract Res Clin Gastroenterol.* 2011; 25:727–739. [PubMed: 22117638]
67. Gupta A, Bowlus CL. Primary sclerosing cholangitis: etiopathogenesis and clinical management. *Front Biosci (Elite Ed).* 2012; 4:1683–1705. [PubMed: 22201985]
68. Tabibian JH, Talwalkar JA, Lindor KD. Role of the microbiota and antibiotics in primary sclerosing cholangitis. *Biomed Res Int.* 2013; 2013:389537. [PubMed: 24232746]
69. O'Mahony CA, Vierling JM. Etiopathogenesis of primary sclerosing cholangitis. *Semin Liver Dis.* 2006; 26:3–21. [PubMed: 16496229]
70. Tabibian JH, O'Hara SP, Larusso NF. Primary sclerosing cholangitis: the gut-liver axis. *Clin Gastroenterol Hepatol.* 2012; 10:819. [PubMed: 22343691]
71. Levy C, Lindor KD. Primary sclerosing cholangitis: epidemiology, natural history, and prognosis. *Semin Liver Dis.* 2006; 26:22–30. [PubMed: 16496230]
72. Lepage P, Häsler R, Spehlmann ME, et al. Twin study indicates loss of interaction between microbiota and mucosa of patients with ulcerative colitis. *Gastroenterology.* 2011; 141:227–236. [PubMed: 21621540]
73. Duboc H, Rajca S, Rainteau D, et al. Connecting dysbiosis, bile-acid dysmetabolism and gut inflammation in inflammatory bowel diseases. *Gut.* 2013; 62:531–539. [PubMed: 22993202]
74. Mistilis SP, Skyring AP, Goulston SJ. Effect of long-term tetracycline therapy, steroid therapy and colectomy in pericholangitis associated with ulcerative colitis. *Australas Ann Med.* 1965; 14:286–294. [PubMed: 5861251]
75. Pohl J, Ring A, Stremmel W, Stiehl A. The role of dominant stenoses in bacterial infections of bile ducts in primary sclerosing cholangitis. *Eur J Gastroenterol Hepatol.* 2006; 18:69–74. [PubMed: 16357622]



76. Olsson R, Björnsson E, Bäckman L, et al. Bile duct bacterial isolates in primary sclerosing cholangitis: a study of explanted livers. *J Hepatol.* 1998; 28:426–432. [PubMed: 9551680]
77. Hiramatsu K, Harada K, Tsuneyama K, et al. Amplification and sequence analysis of partial bacterial 16S ribosomal RNA gene in gallbladder bile from patients with primary biliary cirrhosis. *J Hepatol.* 2000; 33:9–18. [PubMed: 10905580]
78. Chen XM, O'Hara SP, Nelson JB, et al. Multiple TLRs are expressed in human cholangiocytes and mediate host epithelial defense responses to *Cryptosporidium parvum* via activation of NF-kappaB. *J Immunol.* 2005; 175:7447–7456. [PubMed: 16301652]
79. Mimura Y, Sakisaka S, Harada M, Sata M, Tanikawa K. Role of hepatocytes in direct clearance of lipopolysaccharide in rats. *Gastroenterology.* 1995; 109:1969–1976. [PubMed: 7498663]
80. Osnes T, Sandstad O, Skar V, Osnes M. Lipopolysaccharides and beta-glucuronidase activity in choledochal bile in relation to choledocholithiasis. *Digestion.* 1997; 58:437–443. [PubMed: 9383634]
81. Sasatomi K, Noguchi K, Sakisaka S, Sata M, Tanikawa K. Abnormal accumulation of endotoxin in biliary epithelial cells in primary biliary cirrhosis and primary sclerosing cholangitis. *J Hepatol.* 1998; 29:409–416. [PubMed: 9764987]
82. Tabibian JH, O'Hara SP, Splinter PL, Trussoni CE, Larusso NF. Cholangiocyte senescence via N-Ras activation is a characteristic of primary sclerosing cholangitis. *Hepatology.* 2014; 59:2263–2275. [PubMed: 24390753]
83. Mueller T, Beutler C, Picó AH, et al. Enhanced innate immune responsiveness and intolerance to intestinal endotoxins in human biliary epithelial cells contributes to chronic cholangitis. *Liver Int.* 2011; 31:1574–1588. [PubMed: 22093333]
84. Lichtman SN, Keku J, Clark RL, Schwab JH, Sartor RB. Biliary tract disease in rats with experimental small bowel bacterial overgrowth. *Hepatology.* 1991; 13:766–772. [PubMed: 2010172]
85. Yamada S, Ishii M, Liang LS, Yamamoto T, Toyota T. Small duct cholangitis induced by N-formyl L-methionine L-leucine L-tyrosine in rats. *J Gastroenterol.* 1994; 29:631–636. [PubMed: 8000512]
86. Davies YK, Cox KM, Abdullah BA, Safta A, Terry AB, Cox KL. Long-term treatment of primary sclerosing cholangitis in children with oral vancomycin: an immunomodulating antibiotic. *J Pediatr Gastroenterol Nutr.* 2008; 47:61–67. [PubMed: 18607270]
87. Silveira MG, Torok NJ, Gossard AA, et al. Minocycline in the treatment of patients with primary sclerosing cholangitis: results of a pilot study. *Am J Gastroenterol.* 2009; 104:83–88. [PubMed: 19098854]
88. Kim WR, Therneau TM, Wiesner RH, et al. A revised natural history model for primary sclerosing cholangitis. *Mayo Clin Proc.* 2000; 75:688–694.
89. Elfaki DA, Lindor KD. Antibiotics for the treatment of primary sclerosing cholangitis. *Am J Ther.* 2011; 18:261–265. [PubMed: 19770792]
90. Bergquist A, Montgomery SM, Bahmanyar S, et al. Increased risk of primary sclerosing cholangitis and ulcerative colitis in first-degree relatives of patients with primary sclerosing cholangitis. *Clin Gastroenterol Hepatol.* 2008; 6:939–943. [PubMed: 18674735]
91. Quigley EM, LaRusso NF, Ludwig J, et al. Familial occurrence of primary sclerosing cholangitis and ulcerative colitis. *Gastroenterology.* 1983; 85:1160–1165. [PubMed: 6618106]
92. Karlsen TH, Franke A, Melum E, et al. Genome-wide association analysis in primary sclerosing cholangitis. *Gastroenterology.* 2010; 138:1102–1111. [PubMed: 19944697]
93. Chapman RW, Varghese Z, Gaul R, Patel G, Kokinin N, Sherlock S. Association of primary sclerosing cholangitis with HLA-B8. *Gut.* 1983; 24:38–41. [PubMed: 6600227]
94. Donaldson PT, Farrant JM, Wilkinson ML, Hayllar K, Portmann BC, Williams R. Dual association of HLA DR2 and DR3 with primary sclerosing cholangitis. *Hepatology.* 1991; 13:129–133. [PubMed: 1988334]
95. Wiencke K, Karlsen TH, Boberg KM, et al. Primary sclerosing cholangitis is associated with extended HLA-DR3 and HLA-DR6 haplotypes. *Tissue Antigens.* 2007; 69:161–169. [PubMed: 17257319]



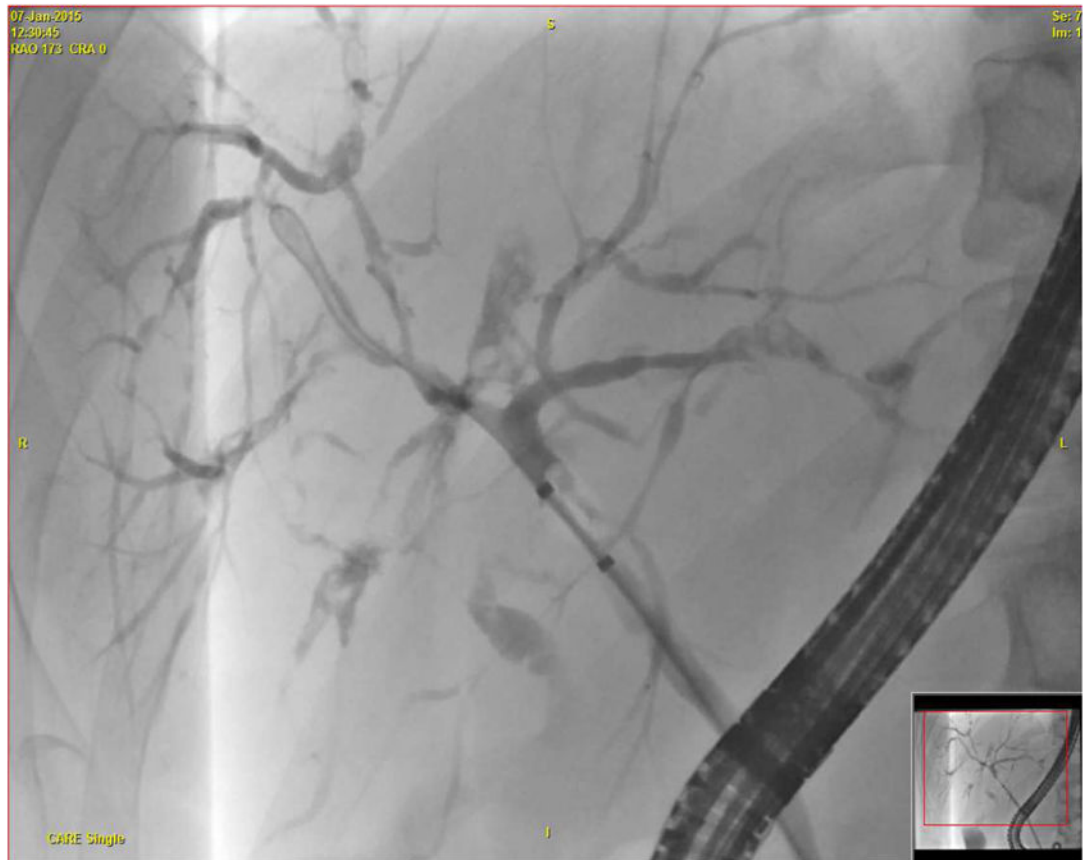
96. Norris S, Kondeatis E, Collins R, et al. Mapping MHC-encoded susceptibility and resistance in primary sclerosing cholangitis: the role of MICA polymorphism. *Gastroenterology*. 2001; 120:1475–1482. [PubMed: 11313318]
97. Coppé JP, Patil CK, Rodier F, et al. A human-like senescence-associated secretory phenotype is conserved in mouse cells dependent on physiological oxygen. *PLoS One*. 2010; 5:e9188. [PubMed: 20169192]
98. Davalos AR, Coppe JP, Campisi J, Desprez PY. Senescent cells as a source of inflammatory factors for tumor progression. *Cancer Metastasis Rev*. 2010; 29:273–283. [PubMed: 20390322]
99. Pollheimer MJ, Trauner M, Fickert P. Will we ever model PSC? - “it’s hard to be a PSC model!”. *Clin Res Hepatol Gastroenterol*. 2011; 35:792–804. [PubMed: 21703962]
100. Folseraas T, Melum E, Rausch P, et al. Extended analysis of a genome-wide association study in primary sclerosing cholangitis detects multiple novel risk loci. *J Hepatol*. 2012; 57:366–375. [PubMed: 22521342]
101. Smit JJ, Schinkel AH, Oude Elferink RP, et al. Homozygous disruption of the murine *mdr2* P-glycoprotein gene leads to a complete absence of phospholipid from bile and to liver disease. *Cell*. 1993; 75:451–462. [PubMed: 8106172]
102. van Nieuwerk CM, Groen AK, Ottenhoff R, et al. The role of bile salt composition in liver pathology of *mdr2* (–/–) mice: differences between males and females. *J Hepatol*. 1997; 26:138–145. [PubMed: 9148004]
103. Fickert P, Zollner G, Fuchsbichler A, et al. Ursodeoxycholic acid aggravates bile infarcts in bile duct-ligated and *Mdr2* knockout mice via disruption of cholangioles. *Gastroenterology*. 2002; 123:1238–1251. [PubMed: 12360485]
104. Fickert P, Fuchsbichler A, Wagner M, et al. Regurgitation of bile acids from leaky bile ducts causes sclerosing cholangitis in *Mdr2* (*Abcb4*) knockout mice. *Gastroenterology*. 2004; 127:261–274. [PubMed: 15236191]
105. Tabibian JH, Macura SI, O’Hara SP, et al. Micro-computed tomography and nuclear magnetic resonance imaging for noninvasive, live-mouse cholangiography. *Lab Invest*. 2013; 93:733–743. [PubMed: 23588707]
106. Porayko MK, Wiesner RH, LaRusso NF, et al. Patients with asymptomatic primary sclerosing cholangitis frequently have progressive disease. *Gastroenterology*. 1990; 98:1594–1602. [PubMed: 2338198]
107. Farrant JM, Hayllar KM, Wilkinson ML, et al. Natural history and prognostic variables in primary sclerosing cholangitis. *Gastroenterology*. 1991; 100:1710–1717. [PubMed: 1850376]
108. Takakura WR, Tabibian JH, Bowlus CL. The evolution of natural history of primary sclerosing cholangitis. *Curr Opin Gastroenterol*. 2017; 33:71–77. [PubMed: 28030370]
109. Angulo P, Maor-Kendler Y, Lindor KD. Small-duct primary sclerosing cholangitis: a long-term follow-up study. *Hepatology*. 2002; 35:1494–1500. [PubMed: 12029635]
110. Björnsson E, Olsson R, Bergquist A, et al. The natural history of small-duct primary sclerosing cholangitis. *Gastroenterology*. 2008; 134:975–980. [PubMed: 18395078]
111. Feldstein AE, Perrault J, El-Youssif M, Lindor KD, Freese DK, Angulo P. Primary sclerosing cholangitis in children: a long-term follow-up study. *Hepatology*. 2003; 38:210–217. [PubMed: 12830004]
112. Dickson ER, Murtaugh PA, Wiesner RH, et al. Primary sclerosing cholangitis: refinement and validation of survival models. *Gastroenterology*. 1992; 103:1893–1901. [PubMed: 1451982]
113. Kamath PS, Wiesner RH, Malinchoc M, et al. A model to predict survival in patients with end-stage liver disease. *Hepatology*. 2001; 33:464–470. [PubMed: 11172350]
114. Loftus EV Jr, Sandborn WJ, Tremaine WJ, et al. Risk of colorectal neoplasia in patients with primary sclerosing cholangitis. *Gastroenterology*. 1996; 110:432–440. [PubMed: 8566590]
115. Sinakos E, Samuel S, Enders F, Loftus EV Jr, Sandborn WJ, Lindor KD. Inflammatory bowel disease in primary sclerosing cholangitis: a robust yet changing relationship. *Inflamm Bowel Dis*. 2013; 19:1004–1009. [PubMed: 23502353]
116. Kugelmas M, Spiegelman P, Osgood MJ, et al. Different immunosuppressive regimens and recurrence of primary sclerosing cholangitis after liver transplantation. *Liver Transpl*. 2003; 9:727–732. [PubMed: 12827560]

117. Broomé U, Bergquist A. Primary sclerosing cholangitis, inflammatory bowel disease, and colon cancer. *Semin Liver Dis.* 2006; 26:31–41. [PubMed: 16496231]
118. O'Toole A, Alakkari A, Keegan D, Doherty G, Mulcahy H, O'Donoghue D. Primary sclerosing cholangitis and disease distribution in inflammatory bowel disease. *Clin Gastroenterol Hepatol.* 2012; 10:439–441. [PubMed: 22094024]
119. Rasmussen HH, Fallingborg JF, Mortensen PB, Vyberg M, Tage-Jensen U, Rasmussen SN. Hepatobiliary dysfunction and primary sclerosing cholangitis in patients with Crohn's disease. *Scand J Gastroenterol.* 1997; 32:604–610. [PubMed: 9200295]
120. Lundqvist K, Broomé U. Differences in colonic disease activity in patients with ulcerative colitis with and without primary sclerosing cholangitis: a case control study. *Dis Colon Rectum.* 1997; 40:451–456. [PubMed: 9106695]
121. Soetikno RM, Lin OS, Heidenreich PA, Young HS, Blackstone MO. Increased risk of colorectal neoplasia in patients with primary sclerosing cholangitis and ulcerative colitis: a meta-analysis. *Gastrointest Endosc.* 2002; 56:48–54. [PubMed: 12085034]
122. Broomé U, Löfberg R, Veress B, Eriksson LS. Primary sclerosing cholangitis and ulcerative colitis: evidence for increased neoplastic potential. *Hepatology.* 1995; 22:1404–1408. [PubMed: 7590655]
123. Brentnall TA, Haggitt RC, Rabinovitch PS, et al. Risk and natural history of colonic neoplasia in patients with primary sclerosing cholangitis and ulcerative colitis. *Gastroenterology.* 1996; 110:331–338. [PubMed: 8566577]
124. Kornfeld D, Ekblom A, Ihre T. Survival and risk of cholangiocarcinoma in patients with primary sclerosing cholangitis. A population-based study. *Scand J Gastroenterol.* 1997; 32:1042–1045. [PubMed: 9361178]
125. Farraye FA, Odze RD, Eaden J, et al. AGA medical position statement on the diagnosis and management of colorectal neoplasia in inflammatory bowel disease. *Gastroenterology.* 2010; 138:738–745. [PubMed: 20141808]
126. Leighton JA, Shen B, Baron TH, et al. ASGE guideline: endoscopy in the diagnosis and treatment of inflammatory bowel disease. *Gastrointest Endosc.* 2006; 63:558–565. [PubMed: 16564852]
127. Tung BY, Emond MJ, Haggitt RC, et al. Ursodiol use is associated with lower prevalence of colonic neoplasia in patients with ulcerative colitis and primary sclerosing cholangitis. *Ann Intern Med.* 2001; 134:89–95. [PubMed: 11177311]
128. Pardi DS, Loftus EV Jr, Kremers WK, Keach J, Lindor KD. Ursodeoxycholic acid as a chemopreventive agent in patients with ulcerative colitis and primary sclerosing cholangitis. *Gastroenterology.* 2003; 124:889–893. [PubMed: 12671884]
129. Gohlke F, Lohse AW, Dienes HP, et al. Evidence for an overlap syndrome of autoimmune hepatitis and primary sclerosing cholangitis. *J Hepatol.* 1996; 24:699–705. [PubMed: 8835745]
130. Kaya M, Angulo P, Lindor KD. Overlap of autoimmune hepatitis and primary sclerosing cholangitis: an evaluation of a modified scoring system. *J Hepatol.* 2000; 33:537–542. [PubMed: 11059857]
131. Zakharia K, Tabibian A, Lindor KD, Tabibian JH. Complications, symptoms, quality of life and pregnancy in cholestatic liver disease. *Liver Int.* 2017
132. Garcia-Tsao G, Sanyal AJ, Grace ND, Carey WD. Practice Guidelines Committee of American Association for Study of Liver Diseases; Practice Parameters Committee of American College of Gastroenterology. Prevention and management of gastroesophageal varices and variceal hemorrhage in cirrhosis. *Am J Gastroenterol.* 2007; 102:2086–2102. [PubMed: 17727436]
133. Runyon BA, AASLD. Introduction to the revised American Association for the Study of Liver Diseases Practice Guideline management of adult patients with ascites due to cirrhosis 2012. *Hepatology.* 2013; 57:1651–1653. [PubMed: 23463403]
134. Bruix J, Sherman M. American Association for the Study of Liver Diseases. Management of hepatocellular carcinoma: an update. *Hepatology.* 2011; 53:1020–1022. [PubMed: 21374666]
135. Brandt DJ, MacCarty RL, Charboneau JW, et al. Gallbladder disease in patients with primary sclerosing cholangitis. *AJR Am J Roentgenol.* 1988; 150:571–574. [PubMed: 3277348]

136. Jessurun J, Bolio-Solis A, Manivel JC. Diffuse lymphoplasmacytic acalculous cholecystitis: a distinctive form of chronic cholecystitis associated with primary sclerosing cholangitis. *Hum Pathol.* 1998; 29:512–517. [PubMed: 9596276]
137. Buckles DC, Lindor KD, Larusso NF, Petrovic LM, Gores GJ. In primary sclerosing cholangitis, gallbladder polyps are frequently malignant. *Am J Gastroenterol.* 2002; 97:1138–1142. [PubMed: 12014717]
138. Karlsen TH, Schrumpf E, Boberg KM. Gallbladder polyps in primary sclerosing cholangitis: not so benign. *Curr Opin Gastroenterol.* 2008; 24:395–399. [PubMed: 18408471]
139. Dodd GD 3rd, Niedzwiecki GA, Campbell WL, Baron RL. Bile duct calculi in patients with primary sclerosing cholangitis. *Radiology.* 1997; 203:443–447. [PubMed: 9114102]
140. Tabibian, JH., Baron, TH. Endoscopic Management of Biliary Obstruction. In: Lindor, KD., Carey, EJ., editors. *Cholestatic Liver Disease. 2.* Humana Press; 2014.
141. Kager LM, Sjouke B, van den Brand M, Naber TH, Ponsioen CY. The role of antibiotic prophylaxis in endoscopic retrograde cholangiopancreatography; a retrospective single-center evaluation. *Scand J Gastroenterol.* 2012; 47:245–250. [PubMed: 22242617]
142. Bai Y, Gao F, Gao J, Zou DW, Li ZS. Prophylactic antibiotics cannot prevent endoscopic retrograde cholangiopancreatography-induced cholangitis: a meta-analysis. *Pancreas.* 2009; 38:126–130. [PubMed: 19238021]
143. Wagner S, Gebel M, Meier P, et al. Endoscopic management of biliary tract strictures in primary sclerosing cholangitis. *Endoscopy.* 1996; 28:546–551. [PubMed: 8911801]
144. van Milligen de Wit AW, Rauws EA, van Bracht J, et al. Lack of complications following short-term stent therapy for extrahepatic bile duct strictures in primary sclerosing cholangitis. *Gastrointest Endosc.* 1997; 46:344–347. [PubMed: 9351039]
145. van Milligen de Wit AW, van Bracht J, Rauws EA, Jones EA, Tytgat GN, Huijbregtse K. Endoscopic stent therapy for dominant extrahepatic bile duct strictures in primary sclerosing cholangitis. *Gastrointest Endosc.* 1996; 44:293–299. [PubMed: 8885349]
146. Johnson GK, Saeian K, Geenen JE. Primary sclerosing cholangitis treated by endoscopic biliary dilation: review and long-term follow-up evaluation. *Curr Gastroenterol Rep.* 2006; 8:147–155. [PubMed: 16533478]
147. Baluyut AR, Sherman S, Lehman GA, Hoen H, Chalasani N. Impact of endoscopic therapy on the survival of patients with primary sclerosing cholangitis. *Gastrointest Endosc.* 2001; 53:308–312. [PubMed: 11231388]
148. Kaya M, Petersen BT, Angulo P, et al. Balloon dilation compared to stenting of dominant strictures in primary sclerosing cholangitis. *Am J Gastroenterol.* 2001; 96:1059–1066. [PubMed: 11316147]
149. Stiehl A, Rudolph G, Klötters-Plachky P, Sauer P, Walker S. Development of dominant bile duct stenoses in patients with primary sclerosing cholangitis treated with ursodeoxycholic acid: outcome after endoscopic treatment. *J Hepatol.* 2002; 36:151–156. [PubMed: 11830325]
150. Gulamhusein AF, Eaton JE, Tabibian JH, Atkinson EJ, Juran BD, Lazaridis KN. Duration of inflammatory bowel disease is associated with increased risk of cholangiocarcinoma in patients with primary sclerosing cholangitis and IBD. *Am J Gastroenterol.* 2016; 111:705–711. [PubMed: 27002801]
151. Chung YE, Kim MJ, Park YN, et al. Varying appearances of cholangiocarcinoma: radiologic-pathologic correlation. *Radiographics.* 2009; 29:683–700. [PubMed: 19448110]
152. Levy C, Lymp J, Angulo P, Gores GJ, Larusso N, Lindor KD. The value of serum CA 19-9 in predicting cholangiocarcinomas in patients with primary sclerosing cholangitis. *Dig Dis Sci.* 2005; 50:1734–1740. [PubMed: 16133981]
153. Brecher, M. *Technical Manual Of The American Association of Blood Banks.* 15. Vol. 15. Bethesda: American Association of Blood Banks; 2005. ABO, H, and Lewis Blood Groups and Structurally Related Antigens; p. 305-306.
154. Coté GA, Sherman S. Biliary stricture and negative cytology: what next? *Clin Gastroenterol Hepatol.* 2011; 9:739–743. [PubMed: 21554986]

155. Levy MJ, Baron TH, Clayton AC, et al. Prospective evaluation of advanced molecular markers and imaging techniques in patients with indeterminate bile duct strictures. *Am J Gastroenterol*. 2008; 103:1263–1273. [PubMed: 18477350]
156. Quinn KP, Tabibian JH, Lindor KD. Clinical implications of serial versus isolated biliary fluorescence in situ hybridization (FISH) polysomy in primary sclerosing cholangitis. *Scand J Gastroenterol*. 2017; 52:377–381. [PubMed: 27908204]
157. Njei B, McCarty TR, Varadarajulu S, Navaneethan U. Systematic review with meta-analysis: endoscopic retrograde cholangiopancreatography-based modalities for the diagnosis of cholangiocarcinoma in primary sclerosing cholangitis. *Aliment Pharmacol Ther*. 2016; 44:1139–1151. [PubMed: 27696456]
158. Kartheuser AH, Dozois RR, LaRusso NF, Wiesner RH, Ilstrup DM, Schleck CD. Comparison of surgical treatment of ulcerative colitis associated with primary sclerosing cholangitis: ileal pouch-anal anastomosis versus Brooke ileostomy. *Mayo Clin Proc*. 1996; 71:748–756. [PubMed: 8691895]
159. Tabibian JH, Abu Dayyeh BK, Gores GJ, Levy MJ. A novel, minimally invasive technique for management of peristomal varices. *Hepatology*. 2016; 63:1398–1400. [PubMed: 26044445]
160. Penna C, Dozois R, Tremaine W, et al. Pouchitis after ileal pouch-anal anastomosis for ulcerative colitis occurs with increased frequency in patients with associated primary sclerosing cholangitis. *Gut*. 1996; 38:234–239. [PubMed: 8801203]
161. Wasmuth HH, Tranø G, Endreseth BH, Wibe A, Rydning A, Myrvold HE. Primary sclerosing cholangitis and extraintestinal manifestations in patients with ulcerative colitis and ileal pouch-anal anastomosis. *J Gastrointest Surg*. 2010; 14:1099–1104. [PubMed: 20480253]
162. Triantos CK, Koukias NM, Nikolopoulou VN, Burroughs AK. Meta-analysis: ursodeoxycholic acid for primary sclerosing cholangitis. *Aliment Pharmacol Ther*. 2011; 34:901–910. [PubMed: 21883323]
163. European Association for the Study of the Liver. EASL Clinical Practice Guidelines: management of cholestatic liver diseases. *J Hepatol*. 2009; 51:237–267. [PubMed: 19501929]
164. Wunsch E, Trottier J, Milkiewicz M, et al. Prospective evaluation of ursodeoxycholic acid withdrawal in patients with primary sclerosing cholangitis. *Hepatology*. 2014; 60:931–940. [PubMed: 24519384]
165. Ali AH, Tabibian JH, Lindor KD. Update on pharmacotherapies for cholestatic liver disease. *Hepatol Commun*. 2017; 1:7–17. [PubMed: 29404429]
166. Hu RW, Carey EJ, Lindor KD, Tabibian JH. Curcumin in hepatobiliary disease: pharmacotherapeutic properties and emerging potential clinical applications. *Ann Hepatol*. 2017; 16:835–841. [PubMed: 29055920]
167. Cameron JL, Pitt HA, Zinner MJ, et al. Resection of hepatic duct bifurcation and transhepatic stenting for sclerosing cholangitis. *Ann Surg*. 1988; 207:614–622. [PubMed: 3377571]
168. Visrodia KH, Tabibian JH, Baron TH. Endoscopic management of benign biliary strictures. *World J Gastrointest Endosc*. 2015; 7:1003–1013. [PubMed: 26322153]
169. Tabibian JH, Asham EH, Goldstein L, et al. Endoscopic treatment with multiple stents for post-liver-transplantation nonanastomotic biliary strictures. *Gastrointest Endosc*. 2009; 69:1236–1243. [PubMed: 19249040]
170. Tabibian JH, Asham EH, Han S, et al. Endoscopic treatment of postorthotopic liver transplantation anastomotic biliary strictures with maximal stent therapy (with video). *Gastrointest Endosc*. 2010; 71:505–512. [PubMed: 20189508]
171. Iwatsuki S, Todo S, Marsh JW, et al. Treatment of hilar cholangiocarcinoma (Klatskin tumors) with hepatic resection or transplantation. *J Am Coll Surg*. 1998; 187:358–364. [PubMed: 9783781]
172. Ahrendt SA, Pitt HA, Kalloo AN, et al. Primary sclerosing cholangitis: resect, dilate, or transplant? *Ann Surg*. 1998; 227:412–423. [PubMed: 9527065]
173. Graziadei IW, Wiesner RH, Batts KP, et al. Recurrence of primary sclerosing cholangitis following liver transplantation. *Hepatology*. 1999; 29:1050–1056. [PubMed: 10094945]
174. Vera A, Moledina S, Gunson B, et al. Risk factors for recurrence of primary sclerosing cholangitis of liver allograft. *Lancet*. 2002; 360:1943–1944. [PubMed: 12493264]

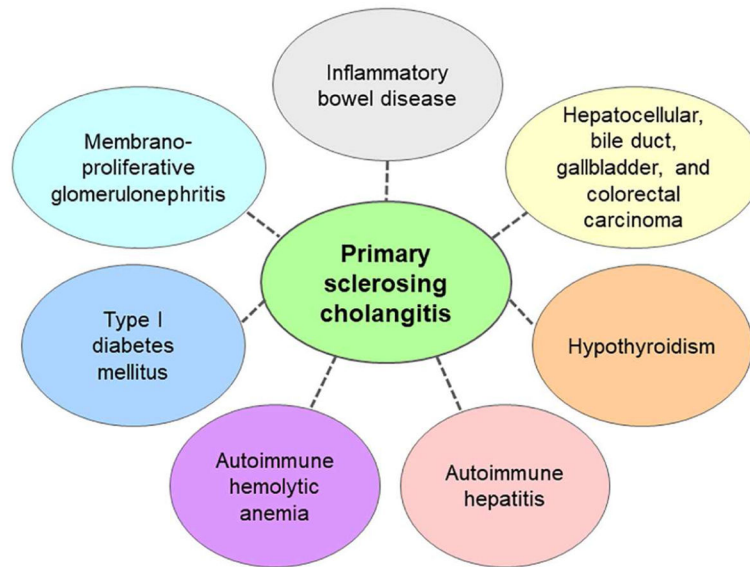
175. Egawa H, Taira K, Teramukai S, et al. Risk factors for recurrence of primary sclerosing cholangitis after living donor liver transplantation: a single center experience. *Dig Dis Sci.* 2009; 54:1347–1354. [PubMed: 19267192]
176. Tamura S, Sugawara Y, Kaneko J, Matsui Y, Togashi J, Makuuchi M. Recurrence of primary sclerosing cholangitis after living donor liver transplantation. *Liver Int.* 2007; 27:86–94. [PubMed: 17241386]
177. Campsen J, Zimmerman MA, Trotter JF, et al. Clinically recurrent primary sclerosing cholangitis following liver transplantation: a time course. *Liver Transpl.* 2008; 14:181–185. [PubMed: 18236392]
178. Cholongitas E, Shusang V, Papatheodoridis GV, et al. Risk factors for recurrence of primary sclerosing cholangitis after liver transplantation. *Liver Transpl.* 2008; 14:138–143. [PubMed: 18236447]
179. Alexander J, Lord JD, Yeh MM, Cuevas C, Bakthavatsalam R, Kowdley KV. Risk factors for recurrence of primary sclerosing cholangitis after liver transplantation. *Liver Transpl.* 2008; 14:245–251. [PubMed: 18236405]
180. De Vreede I, Steers JL, Burch PA, et al. Prolonged disease-free survival after orthotopic liver transplantation plus adjuvant chemoradiation for cholangiocarcinoma. *Liver Transpl.* 2000; 6:309–316. [PubMed: 10827231]
181. Rea DJ, Heimbach JK, Rosen CB, et al. Liver transplantation with neoadjuvant chemoradiation is more effective than resection for hilar cholangiocarcinoma. *Ann Surg.* 2005; 242:451–458. [PubMed: 16135931]
182. Darwish Murad S, Kim WR, Harnois DM, et al. Efficacy of neoadjuvant chemoradiation, followed by liver transplantation, for perihilar cholangiocarcinoma at 12 US centers. *Gastroenterology.* 2012; 143:88–98. [PubMed: 22504095]
183. Goss JA, Shackleton CR, Farmer DG, et al. Orthotopic liver transplantation for primary sclerosing cholangitis. A 12-year single center experience. *Ann Surg.* 1997; 225:472–481. [PubMed: 9193175]



**Fig. 1. Typical cholangiographic findings of primary sclerosing cholangitis**

Endoscopic retrograde cholangiography showing the typical cholangiographic findings of primary sclerosing cholangitis with multifocal stricturing and dilatation of the bile ducts.

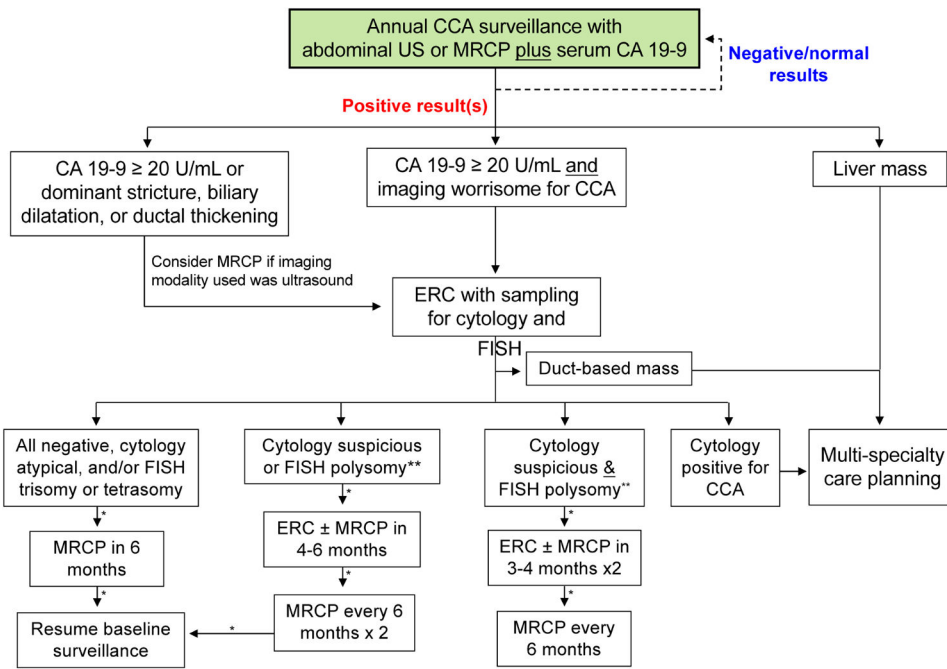




**Fig. 2. Diseases associated with primary sclerosing cholangitis (PSC)**

It is worth mentioning that primary sclerosing cholangitis has the strongest association with inflammatory bowel disease (IBD), which is coexistent in approximately 70% of individuals with PSC. Among patients with PSC-IBD, the lifetime risk of colorectal cancer is estimated at 30× that of the general population and 5× that of individuals with IBD only.





**Fig. 3. Cholangiocarcinoma surveillance in patients with primary sclerosing cholangitis**  
 \*Assumes clinical stability and absence of new signs or symptoms; serum CA 19-9 and liver biochemistries to be checked along with ERC or MRCP, and cytology and FISH to be checked with ERC. \*\*Consider early referral to transplant center if progressive worsening of serum tests or other signs or symptoms. Abbreviations: CA 19-9, carbohydrate antigen 19-9; CCA, cholangiocarcinoma; ERC, endoscopic retrograde cholangiography; FISH, fluorescence *in situ* hybridization; MRCP, magnetic resonance cholangiopancreatography; US, ultrasonography.

**Table 1**

Causes of secondary sclerosing cholangitis and mimics of PSC.

Causes	Disease
Infectious	AIDS cholangiopathy ( <i>e.g.</i> , <i>C. parvum</i> , CMV)
	Helminthic infection ( <i>e.g.</i> , <i>Clonorchis</i> , <i>Opisthorchis</i> , <i>Ascaris</i> )
	Recurrent pyogenic cholangitis ( <i>i.e.</i> , “oriental cholangiohepatitis”)
Chronic intrinsic or extrinsic compression (benign or malignant)	Mirizzi syndrome
	Cholangiocarcinoma
	Diffuse intrahepatic malignancy
	Compressive lymphadenopathy
	Portal hypertensive biliopathy
	Post-operative strictures
	Chronic pancreatitis
Immunologic	IgG4-associated cholangiopathy
	Eosinophilic cholangitis
	Mast cell cholangiopathy
	Histiocytosis X
	Systemic vasculitis
	Hepatic allograft rejection
	Primary biliary cirrhosis
Ischemic	Post-transplant nonanastomotic strictures
	Post-intraarterial chemotherapy
	Post-radiation therapy
Congenital and/or idiopathic	Choledochal cyst ( <i>e.g.</i> , Caroli’s disease)
	Progressive familial intrahepatic cholestasis

Abbreviations: AIDS, acquired immune deficiency syndrome; CMV, cytomegalovirus; IgG4, immunoglobulin G subclass 4; PSC, primary sclerosing cholangitis.

**Table 2**

Variants of primary sclerosing cholangitis: terms and features.

<b>Diagnostic term</b>	<b>Cholangiography</b>	<b>Liver histology</b>
Classic PSC	Multifocal intrahepatic and extrahepatic strictures and resultant segmental proximal ductal dilation	Typical ( <i>i.e.</i> , non-suppurative paucicellular cholangitis, periductal fibrosis, ductular reaction, and ductopenia)
Intrahepatic PSC	Multifocal intrahepatic strictures and resultant proximal segmental ductal dilation	Typical
Extrahepatic PSC	Extrahepatic strictures and resultant segmental proximal ductal dilation	Non-diagnostic, particularly in early disease
Small-duct PSC	Normal	Typical

All of these variants will generally present with a cholestatic pattern on serum laboratory studies.