

UC San Diego

UC San Diego Previously Published Works

Title

Continuous Popliteal-Sciatic Blocks for Postoperative Analgesia

Permalink

<https://escholarship.org/uc/item/35j6495b>

Journal

Anesthesia & Analgesia, Publish Ahead of Print(&NA;)

ISSN

0003-2999

Authors

Sztain, Jacklynn F
Finneran, John J
Monahan, Amanda M
et al.

Publication Date

2019-06-01

DOI

10.1213/ane.0000000000003693

Peer reviewed

Continuous Popliteal-Sciatic Blocks for Postoperative Analgesia: Traditional Proximal Catheter Insertion Superficial to the Paraneural Sheath Versus a New Distal Insertion Site Deep to the Paraneural Sheath

Jacklynn F. Sztain, MD,* John J. Finneran IV, MD,*† Amanda M. Monahan, MD,‡
Bahareh Khatibi, MD,* Patrick L. Nguyen, MD,* Sarah J. Madison, MD,§
Richard H. Bellars, MD,* Rodney A. Gabriel, MD, MAS (Clinical Research),*†
Sonya S. Ahmed, MD,|| Alexandra K. Schwartz, MD,|| William T. Kent, MD,||
Michael C. Donohue, PhD,¶ Jennifer A. Padwal, BS,# and
Brian M. Ilfeld, MD, MS (Clinical Investigation)*†

We tested the hypothesis that during a continuous popliteal-sciatic nerve block, postoperative analgesia is improved with the catheter insertion point “deep” to the paraneural sheath immediately distal to the bifurcation between the tibial and common peroneal branches, compared with the traditional approach “superficial” to the paraneural sheath proximal to the bifurcation. The needle tip location was determined to be accurately located with a fluid bolus visualized with ultrasound; however, catheters were subsequently inserted without a similar fluid injection and visualization protocol (visualized air injection was permitted and usually implemented, but not required per protocol). The average pain (0–10 scale) the morning after surgery for subjects with a catheter inserted at the proximal subparaneural location ($n = 31$) was a median (interquartile) of 1.5 (0.0–3.5) vs 1.5 (0.0–4.0) for subjects with a catheter inserted at the distal supraparaneural location ($n = 32$; $P = .927$). Secondary outcomes were similarly negative. (Anesth Analg XXX;XXX:00–00)

A fascial layer—the “paraneurium”—envelopes the sciatic nerve from its origin until just distal to its bifurcation.¹ Two previously published investigations

From the *Department of Anesthesiology, University of California, San Diego, California; †OUTCOMES RESEARCH Consortium, Cleveland, Ohio; ‡Department of Anesthesiology, University of Pittsburgh, Pittsburgh, Pennsylvania; §Department of Anesthesiology, Stanford University, Stanford, California; ||Department of Orthopedics, University of California, San Diego, California; ¶Department of Neurology, University of Southern California, Los Angeles, California; and #School of Medicine, University of California, San Diego, San Diego, California.

Accepted for publication July 2, 2018.

Funding: This work was supported by the Department of Anesthesiology, University California San Diego (San Diego, CA).

The authors declare no conflicts of interest.

Institutional review board: University of California, San Diego (UCSD) Human Research Protections Program at 9500 Gilman Dr, Mail Code 0052, La Jolla, CA 92093–0052; (858) 657–5100. E-mail: tnelson@ucsd.edu.

This report describes human research. This study was conducted with written informed consent from the study subjects. This report describes a prospective randomized clinical trial. The authors state that the report includes every item in the Consolidated Standards of Reporting Trials (CONSORT) checklist for a prospective randomized clinical trial.

The study was registered before patient enrollment.

This was not an observational clinical study.

Registry URL: [clinicaltrials.gov NCT02523235](https://clinicaltrials.gov/NCT02523235).

Plain Language Summary: We found no evidence that during a “continuous” popliteal nerve block, postoperative analgesia is improved with the perineural catheter tip deep to the paraneural sheath immediately distal to the sciatic bifurcation, compared with a traditional approach with the catheter tip superficial to the paraneural sheath proximal to the bifurcation.

The contents of this article are solely the responsibility of the authors and do not necessarily represent the official views of the funding entity.

Reprints will not be available from the authors.

Address correspondence to Brian M. Ilfeld, MD, MS (Clinical Investigation), Department of Anesthesiology, University California, San Diego, 200 W Arbor Dr, MC 8770, San Diego, CA, 92103. Address e-mail to bilfeld@ucsd.edu.

Copyright © 2018 International Anesthesia Research Society
DOI: 10.1213/ANE.00000000000003693

demonstrated that for “single-injection” blocks, depositing local anesthetic deep to the paraneurium immediately distal to the bifurcation results in a higher success rate and decreased time to onset compared with separate injections superficial to the paraneurium around both the common peroneal and tibial branches.^{2,3} In contrast, 3 investigations found the opposite when similar dual injections of the 2 branches were compared with a single injection superficial to the paraneurium proximal to the bifurcation.^{4–6}

One possible explanation for the differing results is that local anesthetic injected superficial to the paraneurium has to pass through both the paraneurium and epineurium to reach the nerve fibers.⁷ In contrast, local anesthetic injected deep to the paraneurium must diffuse across only the epineurium, and at an equivalent volume, the paraneural sheath will essentially retain the local anesthetic close to the nerve in this relatively small subparaneural space, resulting in a spread over a longer length of nerve.¹ Unfortunately, findings from studies involving single-injection nerve blocks have not always been replicated when investigated in relation to “continuous” peripheral nerve blocks.⁸

We, therefore, conducted this randomized trial to test the hypothesis that during a continuous popliteal-sciatic nerve block, postoperative analgesia is improved with the perineural catheter inserted at a point “deep” to the paraneural sheath just distal to the sciatic nerve bifurcation compared to the decades-old traditional technique in which the catheter tip is inserted at a point “superficial” to this sheath 6–7 cm proximal to the bifurcation.

METHODS

This study adhered to Good Clinical Practice guidelines and was approved by the University of California Institutional

Review Board (#151094; San Diego, CA). All subjects provided written informed consent. The trial was prospectively registered at clinicaltrials.gov (NCT02523235; B.M.I.; August 14, 2015).

Inclusion criteria were as follows: adults (>18 years of age) undergoing foot/ankle surgery with a popliteal-sciatic perineural infusion for postoperative analgesia. Exclusion criteria were as follows: operative extremity neuropathy, chronic opioid use (daily use >4 previous weeks of >20 mg oxycodone equivalent), body mass index >40 kg/m², lidocaine/ropivacaine allergy, renal insufficiency, inability to communicate with investigators, pregnancy, and incarceration.

Subjects were positioned prone. Using a 13- to 6-MHz, 38-mm linear array ultrasound transducer (M-Turbo; SonoSite, Bothell, WA) in the short-axis view, the 2 possible catheter insertion locations were identified. The bifurcation was defined as the most proximal point at which the tibial and common peroneal nerves had separated. If both sites were determined to be acceptable for catheter insertion, then the subject was randomized using a computer-generated list (blocks of 8) in a 1:1 ratio using sealed, consecutively numbered envelopes: (1) proximal or (2) distal insertion.

After sterile preparation and draping, a 17-gauge Tuohy needle was inserted through a lidocaine skin wheal and advanced in-plane beneath the ultrasound transducer imaging the nerve (short-axis view).

Proximal

The needle intersected the sciatic nerve 6–7 cm proximal to the bifurcation and injection with normal saline (<10 mL) used to ensure spread superficial to the paraneurium (“supraparaneural” or “subepimyseal”) without spread deep to the paraneurium (“subparaneural” or “extraepimyseal”).

Distal

The needle tip was inserted into the hypochoic area immediately distal to the sciatic nerve bifurcation where the 2 branches of the sciatic nerve were “adjacent but distinct (ie, diverging)”⁹ deep to the paraneurium between the paraneurium and epineurium (the “subparaneural space/compartments”).⁷ As described previously,¹⁰ “An adequate position was defined as the presence of circular expansion of the paraneural sheath [using <10 mL normal saline]... During the injection process, the Tuohy needle was kept stationary and care was taken to ensure that neural swelling did not occur. The latter was defined as an increase in the cross-sectional surface of the nerve. If neural swelling was detected by US [ultrasound], the needle was carefully withdrawn before resuming the injection.”

Subsequent Injectate Via the Needle

If no postoperative neurological examination was anticipated, the injectate consisted of lidocaine 2% with epinephrine 5–10 µg/mL (40 mL). If a postoperative neurological examination in the recovery room was planned, then the injectate consisted of normal saline (40 mL) and the same local anesthetic/epinephrine mixture delivered via the

catheter after the examination. “Success” was defined as a decrease in cutaneous sensation to cold on the plantar aspect of the foot within 15 minutes.

A 19-gauge perineural catheter (FlexTip Plus; Teleflex Medical, Research Triangle Park, NC) was inserted 3–5 cm past the needle tip and the needle withdrawn. The time for catheter insertion was measured from the time the Tuohy needle first touched the subject until it was completely withdrawn without reinsertion. Treatment group assignment was masked to subjects but not investigators. We recorded whether a single-injection saphenous nerve block (ropivacaine 0.5% with epinephrine 5–10 µg/mL) was administered.

Surgical anesthesia consisted of either the preoperative peripheral nerve block(s) or a general anesthetic with inhaled volatile anesthetic in nitrous oxide and oxygen. Intravenous fentanyl and/or hydromorphone was administered intraoperatively as needed.

Within the recovery room, a ropivacaine 0.2% infusion was initiated via the perineural catheter (basal 6 mL/h, 4-mL bolus, 30-minute lockout) using an electronic infusion pump (ambIT PreSet; Summit Medical Products, Inc, Salt Lake City, UT). Unacceptable pain remaining 20 minutes after a patient-controlled bolus dose was treated with oral oxycodone (5–10 mg) and/or intravenous morphine (2–4 mg).

Outcome measures were collected by telephone at approximately noon the day after surgery. Subjects were contacted again 6–8 days after surgery (perceived sensory or motor abnormalities triggered repeat calls every 2 weeks until resolution).

Statistical Analysis

The prespecified analysis for the primary hypothesis was the Mann-Whitney *U* test. Secondary end points were also tested using the Mann-Whitney *U* test, with the exception of nominal variables, which were analyzed using the Pearson χ^2 test. The 2-sided significance level was set at 0.05. No covariate-adjusted analyses were prespecified. R version 3.4.2 (<https://www.r-project.org/>) was used for all analyses.

To calculate a sample size, we focused on our primary hypothesis that during a continuous popliteal-sciatic nerve block for foot/ankle surgery, postoperative analgesia would be improved with the perineural catheter tip deep to the paraneural sheath between the tibial and common peroneal branches just distal to the sciatic bifurcation, compared to superficial to the paraneurium 6–7 cm proximal to the bifurcation. The primary end point was the average pain as measured with the numeric rating scale in the 2 hours previous to the telephone call the day after surgery. The original power analysis was based on an approximation using the 2-sample *t* test. Using an expected numeric rating scale mean = 2.6 and standard deviation = 2.1 of average pain,¹¹ approximately 31 subjects in each treatment arm were required to detect a difference between treatment group means of 1.5 with a 2-sided α = .05 and power = 0.8 (ClinCalc.com, accessed June 28, 2015).

RESULTS

Sixty-four subjects were enrolled, randomized, and had a catheter inserted successfully per protocol (Table). One

Table. Subject Characteristics			
	Proximal (n = 31)	Distal (n = 32)	P Value ^a
Age (y)	42 (15)	41 (15)	...
Sex (female), n (%)	17 (52)	21 (64)	...
Height (cm)	170 (11)	166 (8)	...
Weight (kg)	79 (22)	75 (18)	...
Body mass index (kg/m ²)	27.3 (7.0)	27.2 (5.6)	...
Primary surgical procedure, ^b n (%)			...
Achilles tendon repair	3 (10)	2 (6)	
Ankle arthroplasty or ORIF	8 (26)	11 (34)	
Arthrodesis/fusion	2 (6)	2 (6)	
Hallux valgus repair	3 (10)	3 (9)	
Hammertoe correction	5 (16)	2 (6)	
Ligament or tendon repair	1 (3)	2 (6)	
Metatarsal ORIF	3 (10)	4 (13)	
Talus or calcaneus ORIF	6 (19)	6 (19)	
Time for catheter insertion (min)	4.5 (4.0–6.0)	4.8 (4.0–7.6)	.408
Lidocaine bolus postoperatively, n (%)	22 (71)	21 (66)	.649
Saphenous nerve blocked, n (%)	3 (10)	9 (28)	.062
Surgical start to stop (min)	112 (61–130)	125 (82–158)	.087
Degree of foot numbness (0–10 scale)	7.0 (4.0–8.5)	7.0 (5.0–9.2)	.413
Fluid leakage at catheter site, n (%)	3 (10)	4 (12)	.722
Catheter inadvertently dislodged, n (%)	4 (13)	4 (12)	.962
Opioid consumption (morphine equivalents)			
Intraoperative (mg)	2.5 (1.1–3.3)	2.5 (1.9–3.8)	.381
After recovery room until POD 1 call (mg)	0.3 (0.0–1.0)	0.0 (0.0–0.8)	.919

Values are reported as number (%) of subjects with Pearson χ^2 tests or median (interquartile range) with Mann-Whitney *U* tests.

Abbreviations: ORIF, open reduction, internal fixation; POD, postoperative day.

^aStatistical test performed only on postintervention variables.

^bPercentages do not add to 100% due to a rounding error.

subject randomized to the distal location was found to have reduced sensation to light touch in both the tibial and common peroneal cutaneous nerve distributions on examination within the recovery room, did not have local anesthetic introduced into her catheter, and withdrew from the investigation (resolved within 12 days). No statistically significant differences between the treatment groups were detected for any end point (Table and Figure). One subject randomized to the distal location had a perineural catheter inserted preoperatively using normal saline without incident. A week after surgery, the subject reported mild “numbness” in the fourth and fifth toes extending to the ball of the foot within the setting of edema that resolved within 7 days.

DISCUSSION

This randomized, subject-masked, controlled, parallel-arm clinical trial found no evidence that for continuous popliteal-sciatic nerve blocks, a catheter inserted at a point deep to the paraneurium immediately distal to the sciatic bifurcation between the tibial and common peroneal branches provides any clinically relevant or statistically significant benefits compared with a traditional catheter insertion point superficial to the paraneurium 6–7 cm proximal to the bifurcation. This finding is in contrast with single-injection popliteal-sciatic nerve blocks, for which benefits have been demonstrated to local anesthetic injection deep to the paraneurium just distal to the bifurcation relative to other supra-paraneural locations.^{2,3}

Our study design deserves comment as there are 2 independent variables that must be differentiated: location relative to the bifurcation (proximal versus distal) and depth relative to the paraneurium (superficial versus deep). This

is common in regional anesthetic investigations, such as comparing epidurals to spinals: the injection location/plane is varied (epidural versus intrathecal), as well as the local anesthetic delivery device (catheter versus needle) and volume/dose of anesthetic (relatively high versus low). A single independent variable is preferable because it makes interpretation of the resulting data far easier. However, as with the epidural versus spinal example, multiple independent variables are sometimes necessary and do not invalidate the results (consider studies comparing general to regional anesthetics). However, there should be good reasons to introduce >1 intervention variable, which we will explain regarding our chosen protocol.

In the decades before the widespread use of ultrasound within regional anesthesia, inserting a perineural sciatic catheter within the popliteal fossa was traditionally done almost exclusively proximal to the bifurcation.¹² Subsequently, ultrasound guidance allowed for precise administration relative to the bifurcation, and evidence mounted that benefits are afforded with local anesthetic administration distal versus proximal to the bifurcation for single-injection popliteal blocks.^{4–6} Previously, we attempted to duplicate these findings for continuous popliteal blocks but discovered the opposite relationship for perineural infusion: postoperative analgesia was superior when the catheter was inserted proximal compared with at the sciatic bifurcation,¹¹ suggesting that no change from the traditional approach was indicated. However, all of these studies were designed before widespread knowledge within the regional anesthesia community of the importance of the paraneural sheath,^{7,13} and the great majority of local anesthetic administration for the initial investigations was most likely superficial to the paraneurium for all treatments.

Postoperative Pain

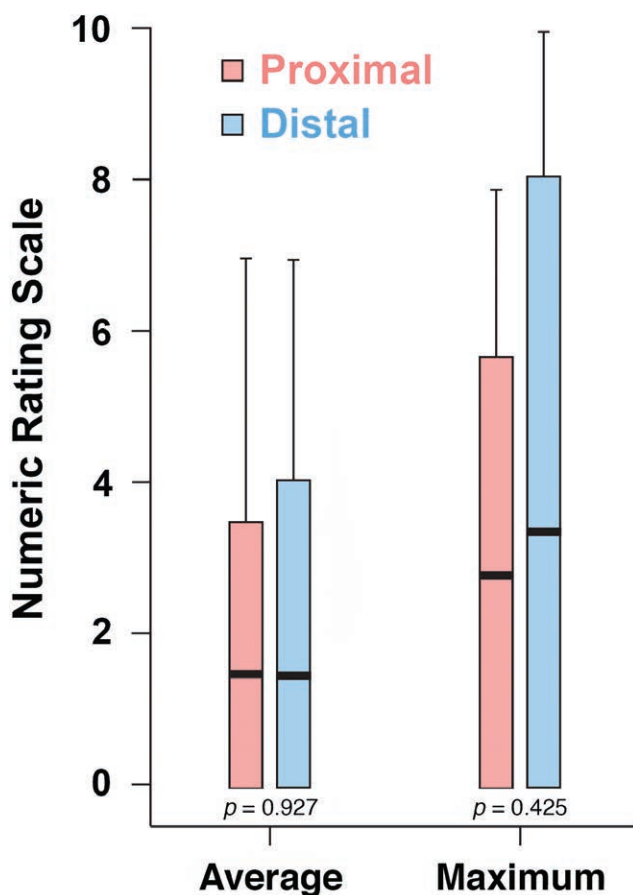


Figure. Perineural catheter location effects on postoperative pain after painful foot and ankle surgery with a ropivacaine 0.2% perineural infusion with either a distal insertion site deep to the paraneural sheath just distal to the sciatic nerve bifurcation or a more proximal insertion site superficial to this sheath 6–7 cm proximal to the bifurcation. Pain severity indicated using a numeric rating scale of 0–10, with 0 equal to no pain and 10 being the worst imaginable pain. Data include the median and maximum pain reported in the 2 h before a data-collection telephone call at noon the day after surgery (“postoperative day 1”). Data are expressed as median (horizontal bars) with 25th–75th (box) and 10th–90th (whiskers). No comparison reached statistical significance ($P > .05$).

Further evidence was published that for single-injection popliteal blocks, benefits are afforded with local anesthetic administration deep to the paraneurium immediately distal to the sciatic bifurcation.^{2,3} We wanted to determine if the same was true for perineural infusion, and therefore we chose to compare the traditional above-the-bifurcation technique with the relatively “new” approach deep to the paraneurium immediately distal to the bifurcation because this would answer an important clinical question of whether a change from the conventional practice was indicated. We concluded that a study design comparing superficial versus deep administration relative to the paraneurium—both at the bifurcation—would not be particularly fruitful given that if the superficial administration was found superior, it still would not be preferable to the traditional proximal technique because that was already determined previously.¹¹ If

the deep administration was found superior, then we would still have to do the present study to determine if practitioners should switch from the conventional proximal superficial to the relatively new distal and deep technique.

Removing the depth relative to the paraneurium as a variable would have been an attractive choice because it would have left only insertion site relative to the bifurcation as the independent variable (ie, both treatment groups receiving catheter deep to the paraneurium, with 1 proximal and the other distal to the bifurcation). However, even though it is possible to place a perineural catheter between the paraneurium and epineurium,¹⁰ without further documentation of safety, we felt the risk-benefit ratio to be unacceptably high due to possible needle-induced nerve injury.¹⁴ Karmakar et al¹³ have described the perineural compartment superficial to the paraneurium as “a well-defined intermuscular space surrounding the sciatic nerve. It is filled with fat and blood vessels, and clearly delineated” with various imaging techniques, including ultrasound.

“In contrast, the subparaneural compartment [deep to the paraneurium] is a potential space with a thin layer of fat separating the paraneural sheath from the epineurium of the nerve...”¹³ Placing a needle deep to the paraneurium is possible immediately distal to the bifurcation because the needle can be directed between the tibial and common perineural branches, theoretically avoiding contact with the epineurium of either. However, proximal to the bifurcation, a needle passed through the paraneurium contacts the epineurium almost immediately. Although questioned by some,^{15,16} intraneural injection remains—at the very least—controversial due to concern of an increased risk of nerve injury.^{14,17–19} It remains unknown whether the single case within our study of an adverse neurological outcome detected within the recovery room was related to the preoperative catheter insertion or an intraoperative factor, but it is noteworthy that the subject had been randomized to the distal insertion deep to the paraneurium.

Several limitations of our study deserve comment. First, the needle tip location was determined to be accurately located with a fluid bolus visualized with ultrasound; however, catheters were subsequently inserted without a similar fluid injection and visualization protocol (visualized air injection was permitted and usually implemented but not required per protocol). Although the subjects of this investigation were masked to treatment group assignment, investigators were aware of the randomization results. In addition, the results apply only to the specific local anesthetic type, concentration, bolus volume, and basal rate of the present study. Furthermore, we evaluated subjects’ analgesia only through noon the day after surgery. Although both treatment groups received identical portable electronic infusion pumps and programmable settings (basal rate, bolus dose, and lockout period), the actual number of doses self-administered by each subject is unavailable. Finally, because we included a diverse group of surgeries that may have different pain outcomes and both groups experienced only mild pain, it may have made finding a difference between treatments difficult.

What we can discern with the present study design is that there is no evidence that benefits are afforded by switching

from a traditional catheter insertion above the bifurcation and superficial to the paraneurium to a relatively new method of insertion distal to the bifurcation and deep to the paraneurium, at least with the present study protocol. ■■

DISCLOSURES

Name: Jacklynn F. Sztain, MD.

Contribution: This author helped conduct the study and write the manuscript.

Name: John J. Finneran IV, MD.

Contribution: This author helped conduct the study and write the manuscript.

Name: Amanda M. Monahan, MD.

Contribution: This author helped conduct the study and write the manuscript.

Name: Bahareh Khatibi, MD.

Contribution: This author helped conduct the study and write the manuscript.

Name: Patrick L. Nguyen, MD.

Contribution: This author helped develop the protocol, conduct the study, and write the manuscript.

Name: Sarah J. Madison, MD.

Contribution: This author helped conduct the study and write the manuscript.

Name: Richard H. Bellars, MD.

Contribution: This author helped develop the protocol, conduct the study, and write the manuscript.

Name: Rodney A. Gabriel, MD, MAS (Clinical Research).

Contribution: This author helped conduct the study, provide the data analysis, and write the manuscript.

Name: Sonya S. Ahmed, MD.

Contribution: This author helped develop the protocol, conduct the study, and write the manuscript.

Name: Alexandra K. Schwartz, MD.

Contribution: This author helped develop the protocol, conduct the study, and write the manuscript.

Name: William T. Kent, MD.

Contribution: This author helped conduct the study and write the manuscript.

Name: Michael C. Donohue, PhD.

Contribution: This author helped provide the data analysis and write the manuscript.

Name: Jennifer A. Padwal, BS.

Contribution: This author helped write the manuscript.

Name: Brian M. Ilfeld, MD, MS (Clinical Investigation).

Contribution: This author designed and implemented the original study, has seen the original study data, reviewed the analysis of the data, approved the final manuscript, and is the author responsible for archiving the study files.

This manuscript was handled by: Richard Brull, MD, FRCPC.

REFERENCES

- Andersen HL, Andersen SL, Trandum-Jensen J. Injection inside the paraneural sheath of the sciatic nerve: direct comparison among ultrasound imaging, macroscopic anatomy, and histologic analysis. *Reg Anesth Pain Med.* 2012;37:410–414.
- Tran DQ, Dugani S, Pham K, Al-Shaafi A, Finlayson RJ. A randomized comparison between subepineural and conventional ultrasound-guided popliteal sciatic nerve block. *Reg Anesth Pain Med.* 2011;36:548–552.
- Perlas A, Wong P, Abdallah F, Hazrati LN, Tse C, Chan V. Ultrasound-guided popliteal block through a common paraneural sheath versus conventional injection: a prospective, randomized, double-blind study. *Reg Anesth Pain Med.* 2013;38:218–225.
- Prasad A, Perlas A, Ramlogan R, Brull R, Chan V. Ultrasound-guided popliteal block distal to sciatic nerve bifurcation shortens onset time: a prospective randomized double-blind study. *Reg Anesth Pain Med.* 2010;35:267–271.
- Buys MJ, Arndt CD, Vagh F, Hoard A, Gerstein N. Ultrasound-guided sciatic nerve block in the popliteal fossa using a lateral approach: onset time comparing separate tibial and common peroneal nerve injections versus injecting proximal to the bifurcation. *Anesth Analg.* 2010;110:635–637.
- Germain G, Lévesque S, Dion N, et al. Brief reports: a comparison of an injection cephalad or caudad to the division of the sciatic nerve for ultrasound-guided popliteal block: a prospective randomized study. *Anesth Analg.* 2012;114:233–235.
- Abdallah FW, Chan VW. The paraneural compartment: a new destination? *Reg Anesth Pain Med.* 2013;38:375–377.
- Ilfeld BM. Continuous peripheral nerve blocks: an update of the published evidence and comparison with novel, alternative analgesic modalities. *Anesth Analg.* 2017;124:308–335.
- Missair A, Weisman RS, Suarez MR, Yang R, Gebhard RE. A 3-dimensional ultrasound study of local anesthetic spread during lateral popliteal nerve block: what is the ideal end point for needle tip position? *Reg Anesth Pain Med.* 2012;37:627–632.
- Tran DQ, González AP, Bernucci F, Pham K, Finlayson RJ. A randomized comparison between bifurcation and prebifurcation subparaneural popliteal sciatic nerve blocks. *Anesth Analg.* 2013;116:1170–1175.
- Monahan AM, Madison SJ, Loland VJ, et al. Continuous popliteal sciatic blocks: does varying perineural catheter location relative to the sciatic bifurcation influence block effects? A dual-center, randomized, subject-masked, controlled clinical trial. *Anesth Analg.* 2016;122:1689–1695.
- Ilfeld BM, Morey TE, Wang RD, Enneking FK. Continuous popliteal sciatic nerve block for postoperative pain control at home: a randomized, double-blinded, placebo-controlled study. *Anesthesiology.* 2002;97:959–965.
- Karmakar MK, Shariat AN, Pangthipampai P, Chen J. High-definition ultrasound imaging defines the paraneural sheath and the fascial compartments surrounding the sciatic nerve at the popliteal fossa. *Reg Anesth Pain Med.* 2013;38:447–451.
- Short A, Chan VW, Perlas A. Is deliberate intraneural injection a case of “false economy”? *Reg Anesth Pain Med.* 2016;41:421–423.
- Bigeleisen PE, Chelly J. An unsubstantiated condemnation of intraneural injection. *Reg Anesth Pain Med.* 2011;36:95.
- Cappelleri G, Cedrati VL, Fedele LL, et al. Effects of the intraneural and subparaneural ultrasound-guided popliteal sciatic nerve block: a prospective, randomized, double-blind clinical and electrophysiological comparison. *Reg Anesth Pain Med.* 2016;41:430–437.
- Neal JM, Barrington MJ, Brull R, et al. The second ASRA practice advisory on neurologic complications associated with regional anesthesia and pain medicine: executive summary 2015. *Reg Anesth Pain Med.* 2015;40:401–430.
- Brull R, Hadzic A, Reina MA, Barrington MJ. Pathophysiology and etiology of nerve injury following peripheral nerve blockade. *Reg Anesth Pain Med.* 2015;40:479–490.
- Wolf FA, Gray AT. Sonography of the paraneural sheath of the sciatic nerve in the popliteal fossa: more than a bifurcation. *Reg Anesth Pain Med.* 2014;39:260–261.