

# UCLA

## UCLA Previously Published Works

### Title

Improved efficacy of pembrolizumab combined with soluble EphB4-albumin in HPV-negative EphrinB2 positive head neck squamous cell carcinoma

### Permalink

<https://escholarship.org/uc/item/35615743>

### Journal

Oncotarget, 15(1)

### ISSN

1949-2553

### Authors

Jackovich, Alexandra

Gitlitz, Barbara J

Tiu-lim, Justin Wayne Wong

et al.

### Publication Date

2024-07-10

### DOI

10.18632/oncotarget.28605

### Copyright Information

This work is made available under the terms of a Creative Commons Attribution License, available at <https://creativecommons.org/licenses/by/4.0/>

Peer reviewed

# Improved efficacy of pembrolizumab combined with soluble EphB4-albumin in HPV-negative EphrinB2 positive head neck squamous cell carcinoma

Alexandra Jackovich<sup>1,2</sup>, Barbara J. Gitlitz<sup>1,2</sup>, Justin Wayne Wong Tiu-lim<sup>1,2</sup>, Vinay Duddalwar<sup>1,2</sup>, Kevin George King<sup>1,2</sup>, Anthony B. El-Khoueiry<sup>1,2</sup>, Jacob Stephen Thomas<sup>1,2</sup>, Denice Tsao-Wei<sup>1,2</sup>, David I. Quinn<sup>1,2</sup>, Parkash S. Gill<sup>1</sup> and Jorge J. Nieva<sup>1,2</sup>

<sup>1</sup>Rutgers New Jersey Medical School, Newark, NJ 07103, USA

<sup>2</sup>Division of Medical Oncology, University of Southern California, Los Angeles, CA 90007, USA

**Correspondence to:** Alexandra Jackovich, **email:** atj41@njms.rutgers.edu  
Jorge J. Nieva, **email:** jorge.nieva@med.usc.edu

**Keywords:** EphrinB2; EphB4; HNSCC; pembrolizumab; HPV-negative

**Received:** June 06, 2024

**Accepted:** June 27, 2024

**Published:** July 10, 2024

**Copyright:** © 2024 Jackovich et al. This is an open access article distributed under the terms of the [Creative Commons Attribution License](#) (CC BY 4.0), which permits unrestricted use, distribution, and reproduction in any medium, provided the original author and source are credited.

## ABSTRACT

**Objective:** Patients with relapsed or metastatic head and neck squamous cell carcinoma (HNSCC) after primary local therapy have low response rates with cetuximab, systemic chemotherapy or check point inhibitor therapy. Novel combination therapies with the potential to improve outcomes for patients with HNSCC is an area of high unmet need.

**Methods:** This is a phase II single-arm clinical trial of locally advanced or metastatic HNSCC patients treated with a combination of soluble EphB4-human serum albumin (sEphB4-HSA) fusion protein and pembrolizumab after platinum-based chemotherapy with up to 2 prior lines of treatment. The primary endpoints were safety and tolerability and the primary efficacy endpoint was overall response rate (ORR). Secondary endpoints included progression free survival (PFS) and overall survival (OS). HPV status and EphrinB2 expression were evaluated for outcome.

**Results:** Twenty-five patients were enrolled. Median follow up was 40.4 months (range 9.8 – 40.4). There were 6 responders (ORR 24%). There were 5 responders in the 11 HPV-negative and EphrinB2 positive patients, (ORR 45%) with 2 of these patients achieving a complete response (CR). The median PFS in HPV-negative/EphrinB2 positive patients was 3.2 months (95% CI 1.1, 7.3). Median OS in HPV-negative/EphrinB2 positive patients was 10.9 months (95% CI 2.0, 13.7). Hypertension, transaminitis and fatigue were the most common toxicities.

**Discussion:** The combination of sEphB4-HSA and pembrolizumab has a favorable toxicity profile and favorable activity particularly among HPV-negative EphrinB2 positive patients with HNSCC.

## INTRODUCTION

Head and neck squamous cell carcinoma (HNSCC) is the seventh most common cancer worldwide, with approximately 930,000 new cases and 470,000 deaths occurring globally in 2020 [1]. In the United States, an estimated 66,000 new cases and 15,000 deaths

are attributable to HNSCC [2]. Major risk factors for HNSCC include tobacco smoking, alcohol consumption, and human papillomavirus (HPV) infection [3, 4]. Despite the decline in prevalence of tobacco use, it remains a primary contributing factor to development of non-HPV-related HNSCC in the United States. In recent years, this subset of patients continues to see worse

outcomes than HPV-associated HNSCC patients with 2-year overall survival of 62% as compared with 95% for non-HPV-associated disease [5, 6].

For advanced and recurrent or refractory HNSCC, common treatment regimens after progression from 1st or 2nd line chemotherapy include targeted therapy or immunotherapy with a PD-1 or PD-L1 inhibitor, regardless of HPV status. Pembrolizumab is approved by the US Food and Drug Administration as 1st and 2nd line monotherapy and in combination with chemotherapy for relapsed and metastatic HNSCC and as monotherapy in the 2nd line. PD-1/PD-L1 inhibitors provide superior outcomes including tumor response in advanced or recurrent HNSCC when compared to traditional chemotherapy [7, 8]. In the KEYNOTE-055 trial of pembrolizumab for platinum and cetuximab refractory HNSCC, overall response rate was 16%, similar to HPV negative population (ORR 15%, 95% CI 10-23%), with progression free survival of 2.1 months and overall survival of 8 months. In KEYNOTE-012, without mandate for prior therapy, ORR was 18% for all patients, while in the KEYNOTE-048 trial as first-line therapy the overall response rate was 20% but with a lower response rate of 14% in HPV negative HNSCC [9, 10]. Patients with HNSCC who progressed during or after platinum-containing treatment, overall survival with pembrolizumab compared with docetaxel, methotrexate or cetuximab was 8.4 months vs. 6.9 months, respectively [7, 9, 10–12]. This observation was confirmed in a pooled analysis of checkpoint inhibitor trials with response rates for HPV-positive and HPV negative patients being 21.9% vs. 14.1%, respectively [13–16].

sEphB4-HSA is a human fusion protein consisting of EphB4 extracellular domain (sEphB4) and full length human serum albumin (HSA). sEphB4-HSA binds exclusively to EphrinB2, therefore blocking binding of endogenous EphB4-receptor and blocks bidirectional signaling [17, 18]. Type one receptor tyrosine kinase EphB4 and its trans-membrane ligand EphrinB2, normally expressed on venous and arterial endothelial cells, respectively, induce bidirectional signaling; forward-signaling in EphB4-receptor expressing cells, and reverse-signaling in EphrinB2-ligand expressing cells. This interaction is critically required for maturation of the developing vascular system in the embryo [19]. The EphB4-EphrinB2 interaction between tumor cell-tumor vessel also promotes tumor growth and enhances tumor angiogenesis, and prohibits immune cell trafficking into the tumor [20–22]. Forward signaling activates Ras-MAPK and PI3K pathway and reverse signaling activates Src mediated events [23]. EphB4 has autonomous function in the tumor cell to promote tumor cell proliferation and survival. Notably, EphB4 and EphrinB2 are highly expressed in head and neck cancers [24–27] and predict poor survival [17, 21, 28].

## RESULTS

### Patients

Between June 21st, 2017, and February 22nd, 2021, 25 patients were enrolled. All patients received at least 1 dose of sEphB4-HSA and pembrolizumab. Therefore 25 patients were included in the analysis of safety. Median duration of follow up was 40.4 months (range 9.8–40.4). Three patients were not evaluable by radiographic response due to early discontinuation and no imaging study on therapy but were included in the intent-to-treat analysis (Figure 1). Fifteen (60%) patients were HPV-negative, 11 of whom were EphrinB2 positive. Patient demographics are shown in Table 1. The median age was 61 (range 31–79) years. Twenty (80%) patients were male (Table 1).

### Safety

The median number of 3-week cycles given was 6 (range 1–30) (Table 1). Sixteen (64%) of 25 patients experienced hypertension, which was the most frequently treatment-related adverse event (AE). Other commonly experienced AEs included fatigue ( $n = 4$ , 16%) and elevated ALT/AST ( $n = 3$ , 12%). Grade 3 toxicities were experienced by 12 patients. The most common grade 3 AEs observed were hypertension ( $n = 9$ , 36%), elevated ALT/AST, hyponatremia, and dysphagia ( $n = 2$  in each, or 8% each). There were no grade 4 treatment-related AEs observed and no treatment-related deaths (Table 2). Two (8%) patients had dose modifications while on therapy and 8 (32%) patients had one or more dose interruptions due to toxicity. Grade 3 toxicities included dysphagia, anorexia, and hypoalbuminemia and were each reported in two (8%) patients; one patient had grade 3 anemia (4%). Dyspnea, generalized muscle weakness, hyperbilirubinemia, and elevated alkaline phosphatase were each reported in one (4%) patient (Table 2).

### Efficacy

Overall response rate (ORR) in the intent-to-treat population of 25 patients was 24% (Table 3). Two (8%) of 25 patients had complete response (CR), 4 (16%) had partial response (PR), and 9 (36%) had stable disease (SD). (Table 3). The total disease control rate, which includes patients who experienced CR, PR, and SD for at least 6 months, was 7 (28%) out of 25 patients. There was one case of pseudo-progression, where subsequent imaging assessments on treatment demonstrated decrease in non-target lesions, while a target lesion in bone ultimately became sclerotic; this patient was not included in the ORR. Three (12%) of 25 patients with stable disease had no viable tumor on pathologic analysis on the week-8 repeat biopsy on therapy but were not included

among responders. One of these patients with pathologic complete response (pCR) continued on treatment with durable disease control for 21 months. A waterfall plot shows the greatest percent tumor decreases for individual evaluable patients, defined as those with at least 1 imaging assessment on study (Figure 2).

In the HPV-negative group, radiographic response occurred in 5 of 15 (33%) patients, and all responders were EphrinB2 positive. There were 11 EphrinB2 positive/HPV-negative patients, who had an overall response rate of 45% (5 of 11). Two of these patients had complete remission. (Table 3). Rapid radiographic response was observed in 3

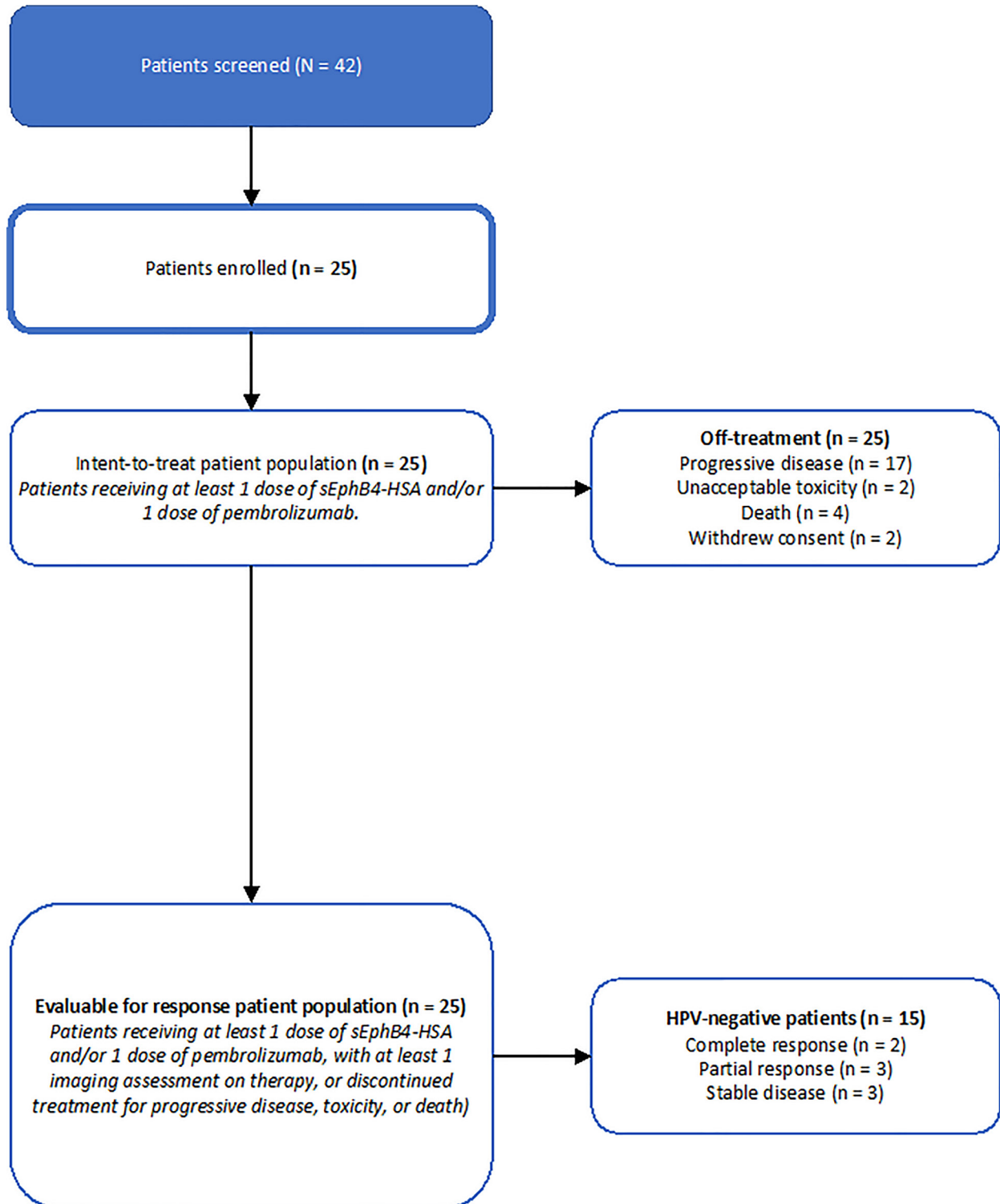


Figure 1: Consort diagram, clinical trial of sEphB4-HSA plus pembrolizumab.

**Table 1: Demographics of all patients and HPV negative, EphrinB2 positive patients**

| Characteristic   | All accrued patients<br>(N = 25) | HPV-Negative/EphrinB2-<br>Positive patients (n = 11) |
|--|----------------------------------|--|
| Age  |                                  |  |
| Median (range) — yr.   | 61 (31 — 79)                     | 61 (38–78)   |
| ≥75 yr. — no. (%)  | 3 (12)                           | 2 (18)   |
| Male sex — no. (%)   | 20 (80)                          | 8 (73)   |
| Race/Ethnicity — no. (%)   |                                  |  |
| White  | 12 (48)                          | 5 (45)   |
| Hispanic*  | 6 (24)                           | 3 (27)   |
| Asian  | 5 (20)                           | 3 (27)   |
| Black  | 2 (8)                            | 0  |
| Smoking or tobacco use — no. (%)                                     |                                  |  |
| Current or former  | 13 (52)                          | 8 (73)   |
| Never  | 12 (48)                          | 3 (27)   |
| ECOG performance-status score — no. (%)                              |                                  |  |
| 0  | 12 (48)                          | 5 (45)   |
| 1  | 13 (52)                          | 6 (50)   |
| Site of primary tumor — no. (%)                                      |                                  |  |
| Larynx   | 2 (8)                            | 2 (18)   |
| Oral cavity  | 10 (40)                          | 4 (36)   |
| Pharynx  |                                  |  |
| Nasopharynx  | 3 (12)                           | 2 (18)   |
| Oropharynx   | 6 (24)                           | 0  |
| Hypopharynx  | 1 (4)                            | 1 (9)  |
| Paranasal sinuses and nasal cavity                                   | 3 (12)                           | 2 (18)   |
| Sites of metastatic disease — no. (%)                                |                                  |  |
| Lung   | 15 (60)                          | 5 (45)   |
| Liver  | 5 (20)                           | 2 (18)   |
| Bone   | 5 (20)                           | 2 (18)   |
| Adrenal Gland  | 2 (8)                            | 0  |
| Node Only  | 7 (28)                           | 5 (45)   |
| No. of prior regimens received for systemic cancer therapy — no. (%) |                                  |  |
| 0  | 5 (20)                           | 1 (9)  |
| 1  | 18 (72)                          | 8 (73)   |
| 2  | 2 (8)                            | 2 (18)   |
| Context of previous systemic therapy regimen — no. (%)               |                                  |  |
| Adjuvant therapy   | 6 (24)                           | 3 (27)   |
| Neoadjuvant therapy  | 3 (12)                           | 1 (9)  |
| Primary disease  | 7 (28)                           | 3 (27)   |
| Disease recurrence   | 2 (8)                            | 0  |
| Metastatic disease   | 2 (8)                            | 3 (27)   |
| No previous systemic therapy   | 5 (20)                           | 1 (9)  |
| Previous receipt of cetuximab — no. (%)                              | 1 (4)                            | 1 (9)  |

\*Including all patients whose ethnicity is Hispanic.

**Table 2: Adverse events**

| Event                           | sEphB4-HSA + Pembrolizumab (N = 25) |                         |
|---------------------------------|-------------------------------------|-------------------------|
|                                 | Any grade<br>No. (%)                | Grade 3 or 4<br>No. (%) |
| Patients with ≥1 event          | 19 (76)                             | 12 (48)                 |
| Hypothyroidism                  | 1 (4)                               | 0                       |
| Immune thrombocytopenic purpura | 0                                   | 0                       |
| Abdominal pain                  | 0                                   | 0                       |
| Colitis                         | 0                                   | 0                       |
| Dysphagia                       | 2 (8)                               | 2 (8)                   |
| Nausea                          | 1 (4)                               | 0                       |
| Stomatitis                      | 0                                   | 0                       |
| Facial edema                    | 0                                   | 0                       |
| Fatigue                         | 4 (16)                              | 1 (4)                   |
| Hypertension                    | 16 (64)                             | 9 (36)                  |
| Dyspnea                         | 1 (4)                               | 1 (4)                   |
| Pneumonitis                     | 0                                   | 0                       |
| Hyperglycemia                   | 1 (4)                               | 0                       |
| Dehydration                     | 0                                   | 0                       |
| Decreased appetite              | 0                                   | 0                       |
| General muscle weakness         | 1 (4)                               | 1 (4)                   |
| Elevated ALT/AST                | 3 (12)                              | 2 (8)                   |
| Elevated ALP                    | 1 (4)                               | 1 (4)                   |
| Hyponatremia                    | 2 (8)                               | 2 (8)                   |
| Anemia                          | 1 (4)                               | 1 (4)                   |
| Hyperbilirubinemia              | 1 (4)                               | 1 (4)                   |

**Table 3: Efficacy of intent-to-treat population in all study patients and HPV-negative/EphrinB2 positive patients**

|   | All Patients<br>(N = 25) | HPV-Negative/EphrinB2-<br>Positive patients (n = 11) |
|---|--------------------------|--|
| Overall Response Rate – no. (%)             | 6 (24)                   | 5 (45)   |
| 95% CI                                      | (11%, 44%)               | (14%, 61%)   |
| CR  | 2 (8)                    | 2 (18)   |
| PR  | 4 (16)                   | 3 (27)   |
| SD  | 9 (36)                   | 3 (27)   |
| PD  | 10 (40)                  | 3 (27)   |
| Overall Survival (Months) (95% CI)          | 8.6 (3.2, 13.7)          | 10.9 (2.0, 13.7)                                     |
| Progression Free Survival (Months) (95% CI) | 2.6 (1.3, 4.1)           | 3.2 (1.1, 7.3)                                       |

(27%) of 11 EphrinB2 positive/HPV-negative subgroup. Specifically, on CT-imaging assessments in these 3 patients, the measurable disease at baseline demonstrated tumor cavitation and rapid regression at 1st and 2nd

CT-scan on therapy. A waterfall plot shows the greatest percent tumor decreases for individual evaluable HPV-negative patients, defined as those with at least 1 imaging assessment on study (Figure 3).

Median overall survival (OS) was 8.6 (95% CI: 3.2, 13.7) months in the total population of 25 patients. Median progression-free survival (PFS) was 2.6 (95% CI: 1.3, 4.1) months in the total population (Figure 4A). A swimmer plot shows individual patient overall survival and time of response among all patients in the intent-to-treat population ( $N = 25$ ) (Figure 5). In the HPV-negative/EphrinB2 positive group, median OS was 10.9 (95% CI: 2.0, 13.7) months and median PFS was 3.2 (95% CI: 1.1, 7.3) months (Table 3, Figure 4B). A swimmer plot shows individual patient overall survival and time of response in the intent-to treat HPV-negative population ( $n = 15$ ) (Figure 6).

### Biomarker analysis and immune cell infiltration analysis

EphrinB2 was expressed in 16 of 25 (64%) patients, which was more common in the HPV negative group Table 4. All 6 responding patients were among the EphrinB2 positive cases, 5 of whom were HPV negative

and EphrinB2 positive. PD-L1 was positive in twelve (48%) of 25 patients. Three of the responding patients had both PD-L1 and EphrinB2 expression (Table 5).

CD3 and CD8 T-cell tumor infiltration was measured on paired samples from baseline and on therapy around week 8 (after 2 cycles) in 13 (52%) of 25 patients. On therapy tissue was not evaluable in 4 cases. Data on the remaining 9 cases is shown (Table 6). Three (23%) of 13 patients had no malignancy in week 8 biopsy consistent with pathologic complete remission (pCR) (Table 6). Of the 6 patients with paired samples, 4 had RECIST-defined response, and all had significant immune cell infiltration (CD3 and CD8) into the tumor. They were all EphrinB2 positive. Among the three PD-L1 positive cases, two were also EphrinB2 positive, both had increase in T cell infiltration and both had response, while the single EphrinB2 negative/PD-L1 positive case did not show a significant intratumoral immune cell increase and was not a responder. Lastly, there was one case which was EphrinB2 negative and PD-L1 negative, who also did not show significant increase of intratumoral immune cells,

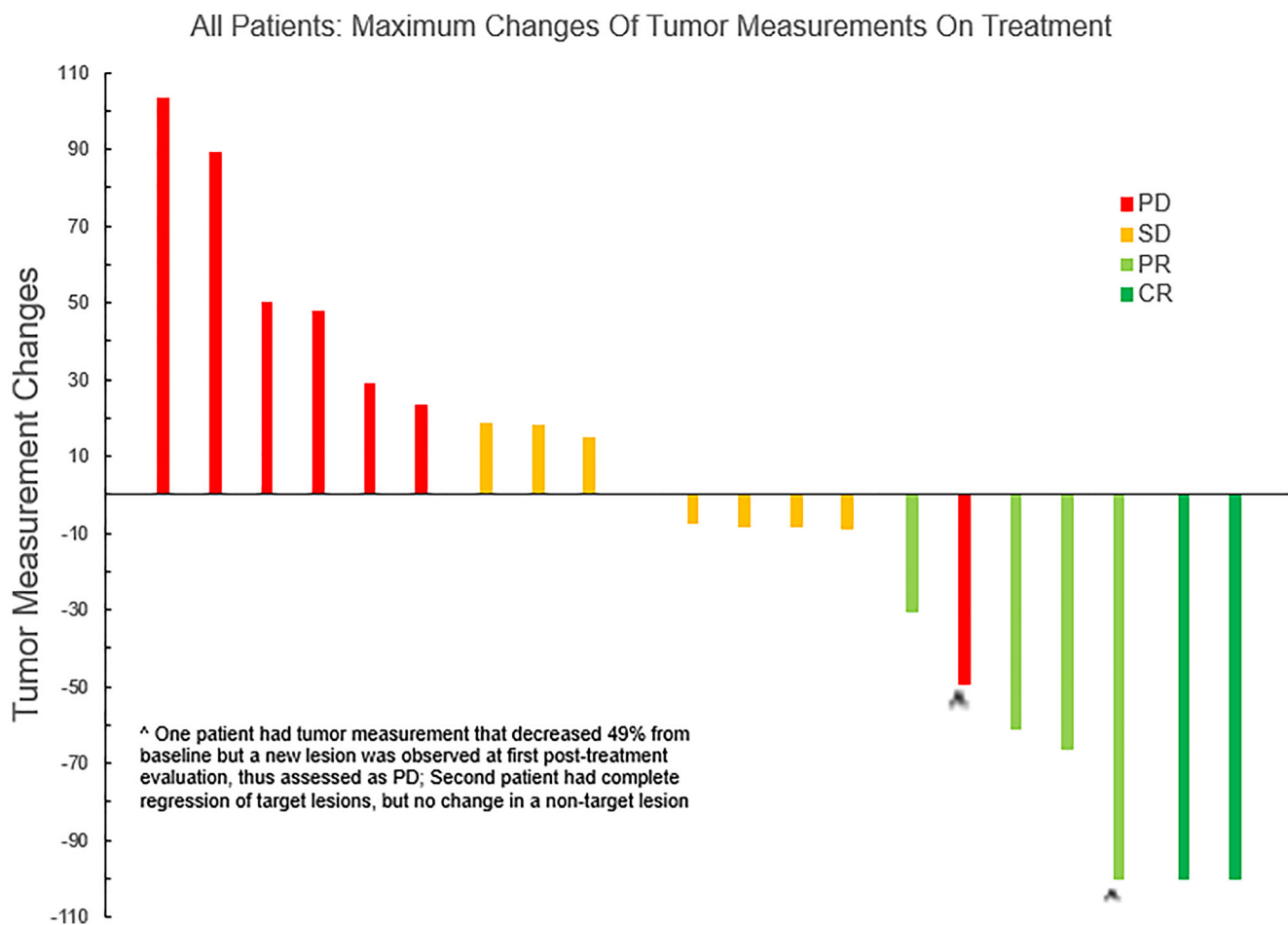
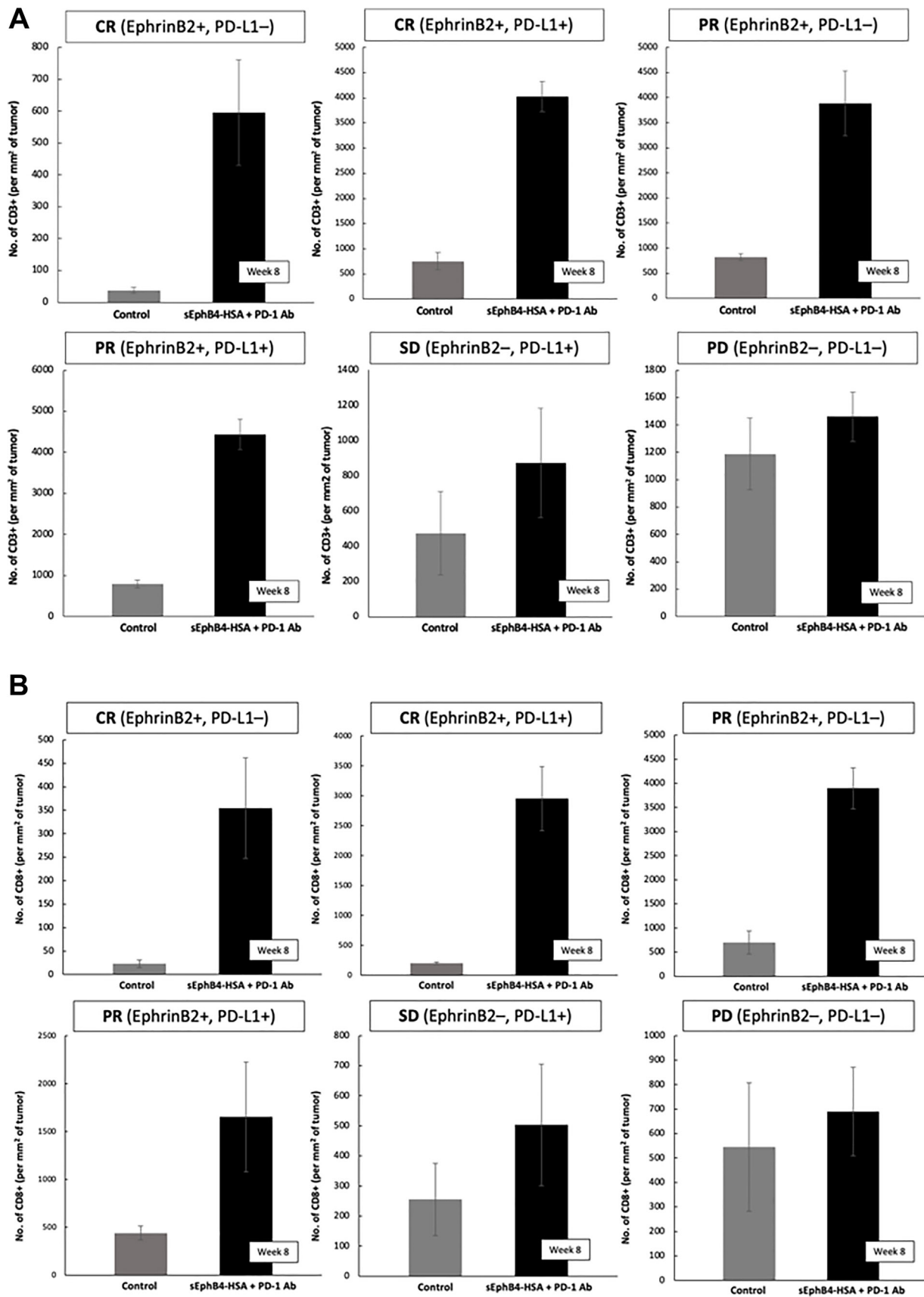


Figure 2: Waterfall plot, all patients with response assessed by imaging, clinical trial of sEphB4-HSA plus pembrolizumab ( $n = 21$ ). Four patients did not have tumor assessment due to early withdrawal.





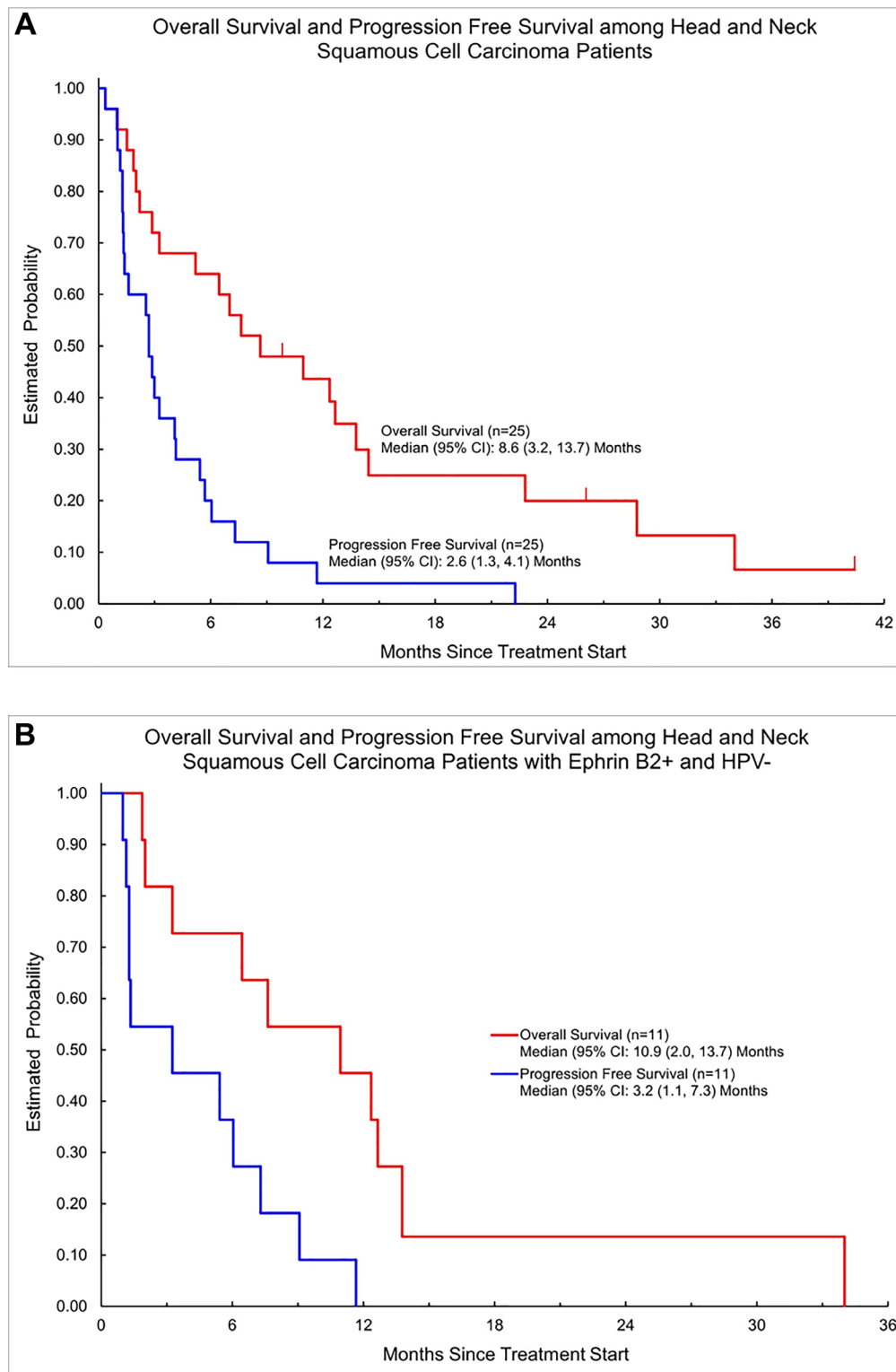
**Figure 3:** (A) Intratumoral CD3+ cell counts before initiation of therapy with sEphB4-HSA + pembrolizumab and on-therapy at week 8 biopsy. (B) Intratumoral CD8+ cell counts before initiation of therapy with sEphB4-HSA + pembrolizumab and on-therapy at week 8 biopsy.



and was not a responder. A summary of all cases with paired sample analysis, biomarker status and response is shown (Table 6) (Figure 3A, 3B). A representative case who achieved complete remission is shown (Figure 7).

## DISCUSSION

This study in relapsed-refractory HNSCC who had progressed after systemic therapy showed favorable



**Figure 4:** (A) Kaplan-Meier survival curve of all patients on clinical trial of sEphB4-HSA plus pembrolizumab. (B) Kaplan-Meier survival curve of HPV-negative patients on clinical trial of sEphB4-HSA plus pembrolizumab.

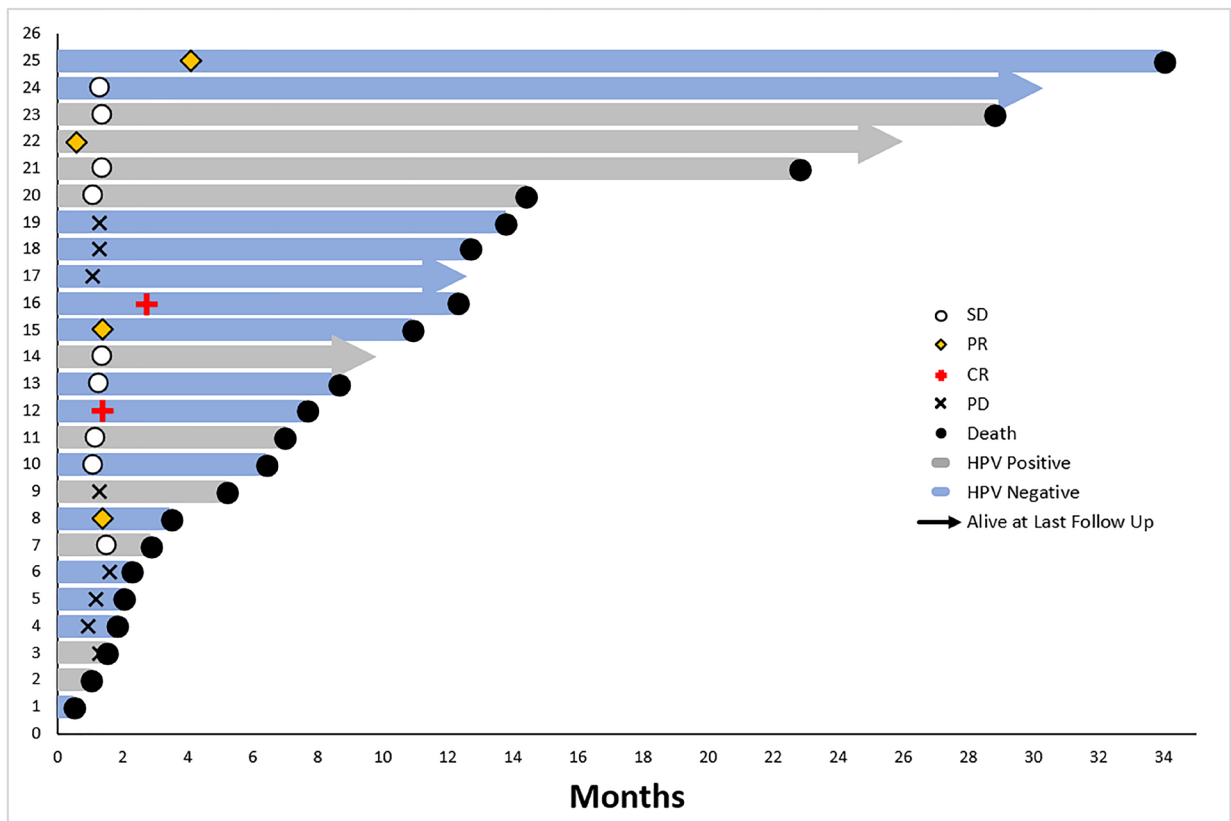


Figure 5: Overall survival swimmer plot, intent-to-treat patient population on clinical trial of sEphB4-HSA plus pembrolizumab ( $n = 25$ ).

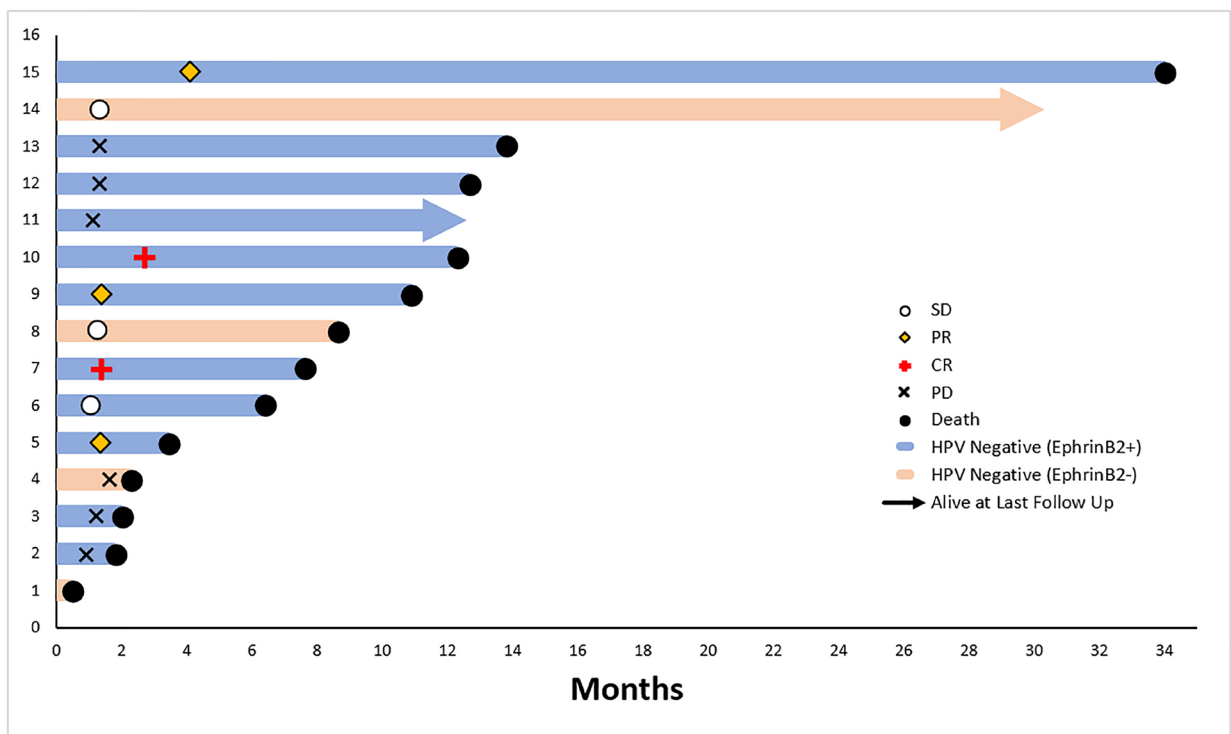


Figure 6: Overall survival swimmer plot, HPV-negative intent-to-treat patient population on clinical trial of sEphB4-HSA plus pembrolizumab ( $n = 15$ ).

**Table 4: EphrinB2, PD-L1 expression and overall response rates in all patients (intent-to-treat population, N = 25)**

| Population (N = 25)<br>ORR (%) | PD-L1 Positive<br>(n = 12)  | PD-L1 Negative<br>(n = 13)  |                                  |
|--------------------------------|-----------------------------|-----------------------------|----------------------------------|
| EphrinB2 positive<br>(n = 16)  | 3/8 (38)                    | 3/8 (38)                    | All EphrinB2 Pos.<br>6/16 (37.5) |
| EphrinB2 negative<br>(n = 9)   | 0/4 (0)                     | 0/5 (0)                     | All EphrinB2 Neg.<br>0/9 (0)     |
|                                | All PD-L1 Pos.<br>3/12 (25) | All PD-L1 Neg.<br>3/13 (23) |                                  |

**Table 5: EphrinB2, PD-L1 expression and overall response rates in HPV-negative patients (intent-to-treat population, n = 15)**

| Population (n = 15)<br>ORR (%) | PD-L1 Positive<br>(n = 7)           | PD-L1 Negative<br>(n = 8)           |   |
|--------------------------------|-------------------------------------|-------------------------------------|---|
| EphrinB2 positive<br>(n = 11)  | 2/5 (40)                            | 3/7 (60)                            | All HPV Neg./EphrinB2 Pos.<br>5/11 (45) |
| EphrinB2 negative<br>(n = 4)   | 0/2 (0)                             | 0/1 (0)                             | All HPV Neg./EphrinB2 Neg.<br>0/4 (0)   |
|                                | All HPV Neg./PD-L1 Pos.<br>2/7 (29) | All HPV Neg./PD-L1 Neg.<br>3/8 (38) |   |

**Table 6: Patients (n = 9) with paired biopsies at baseline and on therapy, and change in intratumoral CD3 and CD8 T cells**

| Patient No. | HPV status | RECIST response | EphrinB2 expression | PD-L1 expression | Intratumoral immune cell increase or pCR |
|-------------|------------|-----------------|---------------------|------------------|--|
| 1           | Positive   | SD              | Positive            | Positive         | pCR                                      |
| 2           | Positive   | SD              | Positive            | Negative         | pCR                                      |
| 3           | Positive   | SD              | Negative            | Positive         | No change                                |
| 4           | Positive   | PD              | Negative            | Negative         | No change                                |
| 5           | Negative   | PR              | Positive            | Positive         | Increase                                 |
| 6           | Negative   | SD              | Positive            | Positive         | pCR                                      |
| 7           | Negative   | CR              | Positive            | Positive         | Increase                                 |
| 8           | Negative   | CR              | Positive            | Negative         | Increase                                 |
| 9           | Negative   | PR              | Positive            | Negative         | Increase                                 |

Abbreviations: SD: Stable Disease; PD: progressive disease; PR: partial response; CR: complete response; pCR: pathologic complete response.

activity in the HPV-negative/EphrinB2-positive patients. sEphB4-HSA in combination with pembrolizumab has a safety profile similar to what has been observed previously with no overlapping toxicity. The most common toxicity with sEphB4-HSA is hypertension which requires management.

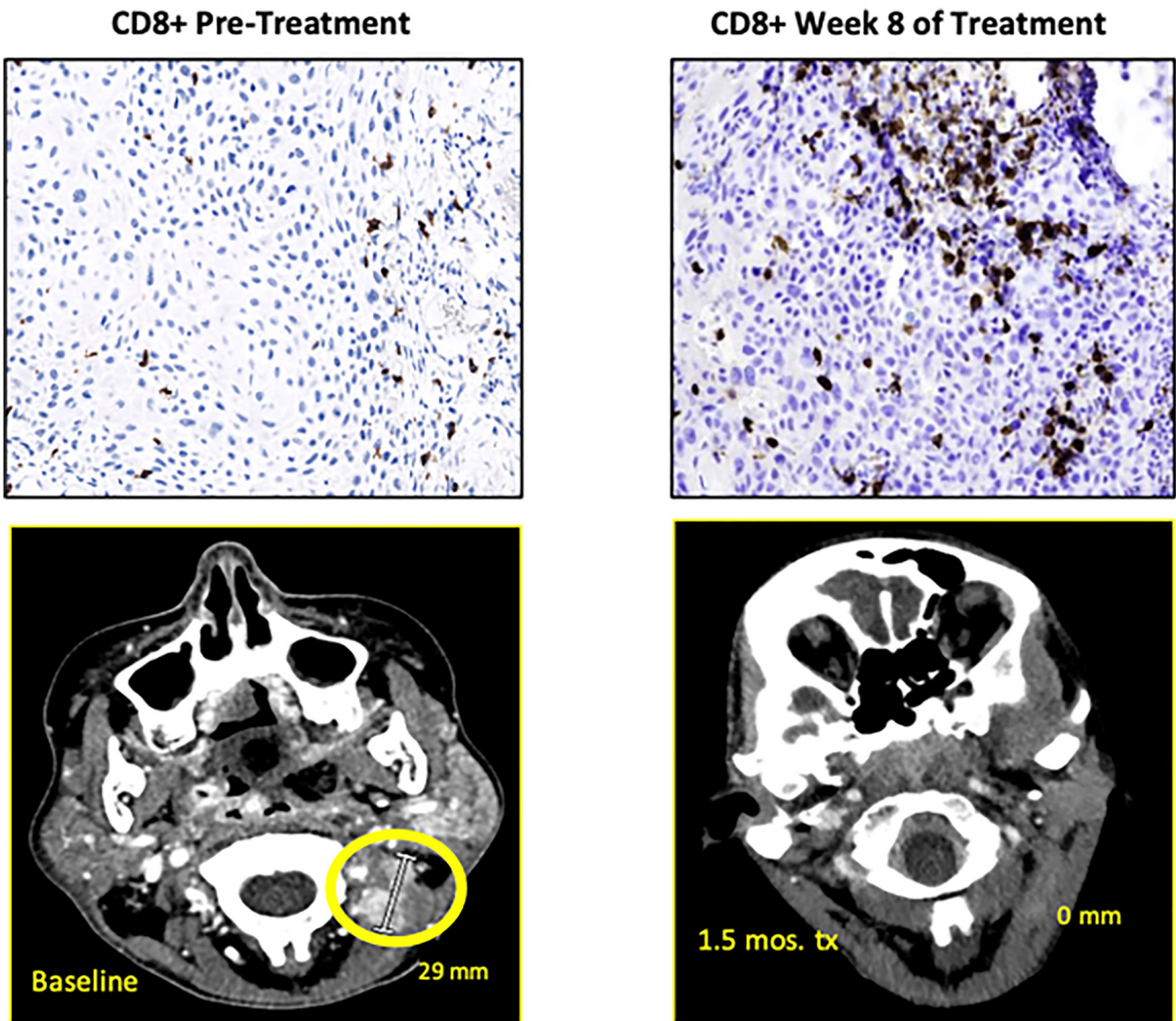
EphrinB2 expression is higher in HPV-negative patients compared to HPV positive patients (73% vs. 60%). this difference does not account for significant difference in response rates among the two groups. This may be related to the level of EphrinB2 expression. HPV may even suppress EphrinB2 expression as observed in

HPV-positive neoplastic keratinocytes *in vitro* [29, 30]. DNA alterations are more frequent in HPV-negative HNSCC which may drive EphrinB2 expression [31]. The median overall survival in the entire cohort of 8.6 months, and 10.9 months in the HPV-negative/EphrinB2 positive group. The HPV-negative population who typically have worse outcomes in HNSCC did better with this combination therapy which should be investigated [7, 11, 12].

Preclinical studies indicate that inhibition of EphrinB2 promotes immune cell recruitment into the tumor [32]. This function is critically required to enhance the efficacy of PD-1-PD-L1 directed therapy. It is known that PD-1 Ab therapy is most effective if the tumors have pre-existing immune cells in the tumor, and PD-1 Ab therapy has low overall response in HNSCC especially in HPV-negative patient population [33, 34].

Increase in recruitment of immune cells when sEphB4-HSA is combined with PD-1 Ab therapy, and a greater than doubling of the overall response rate in the HPV-negative patient population supports complementary and independent functions of each therapy.

Some of the patients developed complete remission on the combination therapy. Genomics and proteomics analysis will help define the patients likely to have rapid tumor regression. In some patients rapid tumor regression seen with this treatment could have undesirable consequences as these patients experienced exposure of underlying tissue and delayed epithelialization of the anatomic defect [35, 36]. Future development for sEphB4-HSA in HNSCC is likely to focus on patients with HPV-negative disease where there is greatest need to improve on the outcomes with pembrolizumab monotherapy.



**Figure 7: Baseline and on-therapy imaging and biopsy results showing radiographic resolution of tumor and increase of intratumoral COB+ cells.**



## MATERIALS AND METHODS

### Patients

This was a phase II, single-arm, non-randomized clinical trial evaluating the efficacy of sEphB4-HSA combined with pembrolizumab (MK-7435) in patients with squamous cell carcinoma of the head and neck (HNSCC). Patients of age  $\geq 18$  years old with HNSCC who met eligibility criteria were enrolled. Patients had locally advanced or metastatic disease that had progressed after platinum-based chemotherapy and received up to 2 prior lines of treatment. Patients who refuse first line platinum-based chemotherapy were also eligible. All patients had measurable disease based on RECIST 1.1 (Response Evaluation Criteria in Solid Tumors), an ECOG (Eastern Cooperative Oncology Group) performance status of 0 or 1, and had baseline tumor tissue available for analysis. Signed informed consent was obtained from each study subject prior to enrollment. Serum, plasma, and peripheral blood mononuclear cells were collected at baseline and every 4 cycles. Tumor tissue was collected at week 8 (cycle 2) on therapy when possible. HPV-positivity was determined in patients with oropharyngeal carcinoma using surrogate p16 positivity in baseline tumor tissue. Patients who received prior therapy with anti-PD-1, or anti-PD-L1 agents were excluded. Other exclusions included known active central nervous system (CNS) metastases, autoimmune disease, pneumonitis, HIV, bleeding disorders, those receiving anti-coagulation or anti-platelet therapy, those with undiagnosed or uncontrolled hypertension ( $>150/90$  mmHg), and those with evidence of stroke or myocardial infarction within 6 months prior to study enrollment. Patients with hypertension controlled with medications were eligible.

### Treatment

Patients received sEphB4-HSA 10 mg/kg once per week on days 1, 8 and 15, and pembrolizumab 200 mg by intravenous infusion, once every 3 weeks, day 1 of each 3-week cycle for up to 24 months. Treatment was discontinued for confirmed radiographic disease progression, unacceptable adverse experiences, intercurrent illness, or noncompliance with treatment. Tumor imaging was performed every 6 weeks (every 2 cycles) by computed tomography (CT) scan of the neck, chest, abdomen, and pelvis and assessed according to RECIST.

The National Cancer Institute Common Terminology Criteria for Adverse Events (NCI CTCAE), Version 4.0 was used to grade and record adverse experiences (AEs) and toxicities. Pembrolizumab was withheld for drug-related toxicities and severe or life-threatening AEs. Treatment was permanently discontinued for all grade 4 toxicities, and certain grade 3 toxicities including renal failure, pneumonitis, infusion reaction, and elevated AST, ALT, or bilirubin. Treatment was continued for any grade

hypertension while antihypertensive drugs were initiated; in cases of a second occurrence of grade 3 hypertension, treatment with sEphB4-HSA was held until hypertension returned to grade  $\leq 2$  at which point treatment could be resumed with dose reduction. Level 1 dose reduction reduced sEphB4-HSA to 5 mg/kg per week and 2.5 mg/kg per week for Level 2. Patients could have a maximum of 2 dose reductions for drug-related toxicity, after which sEphB4-HSA was discontinued.

### Biomarker Analysis

Immunohistochemistry (IHC) was performed on patient tumor samples obtained at baseline and week 8 (cycle 2) on therapy. Biomarkers analyzed included EphrinB2, PD-L1, immune cell markers CD3, and CD8 for both collections. Patient tissue samples at baseline were sent to Caris Life Sciences for comprehensive tumor sequencing and PD-L1 using Monoclonal Rabbit Anti-PD-L1 Clone 28-8 or 22c3 assays. Scoring for PD-L1 on both baseline and on-treatment tissue samples included tumor and immune cell membrane PD-L1 staining, including cytoplasmic staining in the case of the 28-8 assay. Patients were determined to be PD-L1 positive if their tissue sample at baseline demonstrated  $\geq 1\%$  combined positive score (CPS) in the case of the 22c3 assay or  $>1\%$  tumor proportion score (TPS) in the case of the 28-8 assay. The scoring procedures and staining protocol are described in the instructions of the commercial assay for squamous cell carcinoma of the head and neck. IHC for EphrinB2 and immune markers was performed at the CLIA approved core laboratory and analyzed by an independent pathologist (I.S.) EphrinB2 assay used Rabbit Monoclonal Anti-Ephrin B2 antibody. Scoring and analysis for EphrinB2 positivity at baseline and on-treatment biopsy was based on tumor cell membrane staining for EphrinB2. Patients were determined to be EphrinB2 positive if their tissue sample at baseline demonstrated  $\geq 1\%$  TPS [37]. p16 staining was done in the CLIA certified clinical laboratory as a routine service. IHC of immune markers was performed to assess immune cell infiltration into the tumor. This included staining for CD3 and CD8. Immune marker analysis was performed on baseline and on-therapy collected tumor tissues [38]. Tumor infiltration was defined as an increase of at least 100% in immune cells quantified by running DAB positive cell detection analysis on areas within the tumor boundary using *QuPath* software on CD3 and CD8 stained slides within the tumor from baseline to on-therapy biopsy.

### Trial oversight

The study was designed and conducted as in investigator-initiated trial (IIT). The study was approved by the Institutional Review Board (IRB) of the University of Southern California, registered at ClinicalTrials.gov

as NCT03049618. The IRB and the Data Safety and Monitoring Committee (DSMC) provided the safety monitoring of the study. The trial was conducted in accordance with the protocol with Good Clinical Practice Guidelines, and the provisions of the Declaration of Helsinki. All patients provided written informed consent before study enrollment.

## Statistical analysis

Standard descriptive statistics were used to summarize the demographics and baseline clinical characteristics and the results of this trial. The observed overall response rate (ORR) was reported as percentage and its associated 95% confidence interval (CI) was calculated [39]. Overall survival (OS) was calculated from the time of treatment start to date of death, due to any causes. Progression free survival (PFS) was calculated from the time treatment start to death or disease progression observed whichever occurred first; patients who were alive and free of disease progression were censored at the date that their status was last documented. The Kaplan-Meier product limit method was used to display the OS and PFS pattern over time. Median OS and PFS were based on Kaplan-Meier plots; their associated 95% CIs were calculated using Greenwood's standard errors formula [40]. Log-rank test was used for testing the association of HPV, P16, EphrinB2, and PD-L1 status with OS and PFS. Fisher's exact test [41] was used for testing the association of biomarkers with response. All reported *p* values were two-sided and *p* values < 0.05 were considered statistically significant.

## Abbreviations

HNSCC: Head neck squamous cell carcinoma; OS: overall survival; PFS: progression-free survival; ORR: overall response rate; sEphB4-HSA: soluble EphB4-human serum albumin; CR: complete response; PR: partial response; SD: stable disease; PD: progressive disease; HPV: human papillomavirus.

## AUTHOR CONTRIBUTIONS

Protocol design was performed by ABE, JJN, and PSG. Data analysis was performed by AJ, JWWT, KGK. Study procedures were performed by BJG, JWWT, VD, KGK, ABE, JST, DIQ and JJN. Statistical analysis was performed by DT. Protocol writing was performed by AJ, BJG, JWWT, VD, KGK, ABE, JST, DT, DIQ, PSG and JJN.

## CONFLICTS OF INTEREST

Vinay Duddalwar has received consulting fees from DeepTek, Radmetrix, Cohere, Roche and research

grant from Samsung. Barbara Gitlitz is employed by and has stock ownership in Roche/Genentech. Jorge Nieva receives research support from Merck and Genentech. He receives consulting fees from Aadi Biosciences, Affymimmune, ANP Technologies, Astra Zeneca, BioAtla, G1 Therapeutics, Genentech, Kalivir, Mindmed, Naveris, Sanofi. Parkash Gill has equity interest in VasGene.

## ETHICAL STATEMENT

This work was overseen by the University of Southern California Institutional Review Board under protocol HS-16-00584.

## CONSENT

All patients treated in the clinical trial provided written informed consent for participation.

## FUNDING

This work was supported by a research grant from Merck and by the National Cancer Institute's USC Cancer Center Support Grant P30 CA014089.

## REFERENCES

1. Sung H, Ferlay J, Siegel RL, Laversanne M, Soerjomataram I, Jemal A, Bray F. Global Cancer Statistics 2020: GLOBOCAN Estimates of Incidence and Mortality Worldwide for 36 Cancers in 185 Countries. *CA Cancer J Clin.* 2021; 71:209–49. <https://doi.org/10.3322/caac.21660>. [PubMed]
2. Siegel RL, Miller KD, Fuchs HE, Jemal A. Cancer Statistics, 2021. *CA Cancer J Clin.* 2021; 71:7–33. <https://doi.org/10.3322/caac.21654>. [PubMed]
3. Sturgis EM, Wei Q, Spitz MR. Descriptive epidemiology and risk factors for head and neck cancer. *Semin Oncol.* 2004; 31:726–33. <https://doi.org/10.1053/j.seminoncol.2004.09.013>. [PubMed]
4. Hennessey PT, Westra WH, Califano JA. Human papillomavirus and head and neck squamous cell carcinoma: recent evidence and clinical implications. *J Dent Res.* 2009; 88:300–6. <https://doi.org/10.1177/0022034509333371>. [PubMed]
5. Friend K, Levy DT. Reductions in smoking prevalence and cigarette consumption associated with mass-media campaigns. *Health Educ Res.* 2002; 17:85–98. <https://doi.org/10.1093/her/17.1.85>. [PubMed]
6. Fakhry C, Westra WH, Li S, Cmelak A, Ridge JA, Pinto H, Forastiere A, Gillison ML. Improved survival of patients with human papillomavirus-positive head and neck squamous cell carcinoma in a prospective clinical trial. *J Natl Cancer Inst.* 2008; 100:261–69. <https://doi.org/10.1093/jnci/djn011>. [PubMed]

7. Chow LQM, Haddad R, Gupta S, Mahipal A, Mehra R, Tahara M, Berger R, Eder JP, Burtness B, Lee SH, Keam B, Kang H, Muro K, et al. Antitumor Activity of Pembrolizumab in Biomarker-Unselected Patients With Recurrent and/or Metastatic Head and Neck Squamous Cell Carcinoma: Results From the Phase Ib KEYNOTE-012 Expansion Cohort. *J Clin Oncol*. 2016; 34:3838–45. <https://doi.org/10.1200/JCO.2016.68.1478>. [PubMed]
8. Cohen EEW, Soulières D, Le Tourneau C, Dinis J, Licitra L, Ahn MJ, Soria A, Machiels JP, Mach N, Mehra R, Burtness B, Zhang P, Cheng J, et al, and KEYNOTE-040 investigators. Pembrolizumab versus methotrexate, docetaxel, or cetuximab for recurrent or metastatic head-and-neck squamous cell carcinoma (KEYNOTE-040): a randomised, open-label, phase 3 study. *Lancet*. 2019; 393:156–67. [https://doi.org/10.1016/S0140-6736\(18\)31999-8](https://doi.org/10.1016/S0140-6736(18)31999-8). [PubMed]
9. Burtness B, Harrington KJ, Greil R, Soulières D, Tahara M, de Castro G Jr, Psyri A, Basté N, Neupane P, Bratland Å, Fueeder T, Hughes BGM, Mesia R, et al, and KEYNOTE-048 Investigators. Pembrolizumab alone or with chemotherapy versus cetuximab with chemotherapy for recurrent or metastatic squamous cell carcinoma of the head and neck (KEYNOTE-048): a randomised, open-label, phase 3 study. *Lancet*. 2019; 394:1915–28. [https://doi.org/10.1016/S0140-6736\(19\)32591-7](https://doi.org/10.1016/S0140-6736(19)32591-7). [PubMed]
10. Vermorken JB, Trigo J, Hitt R, Koralewski P, Diaz-Rubio E, Rolland F, Knecht R, Amellal N, Schueler A, Baselga J. Open-label, uncontrolled, multicenter phase II study to evaluate the efficacy and toxicity of cetuximab as a single agent in patients with recurrent and/or metastatic squamous cell carcinoma of the head and neck who failed to respond to platinum-based therapy. *J Clin Oncol*. 2007; 25:2171–7. <https://doi.org/10.1200/JCO.2006.06.7447>. [PubMed]
11. Wang J, Sun H, Zeng Q, Guo XJ, Wang H, Liu HH, Dong ZY. HPV-positive status associated with inflamed immune microenvironment and improved response to anti-PD-1 therapy in head and neck squamous cell carcinoma. *Sci Rep*. 2019; 9:13404. <https://doi.org/10.1038/s41598-019-49771-0>. [PubMed]
12. Johnson DE, Burtness B, Leemans CR, Lui VWY, Bauman JE, Grandis JR. Head and neck squamous cell carcinoma. *Nat Rev Dis Primers*. 2020; 6:92. <https://doi.org/10.1038/s41572-020-00224-3>. [PubMed]
13. Ferris RL, Blumenschein G Jr, Fayette J, Guigay J, Colevas AD, Licitra L, Harrington K, Kasper S, Vokes EE, Even C, Worden F, Saba NF, Iglesias Docampo LC, et al. Nivolumab for Recurrent Squamous-Cell Carcinoma of the Head and Neck. *N Engl J Med*. 2016; 375:1856–67. <https://doi.org/10.1056/NEJMoa1602252>. [PubMed]
14. Muro K, Chung HC, Shankaran V, Geva R, Catenacci D, Gupta S, Eder JP, Golan T, Le DT, Burtness B, McRee AJ, Lin CC, Pathiraja K, et al. Pembrolizumab for patients with PD-L1-positive advanced gastric cancer (KEYNOTE-012): a multicentre, open-label, phase 1b trial. *Lancet Oncol*. 2016; 17:717–26. [https://doi.org/10.1016/S1470-2045\(16\)00175-3](https://doi.org/10.1016/S1470-2045(16)00175-3). [PubMed]
15. Baum J, Seiwert TY, Pfister DG, Worden F, Liu SV, Gilbert J, Saba NF, Weiss J, Wirth L, Sukari A, Kang H, Gibson MK, Massarelli E, et al. Pembrolizumab for Platinum- and Cetuximab-Refractory Head and Neck Cancer: Results From a Single-Arm, Phase II Study. *J Clin Oncol*. 2017; 35:1542–49. <https://doi.org/10.1200/JCO.2016.70.1524>. [PubMed]
16. Powles T, O'Donnell PH, Massard C, Arkenau HT, Friedlander TW, Hoimes CJ, Lee JL, Ong M, Sridhar SS, Vogelzang NJ, Fishman MN, Zhang J, Srinivas S, et al. Efficacy and Safety of Durvalumab in Locally Advanced or Metastatic Urothelial Carcinoma: Updated Results From a Phase 1/2 Open-label Study. *JAMA Oncol*. 2017; 3:e172411. <https://doi.org/10.1001/jamaoncol.2017.2411>. [PubMed]
17. Kertesz N, Krasnoperov V, Reddy R, Leshanski L, Kumar SR, Zozulya S, Gill PS. The soluble extracellular domain of EphB4 (sEphB4) antagonizes EphB4-EphrinB2 interaction, modulates angiogenesis, and inhibits tumor growth. *Blood*. 2006; 107:2330–38. <https://doi.org/10.1182/blood-2005-04-1655>. [PubMed]
18. Martiny-Baron G, Korff T, Schaffner F, Esser N, Eggstein S, Marmé D, Augustin HG. Inhibition of tumor growth and angiogenesis by soluble EphB4. *Neoplasia*. 2004; 6:248–57. <https://doi.org/10.1593/neo.3457>. [PubMed]
19. Gerety SS, Wang HU, Chen ZF, Anderson DJ. Symmetrical mutant phenotypes of the receptor EphB4 and its specific transmembrane ligand ephrin-B2 in cardiovascular development. *Mol Cell*. 1999; 4:403–14. [https://doi.org/10.1016/s1097-2765\(00\)80342-1](https://doi.org/10.1016/s1097-2765(00)80342-1). [PubMed]
20. Dong M, Spelke DP, Lee YK, Chung JK, Yu CH, Schaffer DV, Groves JT. Spatiomechanical Modulation of EphB4-Ephrin-B2 Signaling in Neural Stem Cell Differentiation. *Biophys J*. 2018; 115:865–73. <https://doi.org/10.1016/j.bpj.2018.06.031>. [PubMed]
21. Yavrouian EJ, Sinha UK, Rice DH, Salam MT, Gill PS, Masood R. The significance of EphB4 and EphrinB2 expression and survival in head and neck squamous cell carcinoma. *Arch Otolaryngol Head Neck Surg*. 2008; 134:985–91. <https://doi.org/10.1001/archotol.134.9.985>. [PubMed]
22. Broggin T, Piffko A, Hoffmann CJ, Ghori A, Harms C, Adams RH, Vajkoczy P, Czabanka M. Ephrin-B2-EphB4 communication mediates tumor-endothelial cell interactions during hematogenous spread to spinal bone in a melanoma metastasis model. *Oncogene*. 2020; 39:7063–75. <https://doi.org/10.1038/s41388-020-01473-y>. [PubMed]
23. Xi HQ, Wu XS, Wei B, Chen L. Eph receptors and ephrins as targets for cancer therapy. *J Cell Mol Med*. 2012; 16:2894–909. <https://doi.org/10.1111/j.1582-4934.2012.01612.x>. [PubMed]
24. Kumar SR, Singh J, Xia G, Krasnoperov V, Hassanieh L, Ley EJ, Scehnet J, Kumar NG, Hawes D, Press MF,



- Weaver FA, Gill PS. Receptor tyrosine kinase EphB4 is a survival factor in breast cancer. *Am J Pathol*. 2006; 169:279–93. <https://doi.org/10.2353/ajpath.2006.050889>. [PubMed]
25. Ferguson BD, Liu R, Rolle CE, Tan YH, Krasnoperov V, Kanteti R, Tretiakova MS, Cervantes GM, Hasina R, Hseu RD, Iafrate AJ, Karrison T, Ferguson MK, et al. The EphB4 receptor tyrosine kinase promotes lung cancer growth: a potential novel therapeutic target. *PLoS One*. 2013; 8:e67668. <https://doi.org/10.1371/journal.pone.0067668>. [PubMed]
  26. Xia G, Kumar SR, Stein JP, Singh J, Krasnoperov V, Zhu S, Hassanieh L, Smith DL, Buscarini M, Broek D, Quinn DI, Weaver FA, Gill PS. EphB4 receptor tyrosine kinase is expressed in bladder cancer and provides signals for cell survival. *Oncogene*. 2006; 25:769–80. <https://doi.org/10.1038/sj.onc.1209108>. [PubMed]
  27. Liu W, Ahmad SA, Jung YD, Reinmuth N, Fan F, Bucana CD, Ellis LM. Coexpression of ephrin-Bs and their receptors in colon carcinoma. *Cancer*. 2002; 94:934–39. <https://doi.org/10.1002/cncr.10122>. [PubMed]
  28. Bhatia S, Sharma J, Bukkapatnam S, Oweida A, Lennon S, Phan A, Milner D, Uyanga N, Jimeno A, Raben D, Somerset H, Heasley L, Karam SD. Inhibition of EphB4-Ephrin-B2 Signaling Enhances Response to Cetuximab-Radiation Therapy in Head and Neck Cancers. *Clin Cancer Res*. 2018; 24:4539–50. <https://doi.org/10.1158/1078-0432.CCR-18-0327>. [PubMed]
  29. Oweida A, Bhatia S, Hirsch K, Calame D, Griego A, Keysar S, Pitts T, Sharma J, Eckhardt G, Jimeno A, Wang XJ, Parkash G, Califano J, Karam SD. Ephrin-B2 overexpression predicts for poor prognosis and response to therapy in solid tumors. *Mol Carcinog*. 2017; 56:1189–96. <https://doi.org/10.1002/mc.22574>. [PubMed]
  30. Bhatia S, Nguyen D, Darragh LB, Van Court B, Sharma J, Knitz MW, Piper M, Bukkapatnam S, Gadwa J, Bickett TE, Bhuvane S, Corbo S, Wu B, et al. EphB4 and ephrinB2 act in opposition in the head and neck tumor microenvironment. *Nat Commun*. 2022; 13:3535. <https://doi.org/10.1038/s41467-022-31124-7>. [PubMed]
  31. Stransky N, Egloff AM, Tward AD, Kostic AD, Cibulskis K, Sivachenko A, Kryukov GV, Lawrence MS, Sougnez C, McKenna A, Shefler E, Ramos AH, Stojanov P, et al. The mutational landscape of head and neck squamous cell carcinoma. *Science*. 2011; 333:1157–60. <https://doi.org/10.1126/science.1208130>. [PubMed]
  32. Janes PW, Vail ME, Ernst M, Scott AM. Eph Receptors in the Immunosuppressive Tumor Microenvironment. *Cancer Res*. 2021; 81:801–5. <https://doi.org/10.1158/0008-5472.CAN-20-3047>. [PubMed]
  33. Herbst RS, Soria JC, Kowanetz M, Fine GD, Hamid O, Gordon MS, Sosman JA, McDermott DF, Powderly JD, Gettinger SN, Kohrt HE, Horn L, Lawrence DP, et al. Predictive correlates of response to the anti-PD-L1 antibody MPDL3280A in cancer patients. *Nature*. 2014; 515:563–67. <https://doi.org/10.1038/nature14011>. [PubMed]
  34. Tumeh PC, Harview CL, Yearley JH, Shintaku IP, Taylor EJ, Robert L, Chmielowski B, Spasic M, Henry G, Ciobanu V, West AN, Carmona M, Kivork C, et al. PD-1 blockade induces responses by inhibiting adaptive immune resistance. *Nature*. 2014; 515:568–71. <https://doi.org/10.1038/nature13954>. [PubMed]
  35. Scehnet JS, Ley EJ, Krasnoperov V, Liu R, Manchanda PK, Sjoberg E, Kostecke AP, Gupta S, Kumar SR, Gill PS. The role of Ephs, Ephrins, and growth factors in Kaposi sarcoma and implications of EphrinB2 blockade. *Blood*. 2009; 113:254–63. <https://doi.org/10.1182/blood-2008-02-140020>. [PubMed]
  36. El-Khoueiry A, Gitlitz B, Cole S, et al: 17 - A first-in-human phase I study of sEphB4-HSA in patients with advanced solid tumors with expansion at the maximum tolerated dose (MTD) or recommended phase II dose (RP2D). *European Journal of Cancer*. 2016; 69:S11.
  37. Cohen EEW, Bell RB, Bifulco CB, Burtneess B, Gillison ML, Harrington KJ, Le QT, Lee NY, Leidner R, Lewis RL, Licitra L, Mehanna H, Mell LK, et al. The Society for Immunotherapy of Cancer consensus statement on immunotherapy for the treatment of squamous cell carcinoma of the head and neck (HNSCC). *J Immunother Cancer*. 2019; 7:184. <https://doi.org/10.1186/s40425-019-0662-5>. [PubMed]
  38. Bankhead P, Loughrey MB, Fernández JA, Dombrowski Y, McArt DG, Dunne PD, McQuaid S, Gray RT, Murray LJ, Coleman HG, James JA, Salto-Tellez M, Hamilton PW. QuPath: Open source software for digital pathology image analysis. *Sci Rep*. 2017; 7:16878. <https://doi.org/10.1038/s41598-017-17204-5>. [PubMed]
  39. Blyth CR, Still HA. Binomial Confidence Intervals. *J Am Stat Assoc*. 1983; 78:108–16.
  40. Miller RG. Greenwood standard error. *Survival Analysis*. 1981; New York: John Wiley & Sons.
  41. Mehta CR, Patel NR. A Network Algorithm for Performing Fisher's Exact Test in  $r \times c$  Contingency Tables. *J Am Stat Assoc*. 1983; 78:427–34.