

UC Irvine

Western Journal of Emergency Medicine: Integrating Emergency Care with Population Health

Title

Massive Pneumoperitoneum

Permalink

<https://escholarship.org/uc/item/3504n6pq>

Journal

Western Journal of Emergency Medicine: Integrating Emergency Care with Population Health, 11(1)

ISSN

1936-900X

Authors

Hull, Aicha M
Buckley, Peter
Wills, Brandon K

Publication Date

2010

Copyright Information

Copyright 2010 by the author(s). This work is made available under the terms of a Creative Commons Attribution-NonCommercial License, available at <https://creativecommons.org/licenses/by-nc/4.0/>

Peer reviewed

Massive Pneumoperitoneum

Aicha M Hull, MD
Peter Buckley, DO
Brandon Wills, DO, MS

Department of Emergency Medicine, Madigan Army Medical Center, Tacoma, WA

Supervising Section Editor: Sean Henderson, MD

Submission history: Submitted June 4, 2009; Accepted July 13, 2009

Reprints available through open access at http://escholarship.org/uc/uciem_westjem

[West J Emerg Med. 2010; 11(1):92.]

An 82-year-old female presented to the emergency department with acute worsening of abdominal pain, which had been present for three months. Her physical exam showed significant signs of considerable abdominal distention, diffuse tenderness, and rigidity. She was unable to change position for upright abdominal radiographs; therefore, a modified portable flat plate abdominal radiograph was obtained (Figure).

This radiograph exhibited extensive pneumoperitoneum, which also highlights several radiographic findings. The football sign (Arrow A) is pneumoperitoneum, which outlines the falciform ligament. This may be seen as a faint linear opacity situated longitudinally within the right upper abdomen. The vertical opacity of the falciform ligament represents the laces and the remaining abdomen represents the remaining portion of an American football. The football sign is present in only 2% of adults with radiographically evident pneumoperitoneum.¹ Rigler's sign (Arrow B) is demonstrated by the outline of small bowel by intraluminal and extraluminal air.² It is the second most common radiographic appearance of pneumoperitoneum on supine radiographs, seen in 32% of patients with this condition.¹ The most common finding is the presence of right upper quadrant subdiaphragmatic free air.¹ Massive pneumoperitoneum is much less common in adults and older children, possibly due to improved ability of older patients to communicate abdominal symptoms, leading to earlier healthcare evaluation.³

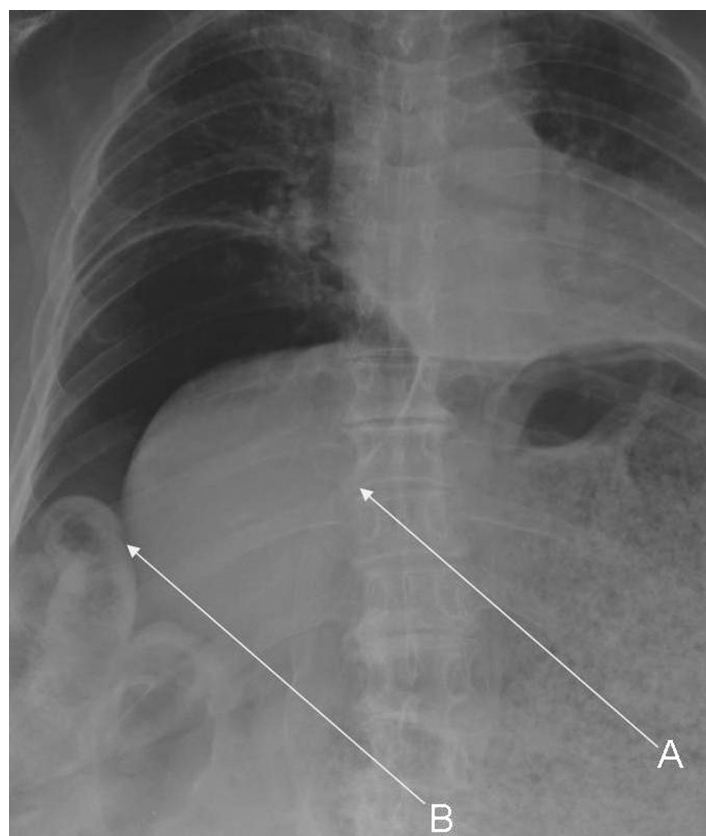


Figure. Abdominal radiograph showing football (A) and Rigler's signs (B).

REFERENCES

1. Levine MS, Scheiner JD, Rubesin SE, et al. Diagnosis of pneumoperitoneum on supine abdominal radiographs. *AJR Am J Roentgenol.* 1991; 156:731-5.
2. Milanchi S, Wood D. Rigler's sign in a patient with massive pneumoperitoneum. *Emerg Med J.* 2006; 23:884.
3. Rampton JW. The football sign. *Radiology.* 2004; 231:81-2.

Address for Correspondence: Aicha Hull, MD, MS, Department of Emergency Medicine, Madigan Army Hospital, Fort Lewis, Tacoma, WA 98431. Email aichahull@gmail.com