

UCSF

UC San Francisco Electronic Theses and Dissertations

Title

An anatomical and clinical study of the anomalous terminations of the common bile duct into the duodenum

Permalink

<https://escholarship.org/uc/item/3262v7wb>

Author

Ruggeri, Robert Arthur Giorgio

Publication Date

1976

Peer reviewed|Thesis/dissertation

AN ANATOMICAL AND CLINICAL STUDY OF THE ANOMALOUS
TERMINATIONS OF THE COMMON BILE DUCT INTO THE DUODENUM

by

ROBERT ARTHUR GIORGIO RUGGERI
B.S., UNIVERSITY OF SANTA CLARA 1974

THESIS

Submitted in partial satisfaction of the requirements for the degree of

MASTER OF ARTS

in

ANATOMY

in the

GRADUATE DIVISION

(San Francisco)



TABLE OF CONTENTS

	Page
ACKNOWLEDGEMENTS	iii
INTRODUCTION	1
METHODS	3
MORPHOLOGY OF THE BILIARY SYSTEM	
A. Embryological Development of the Liver and Biliary System	8
B. Structural Anatomy of the Hepatic-Extrahepatic Biliary System	12
1. Intrahepatic System	12
2. Common Hepatic Duct	13
3. Cystic Duct	14
4. Gallbladder	14
5. Hepatic Pedicle	15
6. Common Bile Duct	18
a. Supraduodenal	18
b. Retroduodenal	19
c. Pancreatic	19
d. Intraduodenal and the Ampulla of Vater	21
e. Sphincter of Oddi	23
f. Blood Supply to the Common Bile Duct	26
RESULTS	28
DISCUSSION	30
LITERATURE CITED	37
FIGURE	41
DATA TABLES	43
PLATES	46

ACKNOWLEDGEMENTS

I would like to express my appreciation to Dr. Harold H. Lindner for providing me with the opportunity to take part in this endeavor. I particularly thank him for his guidance throughout the project, and especially for his help in writing the clinical aspect of my thesis. I am deeply indebted to Dr. Van Arthur Peña, PhD., a second year medical student at the University of California, San Francisco, for his role as co-partner in the study. I appreciate the time he took from his studies to offer constructive criticisms and advice in the preparation of my thesis. The editorial suggestions of the other members of my committee, Dr. H.J. Ralston III and Dr. Malcolm R. Miller, were also valuable in preparing the final manuscript. Special thanks is extended to Dr. Alexander R. Margulis for his kind cooperation and advice in the examination of the cholangiograms. Finally, I wish to acknowledge the kind assistance of W.K. Birkenhagen, M.D., R.S. Bothwell, M.D. and G. Metz, M.D., who helped with the collection of cases at their individual hospitals.

INTRODUCTION

It is commonly appreciated among anatomists and surgeons that there are more anomalies associated with the excretory ducts of the liver and its vascular system than any other area of the body (Flint, 1923). In the past, most of the attention in the medical literature has been directed towards the proximal portions of the biliary tree, and comparatively little attention has been paid to the position of entrance of the common bile duct into the duodenum. As a result, descriptions of anomalies of the termination of the common bile duct are non-existent in the standard anatomical texts. A perusal of the sections on common bile duct anatomy in the British (1973) and American (1974) Gray's Anatomy, Hollinshead's exhaustive Anatomy for Surgeons (1971), and Hollinshead's Textbook of Anatomy (1974), fail to mention anomalies of the terminal course and site of termination of the common bile duct.

My interest in this subject was stimulated by a paper of Keddle, Taylor and Sykes (1974). These authors investigated the site of termination of the common bile duct in 120 patients, and reported anomalies in a surprising 23% of these individuals. Several other authors have also reported anomalies of common bile duct termination, namely Lurje (1937), Dowdy (1962), and Schulenberg (1970). Table One synthesizes the above studies. Single case reports

of extremely rare anomalous terminations of the common bile duct into the posterior wall of the stomach, duodenal bulb and ascending portion of the duodenum have been reported by other authors (Swartley & Weeder, 1935; Rosteck, 1959; Dochez et al., 1960; Eiken et al., 1961)..

In my estimation with respect to termination of the common bile duct, none of the series reported in Table One was of sufficient size or reported in sufficient detail to warrant more than cursory interest. True, Schulenberg (1970) reported 1093 cases, but only mentioned anomalies of the site of entrance of the common bile duct into the duodenum in a short paragraph. I felt that the high incidence of anomalies in Keddie's 120 patients warranted further study, both numerically, and in more detail. As a consequence I decided to study 1000 operative cholangiograms, and to report completely the results relative to common bile duct termination anomalies; their major clinical importance and possible causative factors.

METHODS

The site of termination of the common bile duct into the duodenum was studied radiographically, employing operative cholangiograms. This method permitted facile observation of common bile duct terminations of a large number of patients in a relatively short time.

Operative cholangiography is carried out during the course of an operation either before surgical exploration of the bile ducts; or postoperatively after the exploration of the ducts. The procedure involves the injection of radiopaque solutions, such as diodrast, through a needle or tube into the common bile duct and then exposing an x-ray film. The time added to an operation for each procedure is about 5 minutes. The technique of operative cholangiography is simple, well known and readily procurable in any hospital (Ferris, 1957).

Normally a study of the cholangiograms reveals the entire biliary tree including the numerous variations in size, shape, configuration and anatomical position of the common bile duct. During its descent, the common duct lies within the hepatoduodenal ligament lateral to the right margins of the bodies of the second and third lumbar vertebra. At first the common bile duct curves gently to the left away from the duodenum but gradually returns to penetrate the duodenum, forming in its course a semicircle.

The ductus choledochus may also pass downward in a vertical plane, or it may travel in a zig zag pattern and be distorted to resemble the letter S. In many instances, the common bile duct lies directly over the bodies of the second and third lumbar vertebra, rather than being lateral to them (Plates XII & XIII); or it can lie in a transverse plane throughout its entire length, crossing to the left side of the vertebral column (Plate XVIII). Moreover in viewing the numerous cholangiograms, the lower terminating portion of the common bile duct and its narrow segment as it pierces the duodenal wall may be visualized (Plate IV). This intraduodenal portion of the common bile duct is usually closely associated with the pancreatic duct, and at times if reflux of dye occurs, it too may be observed (Plate V). Also visible are possible developmental abnormalities of the common bile duct and cystic ducts, and lastly demonstration of anatomical changes due to disease or surgery (Plates XVI & XVII). Recognition of all these anatomical variations is necessary before remedial procedures can be considered.

Peroperative cholangiography has become an indispensable aspect of biliary tract surgery since the radiograms demonstrate possible obstruction of the biliary passages. Any stone lodged within the ducts will appear

as a negative shadow in a cholangiogram. Postoperative cholangiograms are important because they confirm the surgeon's opinion that the duct is free of stones, or they reveal the presence of a stone at a time when the surgeon can still re-expose the duct and remove it. In addition, they become a record of the fact that the duct was free of stones at the time of the operation.

In the study, I examined the operative cholangiograms of 2500 unselected patients who have had biliary tract surgery in the past five years. These cholangiograms were obtained from five San Francisco Bay Area hospitals: The University of California, San Francisco General Hospital, a division of the University of California; St. Mary's Hospital, San Francisco; Letterman Army Hospital, San Francisco; and Oak Knoll Naval Hospital, Oakland.

Every patient we reviewed had pre and postoperative cholangiograms taken. In the study, I selected the cholangiograms from each patient that most clearly depicted the entrance of the common bile duct into the duodenum. It didn't matter whether the cholangiograms were taken before or after surgery. Normally, postoperative cholangiograms are made using T-tubes that aid the injection of dye into the biliary ducts. These T-shaped cannulas did not seem to distort the length of the common bile duct or its

termination into the duodenum. Cholangiograms which did not clearly demonstrate the site of entrance of the common bile duct into the duodenum were routinely excluded from the study. Thus about 40% of the cholangiograms actually examined were accepted for the study. As a result, the roentgenograms used in this study were of the quality that, anatomically, the course of the common bile duct and the segments of the duodenum could be delineated clearly. For the purpose of recording the site of termination of the common bile duct, the duodenum was divided into five sections (Fig. 1): the duodenal bulb; the descending duodenum whose parts are described as normal or low; the angle; the transverse duodenum and ascending duodenum. This approach is similar to the method reported by Keddie (1974).

Normally, the duodenum forms a C-shaped curve lying to the right of the midline. In an attempt to discern any relationship between the site of entrance of the common bile duct and variations in the form and length of the duodenum, shapes of the duodenum were compared with four common patterns reported by Hollinshead (1974). Variations in duodenal shape depend in part on variations in the position of the pylorus and its effect on the movable duodenal bulb. Moreover, the disposition

of the last two duodenal parts may also vary: the transverse duodenum may run obliquely upward and to the left; or the transverse and ascending duodena may gradually curve to the left and upward so that they cannot be distinguished.

Measurements of individual duodenal and common duct lengths were also made in each patient reviewed. This was done in an attempt to determine whether length, configuration, or overall shape, had any influence upon the anomalous sites of entrance of the common bile duct. These measurements were made with the use of a Dietzgen flexible rubber ruler employed directly on the flat surface of the cholangiogram. This measuring apparatus bends to match the curve of the common bile duct and duodenum, and allows the measurement of the distance traversed by the organs in question. The actual distances marked off on the flexible rubber ruler are ascertained by comparing them to those on a regular straight-edged ruler.

EMBRYOLOGICAL DEVELOPMENT OF THE LIVER AND BILIARY SYSTEM

A necessary preliminary for any understanding of the normal anatomy of a system and its anomalies entails a review of the chief events in the developmental history of the structures. The hepatic-biliary system begins its development during the fourth week of fetal life when the embryo is 3 mm. long. The liver, together with the biliary ducts, the gallbladder and ventral pancreas arise from a diverticulum on the ventral surface of the primitive gastrointestinal tract, just distal to the junction of the foregut with the midgut. This primordial outgrowth of rapidly proliferating endodermal cells originates from the cellular lining of the gut. At about the same time as the hepatic diverticulum's growth, a dorsal pancreatic bud originates from the posterior wall of the duodenum; directly opposite the hepatic bud. This pancreatic bud develops and grows into the dorsal mesentery.

Once formed, the hepatic diverticulum proceeds to grow ventrally and cranially into the septum transversum. As the solid mass of endodermal cells spreads out within the primitive septum, it gives rise to two solid cellular buds. These two proliferating hepatic cords establish the basic structural plan of the adult liver by their patterned branching. From each of the two primary cell cords that develop, a series of branches grow out at right angles.

Each of these branches, in turn, sprouts a system of radiating smaller branches. These fine distal branches become the ducts of a secretory lobule of the liver. The primordial endodermal cord of cells from which the excretory ducts arise serves as the branch that drains the lobule into one of the main ducts leading to the duodenum (Bloom, 1926; Patten, 1968).

As these growing liver cords proliferate within the septum transversum, they break up the omphalomesenteric veins. In the early embryo, these veins run from the yolk sac to the heart. Once the liver cords penetrate them, these vessels are broken up into smaller sinusoids, which take up spaces between the ramifying branches of endodermal tubular cells. As the embryo ages, the yolk sac regresses and the greater part of the paired omphalomesenteric veins fall into disuse; the remainder form the unpaired portal vein (Patten, 1968).

The liver is unique in its blood supply. The sinusoids not only receive blood from the portal vein, which provides the postnatal liver primary access to the nutrients reabsorbed in the gut, but also from the hepatic artery whose blood supply is rich in oxygen. After the blood passes through the liver sinusoids, it travels on towards the heart by way of the hepatic veins. These vessels are

derived from the omphalomesenteric veins proximal to the point where they were broken up by the growth of the liver.

By the time the embryo approaches the 7 mm. stage, all the necessary primordia for normal biliary structural growth have arisen. These consist of the developing lobes of the liver, the solid channels of the extrahepatic biliary tracts with its gallbladder and cystic duct offshoot.

Vacuolization takes place within the biliary system's solid endodermal cell mass at the beginning of the seventh week of intrauterine life. This important development allows for the transport of bile from the liver to the duodenum. Until vacuolization occurs, the common bile duct is attached to the ventral surface of the duodenum in close contact with the ventral pancreatic bud, the duodenum and the proximal portion of the biliary tract. The normal rearrangement of the terminating part of the common bile duct should result in its entering the midportion of the posteromedial wall of the descending duodenum. It is apparent from the data in past and recent studies, that variations do occur in the new terminating site of the common bile duct.

The rotation of the gut during the seventh week also allows the two pancreatic buds (dorsal and ventral)

to meet and fuse. The ventral bud forms the uncinata process and inferior part of the head of the pancreas; the remaining bulk of the pancreas is derived from the dorsal bud. As the two independent sources of pancreatic glandular tissue fuse, their ducts anastomose. The main pancreatic duct forms from the ducts of the ventral bud and distal part of the dorsal bud. The proximal part of the duct of the dorsal bud usually persists to form the smaller accessory pancreatic duct. Normally, this smaller duct opens two centimeters above the main duct, and if both ducts are present, they will communicate with each other about 60% of the time (Smanio, 1954).

Finally as the liver continues to grow, it projects more and more into the abdominal cavity from the caudal surface of the septum transversum. By the third month, the liver almost fills the abdominal cavity. From this period on, the relative development of the liver is less active, particularly the left lobe, which actually undergoes some degeneration and becomes smaller than the right. However, up until birth, the liver is proportionately larger in the fetus than in the adult.

STRUCTURAL ANATOMY OF THE HEPATIC BILIARY SYSTEM

The most outstanding feature of the so-called normal anatomy of the entire biliary system is its high degree of variability. It has been estimated that one-third of biliary systems show the so called "normal" anatomical arrangement. The remaining two-thirds present some variation from this. My brief discussion of the normal anatomy of the biliary tree will focus mainly on the pancreatic and intraduodenal portions of the common bile duct, and particularly on the site of termination of the common duct. In addition, I will include a discussion of the proximal portions of the biliary tree.

The biliary system can be divided into the intrahepatic and extrahepatic portions. The intrahepatic portion consists of the right and left branches of the bile ducts, arteries and veins distributed in a regular array to the various segments of the liver. As bile is secreted from the hepatic parenchymal cells to its site of action in the small intestine, it first drains into the right and left hepatic ducts; the two main excretory ducts of the liver.

In their descent caudally from the liver, the right and left hepatic ducts lie between the ventral and dorsal layers of the superior portion of the hepatoduodenal ligament. These two excretory ducts are separated from each other and the adjacent corresponding arteries and

veins by areolar tissue. This tissue normally sheaths all the structures within the hepatoduodenal ligament. Due to the presence of this sheath of fibrous tissue that originates from the small biliary radicles within the liver, the relationship of the structures at the hilum of the liver are not easily altered in trauma or inflammation (Lindner & Green, 1964).

Eventually, the right and left hepatic ducts join in the hilum of the liver to form the common hepatic duct. This site of junction varies considerably. The right and left hepatic ducts normally unite at different levels outside the liver in 90% of cases. In the remaining 10%, the union is so high that these two ducts can't be found outside the liver (Hollinshead, 1971).

COMMON HEPATIC DUCT

The common hepatic duct, mentioned above, is formed by the union of the right and left excretory ducts of the liver at the level of the twelfth thoracic vertebra. The common hepatic is the most anterior of the structures present in the hilum of the liver. Once formed, the common hepatic duct descends downward and to the right within the hepatoduodenal ligament and is joined by the cystic duct. The cystic duct usually penetrates the right lateral border of the common hepatic duct at an angle. The length of the

common hepatic duct varies from 1.5 cm. to 4.0 cm. depending upon the point of union with the cystic duct.

CYSTIC DUCT

The cystic duct extends from the neck of the gallbladder to its site of union with the common hepatic duct. The cystic duct is a short tortuous structure, of which all gradations of length are encountered.

The most important structural differences that can occur with the cystic duct are its mode of junction with the common hepatic duct. As previously mentioned, the cystic duct normally enters the common hepatic duct at an angle on its right side. The cystic duct may also join the common hepatic duct in several different ways. Braasch (1958) and Lindner and Green (1964) give composite listings of such possibilities.

GALLBLADDER

As the bile descends towards the duodenum, it does not empty immediately into the bowel upon secretion. Between meals the bile empties via the cystic duct into the gallbladder, which acts as a reservoir and concentrates the bile, until it is needed for the digestions of ingested fats.

The gallbladder is a pear shaped organ, normally lying in a fossa on the visceral surface of the right lobe

of the liver..The gallbladder consists of a blindly ending fundus, a body, an infundibulum and neck which opens into the cystic duct.

The body of the gallbladder comprises the largest mass of the organ and lies in close relationship with the undersurface of the liver. It is not uncommon, because of the anatomical positions of the fundus and body, to have pathological processes within the gallbladder spread and proliferate into contiguous structures..Lindner and Green (1964) in their paper describing the embryology and surgical anatomy of the extrahepatic biliary tract list the clinical possibilities that may occur.

HEPATIC PEDICLE

The common bile duct, the cystic duct and the liver form a triangle in the porta hepatis, about which lie most of the structures of importance during biliary disease and surgery. This triangle varies with the lengths and angle of union of the hepatic and cystic ducts. Variations in the biliary duct system are less common than are variations in the arteries which constitute the major hazard in biliary surgery.

The major structures contained within the pedicle are the portal vein, hepatic artery and extrahepatic bile ducts. The portal vein in the hepatic pedicle lies posterior

to the common hepatic duct and hepatic artery. The relationship of the portal vein to the other structures found in the pedicle is not of particular importance in biliary surgery. The relationship of the branches of the hepatic artery and ducts are more important,

The hepatic artery arises from the celiac axis as the common hepatic artery which extends to the upper border of the first portion of the duodenum. Here it terminates by dividing into a descending branch, the gastroduodenal artery, and an ascending branch, the hepatic artery proper. The hepatic artery as it ascends towards the liver lies parallel and to the left of the common bile duct. Prior to its entry into the liver, the hepatic artery bifurcates into a right and left branch. Normally, the right hepatic artery crosses from left to right behind the common hepatic duct. After giving rise to the cystic artery at this point, the right hepatic artery proceeds upwards between the cystic and right hepatic ducts to enter the right lobe of the liver.

The right hepatic artery has numerous anomalies as to its sites of origin and its position in relationship to the hepatic ducts. During biliary surgery, it is usually this artery that presents itself in the area of danger, despite the fact that both the right and left

hepatic arteries may develop from numerous anomalous sites. Flint (1923) lists these possible abnormal sites encountered in his dissections.

The hepatic pedicle may also contain "accessory" hepatic ducts. These ducts arise from two or more buds given off by the embryonic biliary anlage. Canalization of these extra buds leads to the formation of the accessory ducts. Each one of the extra-hepatic ducts drains a specific area of the liver, and is the sole drainage of that portion. Aberrant hepatic ducts can be present in 11 to 31% of people depending on the study cited (Flint, '23; Lurje, '37; Dowdy, '62; Hollinshead, '71). Until 1923, the existence of accessory bile ducts had not been recorded anatomically (Flint, 1923). When present, they are usually short and exit from either lobe of the liver to empty directly into the gallbladder or the right hepatic, common hepatic, common bile and cystic ducts.

It is of obvious importance for the surgeon to recognize accessory bile ducts, when present, during a cholecystectomy. If one of them is severed and not ligated, the patient will drain bile into his peritoneum and develop postoperative complications. For this reason the standard precautionary procedure to routinely drain the right

upper quadrant is recommended after each cholecystectomy.

COMMON BILE DUCT

The common bile duct begins at the junction of the cystic and common hepatic ducts and terminates in the descending duodenum. The common bile duct is usually 2.5 to 10.0 cm. long and its length varies both with body build and with the lengths and site of junction of the cystic and common hepatic ducts. For ease in description, the common bile duct may be divided into four parts: supraduodenal, retroduodenal, pancreatic and intraduodenal.

The supraduodenal portion of the duct extends from the junction of the common hepatic and cystic ducts to the superior margin of the duodenal bulb. This portion of the duct may or may not be present, depending on where the common bile duct is formed. Sometimes the cystic and common hepatic ducts unite retroduodenally. If such is the case, there is no supraduodenal portion of the common bile duct.

If present, the supraduodenal portion of the common duct descends in the hepatoduodenal ligament along the right lateral margin of the second and third lumbar vertebra. The duct usually lies to the right of the hepatic artery and anterior to the portal vein. Clinically this portion of the common duct is frequently inspected for

disease, and because of its accessibility to the surgeon, readily opened for drainage or the exploration of stones (Lindner and Green, 1964).

The retroduodenal portion of the common bile duct lies dorsal to the first portion of the duodenum. Its length, usually 1 to 2 cm., varies with the position of the first part of the duodenum and its relation to the upper border of the head of the pancreas. This portion of the common bile duct frequently becomes involved in pathological extensions of posterior duodenal ulcers, because of the close proximity of the duct to the duodenal bulb (Lindner and Green, 1964).

The pancreatic portion of the common bile duct extends from the cephalic border of the pancreatic head to the site of entrance of the duct into the duodenal wall, a distance which varies from a short 2.5 cm. to one as long as 6.0 cm. The length of the duct depends on its site of entrance into the duodenum and size of the head of the pancreas. This portion is usually the longest of the four segments of the common duct.

The pancreatic portion of the common bile duct varies in its relationship to the head of the pancreas. The duct may lie retropancreatically (coursing between the dorsal surface of the pancreas and retroperitoneal

tissues of the posterior abdominal wall), or the duct lies in a groove in the dorsal surface of the pancreas. While in this groove, the duct is either completely uncovered or covered by a small lingula of pancreatic tissue. According to Smanio (1954), when the duct lies within the pancreatic tissue, it is easily dissected about 60% of the time. Due to this relationship, the surgeon when exposing the pancreatic portion of the common bile duct must dissect carefully so as not to create a pancreatic fistula or to cause hemorrhaging of the pancreas. Only rarely, (0.5%) does the duct course through the pancreas on its ventral surface.

The retroduodenal and superior pancreatic portions of the duct in their descent normally curve gently to the left. The inferior arc of this curvature is formed by the distal portion of the pancreatic course of the common bile duct as it turns gently to the right to terminate in the descending duodenum. Occasionally, the lower arc of the common duct will abruptly turn laterally toward the descending portion of the duodenum and enter it at a right angle.

As the common bile duct penetrates and passes through the duodenum, it does so in an oblique manner: similar in some respects to the passage of ureters through

the bladder wall. The classical anatomical description of the site of termination of the common duct places the entrance of the duct into the midportion of the postero-medial wall of the descending duodenum; at a site superior to the crossing of the duodenum by the transverse colon. This point is about 7 cm. distal from the pylorus.

The major pancreatic duct also empties into the duodenum through the duodenal papilla. Prior to the time the common bile duct and the major pancreatic duct penetrate the duodenal wall, the two ducts become closely related and run parallel to one another for a distance of from 2 mm. to 10 mm. During this close extra-duodenal association, junction of the two ducts may occur just external to the duodenal wall. The ducts may also join during their tangential course through the duodenal wall, or the common and major pancreatic ducts may enter separately and individually discharge upon the eminence of the major duodenal papilla.

The intraduodenal portion of the common bile duct passes through the bowel wall, and if joined by the major pancreatic duct just proximal to the duodenal papilla, forms the ampulla of Vater. In about 70% of cases there is an ampulla of Vater formed by the confluence of the major pancreatic duct and the common bile duct (Dowdy, 1962).

The ampulla extends from the point of union to the exit of the joined ducts on the duodenal papilla. It averages only 3 to 5 mm. in length (Dowdy, 1962). In those cases in which there is no confluence of the two ducts, there is no ampulla of Vater.

During fetal life the ampulla extends throughout the entire course of the two ducts through the duodenal wall. As growth proceeds, this "common channel" shortens as the point of junction between the common bile duct and pancreatic duct becomes placed progressively nearer the tip of the major duodenal papilla (Schwegler & Boyden, '36-'37; 1937a).

An abrupt narrowing occurs at the site where the common bile duct enters the duodenal wall (Baggenstoss, 1938). This creates problems clinically, as the mean circumference of the lumen of the common bile duct constricts to almost half of its normal size. This site becomes a frequent point for large stones to become lodged in the common bile duct. To make matters worse, any stone that enters the intraduodenal part of the common bile duct has a good chance of obstructing the ostium of the ampulla, since this is the smallest part of the common bile duct.

Another consequence of the entrance of the common bile and chief pancreatic ducts into the duodenum

is that, the longitudinal and circular muscles of the duodenal wall must swing around them in order to allow their passage. As a result, this region is one of the weaker parts of the duodenum, and diverticula of the submucosa and mucosa of the wall commonly arise (Hollinshead, 1957).

SPHINCTER OF ODDI

The ampulla as well as the entire intraduodenal portions of the common bile duct and the major pancreatic duct are surrounded by a sheath of circular smooth muscle fibers. This encircling intrinsic musculature of the duodenal system is known as the sphincter of Oddi.

Rugero Oddi (1887) was not the first to describe these sphincteric fibers. Simon Gage described the structure in 1879, but since Oddi conceived of the sphincter's physiological importance, the muscle complex bears his name (Schwegler and Boyden, 1937b). The main function of the sphincter of Oddi is to maintain enough contraction on the common bile duct to prevent a constant flow of bile from the liver into the duodenum. Bile is excreted by the liver continuously, and becomes concentrated in the gallbladder between meals. Ingestion of fat or meat automatically discharges this reservoir, as they stimulate

the release of the hormone cholecystokinin-pancreozymin from the intestinal glands in the duodenum. This hormone acts to relax the sphincter of Oddi, reopening the common bile duct. At the same time it stimulates the needed contraction of the gallbladder's musculature for the expulsion of bile from the organ.

The portion of the sphincter of Oddi which surrounds the common bile duct is the thickest and most extensive of the duodenal smooth muscle prolongations. It stretches from a point a little above the entrance of the common duct into the duodenal wall all the way to the ampulla, if present, and is called the sphincter choledochus. It increases in thickness as it runs proximally in the direction of the duodenal lumen. The muscle of the sphincter choledochus also extends distally to eventually completely encircle the ampulla and thus form the sphincter ampullae. Some circular muscle fibers extend a short distance proximally from the ampulla to surround the lower end of the pancreatic duct. These fibers form the pancreatic sphincter. It becomes obvious therefore that the sphincter of Oddi is made up of the compensation of three separate sphincteric groupings; those about the common bile duct alone, those about the terminal part of the pancreatic duct and those fibers surrounding the discharging of the

duodenal eminence. Longitudinal smooth muscle fibers are present between the surfaces of the common bile duct and the pancreatic duct. They facilitate the flow of bile through the common duct, shortening the duct as they contract. However, these longitudinal smooth muscle fibers are not part of the sphincteric muscle complex.

Contrary to past common belief, the sphincter does not develop from the circular and longitudinal layers of the intestine. According to Schwegler and Boyden (1937a), it differentiates from mesenchyme quite independent of the developing duodenal musculature, and has therefore no continuity with the bowel. Benevanto and Schein (1968) and Ono and coauthors (1968) further confirm this observation in their separate studies of the sphincter of Oddi. They discovered that the sphincter functions independent of the activity of the duodenum.

The anatomical description of the terminal portion of the common bile duct relates only to those cases in which the common bile duct empties into the central portion of the descending duodenum. As far as I know there is no information available at present relative to the mode of entrance of the common bile duct into the duodenal lumen in those few cases in which visualization of the common bile duct resulted in a concomitant visualization of the

major pancreatic duct (common channel). It appears that the mode and method of junction is similar to that described for the entrance of the two ducts into the midportion of the descending duodenum. However, the number of cases so noted in this study is far too small for me to do more than speculate on the ductal and sphincteric arrangements, when an anomalous site of common duct entrance is present.

BLOOD SUPPLY TO THE COMMON BILE DUCT

The supra and retroduodenal portions of the common bile duct are supplied by descending branches from the cystic and hepatic arteries. The major blood supply to the common bile duct is from the posterior superior pancreaticoduodenal artery which supplies the pancreatic and intra-duodenal portions of the common duct.

The posterior superior pancreaticoduodenal artery arises from the gastroduodenal artery behind the first part of the duodenum, and descends along the dorsal length of the pancreas before joining the posterior inferior pancreaticoduodenal artery. A similar arcade is formed by terminating branches of the gastroduodenal and superior mesenteric arteries on the anterior surface of the pancreas.

These dorsal and ventral arcades not only supply the common bile duct, but also the pancreas and duodenum. The relationships among these structures are as complex as

their common embryological origin and intimate anatomical relationships would indicate.

RESULTS

Of the 1000 cases which were examined, the common bile duct entered the descending duodenum in 86.9% of patients. It entered the angle, the junction between the descending and transverse duodena, and the transverse duodenum in 13.1% of individuals. This latter figure indicates that a significant number of variations from the norm are present. The data is organized according to hospital and site of entrance of the common bile duct, and is presented in Table 2. In this study, no observations were made of aberrant terminations of the common bile duct into the duodenal bulb, ascending duodenum, or any extra duodenal loci.

The average length of the descending duodenum was measured as 9 cm. I found no apparent relationship between the length of the duodenum and anomalies of the termination of the common bile duct; nor did I observe any relationships between either the length or site of entrance of the common bile duct and the shape of the duodenum. In patients whose common bile ducts entered the duodenum proximal to the junction of the descending and transverse duodena, the average length of the common bile duct was 4.8 cm. (range 2.5 cm. to 6.9 cm.). In those cases where the entrance of the common bile duct was anomalous, the average length of the common bile duct was 6.6 cm. (range

3.8 cm. to 10.1 cm.). It is clear from this study that the lengths of the common bile duct vary, as expected, depending on the duct's site of termination into the duodenum. This adds to the already complicated structural pattern of the extrahepatic biliary system, and occurs regularly presenting problems to surgeons trying to locate elusive intraductal stones.

DISCUSSION

Obviously the site of entrance of the common bile duct into the duodenum becomes of great importance to the surgeon and to the radiologist in diseases of the extrahepatic biliary tract both diagnostically and therapeutically. This is felt to be true for the following reasons: (1) The study indicates that in at least 13% of cases the duodenal papilla will appear at the junction of the descending and transverse duodena or the transverse portion of the duodenum, far removed from its normal location in the supracolic portion of the descending duodenum. In at least another 5% the duodenal eminence is found well below the level of crossing of the duodenum by the transverse colon. In order to accurately inspect, probe, flush and manipulate the biliary ampulla and eminence through a duodenotomy incision, one would have to mobilize the transverse colon or perhaps even the ligament of Treitz, so that such a duodenotomy could be carried out. This would entail further time consuming surgical manipulation and possibly add to the surgical morbidity. One wonders whether on those few occasions when the surgeon has been unable to locate the duodenal biliary eminence, it has been occupying a position in the lower descending or transverse duodenum. (2) Although the creation of false biliary passages secondary to

operative procedures upon the distal common duct is a relatively rare event, perhaps one of the reasons for its occurrence is the surgeon's attempt to negotiate a curve which is not there or failure to negotiate a curve which is there. On all of the films which show an abnormal site of biliary entrance, it appears to me that this is a distinct possibility. (3) In those cases where a radical pancreatectomy is to be carried out, leaving behind only a narrow rim of pancreatic tissue, ostensibly containing the common bile duct, it is of great importance to do an operative cholangiogram before such a procedure is carried out, so that the operating surgeon may have some idea as to the site of entry of the common duct into the duodenum. This knowledge it appears would tend to diminish greatly the possibility of a postoperative pancreatico-biliary fistula. (4) Since the data shows an amazingly high percentage of anomalous sites of entry of the common duct into the duodenum, one thought that has bothered Dr. Harold H. Lindner is, why in some almost 40 years of experience in biliary tract surgery has he not encountered this anomaly? One cogent suggestion (Hadfield, 1973) to explain this occurrence lies in the physiologic peristaltic activity inherent in the duodenum. Some observers have compared the duodenum to a churn, a

site of major peristaltic movement with a continual contraction and shifting of duodenal position, carried out during the early stages of food digestion. Is it possible that those cholangiograms which show a remarkable distal opening of the common duct into the duodenum may be showing an apparent anomaly as a result of a forward extension or thrust of that portion of the duodenum which would normally be classified as mid descending duodenum? One argument against this conjecture is the fact that cholangiograms were taken during surgery with the patient on starvation status and obviously not physiologically inclined to have an active duodenum.

(5) It has definitely been observed that those common ducts that are going to enter the duodenal angle or proximal transverse duodenum tend to drop inferiorly from the inferior surface of the first portion of the duodenum rather than curving gently to the left and then compensating with a right curve. Moreover, during its descent, the common bile duct in those cases in which it terminates anomalously, often lies closely adjacent to the right lateral border of the vertebral column or may lie ventral to the vertebrae. These observations were also made by Hicken et al. (1949), and are so constant that I feel it should alert both the radiologist and surgeon to the

possibility of an anomalous duodenal entrance. These facts should also serve as a danger signal in those cases where the common duct is blocked by a stone or tumor and its distal portion cannot be filled with dye. In such cases the surgeon should proceed with caution so that a false passage will not be made. (6) In order to explain the high percentage of anomalies encountered in the termination of the common bile duct, one may envision the following events to be responsible for the production of these anomalies. The Bland Sutton theory states that abnormalities tend to occur at the sites of embryological events. This being true, the simplest explanation for the occurrence of these anomalies suggests that at some time during fetal growth, the primordial hepatic diverticulum develops originally from a site distal to its normal position of outgrowth. Another possibility is that the common bile duct actually enters the descending duodenum normally, but due to an increased length of the proximal upper portion of the duodenum, the lower portion of the descending duodenum folds upon itself to give the impression that the duct terminates anomalously. Another explanation for the abnormal terminations of the common bile duct into the duodenum suggests an aberrant process in the vacuolization of the solid endodermal cell masses of the hepatic, cystic,

and common bile ducts and the gallbladder. This process usually takes place during the seventh week when the fetus is only 5 mm. in length. Any slight variance in the canalization of the biliary ducts may just be the difference between a normal entry and an anomalous one, because of the extremely short distances involved. Also, during the tenth week of intrauterine life, there occurs a dorsal left to right rotation of the ventral pancreatic bud, the duodenum, and proximal portion of the biliary tract. Possible disturbances in the rotation of these structures may cause the normal termination of the common bile duct into the posteromedial surface of the descending duodenum to become anomalous. Finally when the transverse duodenum, which crosses ventral to the midportion of the descending duodenum, reenters the abdominal cavity during the tenth week of fetal life, it can, as it settles within the abdomen, catch the duodenum and pull it horizontally to the left to parallel the colon's course. It thereby may shorten the duodenum's length and change its position and shape; giving us the impression that the duct enters farther distally than its actual normal location.

(7) The majority of problems that arise in the biliary system and necessitate surgery result from stones in the gallbladder or lodged within the ducts. As previously

mentioned, an abrupt narrowing of the common bile duct occurs when it enters the duodenal wall. This site of biliary constriction is a common place for large stones to rest. In addition, any stone that passes into the ampulla may become lodged at its ostium hindering the flow of bile. A completed occlusion of the normal flow of bile from the liver causes the bile to become concentrated in the blood and tissues of the body creating a jaundice in that person. It is essential for the surgeon to know where the common bile duct terminates, if he is to successfully clear the duct of stones during surgery. The standard treatment for cholecystitis and choledocholithiasis is surgery on the gallbladder and common bile duct. Such an operation is not a "routine" procedure, despite the fact that annually 400,000 Americans undergo surgery for biliary disease (KRON-TV, 1976). Biliary surgery usually takes about three to four hours and is considered the most difficult of abdominal procedures, because of the area's notoriously high degree of structural variability. Surprisingly, 6000 people, 2% of those treated, die from complications (Dunphy and Way, 1975). Many of the postoperative complications that arise are due to the surgeon's lack of familiarity with the variants of the extrahepatic biliary system. An alternative

experimental treatment which appears to have efficacy in selected cases employs chenodeoxycholic acid. A study is underway at San Francisco General Hospital to test the effectiveness of using this primary bile salt as a possible nonsurgical treatment for the dissolution of bile stones (Dunphy and Way, '75; KRON-TV, '76). When given orally to gallstone patients, chenodeoxycholic acid expands the bile salt pool to normal bile salt concentrations. This desaturates the bile with respect to cholesterol and slowly dissolves gallstones. If this treatment is found safe, approximately one third of the patients who would undergo gallstone surgery would not require such treatment.

LITERATURE CITED

- Baggenstoss, A.H.: Major duodenal papilla: Variations of pathologic interest and lesions of the mucosa. Arch. Path. 26: 853-72, 1938.
- Beneventano, T.C. and Schein, C.J.: The physiologic basis of cholangiographic interpretation: Pseudocalculus sign and problem of duct spasm. Surgery 63: 673, 1968.
- Bloom, W.: The embryogenesis of human bile capillaries and ducts. American Journal Anatomy 36: 451-65, 1926.
- Braasch, J.W.: Congenital anomalies of the gallbladder and bile ducts. S. Clinics N.A. 38: 627-30, 1958.
- Dochez, C. and Haber, I.: Atypical localization of the choledochus orifice. Fortschr. Geb. Roentgenstr. Nuklearmed 93: 515-18, 1960, (Ger).
- Dowdy, G.S. Jr., Waldron, G.W. and Brown, W.G.: Surgical anatomy of the pancreatico-biliary ductal system - observations. Archives of Surgery, 229-46, 1962.
- Dunphy, J.B. and Way, L.W.: Current Surgical Diagnosis and Treatment, Second Edition, Los Altos, Lange Medical Publications, 1975.
- Eiken, M. and Pock-Steen, O.C.: Termination of the choledochus in a duodenal diverticulum. Fortschr. Geb. Roentgenstr. Nuklearmed 94: 619-22, 1961, (Ger).

- Ferris, D.O.: Technique of operative cholangiography. The Surgical Clinics of North America, 933-37, 1957.
- Flint, E.R.: Abnormalities of the right hepatic, cystic and gastroduodenal arteries, and of the bile ducts. Br. J. Surg. 10: 509-19, 1923.
- Gray's Anatomy, 35th British Edition, Edited by Warwick, R. and Williams, P.L.: Philadelphia, W.B. Saunders, 1973.
- Gray's Anatomy, 29th American Edition, Edited by Goss, C.M.: Philadelphia, Lea and Febiger, 1974.
- Hadfield, G.J.: Surgical anatomy of the biliary tract: As demonstrated by Peroperative Cholangiography. Ann. R. Coll. Surg. England. 52: 380-91. 1973.
- Hicken, N.F., Coray, Q.B. and Franz, B.: Anatomic variations of the extrahepatic biliary system as seen by cholangiographic studies. Surgery, Gynecology and Obstetrics 88: 577-84, 1949..
- Hollinshead, W.H.: The lower part of the common bile duct: A review. The Surgical Clinics of North America, 939-51, 1957.
- Hollinshead, W.H.: Anatomy for Surgeons. Vol. 2, Second Edition, New York, Harper and Row, 1971.

- Hollinshead, W.H.: Textbook of Anatomy. Third Edition,
New York, Harper and Row, 1974.
- Keddie, N.C., Taylor, A.W. and Sykes, P.A.: The termination
of the common bile duct. Br. J. Surg. 61: 623-25,
1974.
- KRON-TV: San Francisco; Newswatch Program 5:30 - 6:30 P.M.
March 7, 1976.
- Lindner, H.H. and Green, R.B.: Embryology and surgical
anatomy of the extrahepatic biliary tract. The
Surgical Clinics of North America, Vol. 44: 1273-85,
1964.
- Lurje, A.: The topography of the extrahepatic biliary
passages. Annals of Surgery, 161-68, 1937.
- Oddi, R.: D'une disposition a sphincter special de
l'ouverture du canal choledoque. Arch. Ital. di
Biol. VIII: 317-22, 1887.
- Ono, K., Watanabe, N., Suzuki, K., Tsuchida, H., Sugiyana, Y.
and Abo, M.: Bile flow mechanism in man. Arch. Surg.
96: 869, 1968.
- Patten, B.M.: Human Embryology, McGraw-Hill Inc., 387-394,
1968.

Rosteck, K.: Deformity of the bulbus duodeni by atypical localisation of the papilla Vater. Fortschr. Geb. Roentgenstr. Nuklearmed 91: 609-12, 1959, (Ger).

Schulenberg, C.A.R.: Anomalies of the biliary tract as demonstrated by operative cholangiography. Medical Proceedings, 351-55, 1970.

Schwegler, R.A. Jr. and Boyden, E.A.: The development of the pars intestinalis of the common bile duct in the human fetus, with special reference to the origin of the ampulla of Vater and the sphincter of Oddi.

(I) The Involution of the Ampulla. Anat. Rec. 67: 441-67, 1936-37.

(II) Early Development of the Musculus Proprius. Anat. Rec. 68: 17-31, 1937a.

(III) The Composition of the Musculus Proprius. Anat. Rec. 68: 193-211, 1937b.

Swartley, W.B. and Weeder, S.D.: Choledochus cyst with double common bile duct. Annals of Surgery 101: 912-20, 1935.

Figure 1. Termination of the common bile duct into the duodenum as determined by operative cholangiography.

DUODENAL DIVISIONS:

1. Duodenal bulb
2. Descending duodenum
 - A. Normal: that part extending from the duodenal bulb to approximately 3 cm. distal to the midpoint.
 - B. Low: below the center portion, but above the angle between the descending and transverse duodenum.
3. Angle, the junction between the descending and transverse duodenum.
4. Transverse duodenum
5. Ascending duodenum

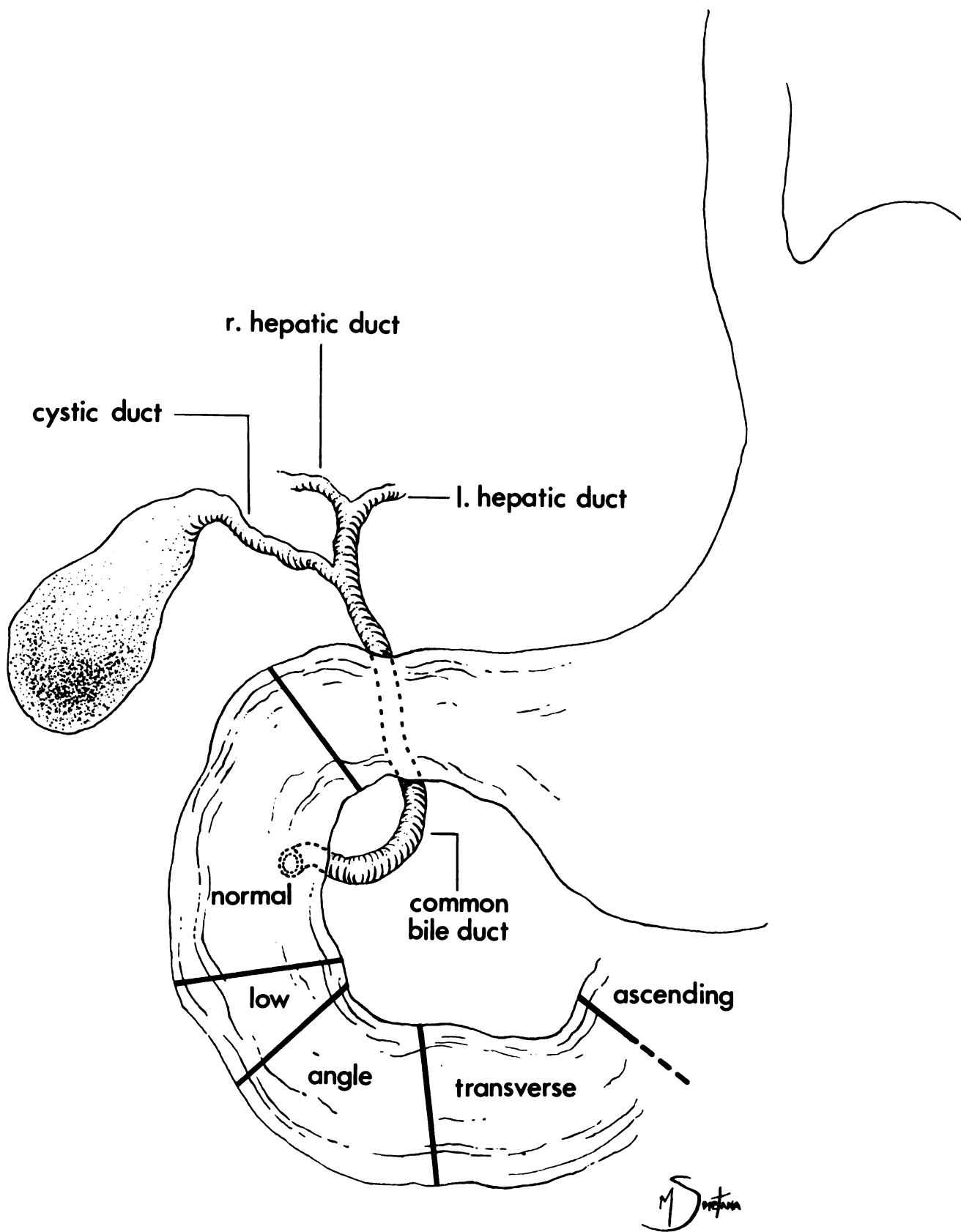


TABLE 1: Summary of Selective Literature

AUTHOR	INSTITUTION	NUMBER OF PATIENTS	% ANOMALIES	TYPE OF STUDY
Lurje, 1937	Moscow, U.S.S.R.	194	8.25	Cadaver Dissection
Dowdy <u>et al</u> , 1962	Hermann Hospital Houston, Texas	100	92 (Normal)	Autopsy Dissection
Schulenberg, 1970	Pretoria, South Africa	1093	5.6	Operative Cholangiograms
Keddie <u>et al</u> , 1974	Royal Infirmary Manchester, Eng.	120	23	Operative Cholangiograms

Table 2. Results: Distribution of the common bile duct terminations in 1000 operative cholangiograms.

	UCSF PATIENTS %	SFGH PATIENTS %	St. MARY'S PATIENTS %	LETTERMAN PATIENTS %	OAK KNOLL PATIENTS %	TOTAL PATIENTS	%
DESCENDING DUODENUM NORMAL	175 82.2%	153 76.5%	234 85.1%	168 78.1%	91 93.9%	821	82.1%
LOW	10 4.7%	17 8.5%	0 0	21 9.8%	0 0	48	4.8%
ANGLE	15 7.0%	22 11.0%	15 5.5%	15 7.0%	6 6.1%	73	7.3%
TRANSVERSE DUODENUM	13 6.1%	8 4.0%	26 9.4%	11 5.1%	0 0	58	5.8%

Plates I-II. Normal operative cholangiograms: the common bile duct terminates into the midportion of the posteromedial wall of the descending duodenum.

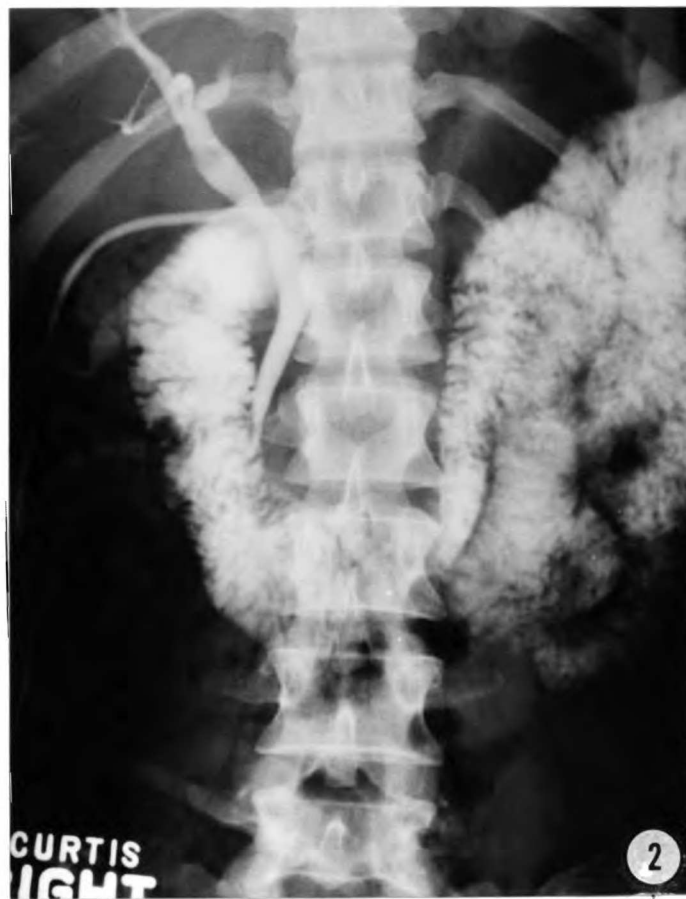
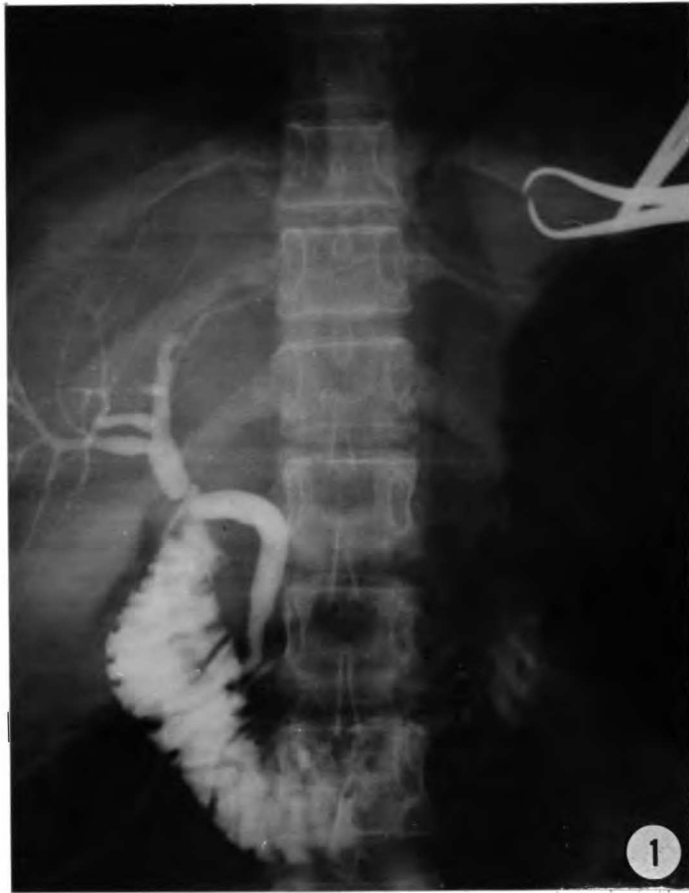
Plate III. A normal operative cholangiogram.
Notice the varying duodenal shapes and positions of the descending common bile duct in relation to the vertebral column throughout the series of photographs.

Plate IV. Normal entry of the common bile duct into the duodenum. The cholangiogram clearly marks the penetration of the common bile duct into the duodenal wall. This point is represented when the common bile duct, normally a bit dilated, suddenly constricts to half its size.

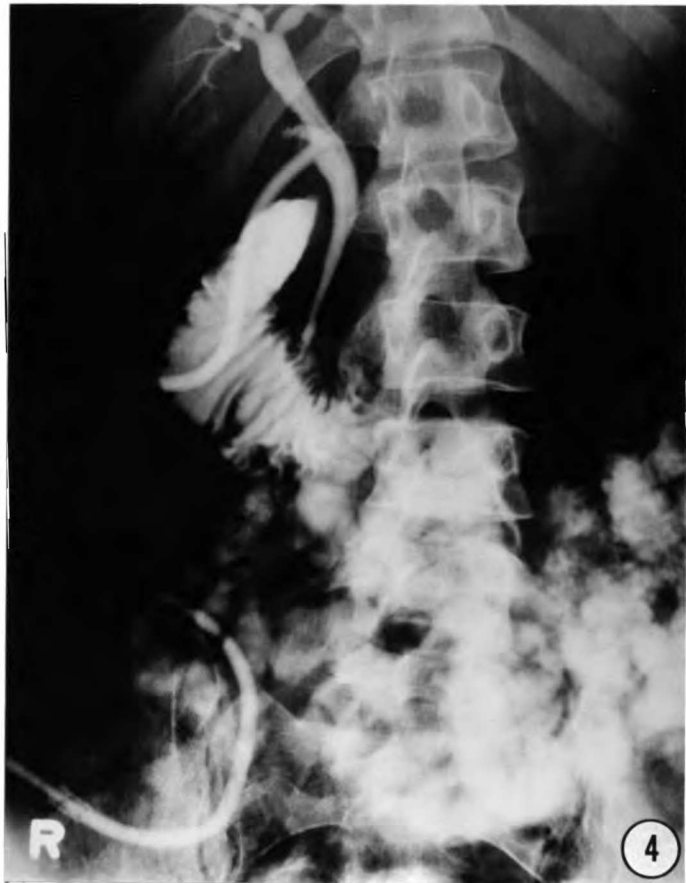
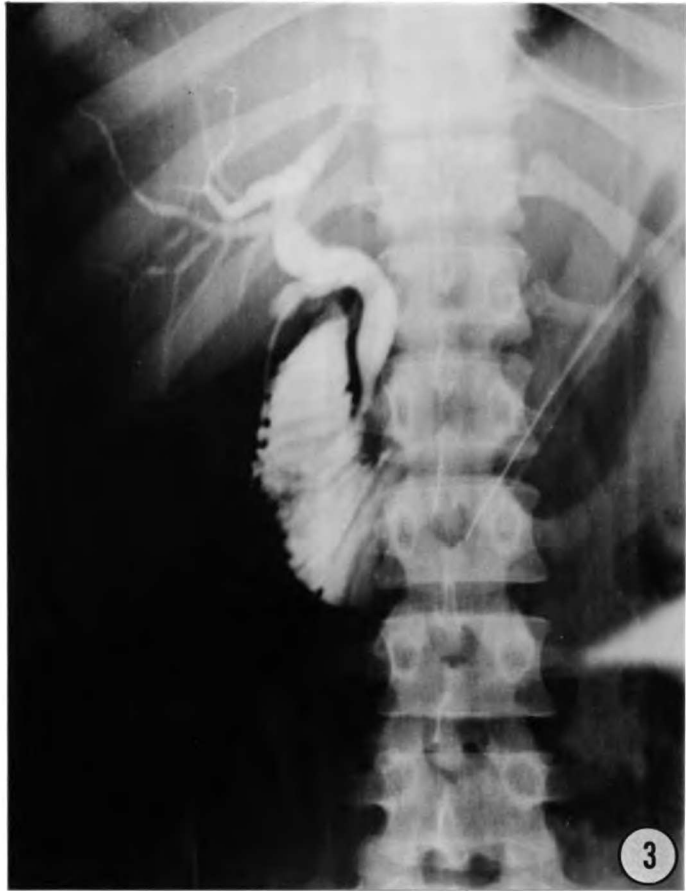
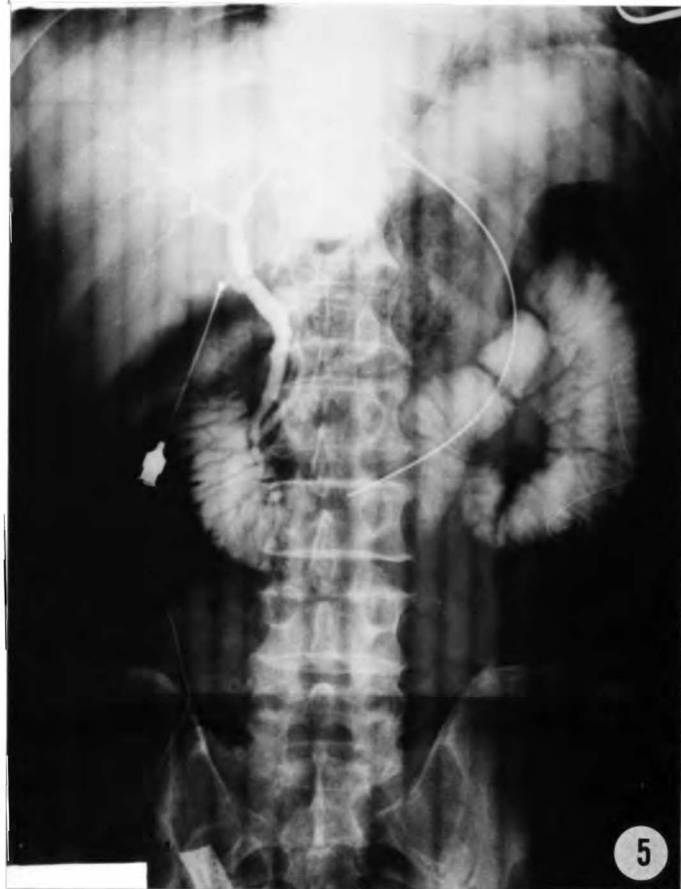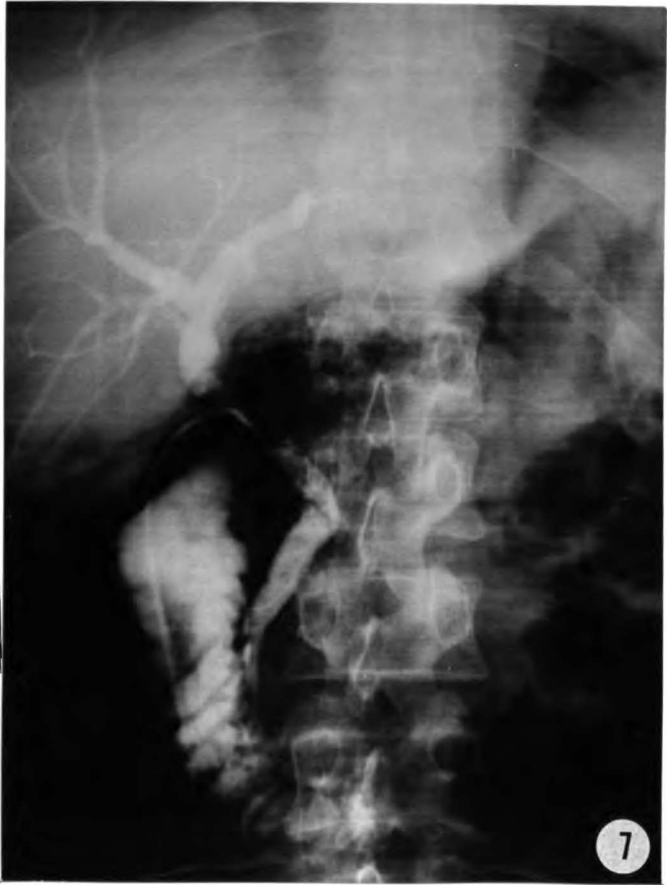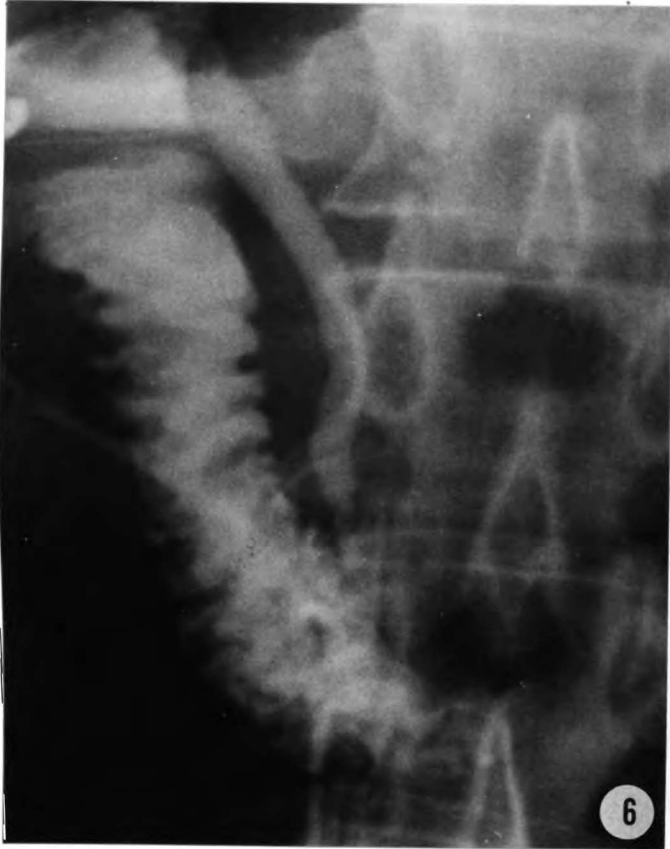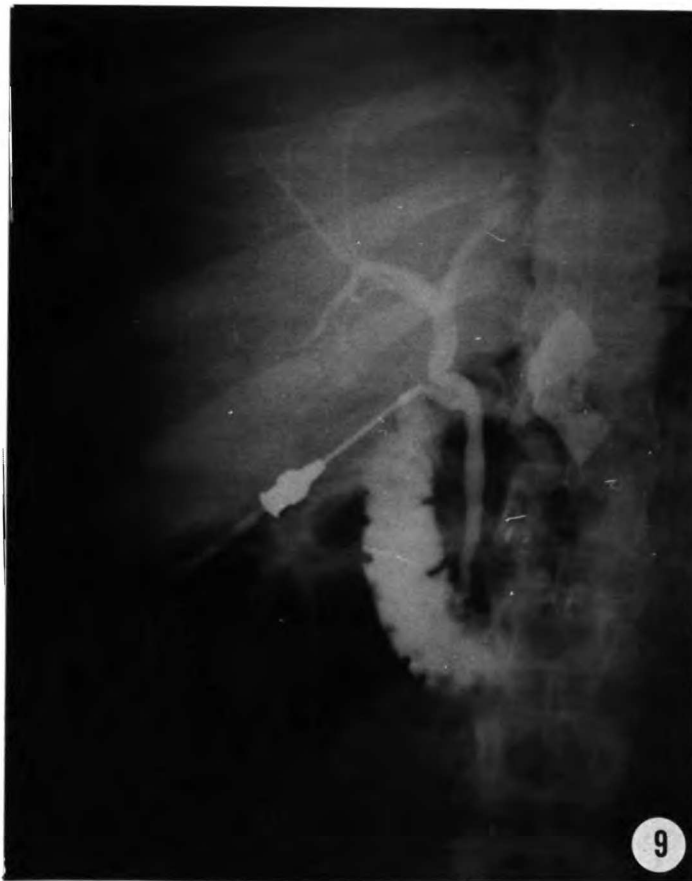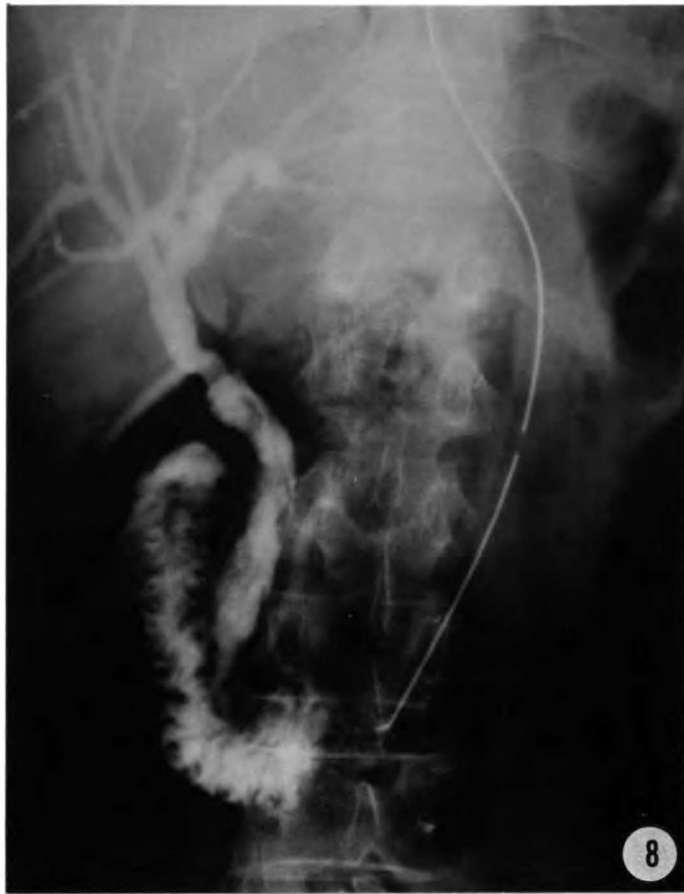Plate V. This normal cholangiogram allows the visualization of the common bile duct, and the major pancreatic duct; the latter via reflux of the injected dye. The ampulla of Vater, the common channel formed by the junction of the two structures can also be seen.



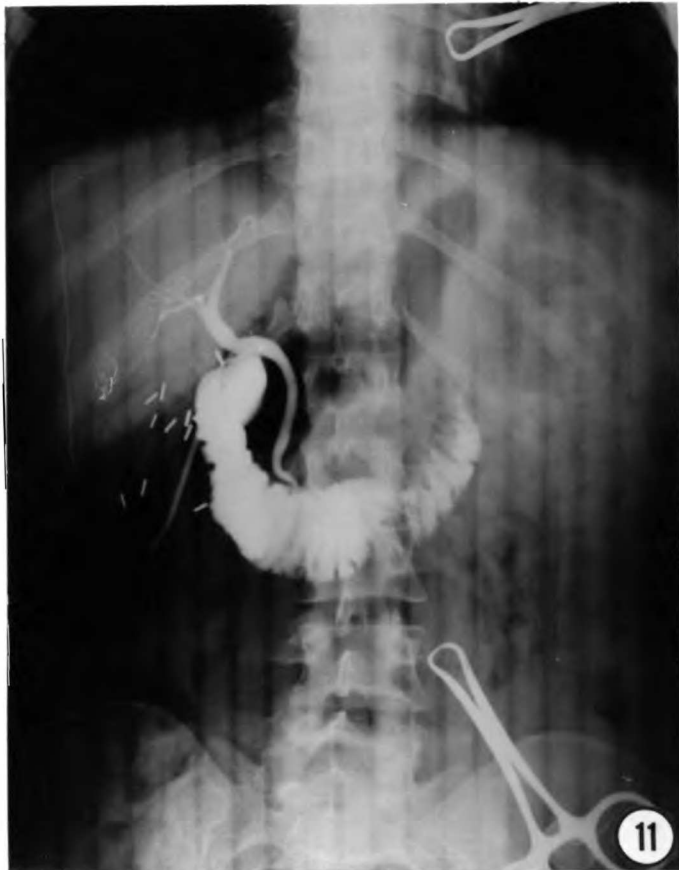
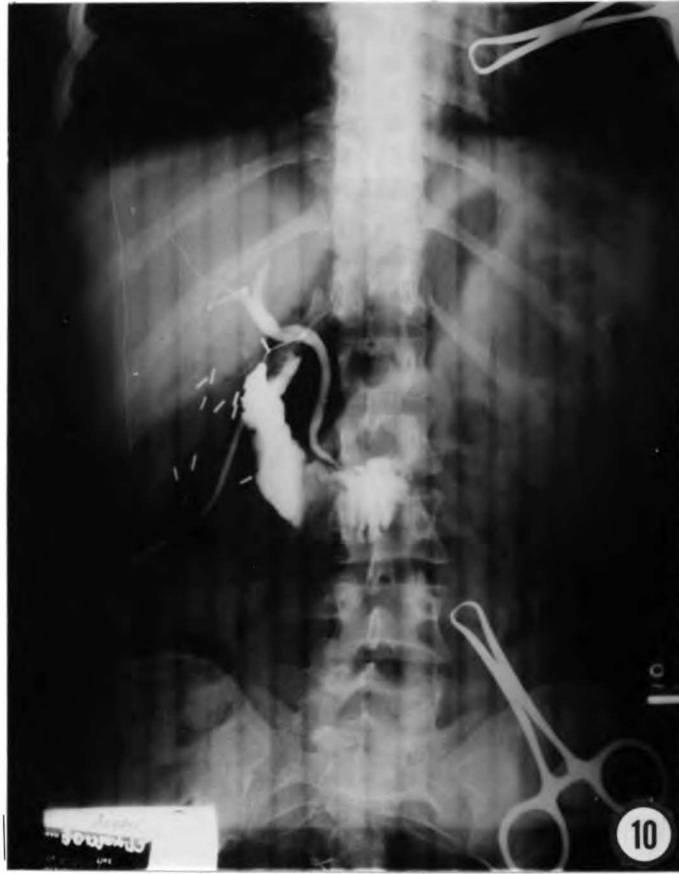Plates VI-VII. Two examples of patients whose common bile duct terminates in the portion of the descending duodenum designated as LOW. The common bile duct enters below the midportion of the duodenum and the transverse colon, but above the angle between the descending and transverse duodena.



Plates VIII-IX. The common bile duct in these two individuals terminates in the ANGLE: the junction between the descending and transverse duodena. Note the obvious longer lengths of the common bile ducts which enter anomalously.



Plates X-XI. Two operative cholangiograms of the same patient whose common bile duct terminates in the TRANSVERSE DUODENUM. Note the distinct drop inferiorly of the common bile duct and its position ventral to the vertebrae.



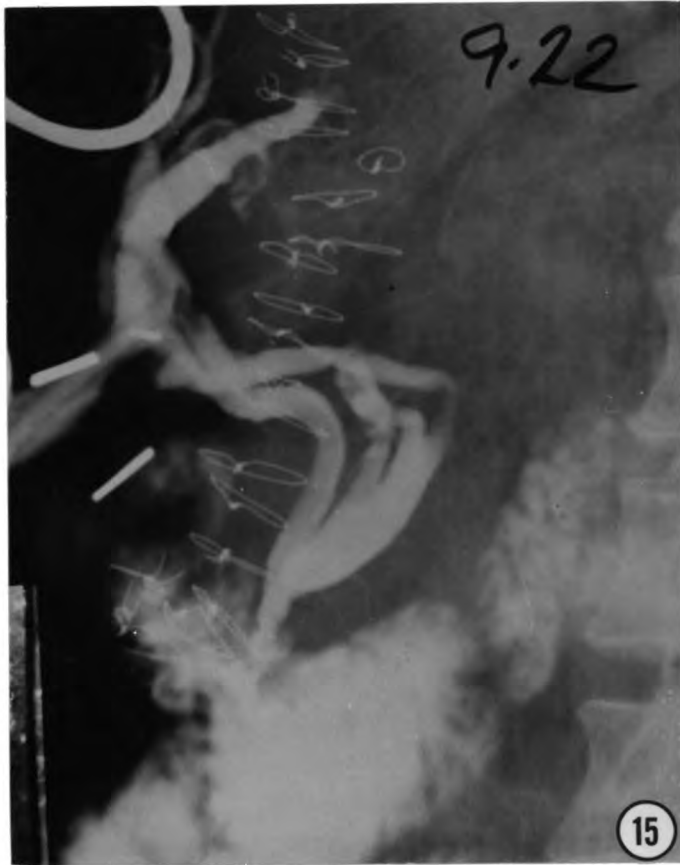
Plates XII-XIII. Two more operative cholangiograms from another patient that clearly show the common bile duct terminating in the TRANSVERSE DUODENUM.

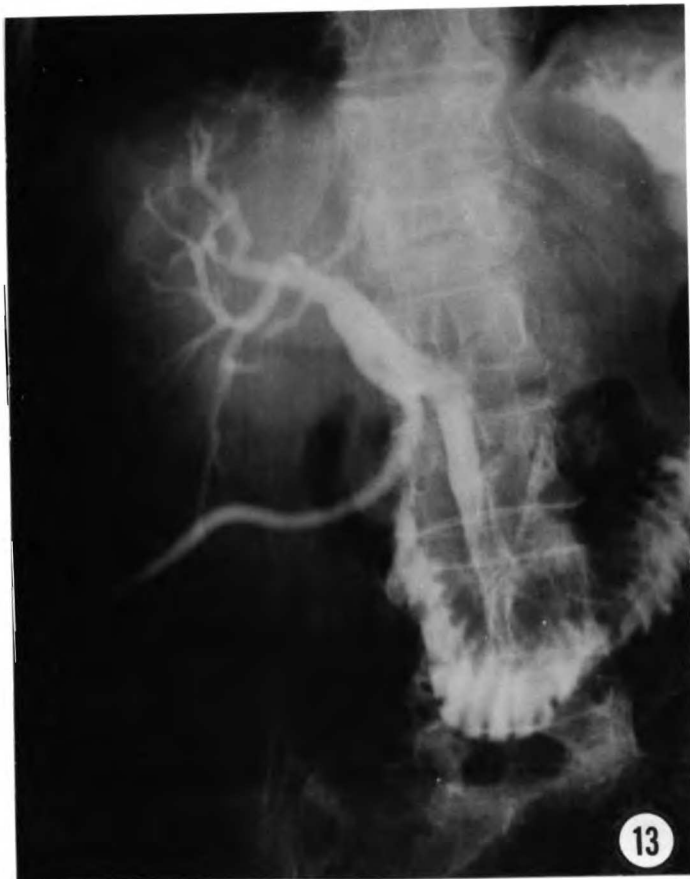
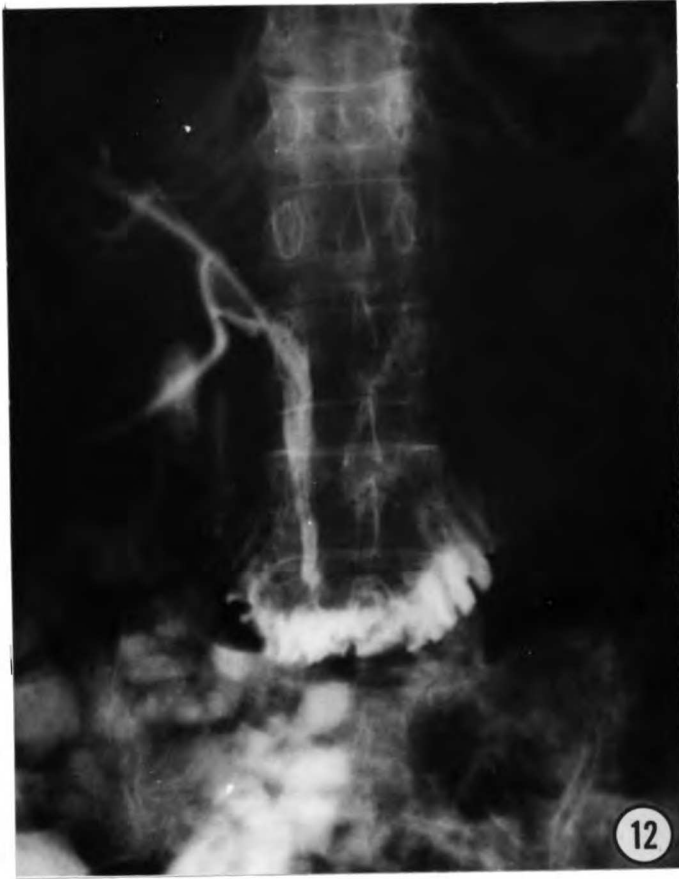
Plate XIV. A third example of the common bile duct
emptying into the TRANSVERSE DUODENUM.

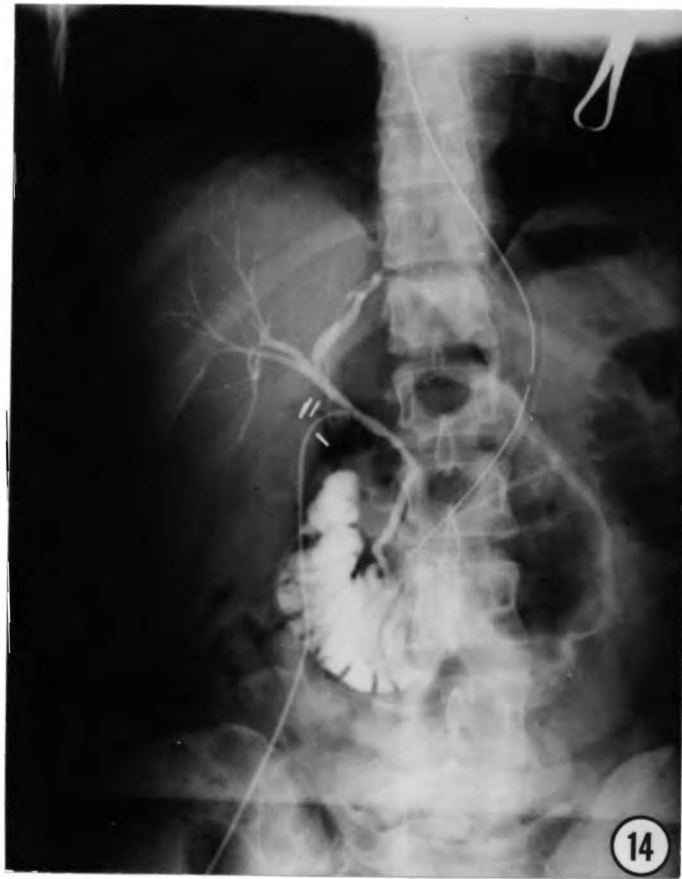

Plate XV. Unusual radiogram of a patient with three common bile ducts which rejoin and penetrate the duodenum as a single duct. Although not clearly seen here, the common bile duct does terminate in a normal manner.



Plates XVI-XVII. An example of an iatrogenic anomaly seen from two different angles. The common bile duct enters at the junction of the pylorus and duodenal bulb due to a choledochoduodenostomy.

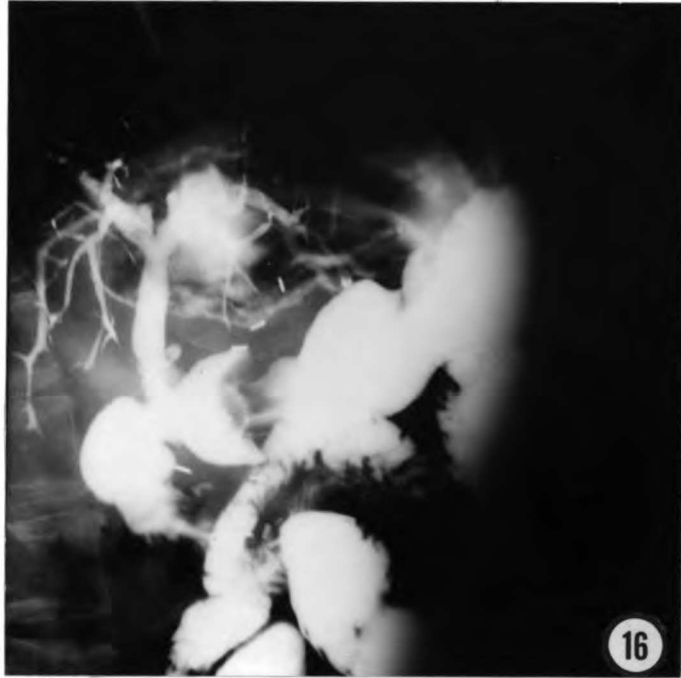
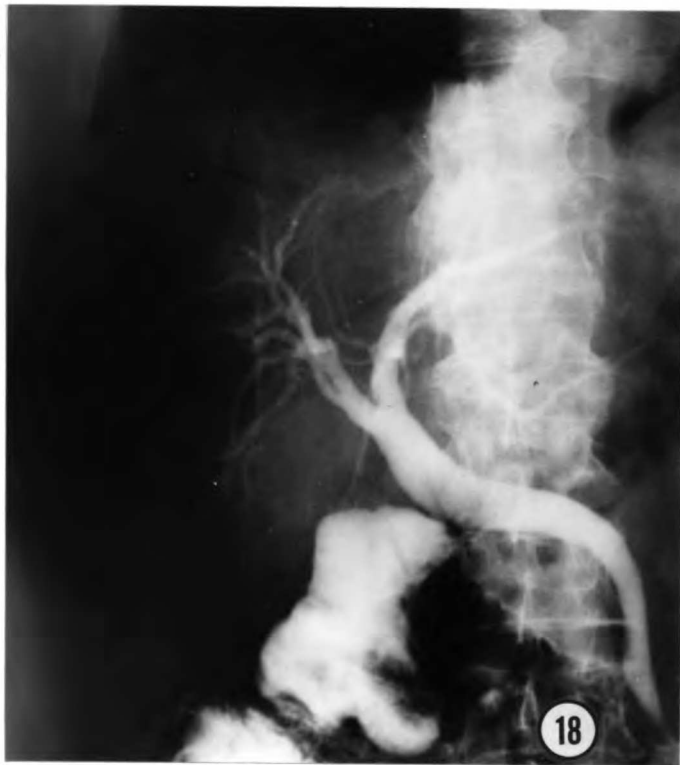
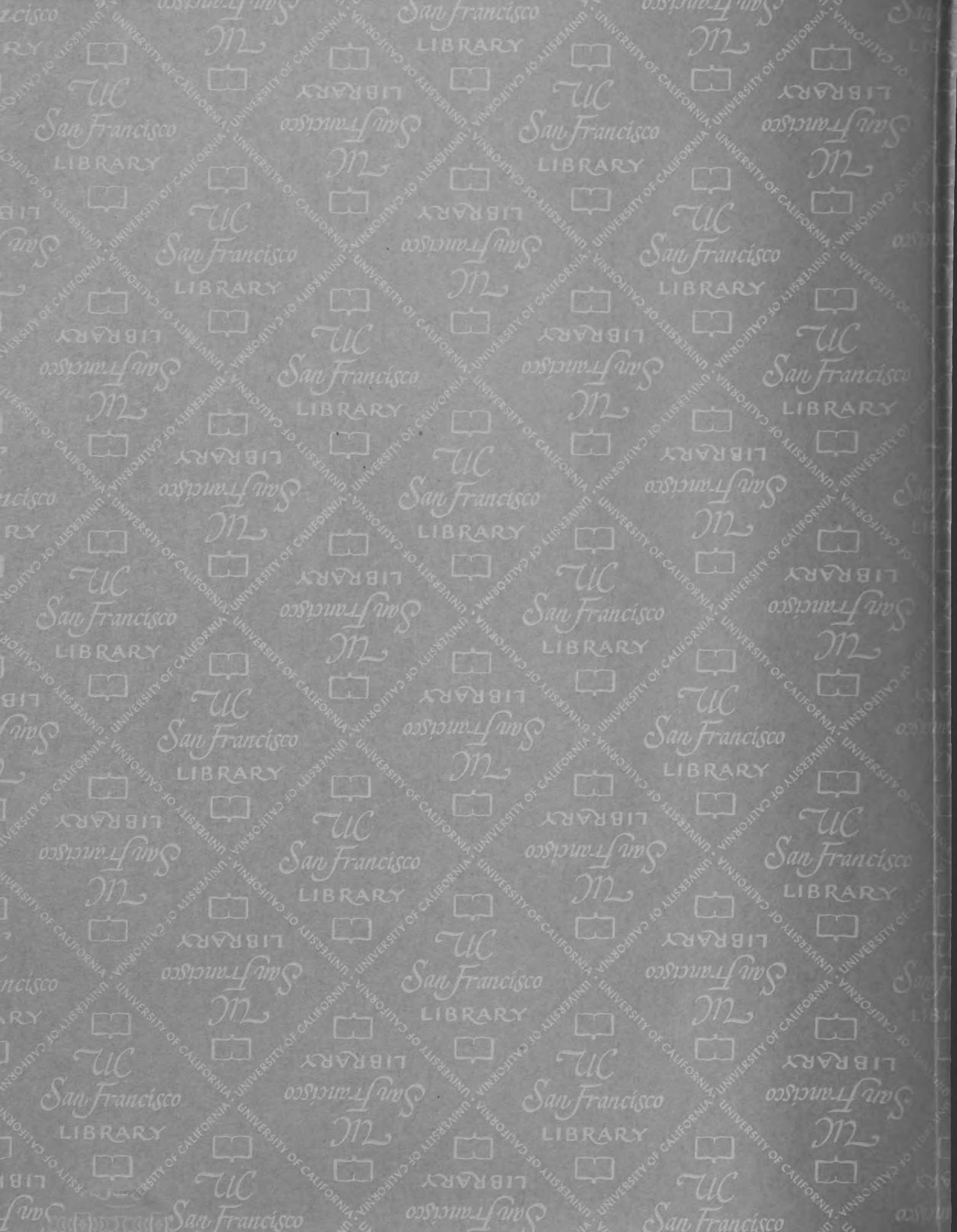Plate XVIII. An unusual view of the common bile duct traversing the vertebral column, and ending up on the left side of the vertebrae. This cholangiogram was the only one of its type in this patient's file, so no decision could be made as to where the common bile duct terminates.


For speculative purposes, we suspect that this site of entry could be in the transverse or ascending duodenum.





FOR REFERENCE

NOT TO BE TAKEN FROM THE ROOM

 CAT. NO. 23 012

PRINTED
IN
U.S.A.

