

# **UCLA**

## **Proceedings of UCLA Health**

### **Title**

Syrinx Formation Associated with Chiropractic Cervical Spinal Manipulation

### **Permalink**

<https://escholarship.org/uc/item/31z235rg>

### **Journal**

Proceedings of UCLA Health, 25(1)

### **Authors**

Bahk, Jason

Poquiz, Patrick

### **Publication Date**

2021-08-04

## CLINICAL VIGNETTE

# Syrinx Formation Associated with Chiropractic Cervical Spinal Manipulation

Jason Bahk, MA, MD and Patrick Poquiz, MD

A 39-year-old man with obesity presented to the emergency room with paresthesias of his distal left upper and lower extremities. His symptoms began two weeks before, after he visited a chiropractor for chronic neck pain. He requested neck manipulation treatment. Immediately after cervical manipulation maneuvers, he experienced rapid-onset bilateral involuntary tremors and unintentional movements of his upper extremities followed by intermittent painful numbness and tingling in the affected extremities.

Over the next several days, his neurological symptoms evolved, in addition to continued paresthesias of the left hand and left foot, he had onset of occipital headaches, brief and intermittent episodes of dysphagia, gait instability, and vertigo that prompted emergency department evaluation. Imaging included computed tomography (CT) head without contrast, and computed tomography angiogram (CTA) of the head and neck, which were negative and he was sent home with instructions to follow-up with his primary care provider. His symptoms persisted and his primary care provider obtained urgent magnetic resonance imaging (MRI) of his head and neck, with special attention to his cervical spine. This noted "cerebellar tonsillar herniation [...] with pointed appearance suggesting Chiari I change with a cystic focus within the upper cervical cord at the level of the C2 vertebral body and edema in the cord inferiorly. This may be a tonsillar herniation-related focal syrinx, however [...] Postcontrast study is recommended for further evaluation." This patient returned to the emergency department for admission given risk of tonsillar herniation.

On admission he was afebrile, with heart rate in the 80s, blood pressure of 134/90, and normal O<sub>2</sub> saturation. His physical exam was only significant for slightly decreased tactile sensation to light touch in the fingers and palm of his left hand, the toes and sole of his left foot, with mild sensory deficits to light touch in the left trigeminal, subsegments V1, V2, and V3 distribution of the cranial nerve examination. His gait was normal, with normal strength in his bilateral upper and lower extremities. He did not have any cervical spinal tenderness to palpation and had full extension and flexion of his neck.

Labs included normal complete blood count (CBC), comprehensive metabolic panel (CMP), (INR/PT), and hemoglobin A1C. Electrocardiogram (ECG) revealed normal sinus rhythm without any hypertrophy, arrhythmias, or ischemic findings. Repeat CTA of the head and neck was again normal, and repeat CT of the head without contrast found unchanged tonsillar

crowding at the foramen magnum. MRI of the brain and cervical spine with and without contrast, was "normal except for a Chiari I malformation with a syrinx in the upper cervical spinal cord measuring 8 x 4 x 9 mm, posterior spinal cord syrinx at the level of C2, and low-lying and pointing cerebellar tonsils below the foramen magnum to the lower C1 level that is consistent with a Chiari I malformation."

Neurology assisted with assessment and management. Frequent neurologic checks were stable. Physical and occupational therapy assessments identified no rehabilitative needs. Surgical intervention was not recommended given the location and risk for complications. With neurologic stability and no evidence of syrinx progression he was discharged home with close neuro and PCP follow-up. He was strongly recommended against further cervical spinal manipulation.

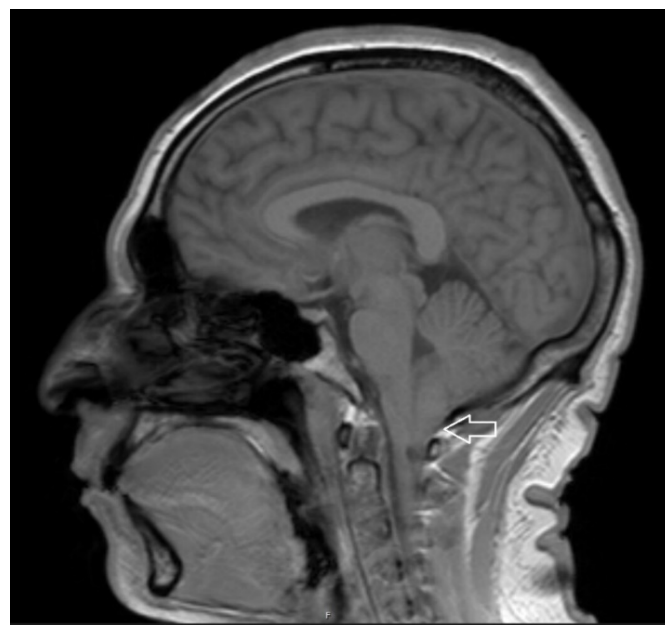

Figure 1. MR brain T1-weighted sagittal view identifying the cerebellar tonsillar herniation/low-lying pointing cerebellar tonsils below the foramen magnum that is typically seen in Chiari I malformations.

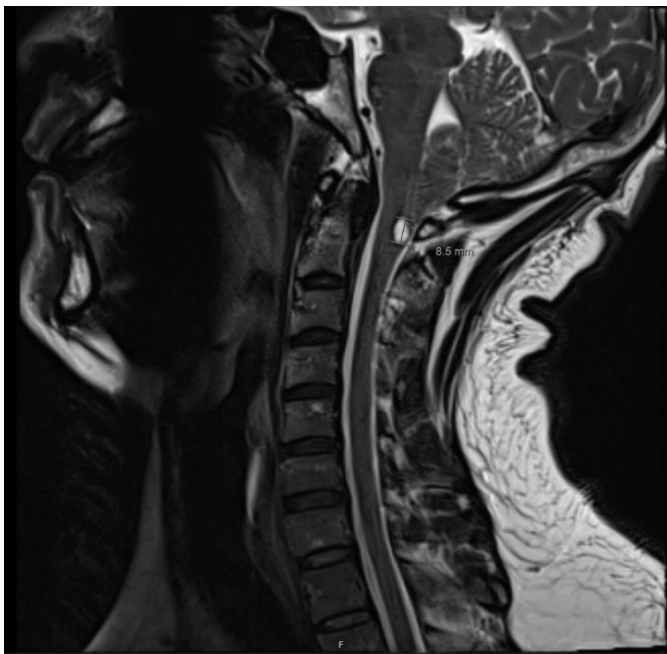


Figure 2. MR C-spine T2-weighted sagittal view measuring rostral-caudal dimension of the posterior cervical cord syrinx at approximately 9 mm. The pointing cerebellar tonsils for Chiari I malformation can also be appreciated here.

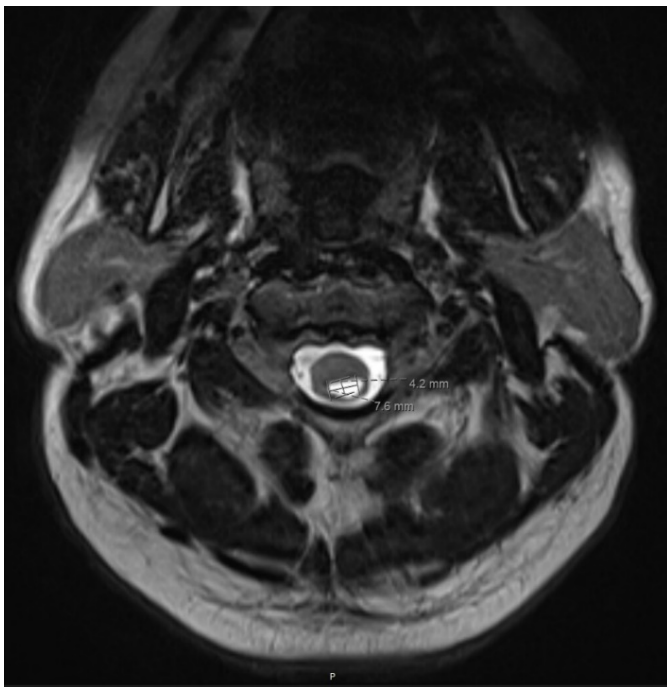


Figure 3. MR C spine T2-weighted axial view of the posterior cervical syrinx measured at approximately 4 x 8 mm.

### Discussion

We reviewed the literature on traumatic complications from spinal manipulation therapy (SMT) and syrinx formation, and

found no prior reports of syrinx formation in the upper cervical spinal cord in an otherwise healthy young male.

Currently, chiropractic neck manipulation in the United States includes high velocity dynamic manipulations for chronic musculoskeletal neck pain and headache relief.<sup>1</sup> Spinal manipulation is defined as “high-velocity, low-amplitude manual thrusts to spinal joints that extend slightly beyond their physiological range of motion.”<sup>2</sup> Chiropractic cervical spine manipulation is now more common and increasingly in use in the United States. While seemingly rare, complications are likely underreported, with the most common being transient ischemic attack and/or cerebrovascular disease as a result of rapid thrusting and application of torque. There are few, randomized controlled trials examining cervical spinal manipulation for the treatment of chronic musculoskeletal neck pain.

Other complications include, vertebral artery dissection, vertebral and internal carotid artery dissection, epidural hematoma, intracranial aneurysm, cauda equina syndrome, spinal cord contusion, and myelopathy.<sup>3</sup> Very rare complications include tonsillar herniation and death.<sup>4</sup> This review of cases reported twenty-six fatalities since 1934. The vast majority of deaths were from cerebral, vascular accidents including thrombosis of the basilar artery, and dissection of vertebral arteries.<sup>4</sup>

This case series, found 11 out of 26 deaths in 30-year-olds, which is likely an under estimate of true mortality and morbidity related to chiropractic cervical spine manipulation. In another case review involving overwhelmingly young patients. The most common problems were vertebral artery dissection, followed by nerve injuries, disc herniations, and hematoma formation with osseous fractures which were often transiently life-threatening.<sup>4</sup>

Thromboembolic disease is one of the most common complications of chiropractic manipulation and is often coincidental. Thromboembolic disease as a result of plaque rupture, thromboembolic nidus formation and/or propagation of thromboembolic material as a result of chiropractic manipulation. The patients may have had thromboembolic cerebrovascular accidents regardless of manipulation. However, a study at two major academic medical centers found an increased risk of thromboembolic stroke and TIAs with a statically significant association with recent cervical spinal manipulation.<sup>3,5</sup>

Another reported a 44-year-old man with ankylosing spondylitis who became quadriplegic with complications after fracture of his C3 and C4 vertebrae. They reported multiple cases of severe spinal injury prior to the modern PubMed indexing, including severe spinal cord complications following SMT. These included T1 paraplegia, death from acute epidural and subarachnoid hemorrhage at the C1-C3 level, cauda equina syndrome after lumbar disc disease, paraplegia in a patient with Paget’s disease, T8 paraplegia in a patient with multiple myeloma, and a 9-year-old child who suffered reversible long-

tract signs following an attempted manipulation of her congenitally-occipitalized atlas.<sup>6</sup>

A retrospective cohort study by chiropractic physicians examined SMT traumatic complications in Medicare Part B beneficiaries. They compared cumulative probability of injury with SMT compared to allopathic musculoskeletal pain treatment. Allopathic treatment had 40 incidents per 100,000 subjects compared to 153 incidents per 100,000 subjects with SMT. The majority of injuries in the chiropractic SMT arm were associated with chronic coagulopathies, inflammatory spondylopathy, osteoporosis, vascular trauma, or anti-coagulation therapy.<sup>5</sup> This single retrospective cohort study may not represent the true safety profile of SMT therapy for neck pain and headache and suggests the need for additional prospective studies and randomized controlled trials with adequate power to detect both serious and less severe complications.

A higher quality case-controlled study with 151 subjects found, manipulation to be an independent risk factor for vertebral artery dissection, and showed that the relative risk of cervical arterial dissection after manipulation was much higher 14% compared to the placebo group 3%, with an almost five-fold increase in complication rates ( $p = 0.032$ ).<sup>6</sup> Patients who were concurrent users of alcohol had a higher risk than patients who did not use alcohol.

Chiropractic manipulation is often perceived as a safe, complementary and alternative medical treatment to deal with musculoskeletal neck, thoracic, and lumbar pain. Complications are reported by the practitioners themselves, but patients with complications tend to not return to their practitioner and complications of chiropractic manipulation may be under-recognized by allopathic physicians. Only a small number of prospective studies have been published, lacking statistical power to accurately determine the frequency of complications.<sup>2</sup> More appropriately-powered statistical studies are necessary.

During our review of the literature, we were unable to find higher level syrinx formation resulting from SMT. This raises concerns about the rates of syrinx formation in patients receiving SMT. Our patient had syrinx formation after a traumatic C-spine manipulation. Further study is needed to determine the efficacy and safety of higher-level spinal manipulation and any patient factors that increase risk of traumatic spinal cord damage.

## REFERENCES

1. **Whedon JM, Mackenzie TA, Phillips RB, Lurie JD.** Risk of traumatic injury associated with chiropractic spinal manipulation in Medicare Part B beneficiaries aged 66 to 99 years. *Spine* (Phila Pa 1976). 2015 Feb 15;40(4):264-70. doi: 10.1097/BRS.0000000000000725. PMID: 25494315; PMCID: PMC4326543.

2. **Ernst E.** Life-threatening complications of spinal manipulation. *Stroke*. 2001 Mar;32(3):809-10. doi: 10.1161/01.str.32.3.809. PMID: 11239206.
3. **Williams LS, Biller J.** Vertebrobasilar dissection and cervical spine manipulation A complex pain in the neck. *Neurology*. 2003 May 13;60(9):1408-9. doi: 10.1212/wnl.60.9.1408. PMID: 12743220.
4. **Ernst E.** Adverse effects of spinal manipulation: a systematic review. *J R Soc Med*. 2007 Jul;100(7):330-8. doi: 10.1177/014107680710000716. PMID: 17606755; PMCID: PMC1905885.
5. **O'Brien J.** Chiropractic Treatment of the Neck Can Be a Risk Factor for Stroke. *Ucsf.Edu*, 14 May 2003, www.ucsf.edu/news/2003/05/4635/chiropractic-treatment-neck-can-be-risk-factor-stroke.
6. **Smith WS, Johnston SC, Skalabrin EJ, Weaver M, Azari P, Albers GW, Gress DR.** Spinal manipulative therapy is an independent risk factor for vertebral artery dissection. *Neurology*. 2003 May 13;60(9):1424-8. doi: 10.1212/01.wnl.0000063305.61050.e6. PMID: 12743225.