

UC Davis

Dermatology Online Journal

Title

Staphylococcus lugdunensis cutaneous infection with sporotrichoid distribution

Permalink

<https://escholarship.org/uc/item/31q811w4>

Journal

Dermatology Online Journal, 23(8)

Authors

di Meo, Nicola
Trevisini, Sara
Noal, Cecilia
et al.

Publication Date

2017

DOI

10.5070/D3238036015

Copyright Information

Copyright 2017 by the author(s). This work is made available under the terms of a Creative Commons Attribution-NonCommercial-NoDerivatives License, available at <https://creativecommons.org/licenses/by-nc-nd/4.0/>

Peer reviewed

Staphylococcus lugdunensis cutaneous infection with sporotrichoid distribution

Nicola di Meo, Sara Trevisini, Cecilia Noal, Katuscia Nan, Giusto Trevisan

Affiliations: Department of Dermatology and Venereology, University of Trieste, Trieste, Italy

Corresponding Author: Sara Trevisini, Clinica Dermatologica Ospedale Maggiore di Trieste, IV Piano Palazzina Infettivi, 34129 Piazza Ospedale 1, Trieste, Italy, Email: saratrevisini@hotmail.com

Abstract

We report the occurrence of *Staphylococcus lugdunensis* cutaneous infection with sporotrichoid distribution of the left lower limb of a 60-year-old man. Recent studies have confirmed that *Staphylococcus lugdunensis* is a significant pathogen in causing skin and soft tissue infections that usually manifest in abscesses, surgical wound infections, and cellulitis. It used to be considered a skin commensal microbe, but if unrecognized it can lead to fulminant endocarditis, meningitis, skin abscesses, peritonitis, and spondylodiscitis.

Keywords: *staphylococcus*, *lugdunensis*, *infection*, *sporotrichoid*

Introduction

Staphylococcus lugdunensis (*S. lugdunensis*) is a coagulase-negative staphylococci first described by Freney and his colleagues in 1988 [1]. The organism is found as a skin commensal in healthy individuals, although it has been implicated in invasive diseases, especially fulminant native, prosthetic-valve endocarditis [2], brain abscess, meningitis, soft tissue infections, spondylodiscitis, foreign body infections, and peritonitis [3]. *S. lugdunensis* has been largely unreported in the dermatology literature, even though the skin has been consistently demonstrated to be the most common site of clinically significant infection [4]. Sporotrichoid distribution of skin lesions (also called nodular lymphangitis) can be caused by many fungal and bacterial infections. We report a case of *S. lugdunensis* cutaneous infection with this particular clinical presentation.

Case Synopsis

A 60-year-old man presented with multiple mildly painful purple nodules and ulcers over the left lower limb in a linear pattern, with a duration of 2 months. The patient was not able to recollect any history of trauma to his foot. The patient described that the lesions had first started on his left elbow as a small single nodule that gradually spread to involve the left leg in a sporotrichoid pattern. Only the first nodule had ruptured, discharged a small amount of pus, and formed an ulcer. Cutaneous examination revealed some edema, with multiple hard nodules on the left leg with surrounding normal to light erythematous and tender skin (**Figure 1**). Lymph node examination revealed enlargement of left femoral lymph nodes. Oral temperature was 36.6°C, heart rate was 75 beats/min, and blood pressure was 130/85 mmHg. Heart, lung, and abdominal examination were unremarkable. The patient was not taking any medication. Clinical differential

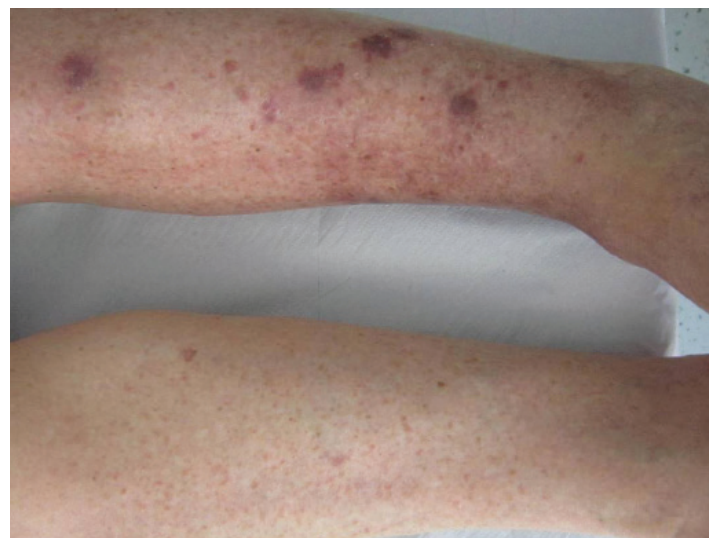


Figure 1. Cutaneous nodules of the patient's left lower limb spread in a sporotrichoid pattern.

diagnosis of skin infections with sporotrichoid distribution includes *Mycobacterium marinum* infection, atypical mycobacteriosis, *Sporothrix schenckii* infection, nocardiosis, leishmaniasis, tularemia, and other bacterial and fungal infections. Therefore, we collected pus from the ulcerated lesion and performed deep tissues biopsies from 4 different nodules for microbiological cultures and histological examination. Laboratory investigations revealed normal red and white blood cell count and liver and renal function tests. The patient was not diabetic. Serology for human immunodeficiency virus, hepatitis C virus, hepatitis B, and syphilis were nonreactive. X-ray of the chest was normal with a negative Quantiferon gold. No abnormalities were detected in the x-ray of left foot except soft tissue swelling.

The histological examination revealed an acute inflammation infiltration involving sweat glands with epithelial proliferation. Periodic acid Schiff and human herpes virus-8 stains were negative. Culture and sensitivities from all the tissue samples collected demonstrated a pure growth of a *S.lugdunensis*, with subsequent laboratory-initiated speciation performed by broad-range polymerase chain reaction enabling its identification (**Figure 2**). The bacterium was methicillin-resistant but was susceptible to vancomycin. Excellent results were observed within 5 days of therapy with intravenous vancomycin, 1 g twice daily. The patient underwent 10 days of treatment with no recurrence.

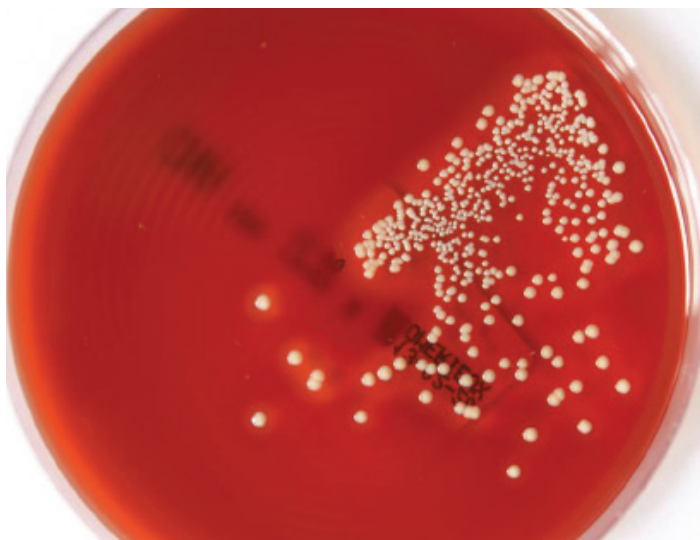

Figure 2. *Staphylococcus lugdunensis* cultured from the sample of one of the cutaneous lesions.

Case Discussion

Nodular lymphangitis describes a characteristic clinical presentation in which erythematous papules and nodules are located along the site of lymphatic drainage. Clinical clues, history, and a focused diagnostic workup can usually lead to a rapid and accurate diagnosis. The presence of nodular lymphangitis suggests a limited differential diagnosis, including cutaneous inoculation with *Mycobacterium marinum* [5], *Sporothrix schenckii* and other fungi, *Leishmania braziliensis*, *Nocardia brasiliensis*, *Francisella tularensis*, and various pyogenic bacteria. As a result, the majority begin from a previous episode of trauma. Systemic complaints are infrequent in nodular lymphangitis. Infections tend to congregate around regional lymphatics without deep penetration or spread to distant areas. *S. lugdunensis* is a coagulase-negative Staphylococcus, part of the normal human skin flora. *S. lugdunensis* shares a number of potential virulence factors with *S. aureus* and it can lead to severe endocarditis, bacteremia, and infections of the skin, eye, oral cavity, central nervous system, bone, joints, and urinary tract. It express a clumping factor, produces thermostable DNase, and a tannase [6]. Definite phenotypic identification of a Gram-positive, catalase-positive coccus as *S. lugdunensis* implies a negative tube coagulase test and positive ornithine decarboxylase activities. However, complete hemolysis, yellow pigmentation, and detection of a fibrinogen affinity factor, although not consistently expressed by *S. lugdunensis*, may lead to its misidentification as *S. aureus* [7].

The increasing recognition of *S. lugdunensis* as a skin community and nosocomial-acquired pathogen highlights the need for dermatologists to be aware of the correct interpretation of the culture. Although *S. lugdunensis* is generally considered to be susceptible to oxacillin, worldwide methicillin resistant *S. lugdunensis* (MRSL) have been increasingly documented [7]. We report this case that, to our knowledge, is the first cutaneous infection of MRSL with sporotrichoid distribution reported in literature and it should be considered in the differential diagnosis of this clinical presentation.

References

1. Freney J, Brun Y, Bes M, Meugnier H, Grimont F, Grimont PAD,

- Nervi C, Fleurette J. *Staphylococcus lugdunensis* sp. nov. and *Staphylococcus schleiferi* sp. nov., two species from human clinical specimens. *Int. J. Syst. Bacteriol.* 1988;38: 168– 72. doi: 10.1099/00207713-38-2-168.
2. Jones RM, Jackson MA, Ong C, Lofland GK. Endocarditis caused by *Staphylococcus lugdunensis*. *Pediatr Infect Dis J.* 2002 Mar;21(3):265-8. [PMID: 12005099].
 3. Kaabia N, Scauarda D, Lena G, Drancourt M. Molecular identification of *Staphylococcus lugdunensis* in a patient with meningitis. *J Clin Microbiol.* 2002 May;40(5):1824-5. [PMID: 11980968].
 4. Donoghue S, Vekic D, Wehrhahn M, Whitfeld M. *Staphylococcus lugdunensis*: case report and discussion. *Australas J Dermatol.* 2014 Nov;55(4):301-3. [PMID: 25399790].
 5. di Meo N, Stinco G, Trevisini S, De Marchi S, Albano A, Trevisan G. Sporotrichoid *Mycobacterium marinum* infection in an elderly woman. *Dermatol Online J.* 2015 May 18;21(5). [PMID: 26295859].
 6. Giordano CN, Kalb RE, Brass C, Lin L, Helm TN. Nodular lymphangitis: Report of a case with presentation of a diagnostic paradigm. *Dermatol Online J.* 2010 Sept 15;16(9):1. [PMID: 20875322].
 7. Al-Charrakh AH, Obayes MH. First Record of Isolation and Characterization of Methicillin Resistant *Staphylococcus lugdunensis* from Clinical Samples in Iraq. *Biomed Res Int.* 2014;2014:736259. [PMID: 25126573].