

UCLA

Proceedings of UCLA Health

Title

Solid Pseudopapillary Tumor of the Pancreas in a 30-Year-Old Male Patient

Permalink

<https://escholarship.org/uc/item/31j5j6b9>

Journal

Proceedings of UCLA Health, 26(1)

Authors

Flynn, Spencer

Kerbel, Russell

Publication Date

2022-08-16

CLINICAL VIGNETTE

Solid Pseudopapillary Tumor of the Pancreas in a 30-Year-Old Male Patient

Spencer Flynn, BA¹ and Russell Kerbel, MD²

¹Medical Student, David Geffen School of Medicine at UCLA, Los Angeles, California

²Associate Clinical Professor of Medicine, David Geffen School of Medicine at UCLA, Los Angeles, California

Introduction

Solid pseudopapillary neoplasms (SPN) of the pancreas make up 2-3% of all pancreatic tumors, although incidence is increasing with widespread use of cross-sectional imaging and increased awareness of these tumors.^{1,2} They are low-grade malignant tumors with a generally favorable prognosis.³⁻⁵ SPNs have had many names in the past, including Frantz's tumor, solid and papillary tumor, solid-cystic tumor, papillary cystic tumor, and solid and papillary epithelial neoplasm.⁶ Solid pseudopapillary tumors occur primarily in young women in their 20s and 30s, with only 10% occurring in men.⁷ Most solid pseudopapillary tumors are asymptomatic, although they can also present with nausea, vomiting, abdominal pain, and symptoms of obstruction.⁶ Typically, there are no abnormalities on laboratory testing, including no evidence of pancreatic insufficiency, normal liver function tests, intact endocrine axes, and no tumor markers in serum or plasma.¹ SPNs most commonly arise in the tail of the pancreas.^{7,8} We describe a case of a solid pseudopapillary tumor of the pancreas. We present a 30-year-old male with pseudopapillary tumor of the pancreas. He presented with nausea, vomiting, diarrhea, and diffuse abdominal pain. With history of opioid use in recovery.

Case Report

A 30-year-old male presented with a 5-month history of worsening, intermittent, generalized abdominal pain associated with nausea, vomiting, and diarrhea. He had lost 40 pounds over this period with decreased appetite. For the 5 days preceding presentation he was unable to keep down food, experiencing 4-5 daily episodes of non-bloody, occasionally bilious vomiting. He alternated between diarrhea and the urge to defecate without being able to do so. He had sweating and chills, but denied fever, chest pain, shortness of breath, flushing, leg swelling, or any genitourinary complaints. Past medical history was significant for anxiety, hypertension, and opioid use disorder, now in recovery. Eleven years prior to presentation, he traveled to India and contracted amoebic dysentery with severe diarrhea and fever treated with antibiotics and steroids in the hospital. His previous surgical history was significant for tonsillectomy and wisdom teeth extraction. Medications prior to hospital admission were amphetamine-dextroamphetamine, clonazepam, and self-medication with kratom to prevent opioid withdrawal. He had no known drug allergies. He did not drink

alcohol and used marijuana recreationally but had never used tobacco. His mother had medullary thyroid cancer and type 2 diabetes mellitus and his father had diverticulitis, hypertension, and hyperlipidemia.

Vitals at presentation were temperature 36.2 C, blood pressure 126/70, heart rate 55, respiratory rate 17, oxygen saturation of 98%, and a BMI of 37.0. Physical exam was significant for hypoactive BS and moderate diffuse abdominal tenderness to palpation. Initial laboratory studies were notable for K 3.3, Cr 1.5 (eGFR 61), hemoglobin 13.2. Otherwise, basic metabolic panel and complete blood count were within normal limits. Glucose was 82 mg/dl. Treatment was initiated with ondansetron, IV fluids, sulfamethoxazole-trimethoprim, acetaminophen, and clonazepam.

Contrast CT scan of the abdomen (Figure 1) revealed an atrophic pancreas with a well circumscribed, 19 x20 mm uncinete mass lesion concerning for neuroendocrine tumor, with surrounding small nodules up to 8 mm in diameter. There were subcentimeter lymph nodes in the mesentery and right lower quadrant.

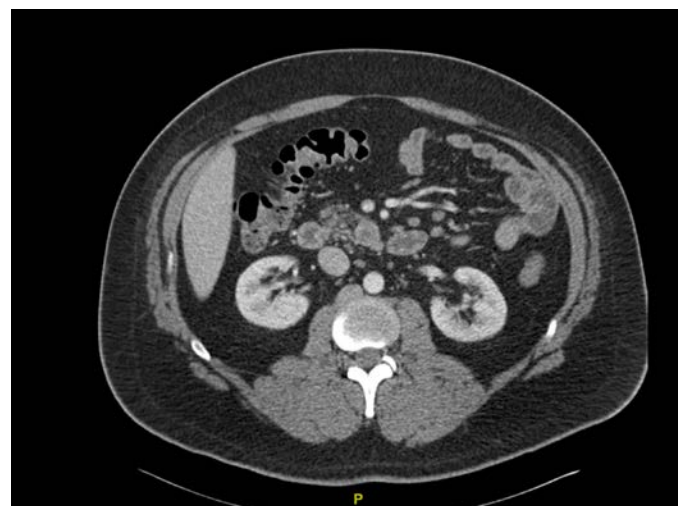


Figure 1

The patient was admitted to medicine services with endocrinology and interventional gastroenterology consultations.

Endocrine labs were significant for low 25 hydroxy vitamin D at 8 ng/mL, high PTH at 92 pg/mL, high glucagon at 65 pg/mL, and low LH, FSH, and free testosterone at 1.7 IU/L, 1.1 IU/L, and 282 ng/dL, respectively. There were normal values of C-peptide, insulin, chromogranin, CEA, CA 19-9, lipase, AM cortisol and ACTH, prolactin, full thyroid panel, thyroid peroxidase antibody, anti-thyroglobulin antibody, gastrin, GGT, lactate dehydrogenase, calcitonin, procalcitonin, VIP, normetanephrine, metanephrine, urine VMA, HVA, urinary catecholamines, IGF-I, urine and plasma 5-HIAA, somatostatin, neuron-specific enolase, substance P, aldosterone, sex hormone binding globulin, and estradiol. He also had an elevated prothrombin time to 15.5 seconds, with INR of 1.3. Hepatic chemistries were normal except for a low ALT at 7.

An upper gastrointestinal endoscopy with fine needle aspiration and biopsy of the tumor and lymph nodes was performed. Cellular smears from the core biopsy of the mass found atypical cells singly or in papillary aggregates, with the cells demonstrating eccentric nuclei, irregular nuclear contours, granular chromatin, and delicate cytoplasm. Tissue staining for CAM5.2 was positive, Sox11 was positive with nuclear staining, and synaptophysin was positive in scattered cells. Chromogranin was negative and beta catenin was negative except for nuclear staining. Overall findings were most consistent with pseudopapillary neoplasm of the uncinata process of the pancreas. Biopsy of lymph nodes did not find any malignant cells. There were fragments of two gastric polyps on biopsy with no other noteworthy gastric abnormalities.

The patient was discharged on cholecalciferol, ergocalciferol, amphetamine-dextroamphetamine, clonazepam, gabapentin, methocarbamol, ondansetron, pantoprazole, polyethylene glycol powder and senna and scheduled for outpatient follow-up with addiction medicine, endocrine, and gastrointestinal surgery. Pre-surgical electrocardiogram identified ventricular trigeminy and echocardiogram found low normal ejection fraction. He was started on metoprolol and underwent further cardiac testing including cardiac MRI and a Holter monitor for 1 week, which found symptomatic high PVC burden (23.4%). Surgery was deferred until PVCs could be controlled. Patient was counseled to stop Kratom and amphetamine-dextroamphetamine, and on follow-up Holter monitor PVC burden was reduced (10.3%).

The patient underwent laparoscopic enucleation of the pancreatic uncinata mass, converted to open operation due to difficulty discerning the mass laparoscopically. Final pathology was consistent with solid-pseudopapillary neoplasm, with maximum diameter of 2.6 centimeters. Perioperative pain was managed by bupivacaine patient controlled epidural analgesia due to prior history of opioid use disorder. During recovery he experienced transient fever to 37.9 C and leukocytosis to 12.2. He was discharged 4 days after surgery. He noticed drainage from his drain site after surgery, and CT scan two weeks after surgery showed a large peripancreatic fluid collection that was 8.5 cm in size and rim-enhancing. CT-guided drainage was successful four weeks after surgery, without further complication.

Discussion

Solid pseudopapillary neoplasms (SPN) are rare, low-grade malignant tumors associated with female sex and an average age of presentation in the 30s.^{4,7,8} It is a nonfunctional epithelial tumor that is often asymptomatic or causes nonspecific gastrointestinal symptoms primarily by mass effect, central hemorrhage, or central necrosis. Metastases are rare, with the most common locations for metastases are liver and peritoneum.⁹

Preoperative diagnosis of SPNs can be difficult due to its nonspecific clinical presentation and subtleties in differentiating it from other pancreatic neoplasms. Evaluation for SPNs should include cross-sectional imaging, ideally contrast-enhanced CT scan or MRI, endoscopic ultrasound with fine needle aspiration (EUS-FNA), and endocrine laboratory studies to investigate potential neuroendocrine tumors. Studies should be done for lymph node invasion and metastases, although fortunately these are rare in patients with SPN.⁵ Typical CT findings are of an encapsulated mass with sharp borders and varying solid and cystic components due to hemorrhagic degeneration. Calcification and solid areas are usually identified at the periphery of the mass. SPN on EUS is characterized as a well circumscribed, hypoechoic, heterogenous solid mass with cystic, hemorrhagic, and calcified areas. EUS-FNA has preoperative diagnostic accuracy around 75-80%,^{10,11} with immunostaining generally positive for beta-catenin (nuclear and cytoplasmic), vimentin, synaptophysin, progesterone receptor (nuclear), CD56, neuro-specific enolase, CD10, and E-cadherin (loss of membrane and nuclear).^{6,12} Nuclear beta catenin expression and membranous E-cadherin loss are especially useful in differentiating SPN from other pancreatic tumors.⁶

Surgical resection with organ preservation is the preferred treatment for SPN.⁶ Margin-negative surgical resection is generally curative, although recurrence occurs in 5-10% of patients by 10 years.^{5,6} Surgical treatment depends on the location and size of the tumor. The most common surgeries include distal pancreatectomy and splenectomy (if tumor at tail), spleen preserving distal pancreatectomy (if tumor at tail), central pancreatectomy with distal pancreaticojejunostomy or pancreaticogastrostomy radical pancreaticoduodenectomy (if tumor at neck), pylorus preserving pancreaticoduodenectomy (if tumor at head), and enucleation (if small SPN distant from pancreatic duct).^{5,6} The most common complications of surgery include postoperative pancreatic fistula, pseudomembranous colitis, pneumonitis, steatorrhea, delayed gastric emptying, portal vein thrombosis, abscess and pancreatitis.^{6,8} The potential use of chemotherapy or radiation in SPN treatment is not well researched. Preoperative chemotherapy with fluorouracil and radiation followed with gemcitabine may decrease the size of an unresectable SPN prior to definitive surgery.¹³ SPN has generally been considered radiosensitive.¹⁴

The reported 5 year survival from SPN is about 97%, and prolonged survival is typical even in patients with metastases following surgical debulking.⁹ There are currently no guide-

lines for follow up after surgical resection of SPN. However, SPN with pathologic features indicating aggressive behavior should receive extended follow up. Features indicating of aggressive behavior include tumor size greater than 5 cm,^{3,7} diffuse growth pattern, high mitotic activity, nuclear atypia, tumor necrosis, and component of sarcomatoid carcinoma.⁹ Potential recommendations for follow-up in aggressive tumors include annual or biannual abdominal CT scans or MRI.⁶

We present a rare pancreatic tumor in a 30-year-old male with history of opioid use disorder. Solid pseudopapillary neoplasms are rare neoplasms but are increasing in incidence. Our patient presented with nonspecific GI symptoms, including nausea, vomiting, diarrhea, and generalized, worsening abdominal pain for 5 months. Abdominal CT, endoscopic ultrasound with fine needle aspiration and immunohistochemical staining, and through endocrine testing led to the diagnosis of solid pseudopapillary neoplasm. It is important to exclude pancreatic adenocarcinoma and neuroendocrine tumors of the pancreas. Surgical resection with clear margins is generally curative and can prevent metastatic disease. The patient is now four months post-surgery, with resolution of symptoms and no tumor recurrence.

REFERENCES

- Gandhi D, Sharma P, Parashar K, Kochar PS, Ahuja K, Sawhney H, Sharma S.** Solid pseudopapillary Tumor of the Pancreas: Radiological and surgical review. *Clin Imaging.* 2020 Nov;67:101-107. doi: 10.1016/j.clinimag.2020.06.008. Epub 2020 Jun 9. PMID: 32559679.
- Valsangkar NP, Morales-Oyarvide V, Thayer SP, Ferrone CR, Wargo JA, Warshaw AL, Fernández-del Castillo C.** 851 resected cystic tumors of the pancreas: a 33-year experience at the Massachusetts General Hospital. *Surgery.* 2012 Sep;152(3 Suppl 1):S4-12. doi: 10.1016/j.surg.2012.05.033. Epub 2012 Jul 6. PMID: 22770958; PMCID: PMC3806101.
- Kim MJ, Choi DW, Choi SH, Heo JS, Sung JY.** Surgical treatment of solid pseudopapillary neoplasms of the pancreas and risk factors for malignancy. *Br J Surg.* 2014 Sep;101(10):1266-71. doi: 10.1002/bjs.9577. Epub 2014 Jul 23. PMID: 25052300.
- Guo N, Zhou QB, Chen RF, Zou SQ, Li ZH, Lin Q, Wang J, Chen JS.** Diagnosis and surgical treatment of solid pseudopapillary neoplasm of the pancreas: analysis of 24 cases. *Can J Surg.* 2011 Dec;54(6):368-74. doi: 10.1503/cjs.011810. PMID: 21939604; PMCID: PMC3238340.
- Lubezky N, Papoulas M, Lessing Y, Gitstein G, Brazowski E, Nachmany I, Lahat G, Goykhman Y, Ben-Yehuda A, Nakache R, Klausner JM.** Solid pseudopapillary neoplasm of the pancreas: Management and long-term outcome. *Eur J Surg Oncol.* 2017 Jun;43(6):1056-1060. doi: 10.1016/j.ejso.2017.02.001. Epub 2017 Feb 10. PMID: 28238521.
- Lanke G, Ali FS, Lee JH.** Clinical update on the management of pseudopapillary tumor of pancreas. *World J Gastrointest Endosc.* 2018 Sep 16;10(9):145-155. doi: 10.4253/wjge.v10.i9.145. PMID: 30283597; PMCID: PMC6162250.
- Butte JM, Brennan MF, Gönen M, Tang LH, D'Angelica MI, Fong Y, Dematteo RP, Jarnagin WR, Allen PJ.** Solid pseudopapillary tumors of the pancreas. Clinical features, surgical outcomes, and long-term survival in 45 consecutive patients from a single center. *J Gastrointest Surg.* 2011 Feb;15(2):350-7. doi: 10.1007/s11605-010-1337-1. Epub 2010 Sep 8. PMID: 20824369.
- Reddy S, Cameron JL, Scudiere J, Hruban RH, Fishman EK, Ahuja N, Pawlik TM, Edil BH, Schulick RD, Wolfgang CL.** Surgical management of solid-pseudopapillary neoplasms of the pancreas (Franz or Hamoudi tumors): a large single-institutional series. *J Am Coll Surg.* 2009 May;208(5):950-7; discussion 957-9. doi: 10.1016/j.jamcollsurg.2009.01.044. PMID: 19476869; PMCID: PMC3109868.
- Tang LH, Aydin H, Brennan MF, Klimstra DS.** Clinically aggressive solid pseudopapillary tumors of the pancreas: a report of two cases with components of undifferentiated carcinoma and a comparative clinicopathologic analysis of 34 conventional cases. *Am J Surg Pathol.* 2005 Apr;29(4):512-9. doi: 10.1097/01.pas.0000155159.28530.88. PMID: 15767807.
- Stoita A, Earls P, Williams D.** Pancreatic solid pseudopapillary tumours - EUS FNA is the ideal tool for diagnosis. *ANZ J Surg.* 2010 Sep;80(9):615-8. doi: 10.1111/j.1445-2197.2010.05404.x. Epub 2010 Aug 19. PMID: 20840404.
- Maimone A, Luigiano C, Baccarini P, Fornelli A, Cennamo V, Polifemo A, Fiscaletti M, de Biase D, Jaboli F, Virgilio C, Stelitano L, Zanini N, Masetti M, Jovine E, Fabbri C.** Preoperative diagnosis of a solid pseudopapillary tumour of the pancreas by Endoscopic Ultrasound Fine Needle Biopsy: A retrospective case series. *Dig Liver Dis.* 2013 Nov;45(11):957-60. doi: 10.1016/j.dld.2013.06.005. Epub 2013 Jul 19. PMID: 23876743.
- Serra S, Chetty R.** Revision 2: an immunohistochemical approach and evaluation of solid pseudopapillary tumour of the pancreas. *J Clin Pathol.* 2008 Nov;61(11):1153-9. doi: 10.1136/jcp.2008.057828. Epub 2008 Aug 15. PMID: 18708424.
- Maffuz A, Bustamante Fde T, Silva JA, Torres-Vargas S.** Preoperative gemcitabine for unresectable, solid pseudopapillary tumour of the pancreas. *Lancet Oncol.* 2005 Mar;6(3):185-6. doi: 10.1016/S1470-2045(05)01770-5. PMID: 15737835.
- Fried P, Cooper J, Balthazar E, Fazzini E, Newall J.** A role for radiotherapy in the treatment of solid and papillary neoplasms of the pancreas. *Cancer.* 1985 Dec 15;56(12):2783-5. doi: 10.1002/1097-0142(19851215)56:12<2783::aid-cnrc2820561211>3.0.co;2-q. PMID: 4052952.