

## **UC Irvine**

### **Journal of Education and Teaching in Emergency Medicine**

#### **Title**

Corneal Sparing Conjunctival Abrasion

#### **Permalink**

<https://escholarship.org/uc/item/30k6h8rd>

#### **Journal**

Journal of Education and Teaching in Emergency Medicine, 2(3)

#### **Authors**

Ehsani-Nia, Hamid  
Dall, Tanya  
Costantini, Samantha

#### **Publication Date**

2017

#### **DOI**

10.5070/M523035674

#### **Copyright Information**

Copyright 2017 by the author(s). This work is made available under the terms of a Creative Commons Attribution License, available at <https://creativecommons.org/licenses/by/4.0/>

Peer reviewed

## Corneal Sparing Conjunctival Abrasion

Hamid Ehsani-Nia, MS\*, Tanya Dall, MD<sup>^</sup> and Samantha Costantini, MD<sup>^</sup>

\*Rowan University School of Osteopathic Medicine, Stratford, NJ

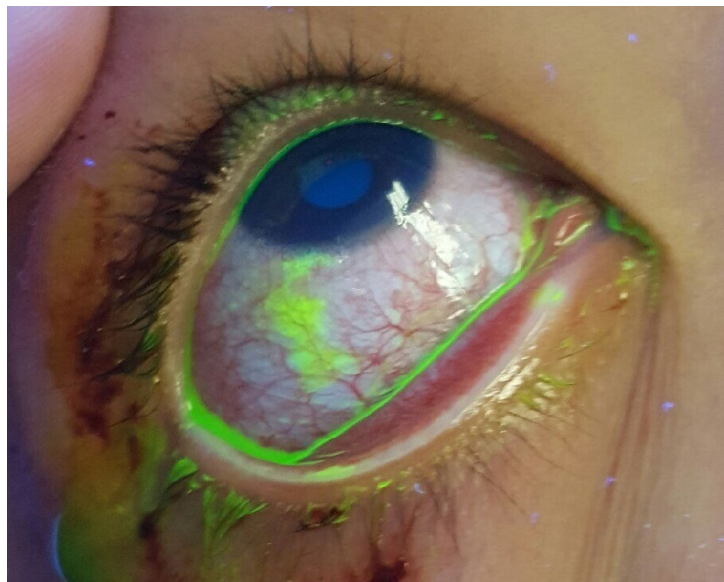
<sup>^</sup>University of California, Irvine, Department of Emergency Medicine, Orange, CA

Correspondence should be addressed to Tanya Dall, MD at [tdall@uci.edu](mailto:tdall@uci.edu)

Submitted: December 6, 2016; Accepted: May 19, 2017; Electronically Published: July 14, 2017; <https://doi.org/10.21980/J8KG93>

Copyright: © 2017 Ehsani-Nia et al. This is an open access article distributed in accordance with the terms of the Creative Commons Attribution (CC BY 4.0) License.

See: <http://creativecommons.org/licenses/by/4.0/>



**History of present illness:** A 15-year-old male was transported to the emergency department via ambulance as a trauma activation after being struck by an automobile while jogging. Patient was alert and oriented, with no focal neurological deficits and no loss of consciousness. The patient complained of right eye foreign body sensation.

**Significant findings:** Physical exam was significant for multiple broken teeth, multiple minor abrasions on the face, and fine shards of shattered glass on his face and hair. His right eye had conjunctival injection, with no signs of subconjunctival hemorrhage or ocular penetration. Vision, extraocular movement, and pupillary exam were grossly intact. Fluorescein staining with slit lamp exam with cobalt blue filter examination of the right eye revealed superficial bulbar conjunctival uptake of fluorescein dye staining an area of the conjunctiva inferior to the limbus 5 mm vertical by 2 mm horizontal (estimation by photo provided). No foreign bodies were visualized in the inferior fornix. These findings were consistent with superficial conjunctival abrasion. The exam noted sparing of the corneal epithelium.

Eh:  
htt

**Discussion:** The conjunctiva is a thin, transparent membrane covering the ocular surface from the corneal limbus to the posterior eyelid margin.<sup>1</sup> When damaged, the patient will classically have a “foreign body” sensation. It is important to identify the extent of the injury as not extending over the cornea, and also to search for lodged foreign bodies that damage the conjunctiva further with each blink. Classically retained foreign bodies will form a linear and vertical pattern of staining with fluorescein.<sup>2,3</sup> Fluorescein stains expose basement membrane and fluoresces bright green under ultraviolet light, thus indicating areas of damage in contrast to its surrounding tissue.<sup>4,5</sup> In the setting of acute trauma, urgent Ophthalmologic consultation is indicated if there is anterior chamber hemorrhage, a ruptured or perforated globe, or conjunctival laceration greater than 1cm.<sup>6</sup> Most minor mechanical traumas to the conjunctiva have an excellent prognosis and can be handled in the emergency department with outpatient treatment with antibiotic drops or ointment.

**Topics:** Ophthalmology, ophtho, eye, cornea, abrasions.

#### References:

1. Khurana AK. Anatomy and development of the eye. In: Khurana AK, ed. *Comprehensive Ophthalmology*. 4<sup>th</sup> ed. New Delhi: New Age International; 2007:3-12.
2. Hamill MB. Conjunctiva. In: Kuhn F, Pieramici DJ, eds. *Ocular Trauma: Principles and Practice*. 1<sup>st</sup> ed. New York, NY: Thieme; 2002:89-94.
3. Kaiser PK, Friedman NJ, Pineda II R. Cornea. In: Kaiser PK, Friedman NJ, Pineda II R, eds. *The Massachusetts Eye and Ear Infirmary Illustrated Manual of Ophthalmology*. London, UK: Elsevier; 2014:173-177.
4. Ponka D, Baddar F. Wood lamp examination. *Canadian Family Physician*. 2012;58(9):976.
5. Wipperman JL, Dorsch JN. Evaluation and management of corneal abrasions. *Am Fam Physician*. 2013;87(2):114-120.
6. Bord SP, Linden J. Trauma to the globe and orbit. *Emerg Med Clin North Am*. 2008;26(1):97-123,vi-vii. doi: 10.1016/j.emc.2007.11.006