

UC Davis

Dermatology Online Journal

Title

Resolution of psoriasis after tonsillectomy

Permalink

<https://escholarship.org/uc/item/3043t0mq>

Journal

Dermatology Online Journal, 23(2)

Authors

Loyal, Jameson
Flores, Sara
Alikhan, Ali

Publication Date

2017

DOI

10.5070/D3232033979

Copyright Information

Copyright 2017 by the author(s). This work is made available under the terms of a Creative Commons Attribution-NonCommercial-NoDerivatives License, available at <https://creativecommons.org/licenses/by-nc-nd/4.0/>

Resolution of psoriasis after tonsillectomy

Jameson Loyal BA¹, Sara Flores MD², Ali Alikhan MD²

Affiliations: ¹University of Vermont College of Medicine, Burlington, VT, ²University of Cincinnati College of Medicine, Cincinnati, OH

Corresponding Author: Jameson Loyal, University of Vermont College of Medicine, Email: Jameson.Loyal@med.uvm.edu

Abstract

A 19-year-old woman experienced recalcitrant psoriasis after streptococcal pharyngitis. Multiple treatment regimens were employed, but results were poor until after the patient underwent tonsillectomy.

Keywords: dermatology; psoriasis; tonsillectomy; pharyngitis; tonsillitis; streptococci

Introduction

Psoriasis is a chronic, T-cell mediated skin disease affecting approximately 2-4% of the western population [1-4]. The severity of psoriasis is dependent on a variety of factors including genetic, infectious, obesity, and environmental factors. There is considerable data suggesting a connection between psoriasis exacerbations and streptococcal pharyngotonsillitis infections. Triggering of interferon- γ -positive, CD-8-positive skin-homing T-cells by streptococcal M proteins through a molecular mimicry-like mechanism likely contributes to psoriasis flares. Emerging evidence suggests the use of tonsillectomy for the clearance or improvement of psoriasis eruptions in select patients [3,5]. Herein we present a young woman who presented with psoriasis on her extremities, trunk, face, and scalp in the setting of multiple pharyngotonsillitis infections. After minimal improvement of the patient's psoriasis with various topical therapies and a trial of apremilast, along with continued episodes of pharyngitis, the patient underwent tonsillectomy and adenoidectomy. Three months post-operatively, the psoriasis cleared completely and the patient discontinued all medications.

Case Synopsis

A nineteen-year-old woman presented to our clinic

with a seven-week history of well-defined, round, erythematous, scaly, pruritic papules and small plaques involving the proximal extremities, trunk, face, and scalp, clinically consistent with guttate psoriasis. The patient denied a family history of psoriasis. She endorsed three episodes of tonsillitis over the previous six months and two instances of streptococcal pharyngitis approximately six to eight weeks prior to the onset of her eruption.

The patient's schedule prevented her from using narrow-band UVB phototherapy and consequently various topical therapies were prescribed over the ensuing eight months. For the patient's facial involvement, desonide 0.05% cream was first prescribed but was later transitioned to mometasone 0.1% cream and then tacrolimus 0.1% ointment. The scalp was first treated with clobetasol 0.05% solution alone and then salicylic acid 6% shampoo was added. Owing to limited resolution of the scalp eruption, the use of National Biological's Dermalight 90's narrow-band UVB scalp comb was combined with topical therapy. Eight months after initially presenting, the topical scalp regimen was changed to a combination calcipotriene 0.005%-betamethasone 0.064% foam. The body eruption was originally treated with mometasone 0.1% cream but was switched to clobetasol 0.05% cream two months later. Because of the recalcitrant nature of this patient's psoriasis, apremilast 30mg twice daily was added to the topical regimen four months after treatment initially started. However, owing to persistent nausea the patient discontinued this medication after five months of use. Even with the use of multiple topical agents and the addition of apremilast, the patient's psoriatic papules on the back, chest, abdomen, thighs, and arms coalesced into larger plaques, having an appearance more consistent with plaque psoriasis.

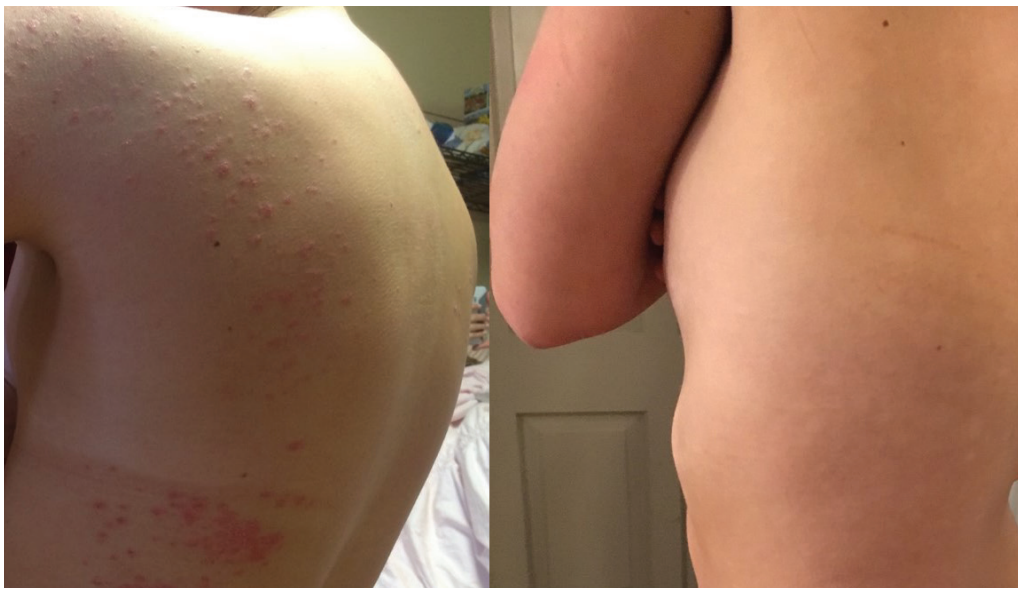

Figure 1A-B. Psoriatic papules and plaques on the lateral back, abdomen, and flank before (A) and three months after (B) tonsillectomy.

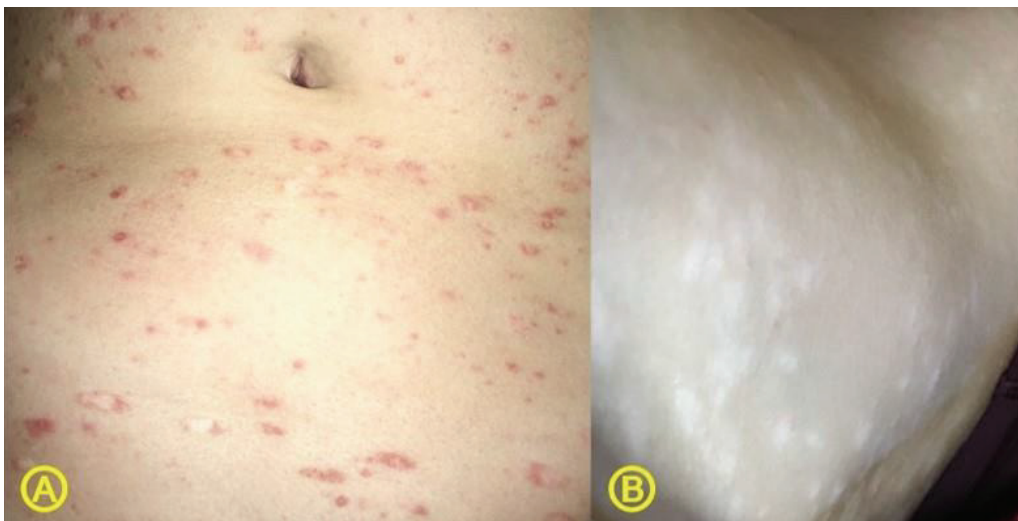


Figure 2A-B. Psoriatic papules and plaques on the abdomen before (A) and three months after (B) tonsillectomy.

After several subsequent episodes of pharyngitis, the patient was referred to the otolaryngology department and ultimately underwent a tonsillectomy and adenoidectomy for chronic tonsillitis and adenoiditis. One month post-operatively, the patient's psoriasis showed no improvement with involvement of over 10% body surface area. Two months post-operatively, the psoriasis had started to clear and approximately three months post-operatively, the psoriasis had cleared completely and the patient discontinued all topical treatments (Figures 1 and 2).

Case Discussion

There is considerable evidence suggesting a

connection between psoriasis exacerbations and streptococcal infections, in particular β -hemolytic streptococcal, pharyngotonsillitis infections. In fact, the first reported link between acute tonsillitis and psoriasis dates back to 1916 [5]. Interestingly, psoriasis patients report developing sore throat and upper respiratory infections more frequently than those without psoriasis. The triggering mechanism behind psoriasis and streptococcal pharyngitis has not been completely elucidated. However, the leading theory involves streptococci residing on the tonsillar epithelium triggering interferon- γ -positive, CD-8-positive skin-homing T-cells through a molecular mimicry-like mechanism [3,5]. This mimicry mechanism relates to structural similarities between human epithelial keratins 14, 16 and 17 and the M protein virulence factor of streptococci of Lancefield groups A, C, and G [4,6,7]. Keratins 16 and 17 are particularly upregulated in psoriatic lesions resulting in a predisposition for this

molecular mimicry cascade. Lancefield groups B and F streptococci lack an M protein and, therefore, have not been shown to exacerbate psoriasis [7]. The streptococcal M protein is a superantigen that causes this exaggerated immune response and cross reactivity with epidermal antigens [1,6].

Although a tonsillectomy is typically reserved for patients with recurrent and/or chronic tonsillitis, peritonsillar abscesses, and airway obstruction in select patients, there is emerging evidence that patients suffering from psoriasis are experiencing clearance or improvement of their skin disease

from this procedure [3,5]. In the first randomized control trial investigating the use of tonsillectomy for reduction of plaque psoriasis severity, Thorleifsdottir et al. reported that 86% of patients undergoing tonsillectomy for plaque psoriasis showed a reduction in Psoriasis Area and Severity Index (PASI) of 30-90%, whereas the control group did not show any significant improvement in psoriasis [3,8]. Reports of significant improvement of guttate psoriasis after tonsillectomy were also demonstrated in case series by McMillin et al. as well as by Hone et al. where 100% and 83% of patients showed complete clearance following tonsillectomy, respectively [2,3,6]. In a large systemic review of 20 studies with a cohort of close to 600 patients, Rachakonda et al. found that the majority of patients undergoing tonsillectomy demonstrated improvement in their psoriasis severity in as little as two months post-procedure. Other benefits from tonsillectomy that were reported included longer psoriasis-free periods and psoriasis flares being more responsive to standard therapies [5]. Improvement in psoriasis post-tonsillectomy likely relates to the decrease in skin-homing T-cells that were once found in the tonsils. It should be noted that other lymphoid tissues particularly in the head and neck region also contain these skin-homing T-cells. Patients who initially report clearance of their psoriasis might still have flares months-to-years post-procedure owing to lingering immune-modulated cells [5].

The recommendation of tonsillectomy for patients suffering from psoriasis, even those patients exhibiting a clear connection between psoriasis flares and streptococcal pharyngitis, lacks substantial evidence [3,5]. The risks of a tonsillectomy, including hemorrhage, infection, laryngospasm, bronchospasm, temporomandibular joint dysfunction, vocal cord injury, and death, must be weighed against the potential benefits of clearance or reduction in psoriatic lesions [5]. More research is needed to determine the long-term efficacy of tonsillectomy in psoriasis as well as identify the patients who would benefit most from this procedure.

References

1. Simões JF, Ribeiro J, Ferreira BR, Paiva S. The role of tonsillectomy in psoriasis treatment. *BMJ Case Rep.* 2015 Jan 30;2015. [PMID: 25636628]
2. Hone SW, Donnelly MJ, Powell F, Blayney AW. Clearance of recalcitrant psoriasis after tonsillectomy. *Clin Otolaryngol Allied*

3. Sci. 1996 Dec;21(6):546-7. [PMID: 9118579]
3. Wu W, Debbaneh M, Moslehi H, Koo J, Liao W. Tonsillectomy as a treatment for psoriasis: a review. *J Dermatolog Treat.* 2014 Dec;25(6):482-6. [PMID: 24283892]
4. Valdimarsson H, Thorleifsdottir RH, Sigurdardottir SL, Gudjonsson JE, Johnston A. Psoriasis--as an autoimmune disease caused by molecular mimicry. *Trends Immunol.* 2009 Oct;30(10):494-501. [PMID: 19781993]
5. Rachakonda TD, Dhillon JS, Florek AG, Armstrong AW. Effect of tonsillectomy on psoriasis: a systematic review. *J Am Acad Dermatol.* 2015 Feb;72(2):261-75. [PMID: 25455609]
6. McMillin BD, Maddern BR, Graham WR. A role for tonsillectomy in the treatment of psoriasis?. *Ear Nose Throat J.* 1999 Mar;78(3):155-8. [PMID: 10188351]
7. Gudjonsson JE, Thorarinsson AM, Sigurgeirsson B, Kristinsson KG, Valdimarsson H. Streptococcal throat infections and exacerbation of chronic plaque psoriasis: a prospective study. *Br J Dermatol.* 2003 Sep;149(3):530-4. [PMID: 14510985]
8. Thorleifsdottir RH, Sigurdardottir SL, Sigurgeirsson B, Olafsson JH, Sigurdsson MI, Petersen H, Arnadottir S, Gudjonsson JE, Johnston A, Valdimarsson H. Improvement of psoriasis after tonsillectomy is associated with a decrease in the frequency of circulating T cells that recognize streptococcal determinants and homologous skin determinants. *J Immunol.* 2012 May 15;188(10):5160-5. [PMID: 22491250]