

# UC Davis

## Dermatology Online Journal

### Title

An atrophic plaque on the breast six years after breast reconstruction surgery

### Permalink

<https://escholarship.org/uc/item/2zt690tx>

### Journal

Dermatology Online Journal, 22(6)

### Authors

Khurana, Michele  
Torbeck, Richard  
Kauh, Young

### Publication Date

2016

### DOI

10.5070/D3226031323

### Copyright Information

Copyright 2016 by the author(s). This work is made available under the terms of a Creative Commons Attribution-NonCommercial-NoDerivatives License, available at <https://creativecommons.org/licenses/by-nc-nd/4.0/>

Peer reviewed

**Volume 22 Number 6**  
**June 2016**

**Case Presentation**

**An atrophic plaque on the breast six years after breast reconstruction surgery**

**Michele Khurana MD, Richard Torbeck MD, Young Kauh MD**

**Dermatology Online Journal 22 (6): 11**

**Department of Dermatology, Sidney Kimmel Medical College at Thomas Jefferson University, Philadelphia, PA**

**Correspondence:**

Richard Torbeck, MD

Department of Dermatology, Sidney Kimmel Medical College at Thomas Jefferson University

833 Chestnut St. Suite 740

Philadelphia, PA 19107, United States

Tel. (215) 955-8325 Fax. (215) 503-3333

Email: Richard.Torbeck@jefferson.edu

---

**Abstract**

Necrobiosis lipoidica (NL) is a cutaneous disease entity that typically manifests as atrophic yellow plaques with telangiectasias on the anterior tibial region. Although NL is commonly associated with diabetes mellitus, the role of trauma in disease development is less commonly emphasized. The relationship between NL and the Köbner phenomenon has been established, as a few cases of NL occurring in surgical scars have been reported in the literature. We report the first case of NL occurring in a mastectomy scar on the breast in a non-diabetic female, and explore the relationship between NL, diabetes mellitus, and trauma.

**Keywords: necrobiosis lipoidica, NL, granulomatous disease, Köbner phenomenon**

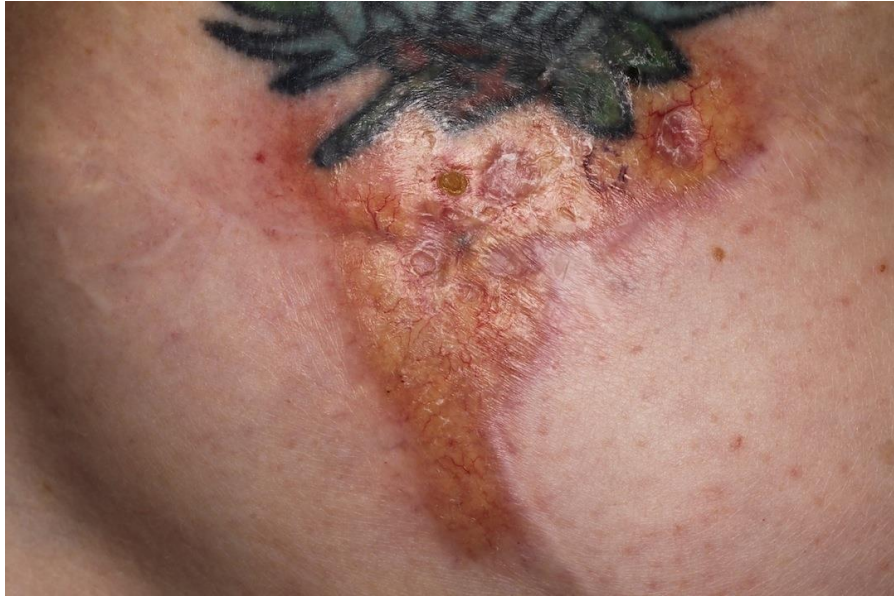**Introduction**

Necrobiosis lipoidica (NL) is a cutaneous disease entity that is commonly associated with diabetes mellitus. The typical presentation includes atrophic yellow plaques with telangiectasias on the anterior tibial region. Although a clear mechanism for pathogenesis has yet to be determined, trauma appears to play a role in disease development. A few case reports of NL occurring in scars have been reported in the literature, thereby establishing a relationship between NL and the Köbner phenomenon. We present a unique case of NL occurring in a mastectomy scar on the breast in a non-diabetic individual. Our case not only highlights a unique presentation of NL but also further adds to the theory that trauma plays a role in the pathogenesis of this disease.

**Case synopsis**

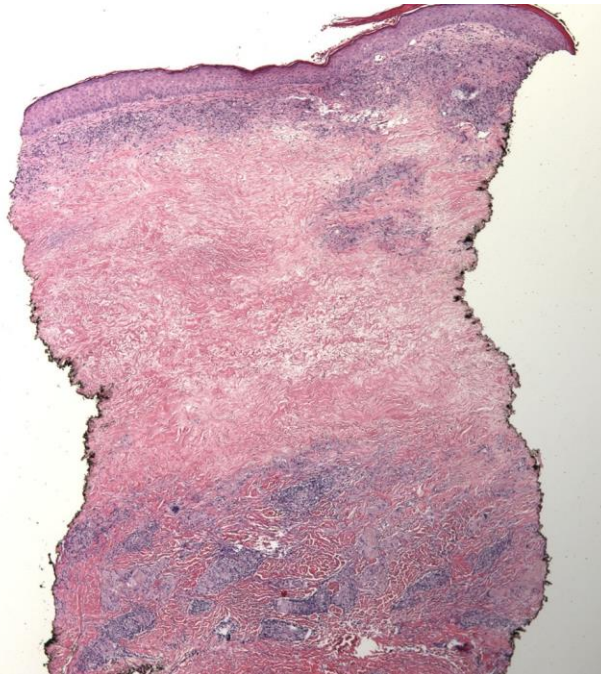
A woman in her late 40s with a history of breast cancer presented to the clinic for evaluation of a persistent red lesion on her breast, six years after breast surgery. She had a bilateral mastectomy with radiation and breast reconstruction surgery in 2003 and 2008, respectively. The lesion had been present for about one year and was located at the site of her mastectomy scar on her left breast. She reported that the plaque was asymptomatic but would bleed when scratched. Review of systems was negative. Her past medical history was significant for hyperlipidemia and obesity. The patient denied any family history of diabetes mellitus but

reported a positive family history of skin cancer. Physical examination revealed a 5.5 x 4.9 cm irregularly shaped atrophic yellow-red plaque with telangiectasias and underlying erythema at the site of a former mastectomy incision on the left breast (Figure 1). No cutaneous anesthesia was noted. A 4mm punch biopsy was performed and the specimen was stained with hematoxylin-eosin.



**Figure 1.** Physical exam revealed an irregularly shaped yellow atrophic plaque with telangiectasia and surrounding erythema within a scar on the breast.

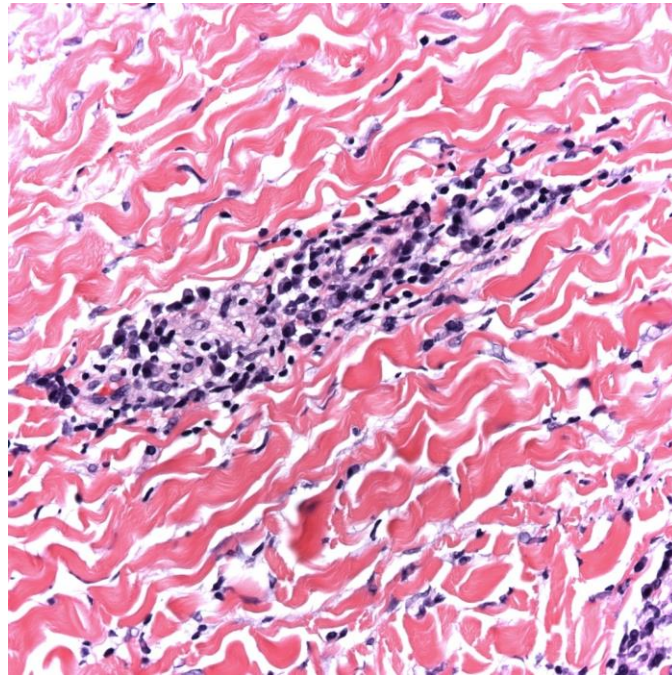
Histopathologic evaluation revealed a horizontally tiered fibrosing granulomatous dermatitis between layers of acellular, pale, degenerated collagen (Figure 2).



**Figure 2.** Histopathologic specimen of the plaque showing a horizontally tiered fibrosing granulomatous dermatitis between layers of acellular, pale, degenerated collagen (H&E, original magnification x 40).

At higher power, a characteristic plasma cell infiltrate in the deep dermis was seen (Figure 3). Laboratory workup showed a normal fasting serum glucose level of 92 mg/dL. The patient's hemoglobin A1c was at the lower end of the pre-diabetic range at

5.7%, indicating an increased risk for diabetes. Based upon clinical and histopathologic findings, the diagnosis of necrobiosis lipoidica was made. She was treated with betamethasone valerate cream 0.1% twice daily to the lesion with some improvement.



**Figure 3.** Histopathologic specimen of the plaque reveals plasma cells with characteristic eccentric nuclei located within the deep dermis (H&E, original magnification x 400).

## Discussion

Necrobiosis lipoidica (NL) is a cutaneous disease entity that is closely associated with diabetes mellitus. Although only 0.3% of diabetic patients develop NL, the majority of patients with NL also have clinically proven diabetes mellitus [1]. However, a significant number of cases have also occurred in nondiabetic patients. A study of 171 patients with NL by Muller et al showed that 65% of subjects had clinical DM while 35% of subjects did not [1]. Necrobiosis lipoidica occurs more commonly in females, showing a 3:1 female to male ratio [1]. Characteristic lesions include asymptomatic irregular plaques with a central yellow atrophic area that may ulcerate, surrounded by a violaceous peripheral border. The majority of lesions are located bilaterally on the lower extremities, particularly on the pretibial region [1]. Rarely, in addition to the characteristic leg lesions, there may be lesions in atypical locations on the hands, forearms, abdomen, face, and/or scalp [1].

Histopathologically, the epidermis may be normal, atrophic, ulcerated, or hyperkeratotic [2]. Characteristic changes seen in NL occur in the dermis, which exhibits varying degrees of granulomatous inflammation, collagen degeneration, and sclerosis [2]. The granulomatous inflammation seen in NL may involve histiocytes arranged in a horizontally oriented or tiered palisade [2]. Collagen degeneration, or “necrobiosis”, is characterized by pale fragmented collagen fibers [2]. Alternating levels of cellular and acellular components can be seen on low power scan. A plasma cell infiltrate in the deep dermis, particularly at the dermal-subcutaneous junction, is a typical finding in NL [2]. Two different histological patterns for NL have been described, with the primary pattern varying based upon diabetic status [1,3]. A “tuberculoid” or “granulomatous” pattern characterized by a histiocytic-epithelioid cell response and mild necrobiosis is predominant in non-diabetic patients, whereas a “palisading granulomatous” or “necrobiotic” pattern with irregular degenerated collagen fibers surrounded by palisading histiocytes is predominant in diabetic patients [1-3]. The latter was seen in our patient’s biopsy of the lesion.

Pathogenesis of NL is unknown, but is thought to relate to glycoprotein deposition in the dermal vasculature, leading to microangiopathy and hypoxia [4]. Trauma appears to serve as a trigger to NL development given the propensity of NL to manifest on the anterior tibial region, a common site for physical trauma. The relationship between the Köbner phenomenon and NL is well-established, as NL has been reported to occur in burn scars on the legs as well as in surgical scars located on the abdomen, upper extremity, and lower extremity [5-9]. In these cases, NL appeared to occur within 2-10 years after surgery or burn injury [5-9]. Our patient’s presentation of NL in a surgical scar on the breast occurred within a similar time frame after surgery as the

above-mentioned cases. This case highlights the predilection for NL to occur in sites of trauma, particularly at the site of a preexisting scar.

A gold standard for treatment of NL has yet to be established. Accepted therapies include topical or intralesional corticosteroids, fibrinolytics, and/or antiplatelet agents [4]. Although not a first line therapy, excision with or without skin grafting is indicated for recalcitrant ulcers [4]. Medical management of glycemic control has not been shown to be successful in clearing of lesions [1]. Muller et al showed that only 6 out of 111 patients with DM and NL experienced clearing of lesions after glycemic control with either insulin or dietary measures alone [1].

## Conclusion

In summary, our case illustrates the relationship between NL, trauma, and diabetes mellitus. Although NL classically manifests on the lower legs, atypical presentations located in scars have been reported in the literature. It is therefore important to include NL in the differential diagnosis of a lesion occurring at a site of trauma, especially if the lesion occurs within a scar. Our case also highlights the fact that NL can occur in non-diabetic patients, despite the association of NL with diabetes. Thus, the authors conclude that whereas a clear link between NL and diabetes has already been established, there is also an important association between NL and the Köbner phenomenon.

## References

1. Muller SA, Winkelmann RK. Necrobiosis lipoidica diabetorum: a clinical and pathological investigation of 171 cases. *Arch Dermatol.* 1966 Mar;93(3):272-81. [PMID:5910868]
2. Lever WF, Elder D. Lever's histopathology of the skin. 10th ed. Philadelphia, PA: Lippincott Williams & Wilkins; 2009.
3. Lowitt MH, Dover JS. Necrobiosis lipoidica. *J Am Acad Dermatol.* 1991 Nov;25(5):735-48. [PMID:1802895]
4. Boateng B, Hiller D, Albrecht HP, Homstein OP. Cutaneous microcirculation in pretibial necrobiosis lipoidica: comparative laser Doppler flowmetry and oxygen partial pressure determinations in patients and healthy probands [in German]. *Hautarzt.* 1993 Sep;44(9):581-6. [PMID:8407326]
5. Sahl WJ. Necrobiosis lipoidica diabetorum: localization in surgical scars. *J Cutan Pathol.* 1978 Oct;5(5):249-53. [PMID:730866]
6. Miller RA. Koebner phenomenon in a diabetic with necrobiosis lipoidica diabetorum. *Int J Dermatol.* 1990 Jan-Feb;29(1):52-3. [PMID:2329027]
7. Ghate JV, Williford PM, Sane DC, Hitchcock MG. Necrobiosis lipoidica associated with Koebner's phenomenon in a patient with diabetes. *Cutis.* 2001 Feb;67(2):158-60. [PMID:11236227]
8. Gebauer K, Armstrong M. Koebner phenomenon with necrobiosis lipoidica diabetorum. *Int J Dermatol.* 1993 Dec;32(12):895-6. [PMID:8125696]
9. Lljajam MA. Koebner's phenomenon and necrobiosis lipoidica diabetorum. *Br J Clin Prac.* 1990 Dec;44(12):765. [PMID:2102235]