

UC Davis

Dermatology Online Journal

Title

Cutaneous angiosarcoma clinically presenting as progressive solid facial edema in a 43-year-old male

Permalink

<https://escholarship.org/uc/item/2xq7w7q6>

Journal

Dermatology Online Journal, 19(11)

Authors

Choi, Won-Tak
Stetsenko, Galina Y
Zhang, Jiong
[et al.](#)

Publication Date

2013

DOI

10.5070/D31911020409

Copyright Information

Copyright 2013 by the author(s). This work is made available under the terms of a Creative Commons Attribution-NonCommercial-NoDerivatives License, available at <https://creativecommons.org/licenses/by-nc-nd/4.0/>

Peer reviewed

Case Presentation

Cutaneous angiosarcoma clinically presenting as progressive solid facial edema in a 43-year-old male

Won-Tak Choi¹, Galina Y. Stetsenko², Jiong Zhang¹, John E. Olerud², Zsolt B. Argenyi^{1,2}, and Evan George¹

Dermatology Online Journal 19 (11): 14

Departments of Pathology¹ and Internal Medicine, Division of Dermatology², University of Washington School of Medicine, Seattle, WA 98195

Correspondence:

Evan George, MD
University of Washington School of Medicine, Department of Pathology,
1959 NE Pacific, Box 356100, Seattle, WA 98195-6100.
Tel: 206-598-4933; E-mail address: evang9@uw.edu

Abstract

Cutaneous angiosarcoma of the head and neck is a rare, highly malignant neoplasm; prognosis is heavily influenced by tumor size, resectability, and stage at initial diagnosis. Most patients present with one to several erythematous to violaceous patches, plaques, or nodules. However, the clinical presentation is highly variable and leads to delayed diagnosis. We report cutaneous angiosarcoma in a 43-year-old man who presented with an 11-month history of progressive solid (non-pitting) edema involving his entire face, scalp, eyelids, and neck without characteristic clinical features of cutaneous angiosarcoma. A skin biopsy had shown non-specific findings consistent with solid facial edema or rosacea. Various etiologies were considered but there was no significant improvement after directed medical therapy. Repeat skin biopsies revealed angiosarcoma involving the dermis and sub-cutis. Computed tomography (CT) of the chest showed multiple lung nodules bilaterally and a lytic lesion in the T6 vertebra consistent with metastases. He was treated with single agent chemotherapy (paclitaxel), and had a partial response that restored his ability to open both eyes spontaneously. However, his edema has recently progressed 7 months after diagnosis. This is a rare example of cutaneous angiosarcoma presenting as progressive solid facial edema, which underscores the diverse range of clinical manifestations associated with this neoplasm.

Keywords: Angiosarcoma, lymphangiosarcoma, facial edema

Introduction

Angiosarcoma is a rare vasoformative, malignant neoplasm comprising 1-3% of adult soft tissue sarcomas [1, 2]. Two-thirds of cases are cutaneous and most of the remaining cases are located in deep soft tissue, breast, or liver. Three distinct clinical variants account for most cases of cutaneous angiosarcoma: idiopathic angiosarcoma of the head and neck, chronic lymphedema-associated angiosarcoma, and post-irradiation angiosarcoma [2]. Idiopathic angiosarcoma of the head and neck is the most common variant, representing 50% of all cases [2]. This is typically a tumor of older individuals with a median age of 70-75 years, male predominance, and a predilection for the scalp and central face. Males tend to present at a younger age than females.

All of the cutaneous angiosarcoma variants are clinically aggressive with a strong propensity for local recurrence and a high capacity for metastasis to regional lymph nodes and distant organs such as lung, liver, and bone. The reported 5-year survival rate ranges from 10 to 30% [1-3]. The neoplasm tends to invade tissue more widely than is clinically apparent and is thus prone to incomplete local excision. A high proportion of patients have locally advanced disease with tumor size greater than 5 cm, regional lymph node involvement, or distant metastases at the time of initial diagnosis, all of which are associated with a poor prognosis [1-3].

Cutaneous angiosarcoma of the head and neck has diverse clinical manifestations. Typical lesions are erythematous to violaceous macules, patches, papules, nodules, or plaques. Lesions may be solitary or multiple. Early lesions may simulate a bruise, a hemangioma, an infection, or an inflammatory disorder. In advanced lesions, ulceration and bleeding are sometimes observed. A few reports document angiosarcoma mimicking rosacea [4] and rhinophyma [5] at presentation. Rare cases presenting with

isolated eyelid edema [6], scarring alopecia [7], and chronic episodic facial edema [8, 9] have also been reported. Owing to its variable clinical presentation, the diagnosis of cutaneous angiosarcoma is often delayed. Herein, we describe angiosarcoma in a 43-year-old man who presented with progressive solid (non-pitting) facial edema.

Case synopsis

A 43-year-old Samoan man residing in Anchorage, Alaska was referred to a university dermatology clinic for the evaluation of an 11-month history of progressive facial swelling. Physical examination revealed diffusely erythematous, edematous, indurated skin over his entire face, scalp, anterior neck, and posterior neck. Bilateral eyelid and periorbital edema prevented him from opening his eyes fully (Figure 1). His past medical history included a cerebral vascular accident with complete right hemiparesis at age of 14, hyperlipidemia, hypertension, diabetes mellitus type 2, gout, vitamin D deficiency, and recurrent otitis media since childhood. He associated the edema with a change in his living situation because he first noticed swollen eyelids and cheeks within 1 week after moving into a different apartment. The swelling gradually spread to his entire face, scalp, and neck.

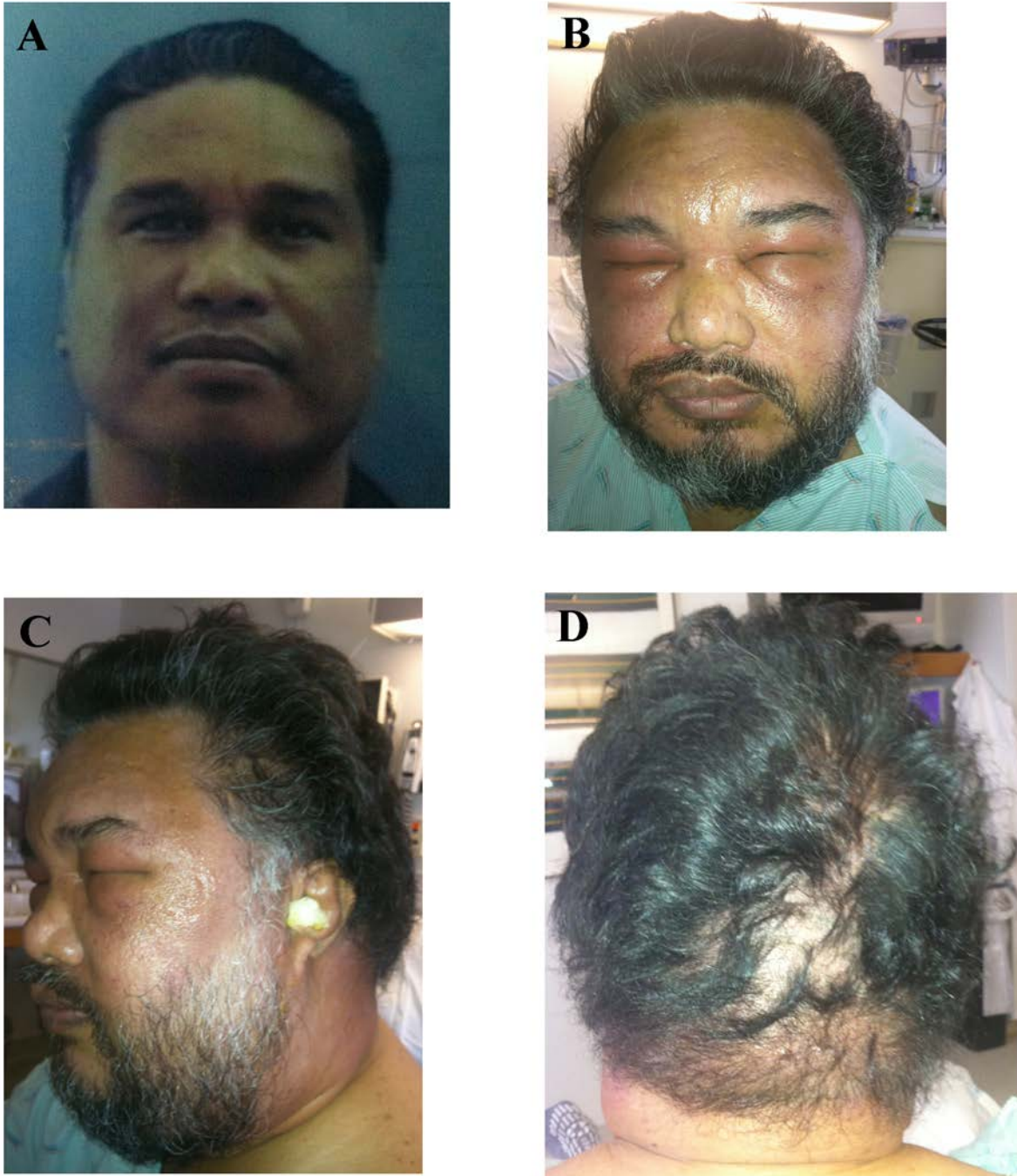

Figure 1. Clinical features of angiosarcoma (B–D) in a 43-year-old male with a 11-month history of extensive, progressive solid facial edema involving his entire face, scalp, anterior and posterior neck, and bilateral eyelids, preventing him from opening his eyes fully. The patient's appearance, 12 months prior to the beginning of symptoms, is shown for comparison (A).

The patient had been extensively evaluated by multiple physicians in Alaska for his severe facial edema, including measurement of serum complement levels, C-reactive protein, erythrocyte sedimentation rate, thyroid function, serum protein electrophoresis, and C1 esterase inhibitor function, which were all normal. No anti-nuclear antibodies or antibodies to extractable DNA antigens were detected. Imaging studies showed evidence of chronic paranasal sinusitis but no evidence of superior vena cava syndrome. A skin biopsy from the submandibular area showed dermal edema, telangiectasia, and mild perifollicular inflammation; this was interpreted as most consistent with solid facial edema or a rosacea variant. However, there was no clinical history of rosacea or severe acne.

Lisinopril-associated angioedema also had been considered, but symptoms had progressively worsened for 9 months after the medication was stopped. Allergen testing showed some low-grade contact reactions to several environmental antigens, including hydroxy-methoxy-benzophenone, lanolin, dust mite, mouse-derived products, and oxybenzone. However, he did not respond to antihistamines. There was no improvement after oral antibiotics and hydroxychloroquine, but prednisone (5-20 mg per day) had resulted in temporary relief.

He was subsequently referred to the university medical center for dermatology consultation. A computed tomography (CT) scan of the head and neck showed diffuse and extensive soft tissue edema as well as skin thickening involving neck, scalp, and face, of unclear etiology. As such, the initial differential diagnosis was broad, including infectious, inflammatory, and neoplastic etiologies. The patient remained afebrile with no leukocytosis or signs of infection. Normal anti-streptolysin O (ASO) and streptozyme titers argued against a variant of streptococcal lymphangitis. HIV, syphilis, and filariasis serologic studies were also negative. A negative C1 esterase inhibitor test ruled out hereditary angioedema, but did not exclude environmental substances in his new apartment as potential contributing factors.

Skin biopsies (6 mm punch) were obtained from the right cheek and right lateral neck. The right cheek sections showed an ill-defined proliferation of dissecting blood vessels and slit-like spaces lined by plump, pleomorphic, mitotically active, hyperchromatic endothelial cells throughout the dermis with extension into the subcutaneous fat (Figure 2). Extra-vascular aggregates and cords of similar appearing atypical cells were also apparent. To a lesser extent, the biopsy from the right lateral neck focally showed similarly pleomorphic, atypical hyperchromatic cells arranged as solid cords dissecting the collagen bundles at the interface between the reticular dermis and sub-cutis. Immunohistochemically, the atypical cells exhibited strong CD31 and CD34 immunoreactivity indicative of endothelial differentiation (Figure 3). Immunohistochemical stains for cytokeratins AE1/AE3, CD20, CD3, CD30, CD45, myeloperoxidase, and S100 proteins were negative excluding a wide range of non-vascular neoplasms. An immunohistochemical stain for Human Herpes virus type 8 was negative arguing against Kaposi sarcoma. The final pathologic diagnosis was angiosarcoma, moderately to poorly differentiated.

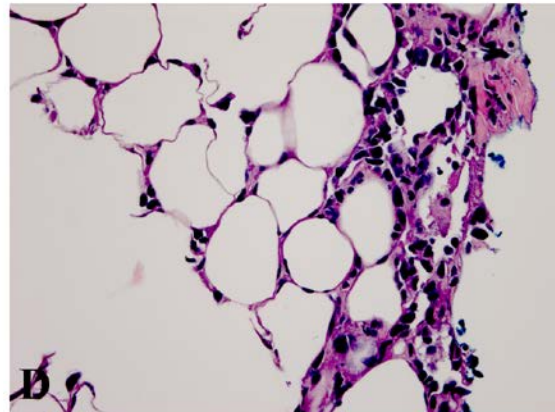
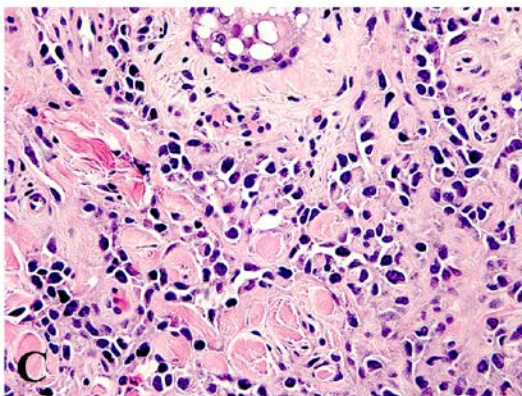
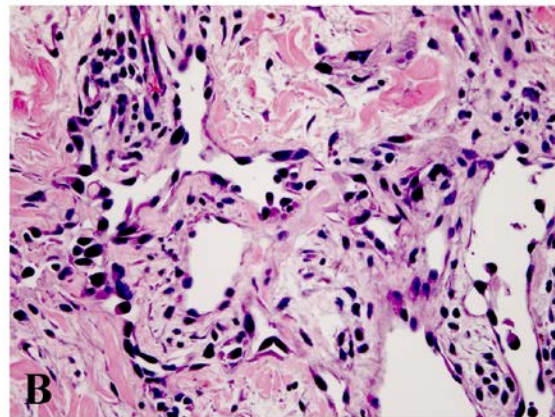
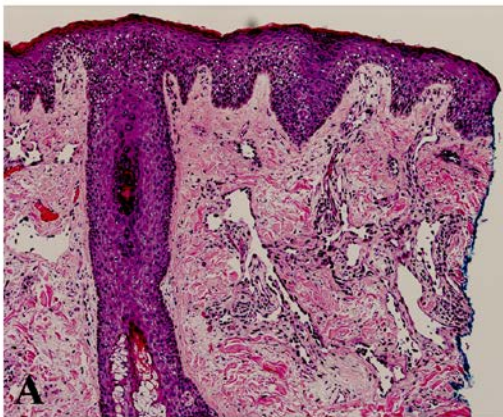


Figure 2. Histopathology of angiosarcoma. (A) Low-power view of irregular anastomosing vessels in the superficial dermis. (B) Irregular vessels lined by enlarged, hyperchromatic endothelium. (C) Reticular dermis with cords of atypical cells and slit-like spaces dissecting between collagen bundles. (D) Atypical cells extending into the subcutaneous fat. (A–D: hematoxylin and eosin).

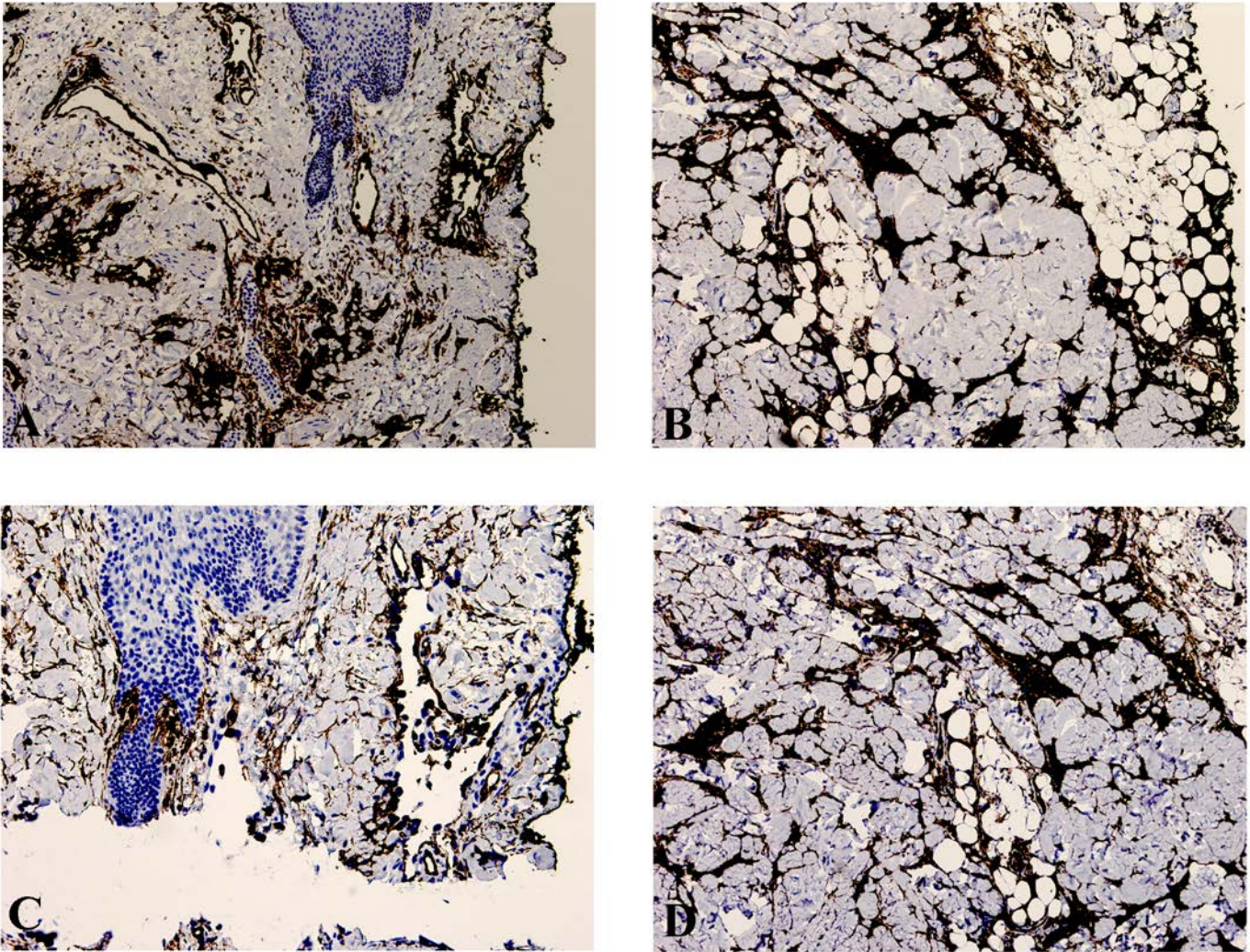


Figure 3. Immunohistochemical features of angiosarcoma. The tumor cells strongly express the endothelial cell markers, CD31 (A–B) and CD34 (C–D).

CT scans showed multiple bilateral pulmonary nodules and a lytic T6 vertebra lesion consistent with metastases; no other abdominal, pelvic, or brain masses were identified. Because of the diffuse involvement of the skin on the entire head and neck, neither surgical resection nor radiation therapy would have been feasible. Given the probable distant metastases, the recommendation was for single agent chemotherapy (paclitaxel) administered at a dose of 80 mg/m² on days 1, 8, and 15 of a 4-week cycle, with completion of at least 2 cycles before assessment of response. Anti-VEGF (vascular endothelial growth factor) biologic therapy was also considered but was not feasible owing to its high monetary cost. In the meantime, after a 5-day course of methylprednisolone at a dose of 1000 mg per day, his facial edema and erythema partially decreased, enabling him to open his left eye spontaneously (Figure 4). However, no significant reduction of skin hardness was achieved, particularly on his posterior neck and scalp. On his hospital day seven, he was discharged and returned to Alaska to receive chemotherapy near his home. Initially, he reported further improvement such that he was able to open both eyes spontaneously. However, at last contact, approximately 7 months after diagnosis, his facial edema had recently worsened, a right neck mass lesion was seen by CT scan, and he was hospitalized for evaluation of worsening dyspnea.

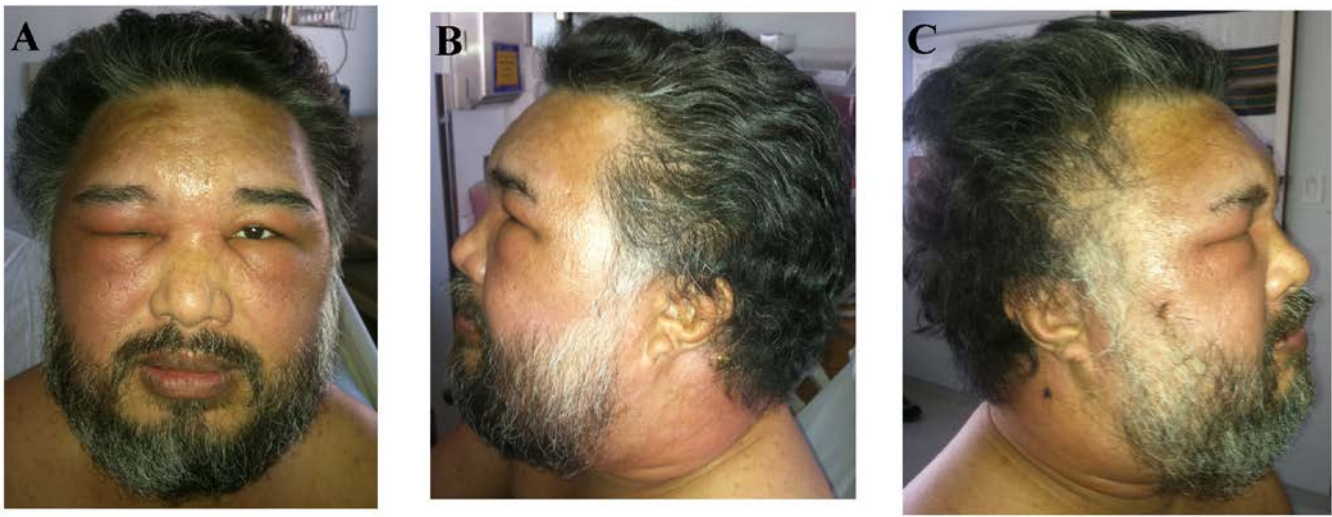


Figure 4. Partial clinical improvement after five days of methylprednisolone, 1000 mg per day, with diminished edema in the face and eyelids; the patient was able to open his left eye spontaneously.

Discussion

Although early clinicopathologic studies of cutaneous angiosarcoma of the head and neck alluded to cases "presenting with facial edema" [3, 10], well-documented cases presenting with facial edema unaccompanied by typical clinical findings of angiosarcoma are sparse. Tay and Ong described a 54-year-old man with a 6-month history of recurrent, episodic swelling of the scalp, eyelids, and face [9]. The edema came and went and was worse in the morning with resolution in the evening. Four months after the onset, he presented to the emergency department with difficulty breathing owing to laryngeal edema. His facial edema had persisted and a diagnosis of angioedema was made. A CT scan of the head revealed extensive soft tissue swelling of the scalp and face. Treatment with corticosteroids and hydroxyzine produced symptomatic improvement but no resolution of his facial edema. He was referred to the National Skin Centre where a skin biopsy of the scalp established the diagnosis of angiosarcoma. He received three cycles of chemotherapy followed by radiotherapy, which led to remission, though the follow-up interval was not specified in this report.

Mackenzie et al also reported a 67-year-old man with a history of fluctuating angioedema of the eyelids, which resolved and recurred spontaneously for 27 years before the edema became persistent [8]. The dermatologic diagnosis was angioneurotic edema, which was supported by a skin biopsy that showed only dermal edema. Despite plastic surgery, his eyelid edema progressed and 3 years later, two nodules appeared on his face that did not respond to corticosteroids or antibiotics. Skin biopsy of the eyelid showed angiosarcoma. Radiation therapy led to marked improvement. However, he developed multiple vertebral bone metastases and died soon thereafter.

In contrast to the above case reports [8, 9], the facial edema of the currently reported patient had progressed steadily over a relatively short 11-month interval extensively involving his entire face, scalp, neck, and bilateral eyelids, preventing him from opening his eyes fully. His clinical presentation resembled that of solid facial edema without any characteristic features of cutaneous angiosarcoma such as discrete masses or hemorrhagic-appearing, bruise-like areas.

For patients with clinically localized disease, surgical excision has long been the mainstay of treatment. Nevertheless, angiosarcoma often permeates tissue far more widely than is clinically apparent, making complete surgical extirpation with negative margins difficult to achieve. Local control and survival are improved with post-operative radiation [1, 2]. Thus, surgical excision followed by post-operative, wide-field radiotherapy is generally recommended for initial management of localized disease.

Angiosarcoma is considered to be only modestly responsive to chemotherapy, which is usually reserved for patients with metastatic or locally advanced disease. In such patients, doxorubicin and weekly paclitaxel have been associated with improved progression-free survival [2, 11]. Nevertheless, there are only anecdotal reports of complete remissions of radiation resistant, inoperable, or metastatic angiosarcoma after treatment with liposomal doxorubicin, paclitaxel, or a combination of the latter with sorafenib [12-14]. Also, there is some recent evidence suggesting that anti-angiogenic biologic agents may have a role in the treatment of patients with metastatic angiosarcoma [2, 15].

In conclusion, we report a rare case of cutaneous angiosarcoma presenting as progressive solid facial edema, underscoring the diverse range of clinical presentations associated with this neoplasm. Angiosarcoma should be included in the differential diagnosis of facial edema and skin biopsies should be considered in patients with unexplained, refractory facial edema.

References

1. Mark RJ, Poen JC, Tran LM, Fu YS, Juillard GF. Angiosarcoma. A report of 67 patients and a review of the literature. *Cancer*. 1996 June;77(11):2400-2406. [PMID: 8635113]
2. Penel N, Marréaud S, Robin YM, Hohenberger P. Angiosarcoma: state of the art and perspectives. *Crit Rev Oncol Hematol*. 2011 Nov;80(2):257-263. [PMID: 21055965]
3. Holden CA, Spittle MF, Jones EW. Angiosarcoma of the face and scalp, prognosis and treatment. *Cancer*. 1987 Nov;59(5):1046-1057. [PMID: 3815265]
4. Mentzel T, Kutzner H, Wollina U. Cutaneous angiosarcoma of the face: clinicopathologic and immunohistochemical study of a case resembling rosacea clinically. *J Am Acad Dermatol*. 1998 May;38(5 Pt 2):837-840. [PMID: 9591798]
5. Aguila LI, Sánchez JL. Angiosarcoma of the face resembling rhinophyma. *J Am Acad Dermatol*. 2003 Sep;49(3):530-531. [PMID: 12963925]
6. Papalas JA, Manavi CK, Woodward JA, Sanguenza OP, Cummings TJ. Angiosarcoma of the eyelid: a clinicopathologic comparison between isolated unilateral tumors and tumors demonstrating extrapalpebral involvement. *Am J Dermatopathol*. 2010 Oct;32(7):694-699. [PMID: 20559124]
7. Murray S, Simmons I, James C. Cutaneous angiosarcoma of the face and scalp presenting as alopecia. *Australas J Dermatol*. 2003 Nov;44(4):273-276. [PMID: 14616495]
8. Mackenzie IJ. Angiosarcoma of the face. *Arch Dermatol*. 1985 Apr;121(4):549-550. [PMID: 4038865]
9. Tay YK, Ong BH. Cutaneous angiosarcoma presenting as recurrent angio-oedema of the face. *Br J Dermatol*. 2000 Dec;143(6):1346-1348. [PMID: 11122065]
10. Jones EW. Dowling oration 1976. Malignant vascular tumours. *Clin Exp Dermatol*. 1976 Dec;1(4):287-312. [PMID: 793743]
11. Penel N, Bui BN, Bay JO, Cupissol D, Ray-Coquard I, Piperno-Neumann S, Kerbrat P, Fournier C, Taieb S, Jimenez M et al. Phase II trial of weekly paclitaxel for unresectable angiosarcoma: the ANGIOTAX Study. *J Clin Oncol*. 2008 Nov;26(32):5269-5274. [PMID: 18809609]
12. Donghi D, Dummer R, Cozzio A. Complete remission in a patient with multifocal metastatic cutaneous angiosarcoma with a combination of paclitaxel and sorafenib. *Br J Dermatol*. 2010 Mar;162(3):697-699. [PMID: 20030640]
13. Eiling S, Lischner S, Busch JO, Rothaupt D, Christophers E, Hauschild A: Complete remission of a radio-resistant cutaneous angiosarcoma of the scalp by systemic treatment with liposomal doxorubicin. *Br J Dermatol*. 2002 Jul;147(1):150-153. [PMID: 12100199]
14. Gambini D, Visintin R, Locatelli E, Galassi B, Bareggi C, Runza L, Onida F, Tomirotti M: Paclitaxel-dependent prolonged and persistent complete remission four years from first recurrence of secondary breast angiosarcoma. *Tumori*. 2009 Nov-Dec;95(6):828-831. [PMID: 20210253]
15. Park MS, Ravi V, Araujo DM. Inhibiting the VEGF-VEGFR pathway in angiosarcoma, epithelioid hemangioendothelioma, and hemangiopericytoma/solitary fibrous tumor. *Curr Opin Oncol*. 2010 Jul;22(4):351-355. [PMID: 20485168]