

UC Irvine

UC Irvine Previously Published Works

Title

Feasibility study for robotic radical prostatectomy cautery-free neurovascular bundle preservation

Permalink

<https://escholarship.org/uc/item/2vg2v4gd>

Journal

Urology, 65(5)

ISSN

0090-4295

Authors

Eichel, L
Chou, D
Skarecky, D W
et al.

Publication Date

2005-05-01

Peer reviewed

Feasibility Study for Robotic Radical Prostatectomy Cautery Free Neurovascular Bundle Preservation

Louis Eichel, M.D., David Chou, M.D., Douglas W. Skarecky, B.S.,
and Thomas E. Ahlering, M.D.,

Department of Urology, University of California (Irvine) Medical Center, Orange, CA.

Key Words: prostatectomy, robotic, cautery, neurovascular bundle

Urology 65(5): 994-998, +video, May 2005

Introduction.

Efforts continue to develop techniques that maintain the neurovascular bundles and minimize trauma for robotic laparoscopic radical prostatectomy (RLP). We evaluate the feasibility of preserving the nerve bundles without cautery or surgical clips.

Technical Considerations.

The seminal vesicles are dissected using scissors and bipolar cautery. After the rectum has been mobilized, the vascular pedicles (VP) are delineated. Laparoscopic bulldog clamps (30mm) are placed at least one cm from the prostate. Using scissors the VP are divided right at the prostate. The NVB is gently dissected off of the prostatic capsule. After mobilizing the bundle, FloSeal™ is applied along its entire length. The FloSeal is then covered with a dry 1 X 4 cm sheet of Gelfoam. Once the prostate is removed, the bulldogs are sequentially withdrawn. The VPs are observed and if pulsatile bleeding is encountered a 3-0 figure of 8 suture is precisely placed for hemostasis. When hemostasis is complete the anastomosis is performed.

Results

In 17 men, temporary vascular occlusion was applied to 27 VP and FloSeal and Gelfoam was applied each time. In four cases (15%) hemostasis was inadequate due to continued arterial bleeding, and were easily controlled with a superficial figure of eight ligature of 3.0 absorbable suture; average EBL was 91cc (range 75-150cc).

Conclusions

Cautery free, clip free, nerve-sparing RLP is feasible using a combination of temporary occlusion of the thick posterior prostatic pedicles with bulldog clamps followed by application of FloSeal. Effect on potency needs further follow-up.

Introduction

The anatomic basis for erectile dysfunction and the technique for nerve sparing radical retropubic prostatectomy was first

described by Walsh and Donker in 1982.¹ In that paper the authors described the tortuous path of the parasympathetic nerves that run from the pelvic plexus past the tips of

the seminal vesicles along side the rectum and then along the posterolateral aspect of the prostate between the true capsule and the lateral prostatic fascia finally piercing the urogenital diaphragm just posterior and lateral to the urethra. With the widespread popularization of this knowledge a major emphasis has been placed on cavernous nerve preservation in appropriately selected patients.

Numerous techniques for nerve preservation have been developed over the past 20 years.¹⁻¹⁰ Originally, emphasis was placed on proper anatomic dissection starting at the apex of the gland and working retrograde. Avoidance of trauma to the neurovascular bundle (NVB) by using bipolar cautery or surgical clips and operative magnification became popular methods for open and laparoscopic prostatectomy alike. In fact, a recent canine study suggests that the use of monopolar, bipolar, and harmonic energy for nerve dissection during radical prostatectomy appears to cause significantly more injury to cavernosal function postoperatively.¹¹ In our attempts to improve our technique for RLP we concentrated on a means to reduce or eliminate the potentially injurious effects of electrocautery on the NVBs. We considered techniques for partial nephrectomy where the vascular supply is temporarily occluded¹², the tumor excised and bleeding then controlled with hemostatic agents such as Floseal™(Baxter, Irvine, CA) and Gelfoam or suture ligature avoiding electrocautery. Herein, we describe our technique and report the

feasibility of cautery and clip free preservation of the NVBs.

Methods

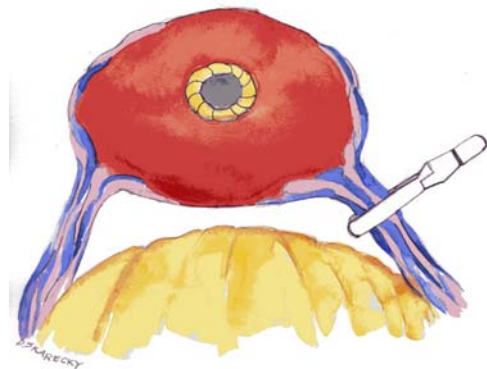
Patient Population:

All procedures were performed robotically by a single surgeon (TA). Men were selected for excision of one or both neurovascular bundles if the patient had extensive involvement noted on biopsy cores (>50% by volume estimate and/or Gleason score >4+3), obvious palpable disease (with biopsy confirmation), inadequate sexual function (SHIM<10) or patient preference. Group 1 patients (case #'s 101-125) consisted of men who underwent NVB preservation (Bilateral=14 and Unilateral=10) utilizing our standard technique of scissors and judicious bipolar electrocautery. Group 2 (case #'s 126-150) consisted of men who underwent NVB preservation (Bilateral=10 and Unilateral=7) utilizing the new technique of temporary vascular occlusion and hemostatic agents without the use of electrocautery or clips. Standard clinical characteristics were recorded prospectively and entered into an electronic database. In particular we focused on estimated blood loss, change in hemoglobin and intraoperative and postoperative complications. A postoperative complication was defined as the need for emergent return to the OR, prolonged hospitalization greater than 48 hours or the need for re-intervention or hospitalization within 30 days of surgery. Operative complications attributable to the technique, such as bleeding, hematuria, pelvic hematoma or abscess, etc were also noted. All

statistical comparisons between the groups were two-sided using Fisher's exact test and the Student t-test for means (SAS 8.2 statistical package).

Operative Technique:

After dividing the posterior bladder neck, the ampula of each vas is isolated and dissected until the tip of the seminal vesicle is exposed. The seminal vesicles are dissected using scissors and judicious use of bipolar cautery. Denonvillers fascia is entered in the midline and the rectum is mobilized to the level of the apex of the prostate. This delineates the prostatic vascular pedicles. Laparoscopic bulldog clamps (30mm) are placed on the vascular pedicles at least one centimeter from the prostate (Figure 1). From this



point, only scissors are used to divide the vascular pedicles very close to the prostate. The lateral prostatic fascia is incised along the prostate and the NVB is gently

dissected off of the prostatic capsule. After completely mobilizing the neurovascular bundle down to the urethra, FloSeal™ (Baxter, Irvine, CA) is applied along the entire length of NVB. The FloSeal is then covered with a dry 1 X 5 cm sheet of Gelfoam™ (Pfizer, NY, NY). This acts as a protective cover to keep the FloSeal particles in place. After the prostate is removed and the surgical field is clear the bulldog clamps are sequentially removed. The vascular pedicles are observed for pulsatile bleeding and if this is encountered the Gelfoam cover is elevated to expose the arterial stump and a 3.0 figure of 8 ligature of absorbable suture is precisely placed for control. The Gelfoam is replaced and the anastomosis performed.

Results

Group 1 patients (undergoing our standard technique with bi-polar electrocautery) had nearly identical clinical characteristics as Group 2 patients (Table 1). Additionally, blood loss and complications were very similar. Neither group required a transfusion or suffered from postoperative delayed bleeding.

Eight of the Group 2 patients did not have temporary vascular occlusion due to the need to perform a wide excision of both NVBs or preoperative impotence. Table 2 lists pertinent findings between these subgroups. The temporary vascular occlusion group patients were significantly younger and had significantly better baseline sexual function. In this group, 10 patients had bilateral temporary occlusion and bilateral nerve preservation and 7 had unilateral temporary occlusion and unilateral nerve preservation.

As noted there was no difference in blood loss or complications.

In Group 2, temporary vascular occlusion was applied to 27 vascular pedicles and FloSeal and Gelfoam was applied each time. In four cases (15%) hemostasis was inadequate due to continued arterial bleeding. All four bleeding vessels were easily controlled with a superficial figure of eight ligature of 3.0 absorbable sutures; of these patients three had EBLs of 75 cc and the remaining EBL was 150 cc.

Discussion

The object of nerve sparing radical prostatectomy is to remove the prostate and seminal vesicles without injuring the delicate neurovascular bundles. The mainstay to nerve preservation is avoidance of nerve transection followed by reduction of traumatic injury. Monopolar electrocautery is known to cause significant thermal and electrical injury to adjacent tissue. Techniques such as bi-polar electrocautery, Harmonic Scalpel™ and Ligasure™ have been introduced in an attempt to reduce thermal injury. These forms of energy reduce thermal injury by simplifying the transmission of energy between two relatively close applicators. Ideally it would be best to avoid thermal energy and just simply cut the vessels. However, with laparoscopic surgery vision is critical and even relatively small amounts of bleeding are not tolerable. Borrowing on the concept of temporary vascular occlusion advocated in partial nephrectomy¹² we elected to test the feasibility of temporary vascular occlusion of the

prostatic vascular blood supply. The video clip demonstrates that bleeding is controlled nicely facilitating accurate transection of the vascular pedicle and dissection of the NVB.

Drawing further on the experience extant with partial nephrectomy we also tested the efficiency of hemostatic agents to control bleeding along the vascular pedicle and NVB. Experience with gelatin matrix hemostatic sealants in the urologic literature is growing. Richter and associates showed improvement of hemostasis in open and laparoscopic partial nephrectomy using a gelatin matrix-thrombin tissue sealant¹³. In their series, 25 patients underwent partial nephrectomy followed by FloSeal application to the tumor bed before re-perfusion of the kidney. No additional attempts at hemostasis were made. They and others¹⁴ have concluded that gelatin matrix provided durable hemostasis following partial nephrectomy. Lee and associates have also described a technique highly dependent on the hemostatic benefits of FloSeal for tubeless percutaneous nephrolithotomy.¹⁵ The benefits of FloSeal and Gelfoam has also been demonstrated in cardiac¹⁶ and vascular surgery.¹⁷

On four occasions (15%) we noted that after removal of the bulldog clamps there was pulsatile bleeding. Peeling the Gelfoam back and suture ligating the specific bleeding artery or arteries easily controlled the bleeding. Once ligated, the FloSeal provided satisfactory hemostasis for the remainder of the NVB.

One potential criticism might be the crushing effect of the bulldog clamp on the NVB. However these clamps are designed for atraumatic control of arteries and veins. Further, the thick posterior pedicles are larger and more bulky which should serve to protect the nerve bundles. In fact, during dissection, the pedicles continue to ooze which would imply that vascular compression is not complete. Hence, the amount of pressure applied is not excessive. Another potential criticism is that the hemostatic agents might be toxic to the nerves. However, to date there is no clinical or experimental information indicating that hemostatic agents are toxic.

This series only represents the description of our technique for cautery free, laparoscopic, nerve sparing radical prostatectomy. The technique appears to be safe as no postoperative bleeding events were encountered. There is no inclusion of follow up data on potency as it is too early in the postoperative period to assess this in this group of patients.

Conclusion

Cautery and clip free nerve sparing RLP is feasible using a combination of temporary occlusion of the prostatic vascular pedicles with bulldog clamps followed by application of hemostatic agents. Follow up studies to evaluate the efficacy of this technique with regard to postoperative potency are required.

References

1. Walsh PC, Donker PJ. Impotence following radical prostatectomy: insight into etiology and prevention. *J Urol* **128**:492-497, 1982.
2. Catalona WJ. Nerve-sparing radical retropubic prostatectomy. *Urol Clin North Am* **12**:187-199, 1985.
3. Walsh PC, Mostwin JL. Radical prostatectomy and cystoprostatectomy with preservation of potency. Results using a new nerve-sparing technique. *Br J Urol* **56**:694-697, 1984.
4. Kursh ED, Bodner DR. Alternative method of nerve-sparing when performing radical retropubic prostatectomy. *Urology* **32**:205-209, 1988.
5. Drew JB, Begun FP, Jacobs SC. Doppler-assisted nerve-sparing radical prostatectomy. *Urology* **33**:228-229, 1989.
6. Petros JA, Catalona WJ. Antegrade approach to radical retropubic prostatectomy in patients with difficult apical dissection. *J Urol* **145**:994-997, 1991.
7. Ruckle HC, Zincke H. Potency-sparing radical retropubic prostatectomy: a simplified anatomical approach. *J Urol* **153**:1875-1877, 1995.
8. Klotz L. Advances in nerve sparing for radical prostatectomy. *Urology* **54**:956-959, 1999.
9. John H, Hauri D. Seminal vesicle-sparing radical prostatectomy: a novel concept to restore early urinary continence. *Urology* **55**:820-824, 2000.

10. Chang DW, Wood CG, Kroll SS, *et al*: Cavernous nerve reconstruction to preserve erectile function following non-nerve-sparing radical retropubic prostatectomy: a prospective study. *Plast Reconstr Surg* **111**:1174-1181, 2003.
11. Ong AM, Su LM, Varkarakis L, *et al*: Nerve sparing radical prostatectomy: Effects of hemostatic energy sources on the recovery of cavernous nerve function in a canine model. *J Urol Suppl* **171**: page **284** Abstract# 1076, 2004.
12. Gill IS, Desai MM, Kaouk JH, *et al*: Laparoscopic partial nephrectomy for renal tumor: duplicating open surgical techniques. *J Urol* **167**(2 Pt 1):469-467; discussion 475-466, 2002.
13. Richter F, Schnorr D, Deger S, *et al*: Improvement of hemostasis in open and laparoscopically performed partial nephrectomy using a gelatin matrix-thrombin tissue sealant (FloSeal). *Urology* **61**:73-77, 2003.
14. User HM, Nadler RB. Applications of FloSeal in nephron-sparing surgery. *Urology* **62**:342-343, 2003.
15. Lee DI, Uribe C, Eichel L, *et al*: Sealing percutaneous nephrolithotomy tracts with gelatin matrix hemostatic sealant: initial clinical use. *J Urol* **171**(2 Pt 1):575-578, 2004.
16. Oz MC, Cosgrove DM, 3rd, Badduke BR, *et al*. Controlled clinical trial of a novel hemostatic agent in cardiac surgery. The Fusion Matrix Study Group. *Ann Thorac Surg* **69**:1376-1382, May 2000.
17. Weaver FA, Hood DB, Zatina M, *et al*:. Gelatin-thrombin-based hemostatic sealant for intraoperative bleeding in vascular surgery. *Ann Vasc Surg* **16**:286-293, 2000.

Table 1.

Clinical characteristics and outcomes of our standard technique (Group 1) versus temporary vascular occlusion (Group 2).

Clinical Factor	Group 1	Group 2	p-value
Case #'s	101-125	126-150	
Age (years)	62.3 (46-75)	61.1 (44-78)	NS
BMI	26.8 (21.7-30.4)	26.7 (21.6-34)	NS
Preop PSA	6.0 (1.4-19.9)	6.1 (1.9-22.8)	NS
AUA symptom score	8.2 (0-24)	8.9 (1-21)	NS
SHIM	18.0 (1-25)	17.4 (1-25)	NS
Estimated blood loss (cc)	90 (25-250)	90 (25-200)	NS
Postop Hgb change (g/dl)	-1.2 (-3.5-1.3)	-1.1 (-4.2-0.8)	NS
Hospital stay (hrs)	27.8 (24-48)	28.3 (24-96)	NS
Complications (%)	1/25 (4%)	2/25 (8%)	NS
Positive Surgical Margins (%)	5 (20%)	3 (15%)	NS

Table 2.

Subset comparison of clinical characteristics and outcomes of patients in Group 2 that had temporary vascular occlusion (Bulldog) versus none.

Clinical Factor (means)	Bulldog	No Bulldog	p-value
	N=17	N=8	
Age (years)	58.1 (44-69)	67.5 (57-78)	.006
BMI	25.2 (21.6-32.3)	28.2 (25.2-34)	.02
PreOP PSA	5.2 (3-8.6)	8.1 (1.9-22.8)	.08
AUA symptom score	8.7 (1-21)	9.4 (1-17)	.79
SHIM	20.8 (11-25)	11.6 (1-25)	.005
Estimated blood loss (cc)	91 (25-250)	88 (25-200)	.81
Postop Hgb change (g/dl)	-1.6 (-0.8-4.2)	-1.9 (1.1-2.5)	.70
Positive Surgical Margins (%)	1	2	NS