

UC Irvine

UC Irvine Previously Published Works

Title

A brief human history of ankylosing spondylitis: A scoping review of pathogenesis, diagnosis, and treatment

Permalink

<https://escholarship.org/uc/item/2sh9b02p>

Authors

Murphy, Sierra N
Nguyen, Brandon A
Singh, Rohin
et al.

Publication Date

2022

DOI

10.25259/sni_294_2022

Copyright Information


This work is made available under the terms of a Creative Commons Attribution License, available at <https://creativecommons.org/licenses/by/4.0/>

Peer reviewed



Review Article

A brief human history of ankylosing spondylitis: A scoping review of pathogenesis, diagnosis, and treatment

Sierra N. Murphy¹, Brandon A. Nguyen¹, Rohin Singh¹, Nolan J. Brown², Shane Shahrestani³, Matthew T. Neal³, Naresh P. Patel³, Maziyar A. Kalani³ 

¹Mayo Clinic Alix School of Medicine, Mayo Clinic, Scottsdale, Arizona, ²Department of Neurosurgery, UC Irvine, Orange, California, ³Department of Neurosurgery, Mayo Clinic, Phoenix, United States.

E-mail: *Sierra N. Murphy - murphy.sierra@mayo.edu; Brandon A. Nguyen - nguyen.brandon@mayo.edu; Rohin Singh - singh.rohin@mayo.edu; Nolan J. Brown - nolanb@hs.uci.edu; Shane Shahrestani - shanesha@usc.edu; Matthew T. Neal - neal.matthew@mayo.edu; Naresh P. Patel - patel.naresh@mayo.edu; Maziyar A Kalani - kalani.mazi@mayo.edu



*Corresponding author:

Sierra N. Murphy,
Mayo Clinic Alix School
of Medicine, Mayo Clinic,
Scottsdale, Arizona, United
States.

murphy.sierra@mayo.edu

Received : 29 March 2022

Accepted : 21 May 2022

Published : 15 July 2022

DOI

10.25259/SNI_294_2022

Quick Response Code:



ABSTRACT

Background: Ankylosing spondylitis (AS) is a chronic, progressive, inflammatory disease of the spine and SI joints. Diagnostic criteria and treatments have continued to evolve, necessitating a historical compendium of AS and its management. This paper aims to review the historical context underlying the discovery of AS, as well as the major diagnostic and therapeutic discoveries in the last two centuries.

Methods: A scoping review of the literature pertaining to AS was performed via the Pubmed, Scopus, and Web of Science databases. Future directions of AS treatments were assessed by querying the clinicaltrials.gov website.

Results: The history of AS can be traced as far back as ancient Egypt (as evidenced by the discovery of its presence in ancient Egyptian mummies) to the late 20th century, when the inherited nature of AS was linked to a genetic factor, HLA-B27. Each discovery made throughout the years led to further investigations into the pathophysiology, diagnosis, and treatment of AS. The criteria to differentiate AS from rheumatoid arthritis were first reported in 1893. Since then, diagnostic criteria for AS have undergone a series of changes before the present-day diagnostic criteria for AS were ultimately determined in 2009 by the Assessment of Spondyloarthritis International Society.

Conclusion: As the pathophysiology of AS is better understood, healthcare providers are able to diagnose and treat the condition more effectively. In particular, earlier diagnosis and multiple treatment options have facilitated efficient and more effective treatment.

Keywords: Ankylosing spondylitis, Bamboo spine, Bekhterev's disease, Spine, Spondyloarthritis

INTRODUCTION

Ankylosing spondylitis (AS) is a chronic, progressive, inflammatory disease of the spine and SI joints.^[53,75] It is a member of a wider class of spondyloarthropathies, specifically those with axial manifestations.^[24,75] With advanced disease, the ossification of the vertebral ligaments leads to fusion of the vertebral bodies and subsequent loss of spinal flexibility^[75] [Figure 1]. Individuals with AS often present with persistent lumbar back pain and stiffness between the

This is an open-access article distributed under the terms of the Creative Commons Attribution-Non Commercial-Share Alike 4.0 License, which allows others to remix, transform, and build upon the work non-commercially, as long as the author is credited and the new creations are licensed under the identical terms.

©2022 Published by Scientific Scholar on behalf of Surgical Neurology International

ages of 20 and 40 years.^[12,28,29] In addition, patients with AS can experience associated uveitis, sacroiliitis, osteoporosis, inflammatory bowel disease, and aortitis and are predisposed to complications, such as traumatic spinal fractures, spinal cord injury, and aortic valvular insufficiency^[16,19,28,58,68] [Figure 2]. As this is a severely debilitating disease, focus is maintained on the pathophysiology and potential therapies for this patient population.

The clinical characterization of AS is a result of centuries of observation and research. This paper aims to review the historical context underlying the discovery and characterization of AS, as well as discuss the development of diagnostic criteria and management of the disease in the last two centuries.

HISTORY OF DISEASE

Recent evidence suggests that AS was present in mummies recovered from ancient Egypt, dating to approximately

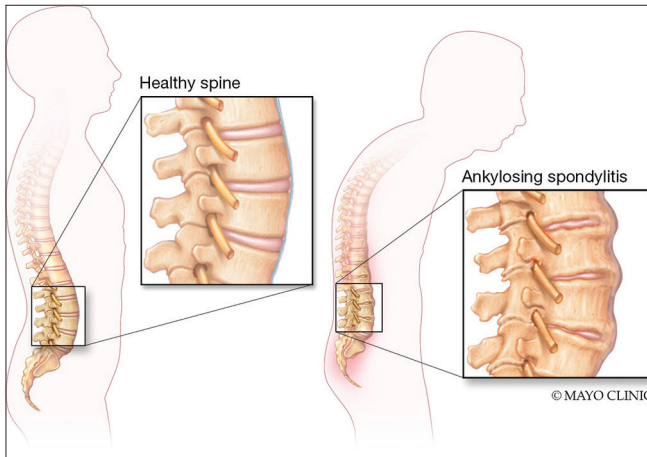


Figure 1: Depiction of ossification of vertebral ligaments leading to fusion of vertebral segments and significant increase of overall kyphosis.

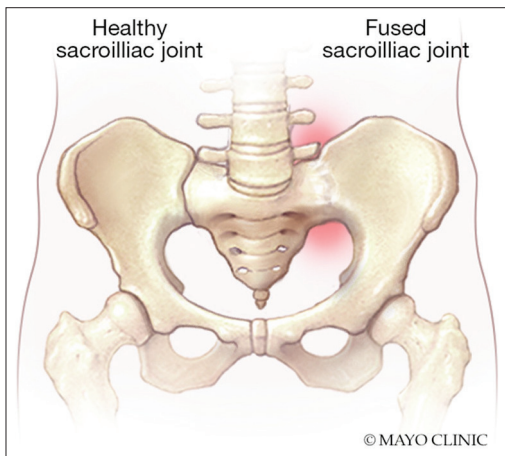


Figure 2: Comparison of healthy SI joint with fusion (ankylosis) of the SI joint with associated inflammation.

1500 B.C.^[23] The remains showed characteristic ossified paraspinous ligaments and obvious SI joint involvement consistent with the description of AS.^[23] Early written descriptions of spinal inflexibility and pain were made by Hippocrates (460 BC–370 BC) and neurologist Caelius Aurelianus (1400s), but could not reliably be determined to be AS.^[54] Irish physician Bernard Connor is believed to be the first to definitively detail the calcification of spinal ligaments, resulting in a fixed, fused spine.^[54] However, the symptomatology was considered a progression of rheumatoid arthritis (RA) until 1893, when prominent Russian neurologist Vladimir Bekhterev recognized AS as a distinct inflammatory disease.^[45] As such, the disease is classically referred to as Bekhterev’s disease.^[45] Of note, tracing the history of AS in written records is made difficult by the many names used for the condition.^[54] AS was officially identified and diagnosed by Adolph Strümpell in 1897 and Pierre Marie in 1898.^[11,36,57]

With the advent of radiographic technology in the 1800s, clinical symptoms could be correlated to image findings. Such findings were later described to include squaring of the lumbar spine, syndesmophyte formation, sacroiliitis, and the pathognomic bamboo spine^[17] [Figure 3]. CT imaging was utilized for studying AS by the 1980s.^[14,26] CT and magnetic resonance imaging (MRI) were both recognized to have increased detection of AS disease and significance in identifying early disease by 1990.^[31,35] Nowadays, these technologies remain crucial for the identification of AS and foundational in diagnostic criteria.

By the end of the twentieth century, the inherited nature of AS was linked to a genetic factor, HLA-B27. The overwhelming majority of patients with AS express HLA-B27, compared to a relatively infrequent incidence of HLA-B27 in the general population. A family study published in 1984 by van der Linden *et al.* found that the risk of AS is 16 times

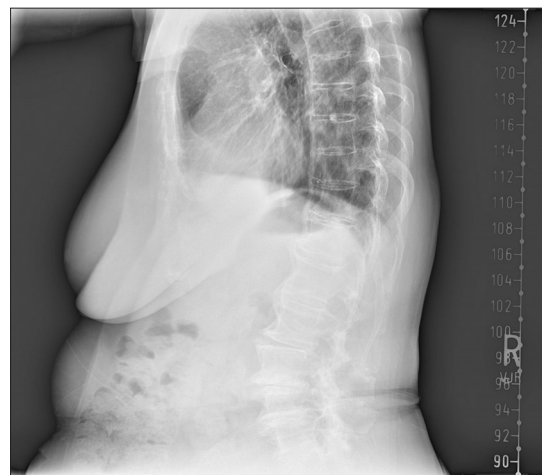


Figure 3: X-ray imaging of patient with AS and the pathognomic “bamboo spine.”

greater in relatives of AS patients expressing HLA-B27, when compared with HLA-B27-positive individuals in the general population.^[55,60,67] Gastrointestinal infection caused by *Klebsiella* was also determined to play a role in the development of AS in 1989. This connection between gut microbiome and AS was supported by the discovery of cross-reactivity between HLA-B27 and antigens found on *Klebsiella* and other gut microorganisms in addition to serological studies identifying antibodies against *Klebsiella* in active AS patients.^[18] These discoveries were a catalyst for further genetic and immunological studies.

EPIDEMIOLOGY

In 2016, the diagnostic prevalence of AS was reported to be 0.09% in the United States.^[69] Globally, estimates range from 0.1% to 1.4%, with large geographic variations that may be partially explained by demographics.^[17,56] A systematic review of literature conducted in 2014 revealed the prevalence of AS to be highest in North America, followed by Europe, Asia, Latin America, and Africa, respectively.^[17] A meta-analysis in 2016 revealed wide confidence intervals for regional prevalence, but generally supported that the lowest average prevalence of AS was in Africa and higher average prevalence could be seen in Northern Arctic communities, North America, and Europe.^[56]

Further analysis demonstrated that Caucasians have a higher prevalence in comparison to other races. Furthermore, Medicare patients were more represented than those with Medicaid or commercial insurance.^[42] Interestingly, AS is nearly twice as common in men than women, despite autoimmune conditions being more prevalent among females; more recent studies suggest a more equal distribution among sexes.^[40,69] The early discrepancy between the sexes is attributed in part to males having more severe radiographic findings, which were more easily detectable.^[6,71] Females with AS onset in the 1950s experienced a delay in diagnosis that averaged 15 years, but with more advanced imaging modalities, AS rates are equalizing among men and women.^[22] The accuracy of AS epidemiological data continues to improve alongside the diagnostic measures for the disease.

DIAGNOSIS

Although AS was likely recognized as distinct from RA before the 19th century, adequate criteria to differentiate the two diseases were first reported in 1893 by neurologist Vladimir Bekhterev. At the time, RA was diagnosed based on the following archetypal, clinical presentation: An insidious onset and gradual spread of painful joints, typically arising from the pollex, and associated with constitutional symptoms of fever and perspiration.^[4,33] In contrast, AS

was described according to spinal posture, inflexibility, and inflammation.^[45] This distinction spurred further efforts to characterize the disease for clinical use.

The Council for International Organizations of Medical Sciences further developed the criteria for diagnosis in 1961.^[59] To make a diagnosis of AS with this criteria, either radiographic sacroiliitis bilaterally with one clinical criterion, or four out of five clinical criterion must be met. The five possible clinical criteria include lumbar back pain lasting longer than 3 months and present at rest, pain and stiffness of the thoracic spine, decreased motion of the lumbar spine, diminished chest expansion, and iritis (either through history or examination).^[25]

Five years later, under the same council, the New York criteria were established.^[8] The major addition was that of sacroiliitis grading.^[25] With bilateral sacroiliitis of advanced grades 3 and 4, one clinical criterion is sufficient for diagnosis. Here, only three clinical criteria are recognized: (1) pain originating from the lumbar spine or dorsolumbar junction, (2) reduced mobility of the lumbar spine demonstrated upon examination in all three planes, and (3) observed chest expansion < 2.5 cm. However, if sacroiliitis is bilateral of grade 2, or unilateral of grade 3 or 4 — with grades 2, 3, and 4, corresponding to small regions of erosion or sclerosis, moderate or advanced sacroiliitis with partial ankylosis, and complete ankylosis, respectively — then either pain reported by patient or both physical exam findings are necessary for diagnosis.^[25]

Of note, a screening criteria for AS were developed based on clinical history in 1977 as described by Calin *et al.*^[12] If 4 of 5 criterion are met, AS is suspected and should be further explored with physician exam and radiographs. Radiographs are often able to detect structural damage associated with advanced AS, however, indicators of SI joint inflammation, one of the earliest manifestations of AS, are not visible.^[43] The screening test considers the following in a patient's history: (1) back pain before the age of 40, (2) gradual onset of back pain, (3) chronic nature of pain exceeding 3 months, (4) stiffness in the morning, and (5) relief with activity.^[25]

Nearly two decades of advancements led to the modification of the New York criteria in 1984, which were more inclusive. Bilateral sacroiliitis grade 2 and higher or unilateral sacroiliitis grade 3 and higher must be accompanied by at least one of the clinical criteria. As reported by patient, the lumbar back pain must be chronic (longer than 3 months) with relief upon exercise, but no subsidence with rest. Alternatively, physical examination must demonstrate reduced motion sagittally and frontally in the lumbar region or reduced chest expansion as compared to age- and sex-matched controls.^[25]

In 1990 and 1991, the Amor criteria and the European Spondyloarthropathy Study Group criteria were developed

for both axial and peripheral spondyloarthropathies but will not be discussed in detail due to their broader nature.^[51] Importantly, these criteria incorporate the genetic component of spondyloarthropathies through family history of related conditions or biomarker HLA-B27, as well as response to NSAIDs, into the preexisting framework for AS diagnosis.^[51]

Present-day diagnostic criteria for AS were determined by the Assessment of Spondyloarthritis International Society (ASAS) in 2009.^[51] The criteria take into consideration associated conditions, genetic biomarkers, response to NSAIDs, early signs of inflammation on MRI, and detailed information on clinical interpretations. In particular, MRI is able to detect inflammatory changes in the SI joints (including bone marrow edema and enhancement of the bone marrow and joint space with contrast administration) early in the disease process, in addition to the structural changes associated with advanced AS.^[43] These criteria are extensive and incorporate advances in imaging modalities and molecular genetics. Furthermore, ASAS unified and standardized the disease classification for more reliable use in clinical trials to judge the effectiveness of therapy by enrolling the proper patients. However, the ASAS criteria possess some limitations in sensitivity and specificity, as well as in the consistency of how images are interpreted.^[46] This framework continues to be analyzed, validated, and improved.^[46]

TREATMENTS

Physical therapy

Exercise is recognized as an alleviating factor in AS; activity-related improvement was even recognized as a characteristic of AS in diagnostic and screening criteria.^[7,37,41] A report in 1932 recommended physical therapy for AS in the form of breathing exercises.^[10] Home exercise programs may alleviate symptoms and improve general health and quality of life at no cost to patients, while therapy supervised by physical therapist represents a more costly option that is effective for patients with declining functionality and moderate or severe disease.^[40] Physical therapy, health education, posture education, and physical exercise programs typically improve function and pain in addition to general well-being by strengthening stabilizing muscles and reducing the load placed on the back.^[40,43] At present, physical therapy programs may also incorporate aquatic therapy and flexibility promoting exercises.^[21,37] Spa therapy and exercise in addition to anti-inflammatory medications and formal physical therapy was associated with significant improvement in function in a randomized control study, and aquatic physical therapy has been shown in meta-analyses to significantly reduce pain and disease activity.^[46,74] Although the methods have evolved, physical therapy is a mainstay of

treatment and prescribed to patients with AS. A summary of therapeutic options for AS can be found in Table 1.

Radiation therapy

In the early to mid-1900s, radiation therapy reportedly served as an effective means of symptom reduction.^[50] While different methods existed for radiation therapy in AS patients, treatment typically involved X-ray exposure at a predetermined dosage of the entire spine or the lower lumbar spine in addition to the SI joints, and was thought to reduce inflammatory activity in the bone and joints of the spine.^[49] Patients demonstrated substantially recovered flexibility in their spine and a considerable reduction in pain following radiation therapy.^[34,49] Radiation therapy did not alter the progression of the disease, but was heavily embraced for symptomatic benefit.^[34,49,50] Unfortunately, as secondary, long-term effects of radiation appeared, the treatment is no longer utilized.^[3,50] A study of nearly 15,000 patients treated with radiation therapy between the years 1935 and 1954 found an increased incidence of leukemia, aplastic anemia, and other cancers associated with the site of radiation.^[9] As such, radiation therapy is no longer pursued in AS.

Pharmacologic treatments

Salicin, and eventually its derivative salicylic acid, was developed in 1838; these are effective treatments in rheumatism, but unsuccessful in improving AS symptoms.^[50] The introduction of Aspirin in 1899 did not alleviate AS symptoms either, thus opioids were utilized for pain management.^[50] In 1949, phenylbutazone, a first generation NSAID, reduced symptoms and possibly slowed progression in AS patients.^[50] However, the hepatotoxicity and resulting anemia necessitated the use of NSAIDs with better safety profiles. Second generation NSAIDs were available starting in 1965 and showed comparable improvement in range of motion and pain to phenylbutazone with less severe adverse effects.^[50] In patients with inadequate response to NSAIDs, corticosteroids could be administered with caution due to long-term systemic effects.^[50] To date, intra-articular corticosteroids are routinely used with image guidance. Of note, disease modifying antirheumatic drugs (DMARDs), such as gold salts and antimalarials, were pursued from 1930 to 1990 without major effect in AS, serving as another point of distinction between RA and AS.^[50]

Within the last decade, immunomodulatory drugs, such as TNF- α inhibitors, have been incorporated in the management of AS. A study assessing use of TNF- α inhibitors in AS patients found significant evidence that patients on an TNF- α inhibitor were 3 to 4 times more likely than patients on a placebo to have at least a 40% improvement

in an overall assessment of patient-reported outcomes of AS symptoms.^[38] In patients with a positive HLA-B27 status and elevated CRP, better responses were observed with earlier TNF- α inhibitor administration.^[50] TNF- α inhibitors also help to mitigate osteoporosis and recovered bone mineral density.^[7] Another added benefit of TNF- α inhibitors is possibly reducing cardiovascular sequelae by decreasing microvascular dysfunction in AS patients.^[5] Unfortunately, such biologics are contraindicated in patients with certain active infections, heart failure, demyelinating disease, autoimmune diseases, or malignancies.^[50,70] Likewise, IL-17 inhibitors and monoclonal antibodies against interleukins have shown promising results.^[75] For example, Secukinumab demonstrated significant improvement in AS symptoms over the course of 52 weeks in a 226-patient study.^[44] This next generation of treatments is improving the lives of patients with AS and was made possible by the advances in genetics and immunology.

Surgical interventions

Nearly one third of patients with AS develop symptomatic kyphosis with positive sagittal balance, requiring osteotomies to improve function and decrease morbidity.^[75] Indications for surgery may, therefore, include degree of sagittal imbalance, chronic back pain, radiographic, and clinical features consistent with AS, and thoracolumbar kyphosis. Among these, kyphosis that limits horizontal gaze, standing upright, and lying flat was the most consistent indication for surgery.^[48]

The earliest account of surgical intervention in AS was reported in 1945, when six AS patients were operated on by Smith-Petersen.^[75] His technique would be called the opening-wedge osteotomy (OWO), which involved manually extending the lumbar spine by resecting the spinous process, pedicles, and facet joints at one level. The posterior osteotomy is then closed and the anterior column is fractured, leaving an open wedge in the anterior spine.^[15] Because of risk to neural and vascular structures, different techniques were explored. One approach, poly-segmental wedge osteotomy (PWO) developed by Wilson in 1949, involved performing multiple closing-wedge osteotomies (CWOs) at different levels.^[72] CWOs involve resection of a posterior wedge of the vertebral body in addition to the posterior elements of the spine. The osteotomies were closed and stabilized using Harrington rods, laminar hooks, and pedicle screws to achieve lumbar extension without fracture and creation of an open wedge.^[1,53] However, PWO was an unsuitable alternative due to increased failure rates. In 1963, Scudese and Calabro were among the first to advocate for singular CWO.^[75] This approach was subsequently improved by Ziwan and Thomassen in 1982 and 1985, respectively.^[61,76] As OWO and CWO became widely adopted, both techniques have improved to suggest no significant difference in neurologic

or vascular complications between them. However, while both procedures typically result in increased functionality and decreased symptoms, they each have limitations. CWO is a more complex procedure requiring more time and resources, while OWO carries a higher risk for paralytic ileus and delayed union.^[15]

Patient-reported outcomes are similar between OWO and CWO. Of note, approximately 88% of patients would still choose to undergo the surgery. Two years after the procedures, patients saw, on average, an improvement >60% in Oswestry Disability Index scores and Visual Analog Scale pain scores.^[48] Radiographic findings were also improved. At 5 years after surgery, the average kyphosis severity was decreased by 40° for CWO and 35° for OWO.^[48] Sagittal vertical axis and lumbar lordosis were also considerably corrected.^[48]

Lumbar osteotomies inspired cervical osteotomies in AS as early as 1958 by Urist.^[52,65] In 2001, Norio Kawahara pioneered the mixed-approach closing-opening wedge osteotomy, which combined the benefits of both CWO and OWO with fewer limitations.^[30] Nowadays, cervical osteotomies, too, are considered safe and effective treatments of AS.^[52]

Additionally, total hip arthroplasty (THA), which has been around since 1891 and modernized in the 1960s, has been performed in patients with AS with moderate effectiveness, but remains unsubstantiated by adequate trials.^[32,75] Regardless, 25–33% of AS patients may experience arthritis severe enough to consider such treatment.^[75] Promisingly, the number of AS patients seeking THA has decreased with earlier interventions.^[75]

As with most surgical interventions, these procedures carry risk of infection, vascular complications, repeat operation (e.g., in the event of hardware failure or nonunion), and other complications. Furthermore, patients with AS undergoing spine surgery are at a significantly increased risk of surgical site infection, respiratory failure, pneumonia, and acute renal failure postoperatively.^[47]

FUTURE DIRECTIONS

There continues to be investigations into more effective treatments for AS. Current clinical trials are evaluating the efficacy of Pell monoclonal antibodies, kinase inhibitors, and DMARDs.^[1,39,41,62] Other studies seek to discern the role of the microbiota in AS by altering the diet or pursuing a fecal transplantation.^[13,20,64] Physical therapy experiments observe the impact of tele-yoga and hippotherapy simulators on patient functionality.^[2,66] Novel surgical interventions, such as myofascial release and its effect on quality of life and disease activity, were also studied.^[63] The wide array of clinical trials for AS is a testament to the efforts being made and an insight into the possible medical advancements to come.

Table 1 : Therapeutic options for treatment of AS.

Treatment	Indications	Additional Considerations
Physical Therapy	Instructions for home exercises and on proper posture always indicated, formal physical therapy may improve function in independent and ambulatory patients, aquatherapy may improve symptoms in patients that can access the necessary facilities.	Home exercises and posture guidance are mainstays in treatment of AS, while other forms of physical therapy may be useful for patients with more severe disease that have access to these resources.
Radiation Therapy	Not indicated.	No longer used in treatment of AS due to side effects of radiation exposure.
Pharmacologic Treatments		
Phenylbutazone	No longer indicated, previously used to reduce pain and improve functionality in patients with AS.	Caused hepatotoxicity in some patients, no longer indicated due to second-generation NSAIDs with fewer side effects.
Second-Generation NSAIDs (such as Etolodac and Ibuprofen)	Reduces pain and improves functionality in patients with AS.	Equally effective as phenylbutazone with fewer side effects, commonly used in the treatment of AS. Different individuals may respond better to different NSAIDs.
Corticosteroids	May improve symptoms in patients that do not respond to NSAIDs.	Intra-articular administration using imaging guidance, associated with numerous side effects. Infection risk associated with injection.
TNF- α Inhibitors (such as Etanercept and Infliximab)	Improves symptoms and may delay disease progression.	Cost may be prohibitive, infection risk associated with injection.
Anti-IL-17 mAbs (Secukinumab)	Improves symptoms of AS.	Cost may be prohibitive, infection risk associated with injection.
Surgical Interventions		
PWO	No longer indicated.	Increased failure rates compared to OWO, CWO, and COWO.
OWO	Correction of kyphotic deformity, improvement of symptoms and functionality in patients with significantly reduced quality of life and moderate to severe AS.	Risks of implant failure, delayed union, and paralytic ileus, in addition to infection, vascular complications, repeat operation, and other complications related to surgery.
CWO		Longer procedure time and more bleeding with a reduced risk of implant failure, delayed union, and paralytic ileus compared to OWO.
COWO		More technically demanding, but better tolerated than OWO and CWO in AS patients.
THA	Improve symptoms of degenerative changes of the hip typically only found in advanced AS.	Technically challenging procedure, likelihood of THA decreases with earlier therapeutic intervention.
AS: Ankylosing spondylitis, PWO: Poly-segmental Wedge Osteotomy, OWO: Opening-wedge osteotomy, CWO: Closing-wedge osteotomies, COWO: Closing-opening wedge osteotomy, THA: Total hip arthroplasty		

Nanotechnology-based drug delivery approaches, such as liposomes, nanoparticles, and hydrogels, have gained popularity as a treatment route by reducing frequency of dosing and increasing retention of medications. One study on nanocurcumin suggested its ability regulate Th17 and possibly modulate disease symptoms in AS.^[27] Nanomedicine has been utilized in the treatment of autoimmune or inflammatory conditions, such as RA and OA, and thus show promise for application in AS as well.^[73]

CONCLUSION

This manuscript provides a brief overview highlighting the history and scientific advancements of AS. While many management strategies have persisted to the present day, such as the use of exercise and NSAIDs, other approaches, such as radiation therapy, have been abandoned. Refined diagnostic criteria and novel medical treatments facilitated early diagnosis and strategies to slow the progression of

the disease. Complex surgical techniques are available for refractory or end-stage cases.

Declaration of patient consent

Patient's consent not required as patient's identity is not disclosed or compromised.

Financial support and sponsorship

Nil.

Conflicts of interest

There are no conflict of interest.

REFERENCES

- AbbVie. A Multicenter, Randomized, Double-Blind, Placebo-Controlled Study Evaluating the Safety and Efficacy of Upadacitinib in Subjects with Active Ankylosing Spondylitis; 2021.
- Acar Y. The Effects of Tele-Yoga in Ankylosing Spondylitis Patients; 2021.
- Arthritis Research and Therapy National Research Foundation. A Spine of the Times A History of Ankylosing Spondylitis. Arthritis Research and Therapy National Research Foundation; 2020. Available from: <https://curearthritis.org/a-spine-of-the-times-a-history-of-ankylosing-spondylitis> [Last accessed on 2021 Sep 18].
- Balfour GW. On rheumatoid arthritis: Its diagnosis, pathology, and treatment. *Edinb Med J* 1876; 21:920-9.
- Batko B, Maga P, Urbanski K, Ryszawa-Mrozek N, Schramm-Luc A, Koziej M, et al. Microvascular dysfunction in ankylosing spondylitis is associated with disease activity and is improved by anti-TNF treatment. *Sci Rep* 2018;8:13205.
- Baumberger H, Khan MA. SAT0417 Gradual progressive change to equal prevalence of ankylosing spondylitis among males and females in switzerland: Data from the swiss ankylosing spondylitis society (SVMB). *Ann Rheum Dis* 2017;76:929.
- Beek KJ, Rusman T, van der Weijden MA, Lems WF, van Denderen JC, Konsta M, et al. Long-term treatment with TNF-alpha inhibitors improves bone mineral density but not vertebral fracture progression in ankylosing spondylitis. *J Bone Miner Res* 2019;34:1041-8.
- Bennett PH, Wood PH, National Institute of Arthritis and Metabolic Diseases (U.S.), Excerpta Medica Foundation. Population Studies of the Rheumatic Diseases: Proceedings of the 3rd International Symposium, New York, June 5th-10th, 1966. Amsterdam, New York: Excerpta Medica Foundation; 1968.
- Brown WM, Doll R. Mortality from cancer and other causes after radiotherapy for ankylosing spondylitis. *Br Med J* 1965;2:1327-32.
- Buckley CW. Spondylitis Deformans: Its Differential Diagnosis and Treatment by Physical Methods; 1932. Available from: <https://journals.sagepub.com/doi/abs/10.1177/003591573202600210> [Last accessed on 2021 Oct 26].
- Bywaters EGL. Symposium on the spondylarthritides historical aspects of ankylosing spondylitis. *Rheumatology* 1979;18:197-203.
- Calin A, Porta J, Fries JF, Schurman DJ. Clinical history as a screening test for ankylosing spondylitis. *JAMA* 1977;237:2613-4.
- Cardoso A. Effect of a Low Starch Diet in the Gut Microbiome Modulation, Disease Activity and Quality of Life in Patients With Ankylosing Spondylitis; 2020.
- Carrera G, Foley W, Kozin F, Ryan L, Lawson T. CT of sacroiliitis. *Am J Roentgenol* 1981; 136:41-6.
- Chang KW, Chen YY, Lin CC, Hsu HL, Pai KC. Closing wedge osteotomy versus opening wedge osteotomy in ankylosing spondylitis with thoracolumbar kyphotic deformity. *Spine* 2005;30:1584-93.
- Chetrit M, Khan MA, Kapadia S. State of the art management of aortic valve disease in ankylosing spondylitis. *Curr Rheumatol Rep* 2020;22:23.
- Dean LE, Jones GT, MacDonald AG, Downham C, Sturrock RD, Macfarlane GJ. Global prevalence of ankylosing spondylitis. *Rheumatology* 2014;53:650-7.
- Ebringer A. The relationship between Klebsiella infection and ankylosing spondylitis. *Baillieres Clin Rheumatol* 1989;3:321-38.
- El Maghraoui A, Ebo'o FB, Sadni S, Majjad A, Hamza T, Mounach A. Is there a relation between pre-sarcopenia, sarcopenia, cachexia and osteoporosis in patients with ankylosing spondylitis? *BMC Musculoskelet Disord* 2016;17:268.
- Ellingsen T. Safety and Clinical Efficacy Associated With Faecal Microbiota Transplantation Performed in Treatment-naïve Patients With Newly Diagnosed Rheumatoid Arthritis, Reactive Arthritis, Ankylosing Spondylitis, Psoriatic Arthritis, Gouty Arthritis, Psoriasis, Hidradenitis Suppurativa, Pulmonary Sarcoidosis, Crohn's Disease, and Ulcerative Colitis: A 52-week, Double-blind, Randomised, Placebo-controlled, Exploratory Trial; 2021.
- Elyan M, Khan MA. Does physical therapy still have a place in the treatment of ankylosing spondylitis? *Curr Opin Rheumatol* 2008;20:282-6.
- Feldtkeller E, Bruckel J, Khan MA. Scientific contributions of ankylosing spondylitis patient advocacy groups. *Curr Opin Rheumatol* 2000;12:239-47.
- Feldtkeller E, Lemmel E-M, Russell AS. Ankylosing spondylitis in the pharaohs of ancient Egypt. *Rheumatol Int* 2003;23:1-5.
- Garcia-Montoya L, Gul H, Emery P. Recent advances in ankylosing spondylitis: Understanding the disease and management. *F1000Res* 2018;7:F1000 Faculty Rev-1512.
- Goei The HS, Steven MM, Van Der Linden SM, Cats A. Evaluation of diagnostic criteria for ankylosing spondylitis: A comparison of the Rome, New York and modified New York criteria in patients with a positive clinical history screening test for ankylosing spondylitis. *Rheumatology* 1985;24:242-9.
- Gordon TP, Sage MR, Bertouch JV, Brooks PM. Computed tomography of paraspinal musculature in ankylosing spondylitis. *J Rheumatol* 1984;11:794-7.
- Hajjalilo M, Dolati S, Abdolmohammadi-Vahid S, Ahmadi M, Kamrani A, Eghbal-Fard S, et al. Nanocurcumin: A novel strategy in treating ankylosing spondylitis by modulating

- Th17 cells frequency and function. *J Cell Biochem* 2019;120:12027-38.
28. Jacobs WB, Fehlings MG. Ankylosing spondylitis and spinal cord injury: Origin, incidence, management, and avoidance. *Neurosurg Focus* 2008;24:E12.
 29. Jadon DR, Shaddick G, Jobling A, Ramanan AV, Sengupta R. Clinical outcomes and progression to orthopedic surgery in juvenile versus adult-onset ankylosing spondylitis. *Arthritis Care Res* 2015;67:651-7.
 30. Kawahara N, Tomita K, Baba H, Kobayashi T, Fujita T, Murakami H. Closing-opening wedge osteotomy to correct angular kyphotic deformity by a single posterior approach. *Spine* 2001;26:391-402.
 31. Kenny JB, Hughes PL, Whitehouse GH. Discovertebral destruction in ankylosing spondylitis: The role of computed tomography and magnetic resonance imaging. *Br J Radiol* 2014;63:448-55.
 32. Knight SR, Auja R, Biswas SP. Total hip arthroplasty over 100 years of operative history. *Orthop Rev* 2011;3:e16.
 33. Luff AP. The differential diagnosis of gout, rheumatism, and rheumatoid arthritis. *Edinb Med J* 1900;7:230-5.
 34. Lyons AR. Early Diagnosis and Treatment in Ankylosing Spondylitis. *Ulster Med J* 1954;23:34-8.
 35. Magnetic Resonance Imaging of Sacroiliac Joint Inflammation Ahlström 1990 *Arthritis and Rheumatism* Wiley Online Library; 2021. Available from: <https://onlinelibrary.wiley.com/doi/abs/10.1002/art.1780331202> [Last accessed 2021 Oct 27].
 36. Marie P. Sur la spondylose rhizomélisque. *Rev Méd* 1898;18:285-315.
 37. Martey C, Sengupta R. Physical therapy in axial spondyloarthritis: Guidelines, evidence and clinical practice. *Curr Opin Rheumatol* 2020;32:365-70.
 38. Maxwell LJ, Zochling J, Boonen A, Singh JA, Veras MM, Ghogomu ET, *et al.* TNF-alpha inhibitors for ankylosing spondylitis. *Cochrane Database Syst Rev* 2015;4:CD005468.
 39. Nanfang Hospital of Southern Medical University. Treat-to-target Strategy in Ankylosing Spondylitis Using Etanercept and Conventional Synthetic DMARDs, a Prospective Randomized Controlled Study; 2019.
 40. Nelson DA, Kaplan RM, Kurina LM, Weisman MH. Incidence of ankylosing spondylitis among male and female united states army personnel. *Arthritis Care Res* 2021. Articles in Press.
 41. Novartis Pharmaceuticals. A Randomized, Partially-blinded Study of Secukinumab to Demonstrate Reduction of Radiographic Progression Versus GP2017 (Adalimumab Biosimilar) at 104 Weeks and to Assess the Long Term Safety, Tolerability and Efficacy up to 2 Years in Patients With Active Ankylosing Spondylitis; 2021.
 42. Ogdie A, Matthias W, Thielen RJ, Chin D, Saffore CD. Racial differences in prevalence and treatment for psoriatic arthritis and ankylosing spondylitis by insurance coverage in the USA. *Rheumatol Ther* 2021;8:1725-39.
 43. Østergaard M, Lambert RG. Imaging in ankylosing spondylitis. *Ther Adv Musculoskelet Dis* 2012;4:301-11.
 44. Pavelka K, Kivitz A, Dokoupilova E, Blanco R, Maradiaga M, Tahir H, *et al.* Efficacy, safety, and tolerability of secukinumab in patients with active ankylosing spondylitis: A randomized, double-blind phase 3 study, MEASURE 3. *Arthritis Res Ther* 2017;19:285.
 45. Pearce J. Vladimir mikhaylovich bekhtereov, (1857-1927). *ACNR* 2020;19:26-7.
 46. Proft F, Poddubnyy D. Ankylosing spondylitis and axial spondyloarthritis: Recent insights and impact of new classification criteria. *Ther Adv Musculoskelet Dis* 2018; 10:129-39.
 47. Puvanesarajah V, Cancienne JM, Shimer AL, Shen FH, Hassanzadeh H. Complications after fusion for thoracolumbar fractures in patients with ankylosing spondylitis. *Glob Spine J* 2017;7:28-32.
 48. Ravinsky RA, Ouellet JA, Brodt ED, Dettori JR. Vertebral osteotomies in ankylosing spondylitis comparison of outcomes following closing wedge osteotomy versus opening wedge osteotomy: A systematic review. *Evid Based Spine Care J* 2013;4:18-29.
 49. Richmond JJ. The importance of radiotherapy in the treatment of ankylosing spondylitis. *Proc R Soc Med* 1951;44:443-7.
 50. Sieper J, Braun J, Rudwaleit M, Boonen A, Zink A. Ankylosing spondylitis: An overview. *Ann Rheum Dis* 2002;61:iii8-18.
 51. Sieper J, Rudwaleit M, Baraliakos X, Brandt J, Braun J, Burgos-Vargas R, *et al.* The assessment of spondyloarthritis international society (ASAS) handbook: A guide to assess spondyloarthritis. *Ann Rheum Dis* 2009;68:ii1-44.
 52. Simmons ED, DiStefano RJ, Zheng Y, Simmons EH. Thirty-Six years experience of cervical extension osteotomy in ankylosing spondylitis: Techniques and outcomes. *Spine* 2006;31:3006-12.
 53. Simone D, Al Mossawi MH, Bowness P. Progress in our understanding of the pathogenesis of ankylosing spondylitis. *Rheumatology* 2018;57:vi4-9.
 54. Spencer DG, Sturrock RD, Buchanan WW. Ankylosing spondylitis: Yesterday and today. *Med Hist* 1980;24:60-9.
 55. Stecher RM, Hersh AH. Familial occurrence of ankylosing spondylitis. *Br J Phys Med* 1955;18:176-83.
 56. Stolwijk C, van Onna M, Boonen A, van Tubergen A. Global prevalence of spondyloarthritis: A systematic review and meta-regression analysis. *Arthritis Care Res* 2016;68:1320-31.
 57. Strümpell A. Bemerkung über die chronische ankylosierende entzündung der wirbelsäule und der hüftgelenke. *Dtsch Z Nervenheilkd* 1897;11:338.
 58. Sun L, Wu R, Xue Q, Wang F, Lu P. Risk factors of uveitis in ankylosing spondylitis. *Medicine (Baltimore)* 2016;95:e4233.
 59. Symposium on Population Studies in Relation to Chronic Rheumatic Diseases R. In: Ball J, Jeffrey MR, Kellgren JH, Council for International Organizations of Medical Sciences, University of Manchester, editors. *The Epidemiology of Chronic Rheumatism; Volume 2: Atlas of Standard Radiographs of Arthritis*. Oxford: Blackwell Scientific Publications; 1963.
 60. Taurog JD, Maika SD, Satumtira N, Dorris ML, McLean IL, Yanagisawa H, *et al.* Inflammatory disease in HLA-B27 transgenic rats. *Immunol Rev* 1999;169:209-23.
 61. Thomassen E. Vertebral osteotomy for correction of kyphosis in ankylosing spondylitis. *Clin Orthop* 1985;194:142-52.
 62. UCB Biopharma SRL. A Phase 3, Multicenter, Randomized, Double-Blind, Placebo-Controlled Study Evaluating the Efficacy and Safety of Bimekizumab in Subjects With Active Ankylosing Spondylitis; 2021.
 63. Universidad de la Sabana. Efficacy of Myofascial Release

- Compared with Sham Therapy on Joint Range of Motion in Patients With Axial Spondyloarthritis; 2020.
64. University Hospital, Clermont-Ferrand. Impact of a Gluten-free Diet on Quality of Life in Patients with Axial Spondyloarthritis: Study Protocol of a Randomized Double-blind Placebo-controlled Trial; 2020.
 65. Urist MR. Osteotomy of the cervical spine; report of a case of ankylosing rheumatoid spondylitis. *J Bone Joint Surg Am* 1958;40-A:833-43.
 66. Uşak University. Effectiveness of Hippotherapy Simulator in Ankylosing Spondylitis; 2021.
 67. van der Linden SM, Valkenburg HA, de Jongh BM, Cats A. The risk of developing ankylosing spondylitis in HLA-B27 positive individuals. A comparison of relatives of spondylitis patients with the general population. *Arthritis Rheum* 1984;27:241-9.
 68. Wallman JK, Mogard E, Marsal J, Andréasson K, Jöud A, Geijer M, *et al.* Irritable bowel syndrome symptoms in axial spondyloarthritis more common than among healthy controls: Is it an overlooked comorbidity? *Ann Rheum Dis* 2020;79:159-61.
 69. Walsh J, Hunter T, Schroeder K, Sandoval D, Bolce R. Trends in diagnostic prevalence and treatment patterns of male and female ankylosing spondylitis patients in the United States, 2006-2016. *BMC Rheumatol* 2019;3:39.
 70. Ward MM, Deodhar A, Gensler LS, Dubreuil M, Yu D, Khan MA, *et al.* 2019 Update of the American college of rheumatology/spondylitis association of America/ spondyloarthritis research and treatment network recommendations for the treatment of ankylosing spondylitis and nonradiographic axial spondyloarthritis. *Arthritis Care Res* 2019;71:1285-99.
 71. Webers C, Essers I, Ramiro S, Stolwijk C, Landewé R, van der Heijde D, *et al.* Gender-attributable differences in outcome of ankylosing spondylitis: Long-term results from the outcome in ankylosing spondylitis international study. *Rheumatology* 2016;55:419-28.
 72. Wilson MJ, Turkell JH. Multiple spinal wedge osteotomy; its use in a case of Marie-Strumpell spondylitis. *Am J Surg* 1949;77:777-82.
 73. Xi Y, Jiang T, Chaurasiya B, Zhou Y, Yu J, Wen J, *et al.* Advances in nanomedicine for the treatment of ankylosing spondylitis. *Int J Nanomed* 2019;14:8521-42.
 74. Zhao Q, Dong C, Liu Z, Li M, Wang J, Yin Y, *et al.* The effectiveness of aquatic physical therapy intervention on disease activity and function of ankylosing spondylitis patients: A meta-analysis. *Psychol Health Med* 2020;25:832-43.
 75. Zhu W, He X, Cheng K, Zhang L, Chen D, Wang X, *et al.* Ankylosing spondylitis: Etiology, pathogenesis, and treatments. *Bone Res* 2019;7:1-16.
 76. Ziwjan JL. The treatment of flexion deformities of the spine in Bechterew disease. *Beitr Orthop Traumatol* 1982;29:195-9.

How to cite this article: Murphy SN, Nguyen BA, Singh R, Brown NJ, Shahrestani S, Neal MT, *et al.* A brief human history of ankylosing spondylitis: A scoping review of pathogenesis, diagnosis, and treatment. *Surg Neurol Int* 2022;13:297.