

UCLA

Proceedings of UCLA Health

Title

Stercoral Colitis in a Nine-Year-Old Boy

Permalink

<https://escholarship.org/uc/item/2s52t192>

Journal

Proceedings of UCLA Health, 24(1)

Authors

Pithia, Neema

Chawla, Soni

Bultron, Gilberto

[et al.](#)

Publication Date

2020-04-03

CLINICAL VIGNETTE

Stercoral Colitis in a Nine-Year-Old Boy

Neema Pithia, MD^{1,2}, Soni Chawla, MD¹, Gilberto Bultron, MD¹ and John Petersen, MD²

¹Olive View-UCLA Medical Center, Sylmar, California

²University of California Los Angeles, Los Angeles, California

Initial Presentation

A 9-year-old male presented to the emergency department with severe right lower quadrant abdominal pain, decreased appetite, and fever. His past medical history was significant for chronic constipation for the last 4 years. On presentation, he was febrile to 38.0°C and tachycardic with a heart rate of 122. His initial exam revealed an ill-appearing child with left lower quadrant and right lower quadrant abdominal tenderness, specifically with tenderness over McBurney's point and associated guarding. Laboratory evaluation included white blood cell count of 10.4 k/ μ L, C-reactive protein of 28.8 mg/L, and urinalysis with trace protein and ketones 40 mg/dL. Ultrasound of the right lower quadrant failed to visualize the appendix, and CT of the abdomen was obtained for further evaluation, which ultimately led to the diagnosis of stercoral colitis (Figure 1).

The Condition

Stercoral colitis is an inflammatory condition involving the colonic wall, most often from fecal impaction secondary to severe and chronic constipation. The inflammatory colitis is directly related to increased intraluminal pressure, with focal pressure colitis which can result in ulceration or pressure necrosis, leading to local ischemia and subsequent colonic perforation.¹ Cases complicated by colonic perforation have mortality rates as high as 35%.² Stercoral colitis has a median age of presentation of 62 and is rarely seen in the pediatric population.³ Previous cases have been associated with chronic opioid use, intensive chemotherapy, and behavioral pathology resulting in chronic constipation.³ Stercoral colitis has a wide differential and is often misdiagnosed as appendicitis or inflammatory bowel disease in the pediatric population and diverticulitis in the adult population.⁴ Computed tomography (CT) is an important tool in early identification and prompt treatment.⁵

This patient's presentation was clinically most consistent with appendicitis, with a calculated pediatric appendicitis score of 7, which correlates to a positive predictive value of 88% for appendicitis.⁶ Despite the initial negative ultrasound, he was considered for empiric appendectomy based on his clinical presentation. Further evaluation with abdominal CT scan identified the much rarer diagnosis of stercoral colitis without

fecaloma and allowed appropriate management with intravenous antibiotics and medical fecal disimpaction.

Our patient's presentation was unique compared to the majority of published pediatric cases, which have been complicated by perforation and need for surgical intervention.⁷ His less complex course may have been due to the severity of his stool impaction or his relatively early diagnosis. Pediatric patients are believed to have lower risk of colonic perforation, as the colonic wall is more pliable in children. This is consistent with rates of perforation in pediatric polypectomy, of 0.01%, compared to the adult risk of 0.082%, an 8-fold increase.⁸ Predisposing factors to perforations in stercoral colitis include presence of adhesions, strictures, or severe diverticular disease, all of which are less likely in the pediatric population.⁸

This case illustrates how a common diagnosis such as functional constipation may result in serious complications with significant morbidity. Early recognition and treatment of stercoral colitis is key to avoid further morbidity in pediatric patients presenting with history of constipation and abdominal pain out of proportion to typical constipation. Stercoral colitis is a dangerous mimicker of much more common diagnoses in the pediatric setting, especially appendicitis, and may not be recognized at initial evaluation. Further studies are needed to assess optimal colonic decompression method, antibiotic use, and bowel regimens to prevent recurrence.

Clinical Course

The patient was admitted for management of presumed infectious proctocolitis, tachycardia and fever. Pediatric surgery, gastroenterology, and infectious disease teams were consulted. Given the patient's ill appearance, a blood culture was obtained, and he was started on empiric piperacillin-tazobactam monotherapy coverage for typical enteric aerobic and anaerobic organisms. His initial bowel regimen was polyethylene glycol 17g and docusate 60mg twice daily. Bisacodyl 5mg suppositories and mineral oil enemas were eventually added due to oral intolerance of medications.

The patient responded well, with resolution of abdominal pain, defervescence after forty-eight hours of antibiotics and signifi-

cant stool output with bowel regimen. He completed polyethylene glycol 3350 oral bowel cleanout prior to discharge, with eventual clear effluent per rectum. His blood culture remained negative.

Prior to discharge, he was switched to amoxicillin clavulanate to complete a 10-day course of empiric antibiotics for his proctocolitis. He was discharged on an aggressive bowel regimen, including polyethylene glycol 17g daily, lactulose 10g

twice daily, 14g fiber supplement daily, fluid goal of at least 2 liters of water daily, and an aerobic exercise plan.

Since discharge, the patient has been compliant with his medications, with regular bowel movements. He is followed by a pediatric gastroenterology for ongoing constipation treatment and has no recurrence of abdominal pain since hospital discharge.

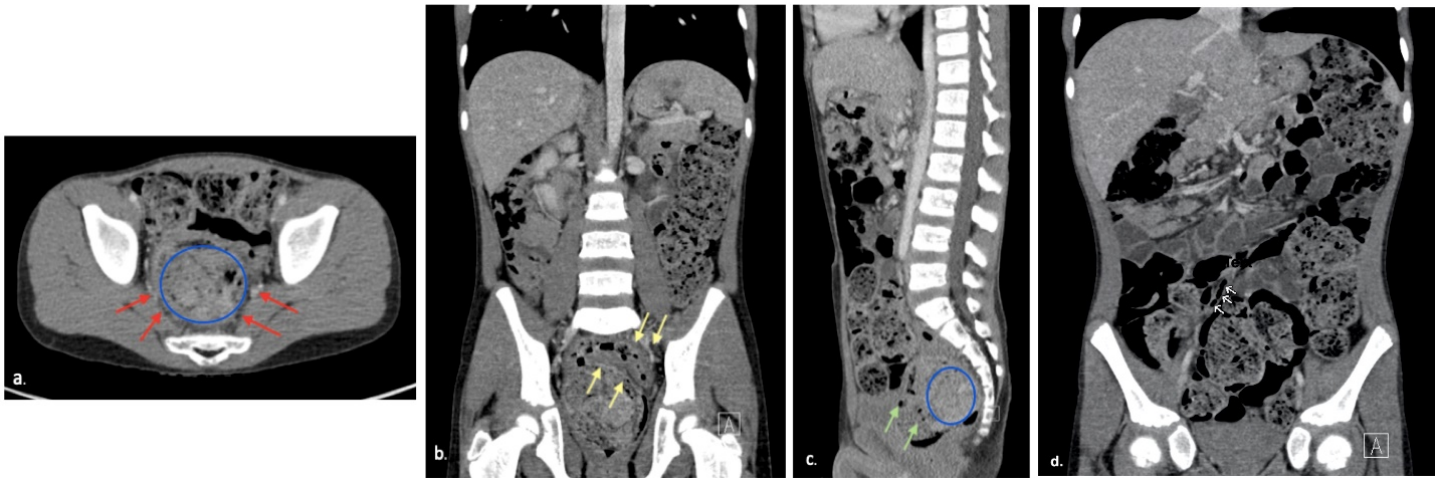


Figure 1. a) *Axial image:* The rectum is distended and filled with dense stool (blue circle) with mild nearly diffuse rectal wall thickening and mild perirectal fat stranding (red arrows) b) *Coronal image:* There is mild diffuse bowel wall thickening (6 to 7 mm) (yellow arrows) involving a short segment of the distal sigmoid colon with mild adjoining presacral fat stranding. No evidence of free air. There is excessive fecal material throughout the colonic segments. The stomach appears to be compressed due to excessive fecal material in the splenic flexure c) *Sagittal image:* The small bowel segments are not dilated. The rectum is distended and filled with dense stool (blue circle) with mild nearly diffuse rectal wall thickening (green arrows) and mild perirectal fat stranding d) Partially visualized nondilated air-filled tubular appearing normal appendix (white arrows)

REFERENCES

1. **Naseer M, Gandhi J, Chams N, Kulairi Z.** Stercoral colitis complicated with ischemic colitis: a double-edge sword. *BMC Gastroenterol.* 2017 Nov 28;17(1):129. doi: 10.1186/s12876-017-0686-6. PubMed PMID: 29179680; PubMed Central PMCID: PMC5704496.
2. **Heffernan C, Pachter HL, Megibow AJ, Macari M.** Stercoral colitis leading to fatal peritonitis: CT findings. *AJR Am J Roentgenol.* 2005 Apr;184(4):1189-93. PubMed PMID: 15788592.
3. **Chakravarty S, Chang A, Nunoo-Mensah J.** A systematic review of stercoral perforation. *Colorectal Dis.* 2013 Aug;15(8):930-5. doi: 10.1111/codi.12123. Review. PubMed PMID: 23331762.
4. **Guelfguat M, Sarkany D.** Stercoral colitis: mimickers and pitfalls. AOCR Electronic Research Exhibits. 2018. <https://cdn.ymaws.com/www.aocr.org/resource/resmgr/2018ResearchExhibits/Guelfguat.pdf>
5. **Ünal E, Onur MR, Balcı S, Görmez A, Akpınar E, Böge M.** Stercoral colitis: diagnostic value of CT findings. *Diagn Interv Radiol.* 2017 Jan-Feb;23(1):5-9. doi: 10.5152/dir.2016.16002. PubMed PMID: 27910814; PubMed Central PMCID: PMC5214077.
6. **Goldman RD, Carter S, Stephens D, Antoon R, Mounstephen W, Langer JC.** Prospective validation of the pediatric appendicitis score. *J Pediatr.* 2008 Aug;153(2):278-82. doi: 10.1016/j.jpeds.2008.01.033. Epub 2008 Mar 19. Erratum in: *J Pediatr.* 2009 Feb;154(2):308-9. PubMed PMID: 18534219.
7. **Caillet A, Steiner M, Sawaya D, Nowicki M.** Stercoral Colitis With Silent Perforation in a Child. *J Clin Gastroenterol.* 2016 Oct;50(9):799-800. doi: 10.1097/MCG.0000000000000610. PubMed PMID: 27466168.
8. **Park JH.** Role of colonoscopy in the diagnosis and treatment of pediatric lower gastrointestinal disorders. *Korean J Pediatr.* 2010 Sep;53(9):824-9. doi: 10.3345/kjp.2010.53.9.824. Epub 2010 Sep 13. PubMed PMID: 21189966; PubMed Central PMCID: PMC3005213.