

UCSF

UC San Francisco Previously Published Works

Title

Development of the human bladder and ureterovesical junction

Permalink

<https://escholarship.org/uc/item/2rb0885d>

Authors

Liaw, Aron
Cunha, Gerald R
Shen, Joel
et al.

Publication Date

2018-09-01

DOI

10.1016/j.diff.2018.08.004

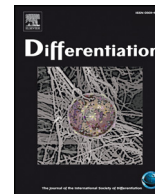
Peer reviewed



ELSEVIER

Contents lists available at ScienceDirect

Differentiation

journal homepage: www.elsevier.com/locate/diff

Development of the human bladder and ureterovesical junction[☆]

Aron Liaw, Gerald R. Cunha, Joel Shen, Mei Cao, Ge Liu, Adriane Sinclair, Laurence Baskin*

Department of Urology, University of California, San Francisco, San Francisco, CA Division of Pediatric Urology, University of California San Francisco Benioff Children's Hospital, San Francisco, CA 94143, United States

ARTICLE INFO

Keywords:

Bladder
Fetal
Development. Trigone, ureterovesical junction

ABSTRACT

The urinary bladder collects urine from the kidneys and stores it until the appropriate moment for voiding. The trigone and ureterovesical junctions are key to bladder function, by allowing one-way passage of urine into the bladder without obstruction. Embryological development of these structures has been studied in multiple animal models as well as humans. In this report we review the existing literature on bladder development and cellular signalling with particular focus on bladder development in humans.

The bladder and ureterovesical junction form primarily during the fourth to eighth weeks of gestation, and arise from the primitive urogenital sinus following subdivision of the cloaca. The bladder develops through mesenchymal-epithelial interactions between the endoderm of the urogenital sinus and mesodermal mesenchyme. Key signalling factors in bladder development include *shh*, TGF- β , *Bmp4*, and *Fgfr2*. A concentration gradient of *shh* is particularly important in development of bladder musculature, which is vital to bladder function. The ureterovesical junction forms from the interaction between the Wolffian duct and the bladder. The ureteric bud arises from the Wolffian duct and is incorporated into the developing bladder at the trigone. It was previously thought that the trigonal musculature developed primarily from the Wolffian duct, but it has been shown to develop primarily from bladder mesenchyme. Following emergence of the ureters from the Wolffian ducts, extensive epithelial remodelling brings the ureters to their final trigonal positions via vitamin A-induced apoptosis. Perturbation of this process is implicated in clinical obstruction or urine reflux. Congenital malformations include ureteric duplication and bladder exstrophy.

1. Introduction

The human bladder is formed from the cranial portion of the primitive urogenital sinus, and collects and stores urine from the kidneys and until it can be expelled at a socially appropriate moment. To this purpose, the bladder, like the ureters, is lined with urothelium surrounded by layers of smooth muscle. The fibromuscular layers of the bladder consist of the lamina propria, consisting of extracellular matrix containing a sparse poorly organized smooth muscle layer (the muscularis mucosa) (Vakar-Lopez et al., 2007) and an outer compartment consisting of a complex weave of thick smooth muscle bundles. In both males and females, the bladder develops identically without differences in size (Shen et al., 2018). Fig. 1 is a wholemount series of female bladder development. In males the prostate develops from epithelial buds arising from the urogenital sinus (urethra) immediately below the bladder (Cunha et al., 2018).

The primitive urogenital sinus arises in the fourth week of gestation

from the cloaca, an epithelial chamber common to both the gastrointestinal and urogenital systems located in the pelvic region (Kromer, 1996). During the fifth to sixth weeks of gestation, the urorectal septum partitions the cloaca into the primitive urogenital sinus ventrally and the anorectal canal dorsally (Fig. 2).

The mechanism of division of the cloaca is not well understood. Originally, it was thought that this partitioning occurred through either a fusion of bilateral ridges of the lateral cloacal walls (Rathke, 1832), by a descending frontal septum (Kromer, 1999; Tourneux, 1888), or a combination thereof (Moore et al., 2013). However, more recent investigations have found neither of these processes are involved (Nivelstein et al., 1998; Zhang et al., 2011). Instead, during the caudal folding of the embryo, parts of the allantois and yolk sac are incorporated internally into the embryo along with their surrounding extraembryonic mesoderm. Rogers et al. suggest that the urorectal septum develops from this extraembryonic mesoderm and is a passive structure that does not actively divide the cloaca (Rogers et al., 2002).

[☆] Supported by National Institute of Health grant K12DK083021.

* Correspondence to: Pediatric Urology, Pediatric Urology, UCSF Benioff Children's Hospitals University of California, San Francisco Department of Urology, 550, 16th St, 5th Floor Mission Hall Pediatric Urology, San Francisco, CA 94158, United States.

E-mail address: Laurence.baskin@ucsf.edu (L. Baskin).

<https://doi.org/10.1016/j.diff.2018.08.004>

Received 1 August 2018; Received in revised form 22 August 2018; Accepted 24 August 2018

0301-4681/© 2018 International Society of Differentiation. Published by Elsevier B.V. All rights reserved.

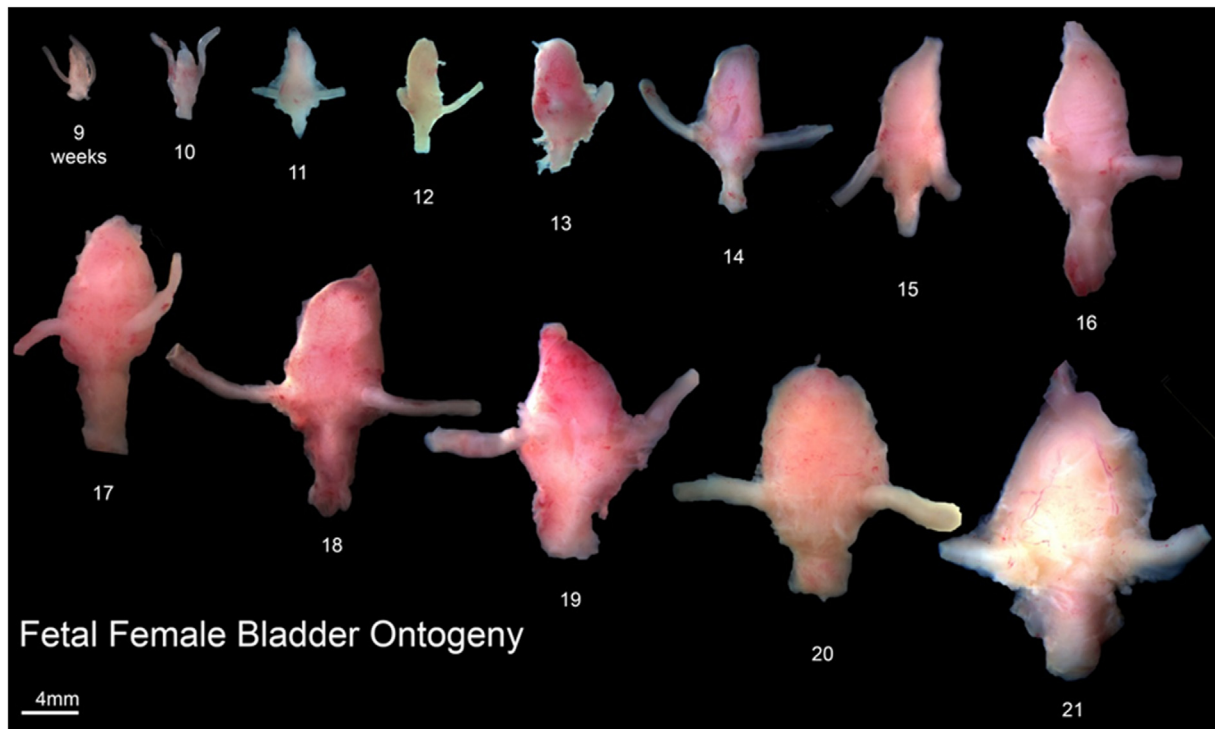


Fig. 1. Ontogeny of Human Female Bladder Development from 9 to 21 weeks of gestation. Note the male (data shown in accompanying paper in this supplement, (Shen et al., 2018)) and female bladder develop in the same fashion.

A more recent explanation is that cells localized to the peri-cloacal mesenchyme contribute to the future perineum, and that, during development, it is the dorsal peri-cloacal mesenchymal cells that remain in a relatively fixed position relative to the cloacal membrane, which is devoid of mesenchyme. It is thus asymmetric proliferation of mesenchymal cells around the cloacal membrane that separates of the urinary and digestive tracts (Wang et al., 2013). Several authors assert that the urorectal septum does not fuse with the cloaca membrane (Nievalstein et al., 1998; Rogers et al., 2002; Zhang et al., 2011). The division of the cloaca is a complex event and the mechanism of subdivision of the cloaca remains controversial.

2. Bladder development

The bladder forms from the primitive urogenital sinus above the confluence with the Wolffian (mesonephric) ducts, which serves as the demarcation between the cranial vesicourethral canal and the caudal “urogenital sinus”. Unfortunately, the terminology is a bit confusing. When the cloaca is partitioned into the “primitive” urogenital sinus and the anorectal canal, the primitive urogenital sinus is in continuity with the allantois that extends cranially up the anterior body wall to end blindly in the umbilical cord. The cranial portion of the primitive urogenital sinus above the junction with the Wolffian (mesonephric) ducts forms the bladder. The caudal or pelvic portion of the primitive urogenital sinus in males forms the prostate, prostatic urethra, bulbourethral glands and the membranous urethra. This caudal portion of the primitive urogenital sinus is simply referred to as the “urogenital sinus”. Thus, one must be cognizant of this unfortunately confusing terminology. In females the urogenital sinus forms the urethra below the bladder neck and in the fetus also forms the sinovaginal bulbs that are confluent with the Mullerian-derived uterovaginal canal (Cunha et al., 2018; Robboy et al., 2017). The junction between the Mullerian-derived uterovaginal canal and the urethra occurs near the future introitus (Robboy et al., 2017). Thus, in humans, urogenital sinus epithelium appears to form the hymen and contributes to the vaginal vestibule (Robboy et al., 2017; Cunha et al., 2018).

The bladder develops from Foxa1-reactive endodermal epithelial cells and mesodermally derived mesenchyme. Foxa1 is a known marker of endodermal epithelial cells within the pelvis and elsewhere (Besnard et al., 2004; Diez-Roux et al., 2011; Robboy et al., 2017). Like many organs in the body, including the gut, integument, male and female internal genitalia and teeth, development of the epithelial and fibromuscular layers of the bladder is dependent upon reciprocal epithelial-mesenchymal interactions (Baskin et al., 1996a, 1996b; Baskin et al., 1997; DiSandro et al., 1998; Tasian et al., 2010) (Fig. 3). Experiments done in rat models show that bladder mesenchyme in isolation does not grow or differentiate into smooth muscle *in vivo*, while grafts containing both bladder mesenchyme and bladder epithelium results in normal development of the epithelium as well as smooth muscle differentiation of the mesenchyme (Baskin et al., 1996a, 1996b). Appropriate epithelial differentiation in the bladder is affected by the mesenchyme with which it is associated during development. Embryonic bladder epithelium grown in association with bladder mesenchyme undergoes normal urothelial differentiation, while embryonic or adult bladder epithelium grown in association with prostatic mesenchyme undergoes prostatic differentiation (Aboseif et al., 1999; Cunha et al., 1983a, 1983b).

Initially, the lumen of the bladder is continuous at its apex with the patent allantois, which subsequently regresses into a thick fibrous cord called the urachus in the embryo and postnatally is called the median umbilical ligament (Gray and Clemente, 1985). Persistent patency of this urachal tract manifests later in life as urachal cysts or a patent urachus, which are prone to infection and are treated with surgical excision (Mesrobian et al., 1997).

Several signalling factors have been implicated in animal models of bladder development. Multiple studies have demonstrated a role for *Shh* in bladder smooth muscle differentiation (Cheng et al., 2008; Freestone et al., 2003; Haraguchi et al., 2007). Shiroyanagi et al. demonstrated with RT-PCR studies in a mouse model that *Shh* mRNA is expressed early in bladder development, peaking at E12.5, and that smooth muscle genes are subsequently expressed over E13.5 to E15.5 (Shiroyanagi et al., 2007). Immunohistochemical studies demonstrate

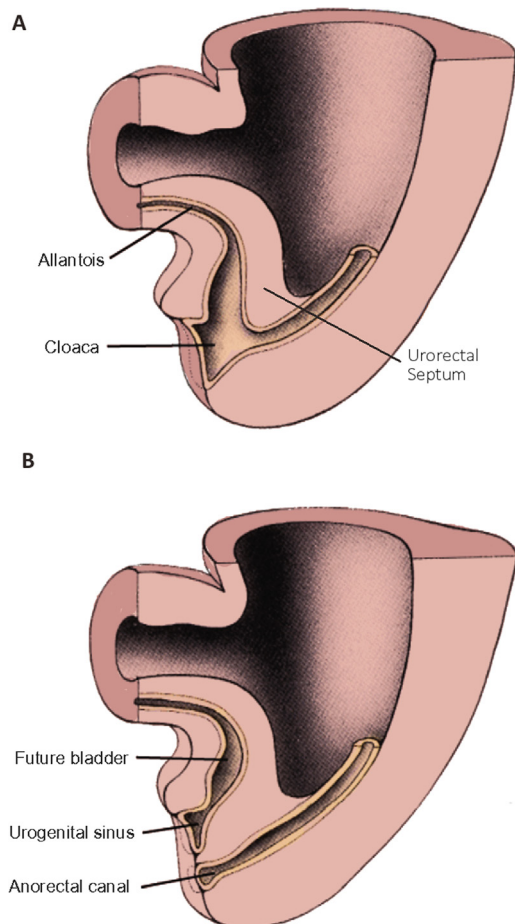


Fig. 2. Division of the cloaca into urogenital sinus and anorectal canal. A) Initial conformation of cloaca and urorectal septum. B) After division of the cloaca into urogenital sinus and anorectal canal. From [Baskin and Cunha, 2018](#), with permission.

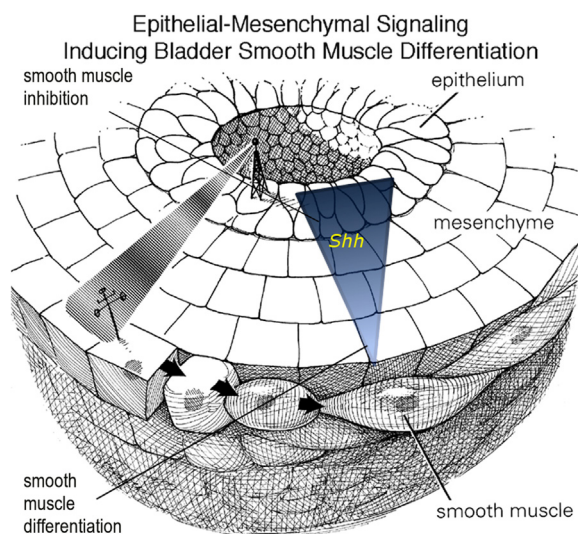


Fig. 3. Like many organs in the body, differentiation in the bladder is driven by interactions between the epithelium and mesenchyme. *Shh* produced by embryonic bladder epithelium signals to the mesenchyme, and in regions of proximity to the epithelium, smooth muscle differentiation is inhibited where the *Shh* signal is strongest. Peripheral mesenchyme, receiving an attenuated *Shh* signal is induced to undergo smooth muscle differentiation. Used with permission *J Urol.* 1996 ([Baskin et al., 1996a, 1996b](#)).

that *Shh* is produced by the developing bladder epithelium ([Jenkins et al., 2007](#)). *Shh* is known to pattern developing mesenchyme via an abrupt on/off concentration gradient, and appears to behave similarly in the embryonic bladder, acting as a paracrine signalling factor from the urothelium that induces mesenchymal differentiation into smooth muscle ([Cheng et al., 2008](#)). Without *Shh* expression smooth muscle fails to develop. However, high concentrations of *Shh* inhibit smooth muscle differentiation and lower *Shh* concentrations induce smooth muscle differentiation ([Cao et al., 2010](#)). *Ptc*, the receptor for *Shh*, is appropriately expressed in embryonic bladder mesenchyme ([Tasian et al., 2010](#)), mirroring the pattern of expression seen in smooth muscle differentiation throughout the body, such as the gut ([Le Guen et al., 2015](#)). Furthermore, the transcription factor *Gli2*, a target of *Shh*, has been shown to up-regulate *Bmp4* expression in the mesenchyme closest to the bladder epithelium, resulting in reduced smooth muscle differentiation ([Cheng et al., 2008](#)). Further distant from the urothelial layer, where *Shh* concentrations are presumably lower, *Bmp4* is commensurately reduced and in peripheral mesenchymal regions robust smooth muscle differentiation occurs. The suggested mechanism for *Shh* activity in bladder patterning is shown in [Figs. 3 and 4](#).

Bmp4 acts through the Smad family of cytoplasmic signal transducers, as does TGF- β . Islam et al. demonstrated that Smads are localized differentially both spatially and temporally throughout murine bladder development, and that the TGF- β receptor inhibitor (SB-431542) inhibits muscular development of the embryonic bladder, suggesting that TGF- β acts along with *Bmp4* in the differentiation of the bladder ([Islam et al., 2013](#)).

More recently, the work of Ikeda et al. shows that along with *Shh*, *Bmp4* and TGF- β , *Fgfr2* is critical for bladder mesenchymal patterning ([Ikeda et al., 2017](#)). *Fgfr2* deletions in E10.5 murine Wolffian duct stroma led to augmented *Shh* activity, along with increased *Boc* and *Cdo* levels, which are co-receptors that enhance sensitivity to *Shh*. Ultimately, these molecular changes led to abnormalities in bladder smooth muscle patterning, seen as loss of smooth muscle and increase in collagen. These changes result in voiding dysfunction postnatally, as well as reduced bladder contractility. Such bladders were also seen to be poorly compliant. Compliance is the physical property of a hollow organ or vessel to distend in response to increased intraluminal volume. Normal compliance in organs such as bladders, blood vessels and lungs is important for proper maintenance of safe intraluminal pressure. Compliance in the bladder is due to relaxation of the muscle and extracellular matrix so that pressure within the bladder remains low as it fills with urine, thereby preventing urinary reflux or hydronephrosis secondary to increased pressure.

The dual properties of compliance and contractility are key to bladder function. In the normal developing bladder, compliance varies over the course of development. In animal models, bladder compliance is initially poor but improves as the bladder matures ([Baskin et al., 1994](#)). As bladder development proceeds smooth muscle fibers increase in number, and the relative amount of collagen decreases, albeit with an increase in the number of elastic collagen fibers. This same pattern is observed in developing human fetal bladders ([Kim et al., 1991](#)). This increase in compliance also coincides with urine production, suggesting that there may be a mechanical stretching component to this phenomenon. A mouse model employed by Beauboeuf et al. used urethral and ureteral ligation of explanted bladders, which resulted in distension by passive accumulation of intraluminal fluid, in a fashion similar to normal urinary accumulation *in vivo*. These bladders showed increase in smooth muscle fibers, as well as a more orderly arrangement of collagen fibers compared to control bladders that were allowed to drain freely and thus did not distend during development. Thus, normal bladder distension appears to affect patterning and differentiation within the developing fibromuscular wall of the bladder ([Beauboeuf et al., 1998](#)).

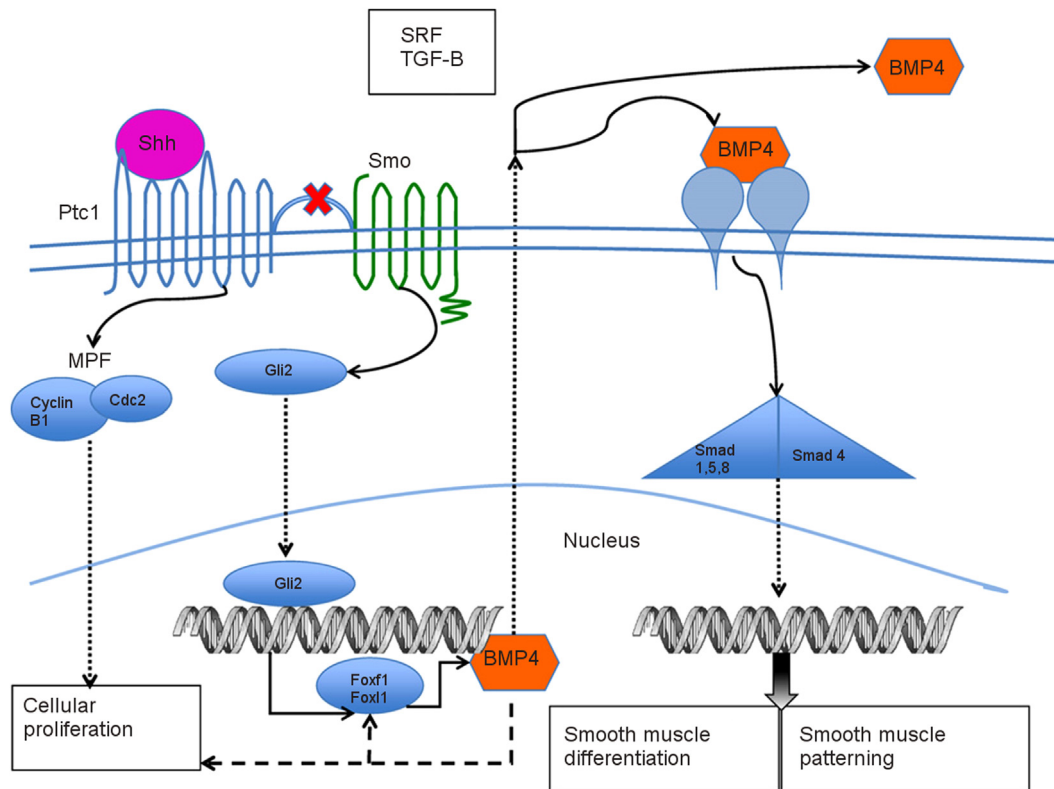


Fig. 4. Shh binds to the Ptc receptor, which releases its inhibition on Smoothed (Smo), activating Gli2. Following translocation into the nucleus, Gli2 activates Bmp4, which signals for smooth muscle differentiation through Smads. M-phase promoting factor (MPF) is also released upon binding of Ptc, and MPF is known to induce mitosis, a function which is likely preserved in the bladder. Serum response factor (SRF) is also important in muscle-cell specific proliferation and differentiation, and may be upregulated in the mesenchyme where Shh levels are low (Shiroyanagi et al., 2007). From Tasian et al. (2010) with permission.

3. Development of the trigone and ureterovesical junction

The bladder trigone is a triangular area at the so-called base of the bladder defined by the ureterovesical junctions cranially and the urethral orifice caudally (Gray and Clemente, 1985) (Fig. 5E). The adult trigone has a smooth epithelial surface and is crucial for normal bladder emptying and continence. The ureterovesical junction in the normal state allows one-way flow of urine from the ureters into the bladder without obstruction. This protects the kidneys from pressure or the reflux of urine or bacteria. Development of the ureteral and trigonal musculature is important to this one-way flow. The thickness of ureteral musculature and the length of the ureter during its passage through the bladder wall increase in a linear fashion throughout human development (Oswald et al., 2003). Deficiencies in trigonal formation lead to a variety of clinical conditions such as vesicoureteral reflux (Fig. 6) which occurs secondary to poor muscle backing resulting in a relatively short ureteral tunnel. Duplication of ureters from splitting of the ureteral bud is often normal with no clinical implications but can result in pathology such as obstruction of the upper pole ureter from a ureterocele (Fig. 7). Ureters can also insert in an ectopic location outside the bladder, leading to hydronephrosis, and urinary incontinence in females if the insertion site is beyond the urinary sphincter (Fig. 8).

Initiation of trigonal development occurs during the fifth to sixth weeks in humans, when the mesonephric (Wolffian) ducts connect to the primitive urogenital sinus. The formation of the ureteric bud is the first stage in the development of the ureterovesical junction. The ureteric bud arises from the Wolffian duct at 4 weeks (Fig. 5A) and grows cranially into the metanephrogenic mesenchyme. Once the ureteric bud makes contact with this mesenchyme, it induces differentiation of the metanephrogenic mesenchyme to form nephrons, while the metanephrogenic mesenchyme reciprocally induces elongation and branching of the ureteric bud (Herzlinger et al., 1994). The section of Wolffian

duct caudal to the ureteric bud is termed the common excretory duct or common nephric duct (Fig. 5A), which is in continuity with the urogenital sinus. Following emergence of the ureteric bud from the Wolffian duct, the common nephric duct makes contact with the developing bladder (Fig. 5A-B). However, rather than being resorbed into the developing bladder, the common nephric duct undergoes apoptosis, a process which also serves to bring the ureter in contact with the urogenital sinus epithelium, where they fuse (Batourina et al., 2005). As a result of further remodelling, expansion, and differentiation the ureteric orifices migrate cranio-laterally to define the upper angles of the trigone, while in males the Wolffian ducts migrate caudally to eventually empty into the prostatic urethra at the apex of the verumontanum as the ejaculatory ducts (Batourina et al., 2002), as seen in Fig. 5C-D (Woolf and Davies, 2013). This complex remodelling process is dependent on vitamin-A mediated apoptosis. The enzyme Raldh2, involved in vitamin-A induced signalling, is expressed in the mesenchyme of the urogenital sinus immediately surrounding the common nephric duct, ureter and Wolffian duct, and inactivation of Raldh2 abrogates apoptosis, and results in obstructive hydronephrosis in a transgenic mouse model (Batourina et al., 2005).

Anatomically, the epithelium of the adult trigone is smooth and thus is distinct from the rugated epithelium lining the rest of the bladder. For this reason trigonal epithelium was initially thought to be derived from the Wolffian ducts, rather than from the urogenital sinus (Tacciuoli et al., 1975; Tanagho, 1976). More recent studies, however, suggest that the epithelium of the trigone is derived from endodermal urogenital sinus epithelium. This interpretation is inferred from tissue recombinant experiments in which mouse trigonal epithelium was combined with urogenital sinus mesenchyme. The resultant tissue recombinants grown in male hosts developed prostatic tissue, interpreted as suggesting that trigonal epithelium is of urogenital sinus origin (Tanaka et al., 2010). Cell lineage analysis in a mouse model showed

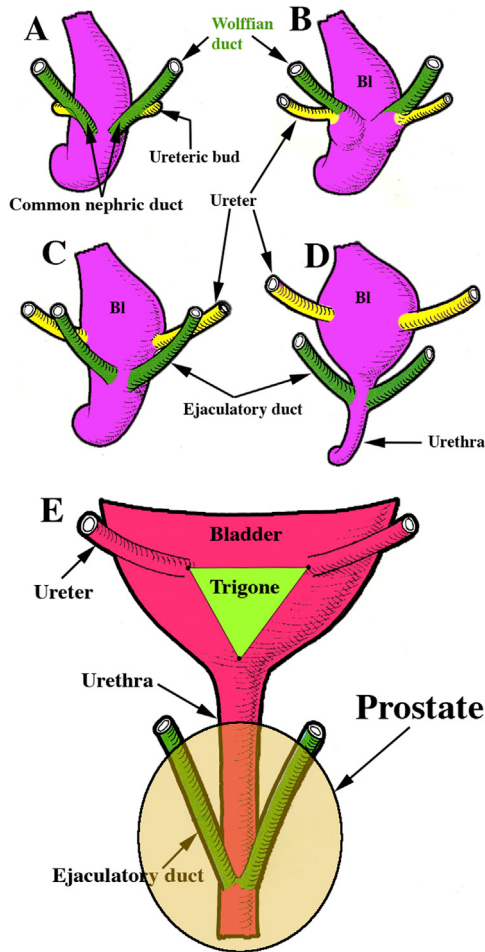


Fig. 5. Origin of the ureteric bud from the Wolffian duct (A) and remodelling of the positions of the ureters and Wolffian ducts (ejaculatory ducts) in male embryos (B-D). Final adult positions of the ureters and ejaculatory ducts in relation to the trigone (E).

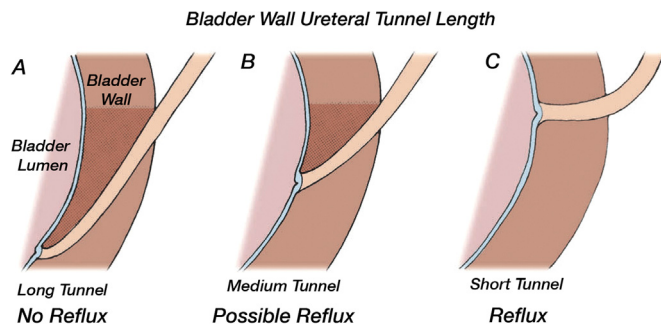


Fig. 6. Defects of the ureterovesical junction can cause vesicoureteral reflux. (A) Long tunnel length results in excellent muscle backing on both sides of the ureter resulting in no reflux (B) Medium tunnel length results in reasonable muscle backing with possible reflux. (C) Short tunnel length results in poor muscle backing resulting in reflux. Modified from the Pediatric Urology Handbook Chapter 6 (Copp et al., 2018) with permission.

that trigonal stromal cells are derived primarily from urogenital sinus mesenchymal cells (Viana et al., 2007).

The ureterovesical junction is functionally a transitional valve between the low pressure upper urinary tract (kidney and ureter) and the variable pressure environment of the bladder and is dependent in part on ureteral musculature at the ureterovesical junction (Fig. 6). Ureteral agenesis results in an abnormally shaped trigone, and it was thought

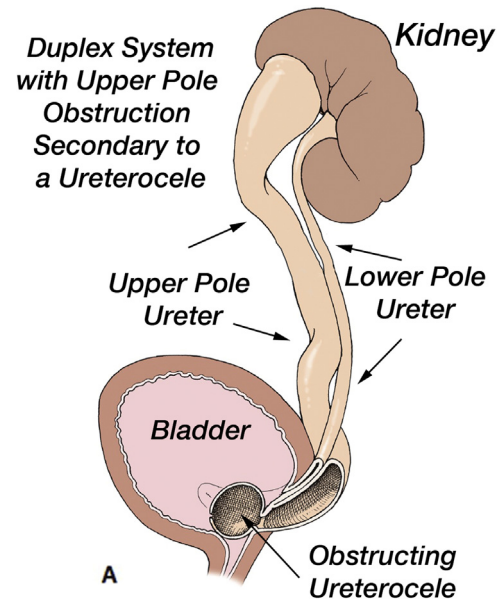


Fig. 7. Duplication of collecting system with upper pole hydroureteronephrosis secondary to an intravesical obstructing ureterocele. Modified from the Pediatric Urology Handbook Chapter 14 (Baskin et al., 2018) with permission.

Posterior View of the Bladder, Urethra, Vagina and Uterus Showing Possible Sites for Ectopic Ureter Insertion

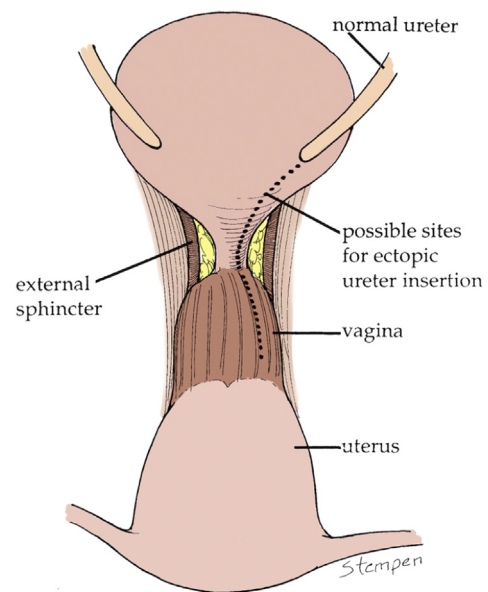


Fig. 8. Ectopic ureteral insertion (bladder neck, urethra, vagina) outside the bladder leading to hydroureteronephrosis and urinary incontinence in females since the insertion site is beyond the urinary sphincter. Modified from the Pediatric Urology Handbook Chapter 14 (Baskin et al., 2018) with permission.

that ureteral musculature formed the sheath that encases the ureter as it passes through the bladder wall. However, Viana et al. observed that in *Pax2* mouse mutants, which exhibit ureteral and renal agenesis, the bladder trigone contains extensive bladder musculature with a gap where the ureter and associated blood vessels normally pass. This suggests that the “ureteral tunnel” through the bladder wall develops normally in the absence of a ureter, and that this tunnel is composed mostly of bladder musculature (Viana et al., 2007). The mechanism by which this tunnel is patterned independent of the ureter is unknown, but, as in bladder development, *Bmp4* signalling has been implicated (Wang et al., 2009). *Bmp4* knockout mice show a reduction of the

smooth muscle coat surrounding the ureter, resulting in hydronephrosis and hydroureter (Miyazaki et al., 2003).

4. Clinical correlation: ureteral duplication and ectopy

Duplication of the ureters (Fig. 7) is a relatively common occurrence in humans (1%), and results from emergence of duplicate ureteric buds. Emergence of the ureteric bud and its outgrowth into the metanephric mesenchyme involves the RET-GDNF-GFR α 1 pathway, and while genes have been identified that lead to duplication of the ureteric bud, the mechanisms by which these genes modulate this phenomenon is unknown. In mouse models, *Nfia* and *Robo2* mutants have been seen to result in ureteric duplication (Grieshammer et al., 2004; Lu et al., 2007), and mice with deletion of *Sprouty1* also show multiple ureteric buds (Basson et al., 2006).

With regard to ureteral duplication, Weigert and Meyer recognised that the more caudal ureteric bud emerging from the Wolffian duct was associated with the lower pole of the kidney, while the cranial ureteric bud became associated with the upper pole of the kidney (Weigert, 1877; Meyer, 1907). As the common nephric duct was incorporated into the bladder, the more caudal bud became incorporated into the trigone first, which resulted in a ureteral orifice within the bladder wall more cephalad and lateral to that normally seen in the case of a single ureter. The cranial duplicate ureteric bud was incorporated later into the bladder, and became associated with the upper pole of the eventual kidney. Because of the delay in incorporation of the cranial ureteric bud into the bladder, this upper pole ureter was positioned caudal and medial to the lower pole ureter. This relationship has become known as the Weigert-Meyer rule, and describes most known cases of defects in the muscular pattern of the ureterovesical junction in the bladder trigone (Shapiro, 2009). In some cases, the upper pole ureter may not be fully incorporated into the bladder at all, and may insert ectopically into the upper part of the vagina or urethra in females or Wolffian duct derivatives in males (the seminal vesicle or vas deferens). Many cases of duplication without ectopy have no clinical symptoms, but ectopic ureters frequently demonstrate clinical findings, from hydronephrosis to incontinence (in females) (Fig. 8).

5. Clinical correlation: vesicoureteral reflux

Vesicoureteral reflux is a common finding in children, with an incidence of 1–2%, of the general population, but as high as 50% in familial lines, suggesting autosomal dominant inheritance (Mak and Kuo, 2003). However, most vesicoureteral reflux is of no consequence clinically. In cases of more severe reflux along with urinary tract infection, though, pyelonephritis and renal scarring can be a consequence (Hoberman et al., 2014).

As seen in Fig. 6, it is thought that reflux occurs due to deficiencies in the musculature of the trigone, resulting in a relatively short intramural tunnel. As the bladder grows normally, the musculature of the trigone develops further, which is thought to result in spontaneous resolution of less severe reflux. More severe reflux is thought to be associated with abnormal signalling from the ureteral bud, resulting in renal dysplasia with associated reflux (Tanagho and Hutch, 1965). This is borne out in a mouse model; renal dysplasia and reflux are seen together in several mutations (Murawski et al., 2011).

Uroplakins are also implicated in vesicoureteral reflux, and ablation of the mouse uroplakin III gene results in small, abnormal urothelial plaques and enlarged ureteral orifices resulting in reflux (Hu et al., 2000). Reflux is also seen in mice with uroplakin II deficiencies, and knockout of multiple uroplakin heterodimers results in absence of urothelial plaque formation and disruption of the normal function of urothelium (Kong et al., 2004). Despite these findings in the mouse, the role of uroplakins in human vesicoureteral reflux is not clear (Jenkins et al., 2006). Genetic linkage studies in 126 sibling pairs with reflux did not show any linkage or association at the human uroplakin III locus

(Kelly et al., 2005). Similarly, Jiang et al. sequenced all four uroplakin genes in 76 patients with vesicoureteral reflux and found only one weak association of a single nucleotide mutation in uroplakin III (UPIII SNP7) with reflux, suggesting that missense changes in human uroplakin genes are not a dominant factor in human vesicoureteral reflux (Jiang et al., 2004).

Clinically, most cases of human vesicoureteral reflux are not associated with renal dysplasia. While several mouse models exist that show renal normoplasia as well as reflux (Murawski et al., 2011), only one has had the causative mutation identified, which is the C3H/HeJ mouse, which shows a 100% incidence of vesicoureteral reflux with otherwise normal kidneys at birth (Murawski et al., 2010). This defect has been mapped to the locus *Vurm1* on chromosome 12, but this locus also works in conjunction with other loci elsewhere in the genome. Primary vesicoureteral reflux is a complex condition genetically, and while familial inheritance and associations are known, the underlying developmental causes remain elusive.

6. Clinical correlation: bladder exstrophy

Bladder exstrophy manifests as the failure of development of the abdominal wall, resulting in a lower abdominal wall defect, disjunction of the pubic symphysis, absence of the anterior wall of the bladder, an anteriorly open prostatic urethra and absence of the dorsal aspect of the penis (epispadias). Exstrophy occurs along a spectrum, ranging from epispadias to more extensive exstrophy including the hindgut, and is clinically referred to as exstrophy-epispadias complex, occurring in approximately 1:30,000 live births.

Many theories have been advanced to explain this spectrum of malformations, but the mechanism remains unknown. Mildenberger et al. proposed that the insertion of the body stalk of the embryo is too caudal, contacting the cranial end of the cloacal membrane (Mildenberger et al., 1988). As a result, normal mesenchymal tissue cannot infiltrate into this region, leaving the affected structures without the covering of skin, an abdominal wall defect, disjunction of the pubic symphysis and the spectrum of urogenital defects described above. Stephens suggested that the embryonic tail, which regresses by 8 weeks of gestation, may temporarily compress and disrupt the mesoderm that separates the cloaca and allantois, forming part of the phallus (Stephens and Hutson, 2005). By this theory, isolated epispadias may arise from this mechanical obstruction, rather than being related to the greater exstrophy-epispadias complex. Thomalla et al. disrupted the cloacal membrane of chicks with a laser, inducing cloacal exstrophy in ~10% of the embryos that were treated in this manner (Thomalla et al., 1985).

Overall, the theories for emergence of bladder exstrophy propose a mechanism based on obstruction or failure of mesenchymal migration (Mildenberger et al., 1988; Stephens and Hutson, 2005), premature rupture of the cloacal membrane (Stec, 2011; Thomalla et al., 1985), abnormal cell-cell interactions or alteration in cell death (Vermeij-Keers et al., 1996). Most recently, Kumar et al. proposed that the persistence of pubic diastasis – an open bony pelvis where the bones of the pubic symphysis are not connected – was the proximate cause (Kumar et al., 2015). This observation is based on several considerations: The complexity of associated anomalies are rare, which is inconsistent with a single underlying genetic or signalling defect. Furthermore, the tissues of the affected structures (i.e. the bladder and pelvis) are largely normal at the cellular and morphogenetic levels, which would again be unusual based upon an underlying genetic or signalling defect. In addition, the human embryo does not pass through a stage where an exstrophic bladder is normal, suggesting that exstrophy is not likely to be due to interruption of the normal process of development (Kumar et al., 2015). Pubic diastasis, on the other hand, is normal in early development, with the pubic symphysis closing at around 8–10 weeks of gestation. Within a closed pubic arch, the levator ani muscles form a ring around the developing hindgut and urogenital sinus. While in a state of pubic diastasis, however, the pelvic musculature rests posterior to the hindgut

and urogenital sinus, and as the musculature develops further, may exert posterior pressure on the anterior structures, disrupting the forming abdominal wall and leading to exstrophy. While an intriguing theory, there is scant scientific evidence for this or any of the embryologic theories of exstrophy.

In conclusion, the bladder forms from urogenital sinus and the urterovesical junction from distal Wolffian duct. The bladder trigone is primarily derived from urogenital sinus mesenchyme. Three major interrelated gene pathways have been identified in bladder development; *Shh*, *TGF β* , and *Fgfr2*. The position of the ureteral orifice is dependent on vitamin-A mediated apoptosis and *Raldh2*. Abnormal development of the bladder and trigone can result in a variety of clinical conditions such as vesicoureteral reflux, duplicated ureters and bladder exstrophy.

References

- Abouseif, S., El-Sakka, A., Young, P., Cunha, G., 1999. Mesenchymal reprogramming of adult human epithelial differentiation. *Differ. Res. Biol. Divers.* 65 (2), 113–118. <https://doi.org/10.1046/j.1432-0436.1999.6520113.x>.
- Baskin, L., Cunha, G., 2018. In: Campbell, M., Walsh, P. (Eds.), *Embryology of the Human Genitourinary Tract*. Saunders, Philadelphia, PA.
- Baskin, L.S., Hayward, S.W., Sutherland, R.A., DiSandro, M.S., Thomson, A.A., Cunha, G.R., 1997. Cellular signaling in the bladder. *Front. Biosci. A J. Virtual Libr.* 2, 592.
- Baskin, L.S., Hayward, S.W., Sutherland, R.A., DiSandro, M.J., Thomson, A.A., Goodman, J., Cunha, G.R., 1996a. Mesenchymal-epithelial interactions in the bladder. *World J. Urol.* 14 (5), 301. <https://doi.org/10.1007/BF00184602>. (Retrieved from). <http://www.ncbi.nlm.nih.gov/pubmed/8912470>.
- Baskin, L., Hayward, S.W., Young, P., Cunha, G.R., 1996b. Role of mesenchymal-epithelial interactions in normal bladder development. *J. Urol.* 156 (5), 1820–1827.
- Baskin, L.S., Kogan, B.A., Stock, J., 2018. *Handbook of Pediatric Urology*, 3rd ed. Wolters Kluwer, Philadelphia, PA.
- Baskin, L., Meaney, D., Landsman, A., Zderic, S.A., Macarak, E., 1994. Bovine bladder compliance increases with normal fetal development. *J. Urol.* 152 (2 Pt 2), 697.
- Basson, M.A., Watson-Johnson, J., Shakya, R., Akbulut, S., Hyink, D., Costantini, F.D., Licht, J.D., 2006. Branching morphogenesis of the ureteric epithelium during kidney development is coordinated by the opposing functions of GDNF and Sprouty1. *Dev. Biol.* 299 (2), 466–477. <https://doi.org/10.1016/j.ydbio.2006.08.051>.
- Batourina, E., Choi, C., Paragas, N., Bello, N., Hensle, T., Costantini, F.D., Mendelsohn, C.L., 2002. Distal ureter morphogenesis depends on epithelial cell remodeling mediated by vitamin A and ret. *Nat. Genet.* 32 (1), 109–115. <https://doi.org/10.1038/ng952>.
- Batourina, E., Tsai, S., Lambert, S., Sprengle, P., Viana, R., Dutta, S., Mendelsohn, C.L., 2005. Apoptosis induced by vitamin A signaling is crucial for connecting the ureters to the bladder. *Nat. Genet.* 37 (10), 1082–1089. <https://doi.org/10.1038/ng1645>.
- Beauboeuf, A., Ordille, S., Erickson, D.R., Ehrlich, H.P., 1998. In vitro ligation of ureters and urethra modulates fetal mouse bladder explants development. *Tissue Cell* 30 (5), 531–536.
- Besnard, V., Wert, S.E., Hull, W.M., Whitsett, J.A., 2004. Immunohistochemical localization of Foxa1 and Foxa2 in mouse embryos and adult tissues. *Gene Expr. Pattern. GEP* 5 (2), 193–208. <https://doi.org/10.1016/j.modgep.2004.08.006>.
- Cao, M., Tasian, G., Wang, M., Liu, B., Cunha, G., Baskin, L., 2010. Urothelium-derived sonic hedgehog promotes mesenchymal proliferation and induces bladder smooth muscle differentiation. *Differ.; Res. Biol. Divers.* 79 (4–5), 244–250. <https://doi.org/10.1016/j.diff.2010.02.002>.
- Cheng, W., Yeung, C., Ng, Y., Zhang, J., Hui, C., Kim, P.C.W., 2008. Sonic hedgehog mediator Gli2 regulates bladder mesenchymal patterning. *J. Urol.* 180 (4), 1543–1550. <https://doi.org/10.1016/j.juro.2008.06.003>.
- Copp, H., Champeau, A., Holmes, N., 2018. Urinary tract infections in children. In: L. Baskin, B. Kogan, J. Stock (Eds.), *Pediatric Urology Handbook*. Wolters Kluwer, p. 53.
- Cunha, G.R., Fujii, H., Neubauer, B.L., Shannon, J.M., Sawyer, L., Reese, B.A., 1983a. Epithelial-mesenchymal interactions in prostatic development. I. morphological observations of prostatic induction by urogenital sinus mesenchyme in epithelium of the adult rodent urinary bladder. *J. Cell Biol.* 96 (6), 1662–1670.
- Cunha, G.R., Sekkingstad, M., Meloy, B.A., 1983b. Heterospecific induction of prostatic development in tissue recombinants prepared with mouse, rat, rabbit and human tissues. *Differ.; Res. Biol. Divers.* 24 (2), 174–180.
- Cunha, G.R., Vezina, C., Isaacson, D., Ricke, W.A., Timms, B., Baskin, L.S., 2018. Development of the human prostate (this issue).
- Diez-Roux, G., Banfi, S., Sultan, M., Geffers, L., Anand, S., Rozado, D., Ballabio, A., 2011. A high-resolution anatomical atlas of the transcriptome in the mouse embryo. *PLoS Biol.* 9 (1), e1000582. <https://doi.org/10.1371/journal.pbio.1000582>.
- DiSandro, M.J., Li, Y., Baskin, L., Hayward, S., Cunha, G., 1998. Mesenchymal-epithelial interactions in bladder smooth muscle: epithelial specificity. *J. Urol.* 160 (3), 1040–1046. [https://doi.org/10.1016/S0022-5347\(01\)62694-6](https://doi.org/10.1016/S0022-5347(01)62694-6). (Retrieved from). <https://www.sciencedirect.com/science/article/pii/S0022534701626946>.
- Freestone, S.H., Marker, P., Grace, O.C., Tomlinson, D.C., Cunha, G.R., Harnden, P., Thomson, A.A., 2003. Sonic hedgehog regulates prostatic growth and epithelial differentiation. *Dev. Biol.* 264 (2), 352–362.
- Gray, H., Clemente, C.D., 1985. *Anatomy of the Human Body*. Lea & Febiger, Philadelphia, Pennsylvania.
- Grieshammer, U., Le Ma, n., Plump, A.S., Wang, F., Tessier-Lavigne, M., Martin, G.R., 2004. SLIT2-mediated ROBO2 signaling restricts kidney induction to a single site. *Dev. Cell* 6 (5), 709–717.
- Haraguchi, R., Motoyama, J., Sasaki, H., Satoh, Y., Miyagawa, S., Nakagata, N., Yamada, G., 2007. Molecular analysis of coordinated bladder and urogenital organ formation by hedgehog signaling. *Development* 134 (3), 525–533. <https://doi.org/10.1242/dev.02736>.
- Herzlinger, D., Qiao, J., Cohen, D., Ramakrishna, N., Brown, A.M., 1994. Induction of kidney epithelial morphogenesis by cells expressing wnt-1. *Dev. Biol.* 166 (2), 815–818. <https://doi.org/10.1006/dbio.1994.1360>.
- Hoberman, A., Greenfield, S.P., Mattoo, T.K., Keren, R., Mathews, R., Pohl, H.G., Carpenter, M.A., 2014. Antimicrobial prophylaxis for children with vesicoureteral reflux. *New Engl. J. Med.* 370 (25), 2367–2376. <https://doi.org/10.1056/NEJMoa1401811>.
- Hu, P., Deng, F.M., Liang, F.X., Hu, C.M., Auerbach, A.B., Shapiro, E., Sun, T.T., 2000. Ablation of uroplakin III gene results in small urothelial plaques, urothelial leakage, and vesicoureteral reflux. *J. Cell Biol.* 151 (5), 961–972.
- Ikeda, Y., Zabarova, I., Schaefer, C.M., Bushnell, D., De Groat, W.C., Kanai, A., Bates, C.M., 2017. *Fgfr2* is integral for bladder mesenchyme patterning and function. *Am. J. Physiol. Ren. Physiol.* 312 (4), F618. <https://doi.org/10.1152/ajprenal.000463.2016>.
- Islam, S.S., Mokhtari, R.B., Kumar, S., Maalouf, J., Arab, S., Yeger, H., Farhat, W.A., 2013. Spatio-temporal distribution of smads and role of smads/TGF- β /BMP-4 in the regulation of mouse bladder organogenesis. *PLoS One* 8 (4), e61340. <https://doi.org/10.1371/journal.pone.0061340>.
- Jenkins, D., Bitner-Glindzic, M., Malcolm, S., Allison, J., de Bruyn, R., Flanagan, S., Woolf, A.S., 2006. Mutation analyses of uroplakin II in children with renal tract malformations. *Nephrol. Dial. Transplant. Off. Publ. Eur. Dial. Transplant. Assoc. - Eur. Ren. Assoc.* 21 (12), 3415–3421. <https://doi.org/10.1093/ndt/gf465>.
- Jenkins, D., Winyard, P.J.D., Woolf, A.S., 2007. Immunohistochemical analysis of sonic hedgehog signalling in normal human urinary tract development. *J. Anat.* 211 (5), 620–629. <https://doi.org/10.1111/j.1469-7580.2007.00808.x>.
- Jiang, S., Gitlin, J., Deng, F., Liang, F., Lee, A., Atala, A., Sun, T., 2004. Lack of major involvement of human uroplakin genes in vesicoureteral reflux: implications for disease heterogeneity. *Kidney Int.* 66 (1), 10–19. <https://doi.org/10.1111/j.1523-1755.2004.00703.x>.
- Kelly, H., Ennis, S., Yoneda, A., Bermingham, C., Shields, D.C., Molony, C., Barton, D.E., 2005. Uroplakin III is not a major candidate gene for primary vesicoureteral reflux. *Eur. J. Hum. Genet.* 13 (4), 500–502. <https://doi.org/10.1038/sj.ejhg.5201322>.
- Kim, K.M., Kogan, B.A., Massad, C.A., Huang, Y.C., 1991. Collagen and elastin in the normal fetal bladder. *J. Urol.* 146 (2 Pt 2), 524–527.
- Kong, X., Deng, F., Hu, P., Liang, F., Zhou, G., Auerbach, A.B., Sun, T., 2004. Roles of uroplakins in plaque formation, umbrella cell enlargement, and urinary tract diseases. *J. Cell Biol.* 167 (6), 1195–1204. <https://doi.org/10.1083/jcb.200406025>.
- Kromer, P., 1996. Development of the urorectal septum and differentiation of the urogenital sinus in human embryos of stages 13 to 19. *Folia Morphol.* 55 (4), 362–363.
- Kromer, P., 1999. Further study of the urorectal septum in staged human embryos. *Folia Morphol.* 58 (1), 53–63.
- Kumar, K., Mammen, A., Varma, K., 2015. Pathogenesis of bladder exstrophy: a new hypothesis. *J. Pediatr. Urol.* 11 (6), 314–318. <https://doi.org/10.1016/j.jpuro.2015.05.030>. (Retrieved from). <https://www.clinicalkey.es/playcontent/1-s2.0-S1477513115002727>.
- Le Guen, L., Marchal, S., Faure, S., de Santa Barbara, P., 2015. Mesenchymal-epithelial interactions during digestive tract development and epithelial stem cell regeneration. *Cell. Mol. Life Sci.: CMLS* 72 (20), 3883–3896. <https://doi.org/10.1007/s00018-015-1975-2>.
- Lu, W., Quintero-Rivera, F., Fan, Y., Alkuraya, F.S., Donovan, D.J., Xi, Q., Maas, R.L., 2007. NFIA haploinsufficiency is associated with a CNS malformation syndrome and urinary tract defects. *PLoS Genet.* 3 (5), e80. <https://doi.org/10.1371/journal.pgen.0030080>.
- Mak, R.H., Kuo, H., 2003. Primary ureteral reflux: emerging insights from molecular and genetic studies. *Curr. Opin. Pediatr.* 15 (2), 181–185.
- Mesrobian, H.G., Zacharias, A., Balcom, A.H., Cohen, R.D., 1997. Ten years of experience with isolated urethral anomalies in children. *J. Urol.* 158 (3 Pt 2), 1316–1318.
- Meyer, R., 1907. Zur anatomie und entwicklungsgeschichte der ureterverdoppelung. *Virchows Archiv für pathologische Anatomie und Physiologie und für klinische Medizin*, Berlin, 87, 408.
- Mildenberger, H., Kluth, D., Dziuba, M., 1988. Embryology of bladder exstrophy. *J. Pediatr. Surg.* 23 (2), 166–170.
- Miyazaki, Y., Oshima, K., Fogo, A., Ichikawa, I., 2003. Evidence that bone morphogenetic protein 4 has multiple biological functions during kidney and urinary tract development. *Kidney Int.* 63 (3), 835–844. <https://doi.org/10.1046/j.1523-1755.2003.00834.x>.
- L. Moore, K., Persaud, V., Torchia, M., 2013. The developing human. clinically oriented embryology.
- Murawski, I.J., Maina, R.W., Malo, D., Guay-Woodford, L.M., Gros, P., Fujiwara, M., Gupta, I.R., 2010. The C3H/HeJ inbred mouse is a model of vesico-ureteric reflux with a susceptibility locus on chromosome 12. *Kidney Int.* 78 (3), 269–278. <https://doi.org/10.1038/ki.2010.110>.
- Murawski, I., Watt, C., Gupta, I., 2011. Vesico-ureteric reflux: using mouse models to understand a common congenital urinary tract defect. *Pediatr. Nephrol.* 26 (9), 1513–1522. <https://doi.org/10.1007/s00467-011-1821-1>. (Retrieved from). <https://www.ncbi.nlm.nih.gov/pubmed/21424527>.
- Nievelstein, R.A., van der Werff, J.F., Verbeek, F.J., Valk, J., Vermeij-Keers, C., 1998. Normal and abnormal embryonic development of the anorectum in human embryos. *Teratology* 57 (2), 70–78 (AID-TERA5 > 3.0.CO;2-A).
- Oswald, J., Brenner, E., Deibl, M., Fritsch, H., Bartsch, G., Radmayr, C., 2003. Longitudinal and thickness measurement of the normal distal and intravesical ureter

- in human fetuses. *J. Urol.* 169 (4), 1501–1504. <https://doi.org/10.1097/01.ju.0000057047.82984.7f>.
- Rathke, H., 1832. *Abhandlungen zur bildungs- und entwickelungs-geschichte des menschen und der thierte.* Vogel, Leipzig (Retrieved from). <https://catalog.hathitrust.org/Record/009027670>.
- Robboy, S.J., Kurita, T., Baskin, L., Cunha, G.R., 2017. New insights into human female reproductive tract development. *Differ. Res. Biol. Divers.* 97, 9–22. <https://doi.org/10.1016/j.diff.2017.08.002>.
- Rogers, D.S., Paidas, C.N., Morreale, R.F., Hutchins, G.M., 2002. Septation of the anorectal and genitourinary tracts in the human embryo: crucial role of the catenoidal shape of the urorectal sulcus. *Teratology* 66 (4), 144–152. <https://doi.org/10.1002/tera.10041>.
- Shapiro, E., 2009. Clinical implications of genitourinary embryology. *Curr. Opin. Urol.* 19 (4), 427–433. <https://doi.org/10.1097/MOU.0b013e32832c90ff>. (Retrieved from). <http://www.ncbi.nlm.nih.gov/pubmed/19461520>.
- Shen, J., Cunha, G., Sinclair, A., Cao, M., Isaacson, D., Baskin, L., 2018. Macroscopic whole-mounts of the developing human fetal urogenital-genital tract: indifferent stage to male and female differentiation. *Differentiation* (this issue).
- Shiroyanagi, Y., Liu, B., Cao, M., Agras, K., Li, J., Hsieh, M.H., Baskin, L.S., 2007. Urothelial sonic hedgehog signaling plays an important role in bladder smooth muscle formation. *Differ. Res. Biol. Divers.* 75 (10), 968–977. <https://doi.org/10.1111/j.1432-0436.2007.00187.x>.
- Stec, A.A., 2011. Embryology and bony and pelvic floor anatomy in the bladder exstrophy-epispadias complex. *Semin. Pediatr. Surg.* 20 (2), 66–70. <https://doi.org/10.1053/j.sempedsurg.2010.12.011>.
- Stephens, F.D., Hutson, J.M., 2005. Differences in embryogenesis of epispadias, exstrophy-epispadias complex and hypospadias. *J. Pediatr. Urol.* 1 (4), 283–288. <https://doi.org/10.1016/j.jpuro.2005.01.008>.
- Tacciuoli, M., Lotti, T., de Matteis, A., Laurenti, C., 1975. Development of the smooth muscle of the ureter and vesical trigone: histological investigation in human fetus. *Eur. Urol.* 1 (6), 282–286.
- Tanagho, E.A., 1976. Embryologic basis for lower ureteral anomalies: a hypothesis. *Urology* 7 (5), 451–464.
- Tanagho, E.A., Hutch, J.A., 1965. Primary reflux. *J. Urol.* 93, 158–164.
- Tanaka, S.T., Ishii, K., Demarco, R.T., Pope, J.C., Brock, J.W., Hayward, S.W., 2010. Endodermal origin of bladder trigone inferred from mesenchymal-epithelial interaction. *J. Urol.* 183 (1), 386–391. <https://doi.org/10.1016/j.juro.2009.08.107>.
- Tasian, G., Cunha, G., Baskin, L., 2010. Smooth muscle differentiation and patterning in the urinary bladder. *Differ. Res. Biol. Divers.* 80 (2–3), 106–117. <https://doi.org/10.1016/j.diff.2010.05.004>.
- Thomalla, J.V., Rudolph, R.A., Rink, R.C., Mitchell, M.E., 1985. Induction of cloacal exstrophy in the chick embryo using the CO₂ laser. *J. Urol.* 134 (5), 991–995.
- Tourneux, F., 1888. Sur les premiers développements du cloaque du tubercule genital et de l'anus chez l'embryon de mouton. *J. Anat.* 24, 503–517.
- Vakar-Lopez, F., Shen, S.S., Zhang, S., Tamboli, P., Ayala, A.G., Ro, J.Y., 2007. Muscularis mucosae of the urinary bladder revisited with emphasis on its hyperplastic patterns: a study of a large series of cystectomy specimens. *Ann. Diagn. Pathol.* 11 (6), 395–401. <https://doi.org/10.1016/j.anndiagpath.2006.12.014>.
- Vermeij-Keers, C., Hartwig, N.G., van der Werff, J.F., 1996. Embryonic development of the ventral body wall and its congenital malformations. *Semin. Pediatr. Surg.* 5 (2), 82–89.
- Viana, R., Batourina, E., Huang, H., Dressler, G.R., Kobayashi, A., Behringer, R.R., Mendelsohn, C., 2007. The development of the bladder trigone, the center of the anti-reflux mechanism. *Development* 134 (20), 3763–3769. <https://doi.org/10.1242/dev.011270>.
- Wang, G.J., Brenner-Anantharam, A., Vaughan, E.D., Herzlinger, D., 2009. Antagonism of BMP4 signaling disrupts smooth muscle investment of the ureter and ureteropelvic junction. *J. Urol.* 181 (1), 401–407. <https://doi.org/10.1016/j.juro.2008.08.117>.
- Wang, C., Wang, J., Borer, J.G., Li, X., 2013. Embryonic origin and remodeling of the urinary and digestive outlets. *PLoS One* 8 (2), e55587. <https://doi.org/10.1371/journal.pone.0055587>.
- Weigert, C., 1877. Über einige bildungsfehler der ureteren. [Virchows] *Archiv für pathologische Anatomie und Physiologie und für klinische Medizin*, Berlin, 70, 490.
- Woolf, A.S., Davies, J.A., 2013. Cell biology of ureter development. *J. Am. Soc. Nephrol.* 24 (1), 19–25. <https://doi.org/10.1681/ASN.2012020127>. (Retrieved from). <http://www.ncbi.nlm.nih.gov/pubmed/23123402>.
- Zhang, T., Zhang, H.L., Wang, D.J., Tang, X.B., Jia, H.M., Bai, Y.Z., Wang, W.L., 2011. Normal development of hindgut and anorectum in human embryo. *Int. J. Colorectal Dis.* 26 (1), 109–116. <https://doi.org/10.1007/s00384-010-1034-2>.