

# UCSF

## UC San Francisco Previously Published Works

### Title

Expansion of phenotype and genotypic data in CRB2-related syndrome

### Permalink

<https://escholarship.org/uc/item/2qk9t640>

### Journal

European Journal of Human Genetics, 24(10)

### ISSN

1018-4813

### Authors

Lamont, Ryan E  
Tan, Wen-Hann  
Innes, A Micheil  
et al.

### Publication Date

2016-10-01

### DOI

10.1038/ejhg.2016.24

Peer reviewed

ARTICLE

# Expansion of phenotype and genotypic data in CRB2-related syndrome

Ryan E Lamont<sup>1</sup>, Wen-Hann Tan<sup>2</sup>, A Micheil Innes<sup>1</sup>, Jillian S Parboosingh<sup>1</sup>, Dina Schneidman-Duhovny<sup>3,4</sup>, Aleksandar Rajkovic<sup>5</sup>, John Pappas<sup>6</sup>, Pablo Altschwager<sup>7,8</sup>, Stephanie DeWard<sup>9</sup>, Anne Fulton<sup>7</sup>, Kathryn J Gray<sup>2</sup>, Max Krall<sup>10</sup>, Lakshmi Mehta<sup>11</sup>, Lance H Rodan<sup>2</sup>, Devereux N Saller Jr<sup>5</sup>, Deanna Steele<sup>5</sup>, Deborah Stein<sup>12</sup>, Svetlana A Yatsenko<sup>5</sup>, François P Bernier<sup>1</sup> and Anne M Slavotinek<sup>\*,10</sup>

Sequence variants in *CRB2* cause a syndrome with greatly elevated maternal serum alpha-fetoprotein and amniotic fluid alpha-fetoprotein levels, cerebral ventriculomegaly and renal findings similar to Finnish congenital nephrosis. All reported patients have been homozygotes or compound heterozygotes for sequence variants in the Crumbs, Drosophila, Homolog of, 2 (*CRB2*) genes. Variants affecting *CRB2* function have also been identified in four families with steroid resistant nephrotic syndrome, but without any other known systemic findings. We ascertained five, previously unreported individuals with biallelic variants in *CRB2* that were predicted to affect function. We compiled the clinical features of reported cases and reviewed available literature for cases with features suggestive of *CRB2*-related syndrome in order to better understand the phenotypic and genotypic manifestations. Phenotypic analyses showed that ventriculomegaly was a common clinical manifestation (9/11 confirmed cases), in contrast to the original reports, in which patients were ascertained due to renal disease. Two children had minor eye findings and one was diagnosed with a B-cell lymphoma. Further genetic analysis identified one family with two affected siblings who were both heterozygous for a variant in *NPHS2* predicted to affect function and separate families with sequence variants in *NPHS4* and *BBS7* in addition to the *CRB2* variants. Our report expands the clinical phenotype of *CRB2*-related syndrome and establishes ventriculomegaly and hydrocephalus as frequent manifestations. We found additional sequence variants in genes involved in kidney development and ciliopathies in patients with *CRB2*-related syndrome, suggesting that these variants may modify the phenotype.

*European Journal of Human Genetics* (2016) 24, 1436–1444; doi:10.1038/ejhg.2016.24; published online 23 March 2016

## INTRODUCTION

We recently described six individuals from three families who shared a novel phenotype characterized by greatly elevated maternal serum alpha-fetoprotein (MSAFP) and/or amniotic fluid alpha-fetoprotein (AFAFP), cerebral ventriculomegaly, and echogenic kidneys with microcysts and histopathological findings consistent with congenital nephrosis (OMIM 219730).<sup>1</sup> Less frequent findings included gray matter heterotopias and cardiac involvement with a ventricular septal defect and mild aortic dilatation. In all cases, compound heterozygosity or homozygosity for sequence variants predicted to affect function in Crumbs family member 2 (*CRB2*, OMIM 609720) were demonstrated.<sup>1</sup> We refer to this pleiotropic phenotype as *CRB2*-related syndrome. In a simultaneously published report, sequence variants in *CRB2* were also shown to cause steroid resistant nephrotic syndrome (SRNS) with renal histological findings of focal segmental glomerulosclerosis (OMIM 616220) in four families.<sup>2</sup> Studies in *Danio rerio* demonstrated that the sequence variants associated with apparently isolated SRNS failed to rescue a mutant *crb2b* phenotype.<sup>2</sup> As *crb2b* is an orthologous gene to *CRB2*, these sequence variants were

considered pathogenic for the renal abnormalities.<sup>2</sup> These patients did not have obvious cerebral or cardiac manifestations. Both of these reports showed that biallelic, sequence variants predicted to affect function in *CRB2* cause phenotypic effects ranging from a severe phenotype manifesting in the second trimester of pregnancy with significant ventriculomegaly and renal failure, to apparently isolated renal disease presenting postnatally.<sup>1,2</sup>

*Crb* function is important in the organization of epithelia derived from ectoderm during organogenesis and in the maintenance of epithelial cell polarity.<sup>3,4</sup> Expression studies in human tissues demonstrated expression of *CRB2* in the fetal eye and fetal cochlea, and in the retinal pigment epithelium, choroid, brain, kidney, heart, placenta and lung.<sup>5</sup> Complete loss of murine *Crb2* function causes widespread phenotypic effects, disrupting head folding, heart tube formation and foregut invagination.<sup>6</sup> However, the clinical and molecular genetic spectrum associated with deleterious sequence variants in *CRB2* has not been clearly defined. We hypothesized that the phenotype associated with variants in *CRB2* would be broader than previously reported and may include eye manifestations, as *CRB2* is expressed in

<sup>1</sup>Department of Medical Genetics and Alberta Children's Hospital Research Institute, University of Calgary, Calgary, Alberta, Canada; <sup>2</sup>Division of Genetics and Genomics, Boston Children's Hospital, Boston, MA, USA; <sup>3</sup>Department of Bioengineering and Therapeutic Sciences, University of California San Francisco, San Francisco, CA, USA; <sup>4</sup>Department of Pharmaceutical Chemistry, University of California San Francisco, San Francisco, CA, USA; <sup>5</sup>Center for Medical Genetics and Genomics, Magee-Womens Hospital of University of Pittsburgh Medical Center, Pittsburgh, PA, USA; <sup>6</sup>Clinical Genetic Services, Department of Pediatrics, NYU School of Medicine, New York, NY, USA; <sup>7</sup>Department of Ophthalmology, Boston Children's Hospital, Boston, MA, USA; <sup>8</sup>Department of Ophthalmology, Pontificia Universidad Católica de Chile, Santiago, Chile; <sup>9</sup>GeneDx, Inc., Gaithersburg, MD, USA; <sup>10</sup>Department of Pediatrics, University of California San Francisco, San Francisco, CA, USA; <sup>11</sup>Division of Medical Genetics, Icahn School of Medicine at Mount Sinai & Mount Sinai Medical Center, New York, NY, USA; <sup>12</sup>Division of Nephrology, Boston Children's Hospital, Boston, MA, USA

\*Correspondence: Professor A Slavotinek, Department of Pediatrics, University of California San Francisco, 1550 4th St, Room RH384D, Rock Hall RH384D, San Francisco 94143-2711, CA, USA. Tel: +1 415 514 1783; Fax: +1 415 502 2374; E-mail: slavotia@peds.ucsf.edu

Received 20 November 2015; revised 26 January 2016; accepted 17 February 2016; published online 23 March 2016

the fetal eye and sequence variants predicted to affect function in *CRB1*, a highly related family member, are associated with retinitis pigmentosa and Leber congenital amaurosis.<sup>7–10</sup> Herein, we present detailed descriptions of five additional individuals with sequence variants predicted to affect function in *CRB2* and review the medical literature for patients who fit the CRB2-related syndrome phenotype. We model the *CRB2* variants and re-examine exome data from two previously reported cases of CRB2-related syndrome for additional sequence variants. Our findings show that some patients with CRB2-related syndrome may present with a predominantly cerebral, rather than renal, phenotype.

## SUBJECTS AND METHODS

### Consent

Patient 2 was consented under a protocol (15-15275) approved by the Committee for Human Research at the University of California, San Francisco. Patients 3 and 4 were consented after approval by the conjoined Research Ethics Board of the University of Calgary. Patients 1 and 5 underwent clinical testing.

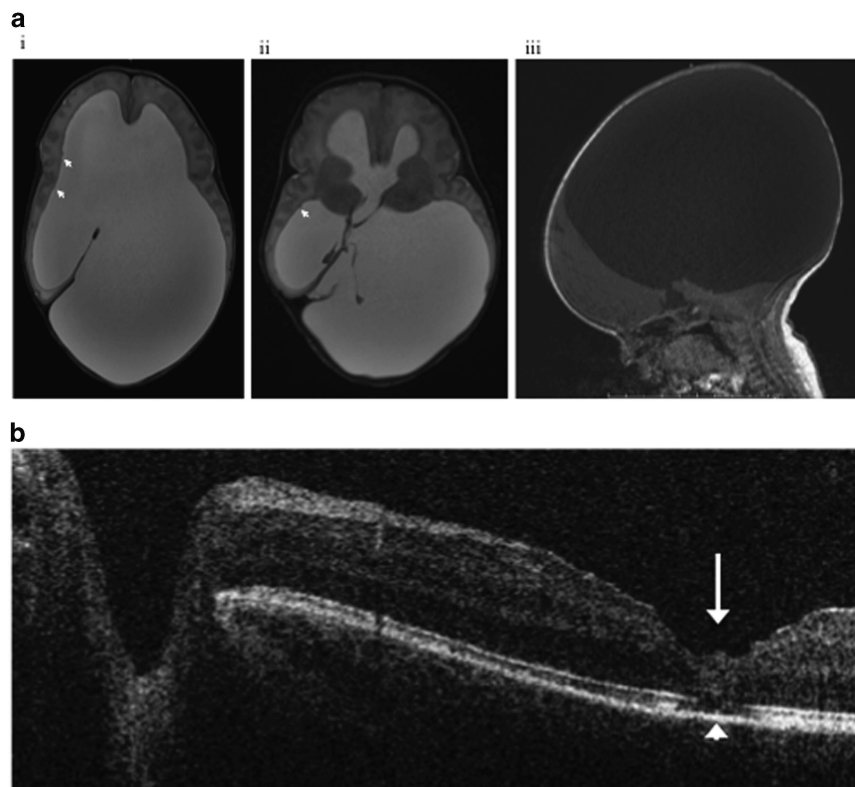
### Patient summaries

The first patient was an 8-month-old female who presented at 16 weeks' gestation with ultrasound (US) findings including bilateral ventriculomegaly, a mildly hypoplastic cerebellum and bilateral echogenic kidneys. MSAFP was 71 multiples of median (MoM) at 16 weeks' gestation. Magnetic resonance imaging (MRI) and US at 19 weeks' gestation showed persistent lateral ventriculomegaly measuring 14–15 mm bilaterally, prominent frontal horns, mild enlargement of the third ventricle, a large pericardial effusion, bilateral

nephromegaly with multiple macrocysts and moderate oligohydramnios. Repeat MRI and US at 22 weeks gestation showed progressive, asymmetric lateral ventriculomegaly, with atrial dimensions of 24 (left) and 16 (right) mm, severe thinning of the brain parenchyma most prominent over the parieto-occipital lobes, and a severely dilated third ventricle.

The baby was delivered at 37 weeks and 5 days gestation by cesarean section due to worsening macrocephaly and breech presentation. Birthweight was 3950 g (90th–97th percentile), length was 51 cm (75th–90th percentile), and head circumference (OFC) was 48.5 cm (>97th centile for age; +7.6 SD). She required continuous positive airway pressure due to respiratory distress and poor oxygen saturation. She was diagnosed with Scimitar syndrome based on the constellation of severely hypoplastic right lung, hypoplastic right pulmonary artery and dextroposition of the heart. She also had a small secundum atrial septal defect. Brain MRI on day 3 demonstrated asymmetric lateral ventriculomegaly, and subependymal gray matter heterotopias (Figure 1a). Endoscopic third ventriculostomy and bilateral endoscopic choroid plexus cauterization were performed at 3 weeks of age and her OFC improved, but she required ventriculoperitoneal (VP) shunt placement at 5 months of age. At 7 months of age, she demonstrated axial hypotonia with head lag, milder appendicular hypertonia, normal deep tendon reflexes and constant downward gaze. Developmentally she was unable to roll over completely, but she was able to rotate her head from side-to-side when she was supine and she was able to sit with support. She was able to bring her hands together and feed herself with a bottle. She had a social smile and was able to coo from 4–5 months of age.

Ophthalmologic examination at 2 months of age demonstrated slightly pale posterior retinae without pigmentary abnormalities. Full field electroretinography demonstrated scotopic amplitudes that were below average for age, but scotopic response parameters were within the 99% predicted normal intervals and photopic amplitudes were normal.<sup>11</sup> Repeat examination at 7 months of



**Figure 1** MRI scan of the brain and optical coherence tomography (OCT) in the first patient, demonstrating hydrocephalus and a retinal defect. (a) Axial T2-weighted sequences (i,ii) and sagittal T1-weighted sequence (iii). Imaging demonstrates asymmetric lateral (i,ii) and third ventriculomegaly (ii). There is volume loss of the cerebral cortex and white matter, particularly parietal and occipital lobes (i–iii). Heterotopic gray matter is present at the margins of the ventricles (arrows). The posterior fossa is displaced downwards (iii). (b) An OCT image of the left macula shows an identifiable pit (arrow) and a hole (short arrow) in the outer retinal laminae at the foveal site.

age revealed very low visual acuity (20/2000), high hyperopia, intermittent nystagmus and irregular retinal pigmentation. Optical coherence tomography of the left macula showed a hole in the outer retinal laminae at the foveal site (Figure 1b).

At 1 month of age, creatinine was at 0.8–0.9 mg/dl and estimated glomerular filtration rate was 30–35 ml/min/1.73 m<sup>2</sup>. Renal US revealed bilateral echogenic kidneys, loss of corticomedullary differentiation, multiple small cysts in both the kidneys and uterus didelphys. At about 6 months of age, she developed systolic hypertension that necessitated treatment with amlodipine. Her creatinine remained elevated at 1.0–1.2 mg/dl until she was 8 months old when it increased to 1.7 mg/dl and she continues to have persistent microscopic proteinuria, hematuria and mild glycosuria, suggestive of tubular dysfunction. She does not have nephrotic syndrome and her renal findings are most consistent with dysplasia. Her postnatal length and weight have tracked within the normal ranges.

The second patient was a male born to a 28-year-old G2 P0101 female who had MSAFP and AFAFP levels of 11 MoM and 96 MoM, respectively during the pregnancy. An US at 31 weeks' gestation demonstrated severe bilateral ventriculomegaly with hydrocephalus, echogenic kidneys and echogenic bowel. The baby was delivered at 35 weeks' gestation by emergency C-section and birthweight was 3360 g (>97th percentile), length was 48.5 cm (90th percentile) and OFC was 45 cm (>97th percentile; +8.3 SD). Intubation and continuous positive airway pressure were transiently required for respiratory distress. Physical examination revealed macrocephaly with an abnormal skull contour, 'boggy' anterior and posterior fontanels and widely split sutures. Tone was generally increased, but there were no focal neurological signs. Cranial US confirmed bilateral enlargement of the lateral ventricles with loss of the interventricular septum. An MRI on the second day of life showed occlusive hydrocephalus secondary to aqueductal stenosis, with subependymal heterotopias. An electroencephalogram was negative for seizures, but was reported to be abnormal, with continuous polymorphic slowing and spike discharges in the left posterior quadrant and attenuation of fast frequencies in the right temporal area. A VP shunt was placed on day 5 and subsequent US demonstrated a minimal decrease in ventricular size.

Renal US on the first day of life showed increased echogenicity of the bilateral renal cortices and loss of corticomedullary differentiation. The kidneys were in their expected locations and each measured 4.4 cm in length. A microarray showed no diagnostic copy number variants.

The third and fourth patients were a sibling pair. The older affected child (V-5, Supplementary Figure S1) had persistent echogenicity of the kidneys and ventriculomegaly on US at 18 weeks' gestation. MSAFP was not obtained. There was prenatal progression of the ventriculomegaly consistent with aqueductal stenosis and persistent echogenicity and enlargement of the kidneys. She was born at 39 weeks' gestation by C-section due to breech presentation and macrocephaly; OFC was not available. A renal biopsy at 8 days of age showed increased glomerular immaturity, minor tubular cyst formation and small crystalline deposits, and there was no effacement of the podocyte foot processes on electron microscopy. The biopsy was consistent with nephrotic syndrome, Finnish type. She required insertion of a VP shunt due to macrocephaly caused by massive dilation of the ventricles and aqueductal stenosis. A large arachnoid cyst in quadrigeminal system was also identified on brain MRI. At 8 months of age, she developed focal seizures and generalized spikes and waves on her electroencephalogram. Her epilepsy proved difficult to treat and she developed significant global developmental delays. Auditory brainstem response testing demonstrated mild to moderate hearing loss on the right and severe hearing loss on the left ear. An ophthalmological examination revealed mild optic atrophy. Her renal function remained relatively stable despite significant proteinuria; however, she developed a B-cell lymphoma at three years of age and died shortly thereafter due to complications from her chemotherapy.

Her younger sister (V-6, Supplementary Figure S1) was also found to have persistent echogenicity of the kidneys and ventriculomegaly on US at 20 weeks' gestation. She developed more severe hydrocephalus than her sister, with marked enlargement of the lateral and third ventricles such that, by full term, there was only a faint cortical rim of cerebral tissue. Her kidneys were also markedly enlarged and diffusely echogenic, however amniotic fluid volumes remained normal. MSAFP was not obtained. She was delivered at 39 weeks'

gestation by C-section and had significant macrocephaly (+5 SD) due to severe hydrocephalus. Her postnatal imaging could not identify any significant cerebral tissue and based on this finding, she entered a palliative care program and died at 8 days of age. Autopsy confirmed near absence of cerebral tissue, with the supratentorial structures represented by only thin meninges, a midline falx and abundant cerebrospinal fluid. The kidneys were greatly enlarged, with minimal cysts and histological findings consistent with Finnish nephrosis.

History for the fifth patient was obtained from the mother, but permission to access medical records was denied. Cerebral ventriculomegaly was detected on US during the pregnancy, but there were no reports of kidney abnormalities. A female was born by vaginal delivery and hydrocephalus was confirmed on a postnatal brain MRI. A VP shunt was placed at 5 days of life. The child walked at 17 to 18 months of life and talked at the expected age. She had seizures at 4 years of age that resolved. At 6 years of age, her growth and intelligence were normal and she was attending a mainstream school without services. She wore glasses for myopia and funduscopy reportedly revealed a right-sided, 'faded' optic nerve. She had no other significant illnesses and a renal US was normal at 6 years of age.

### Literature review

We performed a literature search in PubMed for other reported cases using the term 'hydrocephalus' together with 'nephrosis', and identified several case reports.<sup>12–16</sup> We also reviewed all cases reported in PubMed under the term 'Galloway-Mowat syndrome', since this syndrome involves the combination of nephrotic syndrome and cerebral malformations.<sup>17</sup> Searches were also performed using the terms 'elevated AFP' and 'hydrocephalus' or 'nephrosis'.

### Molecular genetic testing

For the first patient, *CRB2* sequencing was performed on a NextGen platform clinically through GeneDx (GeneDx XomeDxSlice, GeneDx, Inc., Gaithersburg, MD, USA) due to a high *a priori* suspicion that this was the etiology of her clinical presentation. However, since a ciliopathy was on the differential diagnoses, Ciliopathies NextGen sequencing and deletion/duplication panels (Emory Genetics Lab; <http://geneticslab.emory.edu/tests/MCL1>) was also recommended. For the second patient, sequencing of *CRB2* only was performed using Sanger sequencing.<sup>18</sup> For the third and fourth patients, homozygosity mapping was performed using the human GeneChip Mapping 10K 2.0 SNP genotyping array (Affymetrix, Santa Clara, CA, USA) on the third patient only, followed by identity-by-descent mapping using HomozygosityMapper.<sup>19</sup> Whole exome sequencing (WES) was undertaken using the SureSelect exome kit v3 (Agilent, Mississauga, ON, USA) and sequenced on a SOLiD 5500xl (ThermoFisher, Burlington, ON, USA). *CRB2* regions not sufficiently covered by WES were backfilled using Sanger sequencing. The fifth patient underwent WES as a clinical test (GeneDx, Inc.). Variants from individuals 1, 2, 3 and 4 have been submitted to the Leiden Open Variant Database (<http://www.LOVD.nl/CRB2>); variants from individual 5 were previously described.

### Re-analysis of exome data

We obtained and re-analyzed the annotated variant call format (.vcf) files from two previously reported patients (Family 1, sib 2<sup>1</sup> and Family 2, sib 2<sup>1</sup>), to search for variants in genes involved in the pathogenesis of nephrosis and ciliopathies (genes listed in Supplementary Table S1). We used SnpEff<sup>20</sup> to filter for highly deleterious and moderately deleterious variants that had a European allele frequency of <1% according to 1000 genomes (<http://www.1000genomes.org/>). The potential deleteriousness of sequence variants was assessed using SIFT,<sup>21</sup> Polyphen-2<sup>22</sup> and Mutation Taster.<sup>23</sup>

### Protein modeling

Sequence variants in *CRB2* were modeled as previously described.<sup>1</sup>

## RESULTS

### Patient summaries and literature review

The phenotypic features for the five new cases with *CRB2* variants are summarized in Table 1, together with reported findings from the six

**Table 1 Clinical findings in patients with CRB2-related syndrome with *CRB2* mutations<sup>a</sup>**

	Patient 1	Patient 2	Patients 3 and 4 (V-5 and V-6; Supplementary Figure S1)	Patient 5	Reported families (n = 6) reference <sup>1</sup>	Total (n = 11)
Age at diagnosis	16 w <sup>b</sup> gestation	19 w 5 d <sup>c</sup>	Pregnancy	Pregnancy	16–20 w gestation	
<i>Central nervous system</i>						
Ventriculomegaly	+, 14–15 mm	+	+, 2/2	+	4/6	9/11
Aqueductal stenosis		+	+, 2/2			3/11
Gray matter heterotopias	+	+			1/6	3/11
Cerebellar hypoplasia	+, Mild					1/11
Quadrigeminal cyst			+, 1/2			1/11
Seizures			+, 1/2			1/11
<i>Cardiac</i>						
Ventricular septal defect					1/6	1/11
Atrial septal defect	+					1/11
Pericardial effusion	+				1/6	2/11
Scimitar syndrome	+					1/11
<i>Renal</i>						
Renal echogenicity	+	+	+, 2/2		2/6	6/11
Micro- or macrocysts	+				3/6	4/11
Finnish nephrosis			+, 2/2		1/6	3/11
<i>Eye</i>						
Abnormal retinae	+					1/11
Abnormal optic nerve			+, 1/2	+		2/11
<i>Other</i>						
Uterus didelphys	+					1/11
B-cell lymphoma			+, 1/2			1/11
Outcome	Alive 8 m <sup>d</sup>	Alive 2 m	Deceased; 1 w and 3 y <sup>e</sup>	Alive 6 y	Variable	Variable
<i>Amniotic fluid testing</i>						
MSAFP <sup>f</sup>	+, 36–71 MoM <sup>g</sup>	+, 11 MoM	Not done		5/5; 5–18 MoM <sup>h</sup>	7/7
AFAFP <sup>i</sup>		+, 96 MoM	Not done		5/5; 18–89 MoM	6/6
<i>Investigations</i>						
Karyotype		46,XY	Normal		4/4 Normal	4/4
Array CGH <sup>j</sup>	Normal	Normal			4/4 Normal	Normal
<i>NPHS1</i> sxequencing	–	Not done	–	Not done	1/6; c.1440+1G>A	6/6
<i>NPHS2</i> sequencing	–	Not done	p.Arg229Gln	Not done	–	Normal
Other sequencing	<i>BBS7</i> mutation	Not done	–	Not done	<i>NPHS4</i> mutation	
<i>CRB2</i> sequencing	p.Arg1115Cys/ p.Cys1098Ser <i>fs</i> *53	p.Cys1129Arg/ p.Gly1036Ala <i>fs</i> *43	p.Trp498Cys/ p.Asp1076Ala (both HZ <sup>k</sup> )	p.Glu643Ala/ p.Asn800Lys	Various	–

<sup>a</sup>Cases with isolated SRNS were not included in this analysis.

<sup>b</sup>w = weeks.

<sup>c</sup>d = days.

<sup>d</sup>m = months.

<sup>e</sup>y = years.

<sup>f</sup>MSAFP = Maternal serum alpha-fetoprotein.

<sup>g</sup>MoM = Multiple of Median.

<sup>h</sup>5–18 MoM = measurements were in twins.

<sup>i</sup>AFAFP = Amniotic fluid alpha-fetoprotein.

<sup>j</sup>Array CGH = array comparative genomic hybridization.

<sup>k</sup>HZ = homozygous.

published patients with CRB2-related syndrome.<sup>1</sup> MSAFP and AFAFP were elevated in all patients tested, and in one instance, AFAFP was elevated to 96 MoM. These values were indicative of fetal proteinuria. Cerebral ventriculomegaly was present in 5/5 of the new patients and 9/11 (82%) overall; ventriculomegaly was associated with aqueductal stenosis in 3/11 (27%). Gray matter heterotopias were noted

in 3/11 (27%). Renal findings were present in 4/5 new patients, with either cystic kidney disease or Finnish nephrosis. There were single reports of a ventricular septal defect and an atrial septal defect with Scimitar syndrome. Two patients had abnormal optic nerves and one had with very low visual acuity and irregular retinal pigmentation. The variability in clinical outcome was striking, ranging from isolated renal

**Table 2 Clinical findings in patients with probable CRB2-related syndrome who have not undergone CRB2 mutation analysis**

	Reference <sup>15</sup> ; (1 and 2)	Reference <sup>12</sup> ; (1 and 2)	Reference <sup>16</sup> ; (V-1, V-2, V-3, V-6, V-9, V-10)	Reference <sup>13</sup>	Reference <sup>14</sup> ; (Family A Sibs 1–3)	Reference <sup>14</sup> ; (Family B Sib 1)	Total (n = 15)
Age at diagnosis		3–17 w <sup>a</sup>	16–32 w gestation	18 w	12–20 w gestation	15 w gestation	
<i>Central nervous system</i>							
Ventriculomegaly	+, 2/2	+, 1/2	+, 6/6	+	+, 3/3	+, 'borderline'	14/15
Aqueductal stenosis	+, 1/2	+, 1/2					2/15
Heterotopias	+, 1/2 <sup>b</sup>	+, 1/2					2/15
Hyperpl. choroid plexus <sup>c</sup>			+				1/15
<i>Cardiac</i>							
Pericardial effusion					+, 1/3	+	2/15
<i>Renal</i>							
Renal echogenicity		+, 1/2	+, 6/6			+	8/15
Micro- or macrocysts	+, 1/2		+		+, 1/3		3/15
Nephrosis	+, ½	+, 1/2		+	+, 1/3		4/15
<i>Other</i>							
Polydactyly			1/6				1/15
Outcome	Variable	Variable	SB <sup>d</sup> x1; TOP <sup>e</sup> x 5	TOP	TOP x 3	TOP	Variable
<i>Amniotic Fluid Testing</i>							
MSAFP <sup>f</sup>	Elevated sib 1		5/5 elevated	+, elevated	8–29 MoM <sup>g</sup>	21 MoM	9/9
AFAFP <sup>h</sup>	Elevated sib 2	20x ↑ (sib 2)	5/5 abnormal		13 MoM in sib	24 MoM	4/4
AF <sup>i</sup> Acetylcholinesterase					2	faint	5/6
<i>Investigations</i>							
Karyotype	46,XX in sib 2	46,XY in (2)	3/3 normal		46,XX in sib 2	46,XX	Normal
NPHS1 Sequencing					Normal in sib 2		Normal

<sup>a</sup>w = weeks.

<sup>b</sup>described as raised cellular nodules on the ependymal surface of the lateral ventricles.

<sup>c</sup>Hyperpl. choroid plexus = Hyperplasia of choroid plexus' MSAFP.

<sup>d</sup>SB = stillbirth.

<sup>e</sup>TOP = Termination of Pregnancy

<sup>f</sup>Maternal serum alpha-fetoprotein.

<sup>g</sup>MoM = Multiple of Median.

<sup>h</sup>AFAFP = Amniotic fluid alpha-fetoprotein; AF Acetylcholinesterase.

<sup>i</sup>Amniotic fluid acetylcholinesterase.

disease or cerebral ventriculomegaly that were successfully treated to a severe presentation in the second trimester with multiple malformations. However, the medical records from one child with a milder phenotype were not examined, and it is possible that there were additional clinical features or that the variants in this case did not affect protein function to the same degree as other variants. One individual developed B-cell lymphoma at three years of age; no other malignancies were reported.

We ascertained 15 patients from the medical literature with possible CRB2-related syndrome based on the clinical descriptions (Table 2).<sup>12–16</sup> These cases have not undergone CRB2 sequencing and thus were not combined with CRB2 variant-positive cases due to possible ascertainment bias and lack of diagnostic certainty. Ventricular dilatation/hydrocephalus was present in 14/15 and was more rarely accompanied by aqueductal stenosis, gray matter heterotopias, splitting of the central canal of the spinal cord and hyperplasia of the choroid plexus.<sup>12,15,16</sup> Two affected individuals had pericardial effusions, but structural heart defects were not observed.<sup>14</sup> Renal echogenicity was present in eight, renal cysts in two and nephrosis or Finnish nephrosis in two patients. Postaxial polydactyly was found in one child, but was considered unrelated.<sup>16</sup> The longest survivor was

deceased at 2 years and 10 months of age. Similar to patients with proven CRB2 variants that affected function, MSAFP and AFAFP were elevated in all the patients investigated and cerebral ventriculomegaly was present in 12/13 (92%). Renal echogenicity was described in 8/13 (62%).

### Molecular genetic testing results

Novel and previously reported sequence variants identified in CRB2 are listed in Table 3 and have been deposited into a public database (<http://databases.lovd.nl/shared/genes/CRB2>). In the first patient, two heterozygous variants were detected in CRB2 (NM\_173689.6) c.(3291\_3292delCT), p.(Cys1098Serfs\*53) and c.(3343C>T), p.(Arg1115Cys). The mother was heterozygous for the c.(3343C>T) variant only; DNA from the father was not available. Examination of the sequencing trace revealed that the CRB2 sequence variants were inherited in trans, consistent with autosomal recessive inheritance. The missense variant had discordant *in silico* predictions (Table 3), but was not found in ExAC browser. This patient was also tested for sequence variants in genes associated with ciliopathies and found to be heterozygous for c.(712\_715delAGAG), predicting p.(Arg238Glu fs\*59)

Table 3 Novel and reported mutations in *CRB2*

Genomic position	Nucleotide alteration	Amino acid alteration	SIFT <sup>a</sup>	Poly-phen-2 <sup>b</sup>	Mutation taster <sup>c</sup>	ExAC browser <sup>d</sup>	Conservation	Classification
<i>Isolated renal</i> chr9:g.126133191G>C	c.(1859G>C)	p.(Cys620Ser)	D; 0	PD <sup>g</sup> ; 0.989	DC <sup>h</sup> ; 0.999	Not present	Pt/Mm/Fc <sup>k</sup> /Mmus/ <sup>l</sup> Gg <sup>m</sup> /Tr <sup>n</sup> / <sup>o</sup>	PV <sup>q</sup>
chr9:g.126133214C>T	c.(1882C>T)	p.(Arg628Cys)	D; 0.027	PD; 0.995	DC; 0.999	2/119,188	Pt/Mm/Mmus/ <sup>l</sup> Gg/Dr	PV
chr9:g.126133218G>C	c.(1886G>C)	p.(Cys629Ser)	D; 0	PD; 0.997	DC; 0.999	Not present	Pt/Mm/Fc/Mmus/Gg/Tr/Dr/Xt	PV
chr9:g.126135914_126135915ins CCGGCGGGCCCCGGC	c.(31085_31096ins CCGGCGGGCCCCGGC)	p.(Gly1036Alafs*42)	-	-	DC; 1.0	Not present	-	PV
chr9:g.12613929G>A	c.(3746G>A)	p.(Arg1249Gln)	N <sup>i</sup> ; 0.11	PD; 0.998	DC; 0.999	111/82,212	Pt/Mm/Fc/Mmus/Gg/Tr/Dr/Xt	VUS <sup>s</sup>
<i>CRB2-related syndrome</i> chr9:g.126132826G>T	c.(1494G>T)	p.(Trp498Cys)	D; 0.025	PD; 0.968	DC; 0.996	90/120,792	Pt/Mm/Fc	VUS
chr9:g.126133229C>T	c.(1897C>T)	p.(Arg633Trp)	D; 0.002	PD; 1.0	DC; 0.994	Not present	Pt/Mm/Fc/Mmus/Gg/Tr/Dr/Xt	PV
chr9:g.126133349A>C	c.(1928A>C)	p.(Glu643Ala)	D; 0.007	PD; 0.999	DC; 0.999	5/117,750	Pt/Mm/Fc/Mmus/Gg/Tr/Xt	PV
chr9:g.126133697G>A	c.(2277G>A)	p.(Trp759*)	-	-	DC; 1.0	2/118,572	Pt/Mm/Fc/Mmus/Gg/Tr/Dr/Xt	PV
chr9:g.126133821C>G	c.(2400C>G)	p.(Asn800Lys)	D; 0.004	PD; 0.999	DC; 0.999	17/118,106	Pt/Mm/Fc/Mmus/Gg/Tr/Dr/Xt	PV
chr9:g.126135914_126135915ins CCGGCGGGCCCCGGC	c.(31085_31096ins CCGGCGGGCCCCGGC)	p.(Gly1036Alafs*42)	-	-	DC; 1.0	Not present	-	PV
chr9:g.126136037A>C	c.(3227A>C)	p.(Asp1076Ala)	D; 0.011	Poss.D; 0.948	DC; 0.871	Not present	Pt/Mm/Fc	PV
chr9:g.126136101_126136102delCT	c.(3291_3292delCT)	p. (Cys1098Serfs*53)	-	-	DC; 1.0	Not present	-	PV
chr9:g.126136153C>T	c.(3343C>T)	p.(Arg1115Cys)	T <sup>i</sup> ; 0.19	Poss. D; 0.925	PM <sup>v</sup> ; 0.992	Not present	Pt/Mm/Fc	VUS
chr9:g.126136195T>C	c.3(385T>C)	p.(Cys1129Arg)	D; 0	PD; 0.991	DC; 0.999	Not present	Pt/Mm/Mmus/ <sup>l</sup> Gg/Tr/Dr/Xt	PV

All variant nomenclature used hg19 as the reference sequence.

<sup>a</sup>SIFT = <http://sift.jcvi.org>.

<sup>b</sup>Polyphen-2 = <http://genetics.bwh.harvard.edu/pph2/>.

<sup>c</sup>Mutation taster = <http://www.mutationtaster.org>.

<sup>d</sup>ExAC browser = <http://exac.broadinstitute.org/>.

<sup>e</sup>SRNS = Steroid resistant nephrotic syndrome.

<sup>f</sup>D = Deleterious.

<sup>g</sup>PD = Probably damaging.

<sup>h</sup>DC = disease causing.

<sup>i</sup>PT = Pan troglodytes.

<sup>j</sup>Mm = Macaca mulatta.

<sup>k</sup>Fc = Felix catus.

<sup>l</sup>Mmus = Mus musculus.

<sup>m</sup>Gg = Gallus gallus.

<sup>n</sup>Tr = Takifugu rubripes.

<sup>o</sup>Dr = Danio rerio.

<sup>p</sup>Xt = Xenopus tropicalis.

<sup>q</sup>PV = Pathogenic variant.

<sup>r</sup>N = neutral.

<sup>s</sup>VUS = Variant of unknown significance.

<sup>t</sup>Poss. D = Possibly damaging.

<sup>u</sup>T = Tolerated.

<sup>v</sup>PM = Polymorphism.

in *BBS7* (NM\_018190.3). This sequence variant was reported to be pathogenic.

In the second patient, sequencing revealed a novel missense substitution, c.(3385T>C), p.(Cys1129Arg), that was predicted to perturb the donor splice site for exon10 (<http://www.mutationtaster.org/>), and a 16 basepair (bp) insertion, c.(3108\_3109insCCGGCGCGCCCCGGC), p.(Gly1036Alafs\*42). Both of these sequence variants were predicted to affect function (Table 3). Sequencing of the mother showed that the frameshift variant was maternally inherited; the mother did not carry the missense variant. DNA from the father was unavailable.

Patients three and four were siblings. Homozygosity mapping in patient three revealed large regions of autozygosity on chromosomes 8, 9, 11, and 17 (data not shown) and WES analysis did not identify any disease-causing variants. Sanger sequencing of *CRB2* identified two homozygous sequence variants predicted to result in non-synonymous substitutions: c.(1494G>T), p.(Trp498Cys) and c.(3227A>C), p.(Asp1076Ala). Segregation analysis showed that patient four was homozygous for both *CRB2* variants, both parents were heterozygous for both variants (in cis), and the variants were not homozygous in two unaffected siblings. The c.(1494G>T) variant was observed in the heterozygous state at a low frequency (Table 3), as may occur for autosomal recessive conditions, but the c.(3227A>C) variant was novel. It was considered likely that at least one or both of the variants affected function, based on the high degree of clinical overlap with other individuals with CRB2-related syndrome (Table 1).

The fifth patient was a compound heterozygote for two previously described missense substitutions, p.(Glu643Ala) and p.(Asn800Lys). These sequence variants have previously been seen in patients of Ashkenazi Jewish ethnicity.<sup>1</sup>

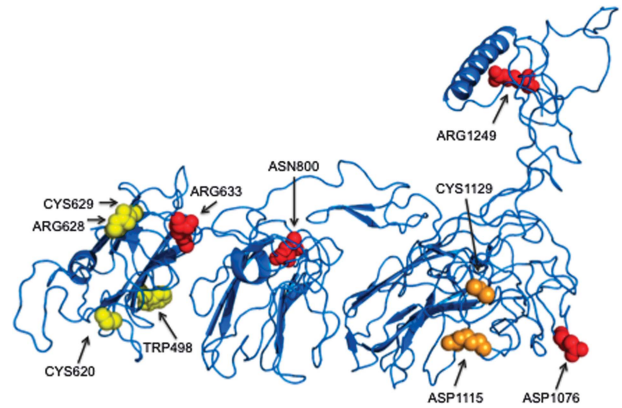
#### Re-analysis of exome data

The third and fourth patients in this report were both heterozygous for p.(Arg229Gln) in *NPHS2* (Table 1) that was reported as a weak, hypomorphic mutation in SRNS,<sup>24</sup> particularly when present with other specific variants.<sup>25</sup> This variant has an allele frequency of more than 1% in many populations and has been proposed to be a potential modifying allele in SRNS, associated with a more severe and earlier onset presentation.<sup>26,27</sup>

Sequence variants predicted to be pathogenic in the second sib from the first family from the original report of CRB2-related syndrome<sup>1</sup> included c.(4179T>A), p.(Phe1393Leu) in *NPHP4* (NM\_015102.4) (Supplementary Table S2). In the second sib from the second family from the original report of CRB2-related syndrome,<sup>1</sup> c.(355G>A), p.(Gly119Ser) in *BBS12* (NM\_001178007.1) was observed (Supplementary Table S2). Both patients were also homozygous for c.(21\_22ins GTGAGCGG), p.(Thr8Valfs\*5) in *TTC21B* (NM\_024753.4). Sequence variants in this gene are associated with focal segmental glomerulosclerosis<sup>28</sup> and may modify ciliopathy phenotypes.<sup>29</sup> However, this variant has an allele frequency of 37/16,806 in controls, with 16 homozygotes (ExAC browser), and it occurs in a GC- and repeat rich region, suggesting possible alignment artifact.

#### Protein modeling

The novel variants were grouped into two categories – ‘Cys’ alterations that affected the cysteine residues at positions 498, 620, 628, 629, 1115 and 1129 that were likely to disrupt the folding of CRB2 by interfering with the disulfide (S-S) bond formation, and ‘charge’ alterations (residues 633, 643, 800, 1076, 1115, 1129 and 1249) that were



**Figure 2** Position of ‘Cys’ and ‘Charge’ Mutations in CRB2. Representation of residues 439–1284 in CRB2, showing variants that affected a cysteine residue (‘Cys’ variants) in yellow and variants that were predicted to alter charge (‘charge’ mutations) at a residue in red. The two variants that have both properties are colored in orange. The N-terminus of the protein has not been included as there were no mutations affecting this portion of the protein.

predicted to interfere with conformation or protein interactions (Figure 2).

#### DISCUSSION

We present five new patients with CRB2-related syndrome and refine the clinical manifestations associated with sequence variants predicted to affect *CRB2* function. These cases indicate that ventriculomegaly/hydrocephalus and cerebral involvement are prominent features of the phenotype and reveal that aqueductal stenosis, mild cerebellar hypoplasia, a quadrigeminal cyst, atrial septal defect, Scimitar syndrome and uterus didelphys are other new clinical findings potentially associated with *CRB2* variants (Table 1). In addition, renal echogenicity and macro- or microcysts, as well as Finnish congenital nephrosis were observed in these five new patients, although the renal involvement was mild or undetectable in several patients despite elevated AFP levels during prenatal life (Table 1). Several patients demonstrated eye involvement, including one with reduced visual acuities and possible retinal pigmentation and another with mild optic atrophy. The full extent of the ocular pathology associated with *CRB2* variants is undetermined, as many patients with CRB2-related syndrome have been reported at a young age. However, given the reported eye findings with *CRB1* variants<sup>7–10</sup> and the demonstration that ablation of CRB2 can induce ocular changes found with retinitis pigmentosa and Leber congenital amaurosis,<sup>30,31</sup> ophthalmological monitoring will be an important addition to brain and kidney evaluation in CRB2-related syndrome.

Despite phenotypic variability, the CRB2-related syndrome phenotype was characteristic and consistent in terms of the organ systems involved, predominantly affecting the brain and kidneys (Table 1). The outcome for these five patients was, on average, better than for the patients from the original report of CRB2-related syndrome, in which all patients were deceased by six months of age.<sup>1</sup> One child in the new group of patients was deceased from B-cell lymphoma at three years of age, but *CRB2* does not have a known role in the pathogenesis of malignancies.

In regards to the patients with possible CRB2-related syndrome who have not undergone genetic testing, these patients provide further evidence that aqueductal stenosis and gray matter heterotopias form part of the phenotype. We also searched the literature for reports of



other patients with renal defects, brain malformations and elevated MSAFP and AFAFP measurements. Galloway-Mowat syndrome (GMS; OMIM 251300) is characterized by SRNS, gray matter heterotopias, microcephaly and hiatal hernia<sup>32,33</sup> and some cases of CRB2-related syndrome may have been misclassified as GMS. However, we found only one sibship reported as GMS that we considered likely to have had CRB2-related syndrome because of hydrocephalus with gray matter heterotopias, renal findings consistent with Finnish nephrosis and a twentyfold increased AFP in one of the pregnancies.<sup>13</sup>

Our report increases the number of reported *CRB2* variants to 14 (Table 3); the variants frequently involved cysteine residues that would alter disulfide bridge formation or charged amino acids important for protein domain interactions (Figure 2). Only two frameshift variants have been noted and these occurred in a patient with CRB2-related syndrome and a child with SRNS. One previously reported variant in SRNS, p.(Arg1249Gln), has been reported in the ExAC browser in a homozygous state in two individuals who were not known to have renal or cerebral defects, thus suggesting that this substitution may be a hypomorphic variant or a variant of unknown significance. Interestingly, the clustering of variants associated with SRNS in the tenth EGF-like domain<sup>2</sup> initially suggested a possible phenotype genotype relationship, but at present there is too little data to draw conclusions. Modeling of the position of the sequence variants demonstrated that all but one of the variants involved the extracellular portion of the protein (Figure 2), suggesting that signaling through the Crumbs complex could remain intact, although no functional studies have yet been performed.

We were intrigued by the finding of a heterozygous *NPHS2* missense variant in both children from the sibling pair who each were homozygous for two missense variants in *CRB2* (Table 1). As a child in one of the previously reported families<sup>1</sup> was heterozygous for a splice variant in *NPHS1* and there is a strong overlap between the renal phenotypes observed in patients with CRB2-related syndrome and Finnish congenital nephrosis resulting from *NPHS1* variants, we reasoned that the inheritance of additional alleles predicted to alter function in genes related to CRB2 function could be exerting modifying effects. In one of the original families, re-analysis found a heterozygous sequence variant in *NPHP4* c.(4179 T>A), p.(Phe1393-Leu), a variant that was not seen in homozygous form in 1000 genomes and ExAC browser, that affects a highly conserved amino acid residue and that was predicted to affect function (Supplementary Table S1). This gene has been linked to nephronophthisis and cerebello-oculo-renal syndrome.<sup>34,35</sup> This finding, together with the *BBS7* and *BBS12* sequence variants reported in other CRB2-related syndrome patients, indicates that oligogenic inheritance or genetic burden may be critical for the phenotypic expression of *CRB2* variants and compromise phenotype. However, further studies to determine the effects of loss of function of these alleles in combination with *CRB2* loss of function are needed for verification.

## CONCLUSION

We report here the clinical features of five additional patients with CRB2-related syndrome and review the phenotype for 15 patients with similar clinical findings that were reported in the literature but that did not undergo *CRB2* sequencing. This series reveals that the predominant manifestations were raised MSAFP and AFAFP, and cerebral ventriculomegaly and hydrocephalus, in addition to cystic kidney disease and renal findings that resemble Finnish congenital nephrosis. We suggest that modifier alleles or genetic burden may contribute to the clinical variability exhibited by patients with CRB2-related syndrome.

## CONFLICT OF INTEREST

The authors declare no conflict of interest.

## ACKNOWLEDGEMENTS

We are grateful to the families for their participation in this study. This work was supported by grant R21EY022779-02 to Professor Anne Slavotinek from the National Eye Institute, National Institutes of Health and a grant from the Alberta Children's Hospital Foundation to AMI, JSP and FPB. REL was supported by a fellowship from the Alberta Children's Hospital Foundation.

- 1 Slavotinek A, Kaylor J, Pierce H *et al*: *CRB2* mutations produce a phenotype resembling congenital nephrosis, Finnish type, with cerebral ventriculomegaly and raised alpha-fetoprotein. *Am J Hum Genet* 2015; **96**: 162–169.
- 2 Ebarasi L, Ashraf S, Bierzynska A *et al*: Defects of *CRB2* cause steroid-resistant nephrotic syndrome. *Am J Hum Genet* 2015; **96**: 153–161.
- 3 Tepass U, Knust E: Crumbs and Stardust act in a genetic pathway that controls the organization of epithelia in *Drosophila melanogaster*. *Dev Biol* 1993; **159**: 311–326.
- 4 Katoh M, Katoh M: Identification and characterization of Crumbs homolog 2 gene at human chromosome 9q33.3. *Int J Oncol* 2004; **24**: 743–749.
- 5 van den Hurk JA, Rashbass P, Roepman R *et al*: Characterization of the Crumbs homolog 2 (*CRB2*) gene and analysis of its role in retinitis pigmentosa and Leber congenital amaurosis. *Mol Vis* 2005; **11**: 263–273.
- 6 Xiao Z, Patrakka J, Nukui M *et al*: Deficiency in Crumbs homolog 2 (*Crb2*) affects gastrulation and results in embryonic lethality in mice. *Dev Dyn* 2011; **240**: 2646–2656.
- 7 Jacobson SG, Cideciyan AV, Aleman TS *et al*: Crumbs homolog 1 (*CRB1*) mutations result in a thick human retina with abnormal lamination. *Hum Mol Genet* 2003; **12**: 1073–1078.
- 8 Tiab L, Largueche L, Chouchane I *et al*: A novel homozygous R764H mutation in crumbs homolog 1 causes autosomal recessive retinitis pigmentosa. *Mol Vis* 2013; **19**: 829–834.
- 9 Khan AO, Aldahmesh MA, Abu-Safieh L, Alkuraya FS: Childhood cone-rod dystrophy with macular cystic degeneration from recessive *CRB1* mutation. *Ophthalmic Genet* 2014; **35**: 130–137.
- 10 Tsang SH, Burke T, Oll M *et al*: Whole exome sequencing identifies *CRB1* defect in an unusual maculopathy phenotype. *Ophthalmology* 2014; **121**: 1773–1782.
- 11 Fulton AB, Hansen RM, Moskowitz A, Akula JD: The neurovascular retina in retinopathy of prematurity. *Prog Retin Eye Res* 2009; **28**: 452–482.
- 12 Palm L, Hägerstrand I, Kristofferson U *et al*: Nephrosis and disturbances of neuronal migration in male siblings—a new hereditary disorder? *Arch Dis Child* 1986; **61**: 545–548.
- 13 Spear GS, Steinhaus KA, Quddusi A: Diffuse mesangial sclerosis in a fetus. *Clin Nephrol* 1991; **36**: 46–48.
- 14 Jolly M, Goodburn S, Cox P, Loughna P: Congenital nephropathy and ventriculomegaly: a report of four cases. *Prenat Diagn* 2003; **23**: 48–51.
- 15 Sinclair-Smith CC, Wiggelinkhuizen J, Nelson MM: Increased amniotic fluid alpha-fetoprotein, familial hydrocephalus, and renal dysmorphism. *Am J Dis Child* 1980; **134**: 619–621.
- 16 Reuss A, den Hollander JC, Niermeijer MF *et al*: Prenatal diagnosis of cystic kidney disease with ventriculomegaly: a report of six cases in two related sibships. *Am J Med Genet* 1989; **33**: 385–389.
- 17 Keith J, Fabian VA, Walsh P, Sinniah R, Robitaille Y: Neuropathological homology in true Galloway-Mowat syndrome. *J Child Neurol* 2011; **26**: 510–517.
- 18 Slavotinek AM, Mehrotra P, Nazarenko I *et al*: Focal facial dermal dysplasia, type IV, is caused by mutations in *CYP26C1*. *Hum Mol Genet* 2013; **22**: 696–703.
- 19 Seelow D, Schuelke M, Hildebrandt F, Nurnberg P: HomozygosityMapper— an interactive approach to homozygosity mapping. *Nucleic Acids Res* 2009; **37**: W593–W599.
- 20 Cingolani P, Platts A, Wang le L *et al*: A program for annotating and predicting the effects of single nucleotide polymorphisms, SnpEff: SNPs in the genome of *Drosophila melanogaster* strain w1118; iso-2; iso-3. *Fly* 2012; **6**: 80–92.
- 21 Kumar P, Henikoff S, Ng PC: Predicting the effects of coding non-synonymous variants on protein function using the SIFT algorithm. *Nat Protoc* 2009; **4**: 1073–1081.
- 22 Adzhubei IA, Schmidt S, Peshkin L *et al*: A method and server for predicting damaging missense mutations. *Nat Methods* 2010; **7**: 248–249.
- 23 Schwarz JM, Rödelberger C, Schuelke M, Seelow D: MutationTaster evaluates disease-causing potential of sequence alterations. *Nat Methods* 2010; **7**: 575–576.
- 24 Machuca E, Hummel A, Nevo F *et al*: Clinical and epidemiological assessment of steroid-resistant nephrotic syndrome associated with the *NPHS2* R229Q variant. *Kidney Int* 2009; **75**: 727–735.
- 25 Tory K, Menyhárd DK, Woerner S *et al*: Mutation-dependent recessive inheritance of *NPHS2*-associated steroid-resistant nephrotic syndrome. *Nat Genet* 2014; **46**: 299–304.
- 26 Kerti A, Csohány R, Wagner L *et al*: *NPHS2* homozygous p.R229Q variant: potential modifier instead of causal effect in focal segmental glomerulosclerosis. *Pediatr Nephrol* 2013; **28**: 2061–2064.

- 27 Ozaltin F, Ibsirlioglu T, Taskiran EZ *et al*: Disruption of PTPRO causes childhood-onset nephrotic syndrome. *Am J Hum Genet* 2011; **89**: 139–147.
- 28 Huynh Cong E, Bizet AA, Boyer O *et al*: A homozygous missense mutation in the ciliary gene TTC21B causes familial FSGS. *J Am Soc Nephrol* 2014; **11**: 2435–2443.
- 29 Davis EE, Zhang Q, Liu Q *et al*: TTC21B contributes both causal and modifying alleles across the ciliopathy spectrum. *Nat Genet* 2011; **43**: 189–196.
- 30 Pellissier LP, Alves CH, Quinn PM *et al*: Targeted ablation of CRB1 and CRB2 in retinal progenitor cells mimics Leber congenital amaurosis. *PLoS Genet* 2013; **9**: e1003976.
- 31 Alves CH, Pellissier LP, Vos RM *et al*: Targeted ablation of Crb2 in photoreceptor cells induces retinitis pigmentosa. *Hum Mol Genet* 2014; **23**: 3384–3401.
- 32 Shiihara T, Kato M, Kimura T *et al*: Microcephaly, cerebellar atrophy, and focal segmental glomerulosclerosis in two brothers: a possible mild form of Galloway-Mowat syndrome. *J Child Neurol* 2003; **18**: 147–149.
- 33 Colin E, Huynh Cong E, Mollet G *et al*: Loss-of-function mutations in WDR73 are responsible for microcephaly and steroid-resistant nephrotic syndrome: Galloway-Mowat syndrome. *Am J Hum Genet* 2014; **95**: 637–648.
- 34 Mollet G, Salomon R, Gribouval O *et al*: The gene mutated in juvenile nephronophthisis type 4 encodes a novel protein that interacts with nephrocystin. *Nat Genet* 2002; **32**: 300–305.
- 35 Alazami AM, Alshammari MJ, Baig M *et al*: NPHP4 mutation is linked to cerebello-oculo-renal syndrome and male infertility. *Clin Genet* 2014; **85**: 371–375.

Supplementary Information accompanies this paper on European Journal of Human Genetics website (<http://www.nature.com/ejhg>)