

# UC San Diego

## UC San Diego Previously Published Works

### Title

The role of biomarkers and MEG-based imaging markers in the diagnosis of post-traumatic stress disorder and blast-induced mild traumatic brain injury

### Permalink

<https://escholarship.org/uc/item/2q32151t>

### Authors

Huang, Mingxiong  
Risling, Mårten  
Baker, Dewleen G

### Publication Date

2016

### DOI

10.1016/j.psyneuen.2015.02.008


Peer reviewed



Available online at [www.sciencedirect.com](http://www.sciencedirect.com)

ScienceDirect

journal homepage: [www.elsevier.com/locate/psyneuen](http://www.elsevier.com/locate/psyneuen)



# The role of biomarkers and MEG-based imaging markers in the diagnosis of post-traumatic stress disorder and blast-induced mild traumatic brain injury

Mingxiong Huang<sup>a,b,c,\*</sup>, Mårten Risling<sup>d</sup>, Dewleen G. Baker<sup>e,f</sup>

<sup>a</sup> Radiology Services, VA San Diego Healthcare System, San Diego, CA, USA

<sup>b</sup> Research Services, VA San Diego Healthcare System, San Diego, CA, USA

<sup>c</sup> Department of Radiology, University of California, San Diego, CA, USA

<sup>d</sup> Karolinska Institutet, Department of Neuroscience, Stockholm, Sweden

<sup>e</sup> Veterans Affairs Center for Excellence in Stress and Mental Health (CESAMH), San Diego, CA, USA

<sup>f</sup> University of California San Diego, Department of Psychiatry, La Jolla, USA

Received 16 April 2014; received in revised form 13 February 2015; accepted 15 February 2015

## KEYWORDS

Traumatic brain injury (TBI);  
Blast;  
Concussion;  
PTSD;  
Magnetoencephalogram;  
Diffusion tensor imaging (DTI);  
Military;  
Veteran

## Summary

**Background:** Pervasive use of improvised explosive devices (IEDs), rocket-propelled grenades, and land mines in the recent conflicts in Iraq and Afghanistan has brought traumatic brain injury (TBI) and its impact on health outcomes into public awareness. Blast injuries have been deemed signature wounds of these wars. War-related TBI is not new, having become prevalent during WWI and remaining medically relevant in WWII and beyond. Medicine's past attempts to accurately diagnose and disentangle the pathophysiology of war-related TBI parallels current lines of inquiry and highlights limitations in methodology and attribution of symptom etiology, be it organic, psychological, or behavioral. New approaches and biomarkers are needed.

**Preclinical:** Serological biomarkers and biomarkers of injury obtained with imaging techniques represent cornerstones in the translation between experimental data and clinical observations. Experimental models for blast related TBI and PTSD can generate critical data on injury threshold, for example for white matter injury from acceleration. Carefully verified and validated models can be evaluated with gene expression arrays and proteomics to identify new candidates for serological biomarkers. Such models can also be analyzed with diffusion MRI and microscopy in order to identify criteria for detection of diffuse white matter injuries, such as DAI (diffuse axonal injury). The experimental models can also be analyzed with focus on injury outcome in brain stem regions, such as locus coeruleus or nucleus raphe magnus that can be involved in response to anxiety changes.

\* Corresponding author at: UCSD Radiology Imaging Laboratory, San Diego, CA 92121, USA. Tel.: +1 858 534 1254; fax: +1 8585346046.  
E-mail address: [mxhuang@ucsd.edu](mailto:mxhuang@ucsd.edu) (M. Huang).

<http://dx.doi.org/10.1016/j.psyneuen.2015.02.008>

0306-4530/Published by Elsevier Ltd.

Please cite this article in press as: Huang, M., et al., The role of biomarkers and MEG-based imaging markers in the diagnosis of post-traumatic stress disorder and blast-induced mild traumatic brain injury. *Psychoneuroendocrinology* (2015), <http://dx.doi.org/10.1016/j.psyneuen.2015.02.008>

*Clinical:* Mild (and some moderate) TBI can be difficult to diagnose because the injuries are often not detectable on conventional MRI or CT. There is accumulating evidence that injured brain tissues in TBI patients generate abnormal low-frequency magnetic activity (ALFMA, peaked at 1–4 Hz) that can be measured and localized by magnetoencephalography (MEG). MEG imaging detects TBI abnormalities at the rates of 87% for the mild TBI, group (blast-induced plus non-blast causes) and 100% for the moderate group. Among the mild TBI patients, the rates of abnormalities are 96% and 77% for the blast and non-blast TBI groups, respectively. There is emerging evidence based on fMRI and MEG studies showing hyper-activity in the amygdala and hypo-activity in pre-frontal cortex in individuals with PTSD. MEG signal may serve as a sensitive imaging marker for mTBI, distinguishable from abnormalities generated in association with PTSD. More work is needed to fully describe physiological mechanisms of post-concussive symptoms.  
Published by Elsevier Ltd.

## 1. Background

Blast injuries are deemed the signature wounds of the first wars (Afghanistan and Iraq) of the 21st century (Lancet, 2007; Galarneau et al., 2008). According to a recent U.S. Department Veterans Affairs (DVA) and Defense (DoD) report, 12–23% of returning service members reported a TBI during deployment (O’Neil et al., 2013). Of these, the majority are in the “mild” range of severity (mTBI) (Centers for Disease Control and Prevention and National Center for Injury Prevention and Control 2003; Hoge et al., 2009; O’Neil et al., 2013). A review of the literature from 20th century wars (WWI, WWII, Vietnam) shows that current lines of scientific inquiry regarding the etiology of those symptoms parallel earlier attempts to disentangle the pathophysiology of post-concussive symptoms (PCS) from mental health symptoms, and to distinguish mTBI from war-related mental health syndromes, such as PTSD (Jones et al., 2007). Moreover this literature highlights limitations in methodology and attribution of symptom etiology, be it organic, psychological, or behavioral, that remain a focus of investigations today (Myers, 1915; Fulton, 1942; Jones et al., 2007; Rosenfeld et al., 2013).

A particular challenge in disentangling the symptoms and physiology has been establishing a quantitative, unassailable diagnostic methodology for defining mTBI, such a distinguishing blood or imaging biomarker signature. Most studies have relied on self-report of a concussive event, and have defined mTBI clinically, using symptom-based criteria. Brain changes that may accompany mTBI have been hard to visualize using standard imaging methods (Huang et al., 2012). While neurocognitive tests are used clinically and can be helpful, authors of the recent U.S. DVA Report observed that only a few studies among those reviewed found an association between mTBI and cognitive deficits (O’Neil et al., 2013). However, longitudinal follow-up of military personnel initially evacuated to Longstuhl with mTBI (self-report of war-related brain injury event) showed that rates of disability 6–12 months after evacuation were high and outcomes worse, overall in those service members with mTBI, comparable to those of civilian cohorts or polytrauma patients with mTBI (MacDonald et al., 2014). MacDonald et al. found no substantial differences in cognition between the evacuated personnel with and without a history of mTBI, however rates of PTSD and depression were higher in the mTBI group (MacDonald et al., 2014).

A substantial number of cross-sectional studies have shown higher (nearly double) rates of PTSD in individuals with mTBI, observed in both military (Hoge et al., 2008; Schneiderman et al., 2008; Luethcke et al., 2011; Vasterling et al., 2012; Rosenfeld et al., 2013) and civilian (Bryant et al., 2010; Mayou et al., 2000) settings. Moreover, these findings have been corroborated using prospective study designs in civilians (Roitman et al., 2013) and in active duty service members (Yurgil et al., 2014). In an 10 day and 8 month follow-up of civilians who presented to the emergency room as a result of motor vehicle accidents, some with mTBI (<30 min loss of consciousness) and some without, Roitman et al., showed that those with head injury and loss of consciousness (LOC) had higher levels of PTSD at follow-up. In the Marine Resiliency Study (MRS), a prospective, longitudinal study, of Marines and Sailors assessed at pre-deployment and again at 3–6 months after a 7-month deployment to Iraq or Afghanistan rates of reported prior TBI were 56.8% at the pre-deployment interview, and rates of deployment-related TBI were 19.8%; of the deployment-related TBIs approximately 87.2% were mild (Baker et al., 2012; Yurgil et al., 2014). As was observed in the civilian study, war-related mTBI significantly increased post-deployment PTSD symptom scores, either doubling or nearly doubling the PTSD rates in combatants who, prior to deployment, had been mentally healthy (Yurgil et al., 2014).

These two prospective studies provide accumulating evidence that mTBI is a robust prognostic indicator of subsequent PTSD development, raising the question as to the underlying cause. Whereas heightened emotional salience of traumatic events that involve blast/concussive injuries versus those without may, in part, provide an explanation for higher PTSD rates after mTBI, another likely, or perhaps even primary explanation may be that mTBI associated structural and functional brain changes increase vulnerability for development of mental disorders such as PTSD (Yurgil et al., 2014). Damage of the mTBI prefrontal cortical networks implicated in PTSD has been suggested as a possible cause of the increased vulnerability (Hoffman and Harrison, 2009; Yurgil et al., 2014).

Pre-clinical studies, as described below, focused on the pathophysiology and mechanisms of neurotrauma may contribute important information regarding mTBI associated brain changes that may contribute to PTSD development. These studies are needed to form a solid scientific basis

for understanding observed clinical outcomes, and to inform clinical decision making and biomarker development.

## 2. Preclinical

The use of improvised explosive devices (IEDs) in contemporary asymmetric warfare has changed the scene and spectrum of TBI at the battlefield. The signature TBI has changed from penetrating during the war in Vietnam to blast induced TBI. At the same time, new equipment for body protection has increased the survival rate after TBI at the battlefield. A blast injury is a complex type of physical trauma and includes a variety of injuries, ranging from mild to lethal. The majority of blast induced TBI fall into the category of mild TBI (Hoge et al., 2008) and several groups have tried to develop relevant experimental models for mild blast TBI. It is not possible to make a full review of all experimental research with a focus on blast induced TBI here. However, it is important to underscore the different physics in blast TBI and TBI in a civilian setting, more frequently a result of blunt trauma injury. Extreme forces and their complex propagation characterize blast TBI.

Injury from blast can result from secondary, tertiary and even quaternary effects as well as the primary supersonic pressure wave produced by the blast, all of which have been studied in brain injury models. Secondary effects, due to the impact of flying objects, such as shrapnel fragments, can generate penetrating injuries. The proportion of such injuries was larger in previous conflicts, but seems to have been reduced by improvements in helmet construction. Tertiary effects of blast result from acceleration/deceleration trauma, which may result in tissue shearing and diffuse injuries, such as DAI (diffuse axonal injuries). If the trauma is rotational, the position of the axis of rotation will be an important factor in the injury mechanism and areas at a greater distance from this axis will sustain larger forces. Quaternary effects of blast result from heat, smoke or emission of electromagnetic pulses from detonations (Lee et al., 2011).

If the injury is associated with fragment penetration this will induce more severe focal injury, with subsequent diffuse secondary injuries due to propagation of pressure waves and temporary cavities. Secondary traumatic brain damage occurs as a complication of the different types of TBI and includes ischemic and hypoxic damage, swelling, raised intracranial pressure and infection. The secondary TBI is potentially partly reversible with adequate treatment. Many clinical TBI patients suffer from multiple injuries, i.e. pulmonary lesions or amputations, which can have effects on the outcome of the TBI (due to hypoxia or systemic inflammation). The complexity of the clinical injury and the fact that exposure data seldom are available has created a need for experimental research on biological effects of blast. One early example of this research is the PhD thesis by Carl-Johan Clemedson "An experimental study on air blast injuries" (Clemedson, 1949). During the 65 years that have passed since that publication, a considerable number of animal models have been proposed suitable for research on blast induced TBI. The primary blast wave is the propagation of a supersonic pressure wave with short duration. The threshold for injuries is determined by factors such as peak pressure,

duration and shape of the wave (reflections, underpressure etc.). Models for better understanding the primary blast wave include (1) open field exposure, (2) blast tubes for explosives and (3) Shock tubes with compressed air or gas.

- *Open field exposure.* Examples here are the large-scale classical experiments in the U.S. in desert areas and ponds, employing large sets of animals of different species and sizes. These experiments determined thresholds for bleeding in air filled organs such as the lungs and intestines, but the potential effects on the central nervous system were not assessed. For simple waveforms, i.e. the Friedländer type of wave, dose response curves (the Bowen curves) were determined.
- *Blast tubes for explosives.* During 1950s large size blast tubes were created to study effects of wave forms relevant to nuclear detonations, i.e. comparatively long duration of the primary peak. The tubes were often used to study how construction details such as doors could withstand a blast wave. One exception was the studies by Clemedson at the Swedish FOA (Swedish Defence Research Establishment) using a smaller blast tube (Clemedson and Criborn, 1955) in which a charge of plastic explosive was used. These types of systems are still in use, but have been outnumbered by shock tube systems.
- *Shock tubes with compressed air or gas.* Systems with compressed air were used already in the 1950s (Clander et al., 1955). Most systems comprise two chambers, separated by a membrane. The gas is loaded into an overpressure chamber (the driver section), which is separated from the main compartment (driven section) by a membrane (diaphragm). The object, i.e. the experimental animal is positioned somewhere in the main section. The operator of the system can rupture the diaphragm at a predetermined pressure and the compressed gas enters the main section as a blast wave. The main section is usually several meters long. If more than one overpressure chamber is positioned in a series rather complex waveforms can be created (Cernak et al., 2011). One advantage with this type of shock tube is the absence of quaternary blast effects and other disadvantages of explosives. However, this advantage can also be regarded as a disadvantage.

One significant problem with the variety of experimental models for blast TBI is that it is very difficult to actually compare the different models. For example, there is no real consensus for monitoring of pressure curves for different models for primary blast. Researchers seem to disagree about recording techniques to access peak pressure, duration and acceleration movements. Blast waves cause damage by a combination of the compression of the air in front of the wave and the subsequent wind, but there is no real consensus on how to represent such parameters in the laboratory situation. Experimental models should be carefully validated in terms of physical parameters (Antona-Makoshi et al., 2014) and outcome (morphologic, functional, molecular and gene expression changes) (Risling et al., 2011). All methods that could facilitate a good translation to clinical data (serological biomarkers, neurophysiology and imaging) are recommended.

Dr. Ibolja Cernak has shown that blast TBI can be a systemic reaction to blast (Cernak, 2010). General inflammatory reactions from the primary blast can contribute to the reactions of the brain. The propagation of pressure waves through the body in blast trauma is still a subject of disagreement. Important data can be retrieved by carefully planned experiments utilizing incomplete body protection (Cernak, 2010). The importance of repeated mild TBI for development of late development of neurodegenerative disease has been documented in sports medicine (Guskiewicz et al., 2005) and repeated injuries will undoubtedly be included in a number of protocols for research on blast TBI. Studies on operators in breaching training can provide a very interesting strategy to collect good exposure data and biomarkers after repeated controlled detonations (Tate et al., 2013). One central problem is that exposure data from actual clinical situations are lacking. Acceleration probes mounted in helmets may help to solve this problem and if the same type of sensors will be implanted for use in animal experiments translation of data may be facilitated.

As noted above, veterans with histories of blast-induced mTBI who have been exposed to explosions are more likely to have headaches, features of migraine, more severe pain, PTSD, and impaired sleep with nightmares. It is difficult to achieve a good representation of such parameters in the evaluation of animal experiments for blast TBI, i.e. blast models that make use of rodents and pigs. Refined behavioral tests with a high sensitivity for stress reactions similar to posttraumatic stress will be important in the future work with blast (Kamnaksh et al., 2011; Kovetski et al., 2011; Kwon et al., 2011). Additional experiments are required to enable an understanding of the co-morbidity of TBI and PTSD. Such experiments could be combined with biomarker sampling, behavior analysis such as the Forced Swim Test and functional imaging. A recent study has revealed significant changes in catecholamines and serotonin in rodents exposed to a mild TBI (Kawa et al., 2014).

One way to accomplish a better translation between animal experiments and the clinic would be to employ the same methodology for analysis. Imaging, e.g. with MRI (Kamnaksh et al., 2014) or magnetoencephalogram (MEG), and systematic use of biomarkers can be used in both settings and help to bridge the gap between the lab bench and the hospital bed (Agoston et al., 2012). It is important to consider that the limited size of rodent brains creates a demand for good resolution in the imaging technique. Strain differences between different rodents may create difficulties in the interpretation of biomarkers. Different timetables for injury induced changes in biomarkers between rodents and humans should also be considered. Computer based reconstruction of clinical injuries and exposure in the experimental models can help to narrow the knowledge gap between experiments and clinical observations (Kleiven, 2007). Fine-tuning of the finite element models would need to include both tissue properties and a proper representation of fiber tracts. Modeling however, has limited use if the predictions cannot be validated by actual biological observations. The different geometrical shape of the rodent brain and humans can create obstacles in modeling. It is therefore advantageous if data from larger animals, such as pigs, are available also.

The Vietnam Head Injury study can also be used as an example of translation. Outcome data from a large cohort

of patients that survived penetrating brain injuries has been analyzed during more than 35 years (Raymont et al., 2011). This is probably one of the most detailed follow-up neurotrauma studies that has ever been conducted. This material has been employed to reveal the importance of the growth factor BDNF on the outcome of the injury (Rostami et al., 2011) an observation that later was brought back for further investigation in a suitable animal model (Rostami et al., 2014).

In summary, blast TBI involves complex energy transfer and several possible mechanisms. The primary blast wave, acceleration generated tissue strain, smoke and heat can induce both mild TBI and more severe injuries. It is essential to have a good control on physics during animal experiments on blast induced TBI. Translation to clinical situations can be facilitated if serological biomarkers and advanced imaging techniques can be used.

### 3. Clinical

In humans, the observation that repeated mild injuries could result in chronic traumatic encephalopathy (CTE) (Lakis et al., 2013; Stein et al., 2014). has influenced scientists to start experimental projects on repeated mild blast induced TBI (Petraglia et al., 2014a,b; Glushakova et al., 2014; Goldstein et al., 2014).

Also there is now evidence that changes in endocrine functions and regulation can show significant changes in TBI patients. Serum levels of melatonin can probably contribute to long-term sleep disturbances in TBI patients (Seifman et al., 2014). It has been observed that pituitary dysfunction may be one of the consequences of blast TBI (Baxter et al., 2013) and this observation should be analyzed also in experimental models for blast.

Of course, there is an extensive pre-clinical and clinical literature showing abnormalities in neuroendocrine function in PTSD, review of which is beyond the focus of this paper (de Kloet et al., 2006; Krystal and Neumeister, 2009). Plasma melatonin levels collected 48 h after a trauma in Australian troops are reported to predict later PTSD, but, a recent study that assessed polysomnography with simultaneous blood sampling in returning Dutch troops observed no PTSD-related plasma melatonin abnormalities, despite sleep disturbance (McFarlane et al., 2010; van Liempt et al., 2013). The same Dutch study, though, showed evidence for a link between hypothalamic–pituitary–adrenal (HPA) axis abnormalities that were observed and sleep disturbance in the troops with PTSD (van Liempt et al., 2013).

To date most neuroendocrine research has focused on either PTSD or mTBI and has not grappled with the complexities of disentangling effects of possible co-occurring disorders. Clearly, going forward, as our ability to detect post-head injury residual brain injury improves, it will be important to carefully characterize diagnostic status (mTBI, PTSD and the combination) in endocrine and autonomic research in military cohorts in order to fully tease apart biomarkers related to separate (mTBI, PTSD) and combined (mTBI and PTSD) status, given the high co-occurrence of both disorders in deployed troops.

Inflammatory reactions and cell death after TBI can be different in males and females (Gunther et al., 2015).

Such differences can possibly be related to endocrine functions. Also metabolic functions can be altered after TBI. For example, changes in the cytochrome p450 superfamily of metabolic enzymes could influence the metabolism of inflammatory mediators, drugs and hormones (Birnie et al., 2013). Metabolic abnormalities have been proposed, but are yet to be studied in humans with PTSD (Naviaux, 2014).

At present, it is unclear why similar mTBI events can lead to dramatic neurobehavioral decompensation with persistent PCS in some individuals, but not in others (Jeter et al., 2013). Retrospective and prospective studies of combat-related TBI show that most (<85%) deployment-related TBIs are mild (MacGregor et al., 2011; Yurgil et al., 2014). But diagnoses are based primarily on the characteristics of the acute clinical sequelae following the injury. The subtle, scattered and varied lesion(s) usually go undetected by conventional CT, and they are often unobservable on conventional MRI as well (Van Boven et al., 2009; Bigler and Orrison, 2004; Johnston et al., 2001; Kirkwood et al., 2006). Teasdale and Jennet showed that intracranial lesions in mTBI are detected by conventional neuroimaging techniques in only 4%, 16%, and 28% of patients with Glasgow Coma Scale scores (GCS) (Teasdale and Jennett, 1974) of 15, 14, and 13, respectively (Culotta et al., 1996).

Usually, the persistent PCS and cognitive deficits in TBI patients cannot be explained solely by focal pathology. DAI is a major contributor to these deficits and is commonly induced by sudden acceleration-deceleration or rotational forces. In a rodent TBI model, axonal injury was the most prominent feature following blast exposure (Garman et al., 2011). In humans, the subsequent tissue injury is characterized by axonal stretching, inflammation, disruption, and separation of nerve fibers, although axotomy is relatively rare in even severe TBI (Adams et al., 1989; Bassar and Pierpaoli, 1996; Gennarelli et al., 1982; Xu et al., 2007). Conventional CT and MRI are primarily sensitive to blood from nearby torn capillaries, rather than axonal damage itself, hence they underestimate the presence of DAI, especially in mTBI. New approaches using diffusion tensor imaging (DTI), positron emission topography (PET), and macromolecular proton fraction (MPF) have showed promising capability in detecting injuries and/or abnormalities that are not visible in CT and MRI (e.g., Petrie et al., 2014; MacDonald et al., 2011; Davenport et al., 2012; Shenton et al., 2012).

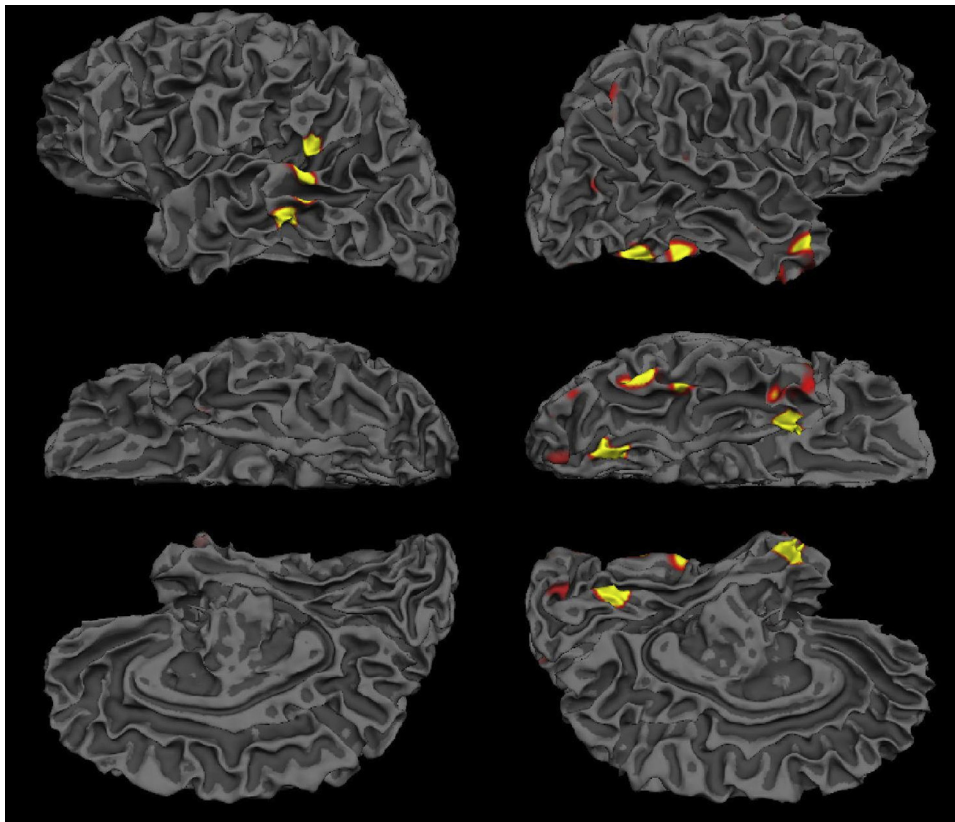
Magnetoencephalogram (MEG) is a non-invasive functional imaging technique that directly measures the magnetic signal due to neuronal activation in gray matter (GM) with high temporal resolution (<1 ms) and spatial localization accuracy (2–3 mm at cortical level) (Leahy et al., 1998). MEG demonstrates sensitivity to abnormal neuronal signals resulting from axonal injuries. Neurophysiological studies in animals have established a solid connection between pathological delta-wave (1–4 Hz) generation in GM and axonal injuries in WM. Gloor et al. showed that polymorphic delta-band slow-waves produced by (white matter) WM axonal lesions in the cat were localized to the GM area of cortex overlying the lesion (Ball et al., 1977; Gloor et al., 1977). They also found that pathological delta-waves can be induced by the administration of atropine in the WM (Schaul et al., 1978). It is known that atropine is a competitive antagonist of acetylcholine receptors and can block

and/or limit the cholinergic pathway. These experiments concluded that cortical de-afferentation was an important factor in abnormal delta-wave production, owing to WM lesions (i.e., axonal injury) and/or defects in the cholinergic pathway (Schaul, 1998). In the human brain, the projections of cholinergic pathways highly overlap with the WM fiber tracts (Selden et al., 1998), which make the cholinergic pathways similarly susceptible as the WM tracts to TBI.

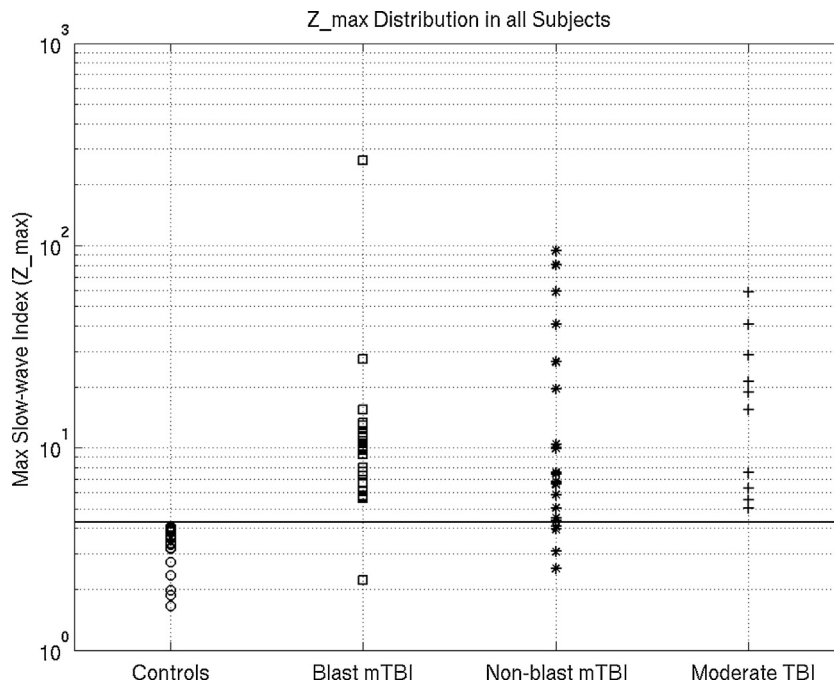
Human studies by Lewine et al., and our laboratory showed that the brains of mTBI patients generate abnormal low-frequency magnetic fields that can be measured and localized by resting-state MEG (Huang et al., 2009, 2012; Lewine et al., 1999, 2007). MEG was also found to be more sensitive than conventional MRI or EEG in detecting abnormalities in mTBI patients (Lewine et al., 1999, 2007). Unlike normal resting-state MEG data, which is dominated by neuronal activity with frequencies above 8 Hz, injured neuronal tissues (due to head trauma, brain tumors, stroke, and epilepsy) generate abnormal focal or multi-focal low-frequency neuronal magnetic signals (delta-band 1–4 Hz, or theta-band 5–7 Hz) that can be directly measured and localized using MEG (Baayen et al., 2003; de Jongh et al., 2003; Decker and Knott, 1972; Lewine et al., 1999; Lewine and Orrison, 1995; Nagata et al., 1985; Vieth et al., 1996). While TBI is not the only neurological disorder that generates abnormal slow-wave, in practice, brain tumors, stroke, and epilepsy can be easily ruled out based on structural imaging (i.e., CT and MRI for tumor and stroke) and medical history (for epilepsy).

Fig. 1 shows an example of the abnormal resting-state MEG slow-wave findings in one of studies (Huang et al., 2009) from a chronic mTBI patient (sport injury) with persistent PCS including: pressure headaches, dizziness, fatigue, memory problems, difficulty falling asleep, and changes in speech and language. Multiple clinical CT and MRI scans were all negative. Fig. 1 shows that the abnormal MEG slow-waves came from: (1) lateral superior-posterior left temporal lobe, and (2) an area containing three sub-regions in the ventral right temporal and occipital lobes (Huang et al., 2009). Deafferentation due to axonal injuries was most likely the cause of slow-waves in these GM regions which was confirmed by Diffusion Tensor Imaging (DTI) tractography analysis (Huang et al., 2009).

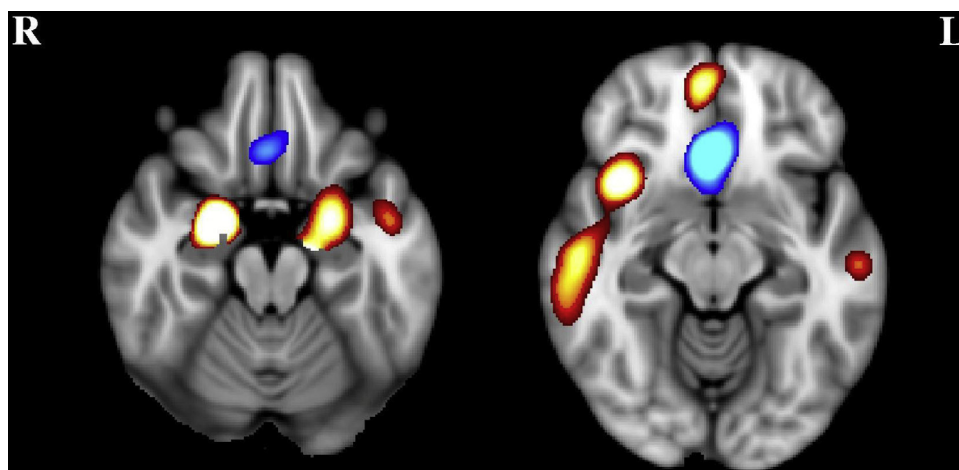
In a separate region-of-interest (ROI) study from our lab (Huang et al., 2012), we assessed abnormal resting-state MEG slow-wave (1–4 Hz) generation from 96 cortical regions from three TBI groups: 23 mild TBI patients exposed to combat-related blasts, 22 mild TBI patients with non-blast causes (sports, motor vehicle accidents, fall, and assault), and 10 moderate TBI patients with non-blast causes. The normative database for the ROI-based MEG slow-wave power was established using data from 44 healthy control subjects. Fig. 2 shows a conservative threshold (horizontal line) in which all healthy control subjects' slow-wave measures were below this level (0% false-positive rate). With such a threshold, the positive detection rates were 96% for mild blast-induced TBI patients (22 out of 23), 77% for the mild non-blast TBI patients (17 out of 22), and 100% for the moderate TBI patients (10 out of 10). When we combined the blast-induced and non-blast mild TBI groups together, the correct diagnostic rate was about 87% for the combined mild TBI group. This study provides a foundation for using



**Figure 1** Abnormal MEG slow-waves. (1) Left column: L lateral superior-posterior temporal region. (2) Right column: R inferior-temporal areas. Three rows are lateral-, ventral-, and middle-views, respectively.



**Figure 2** Frequency-domain MEG low-frequency source imaging power are plotted separately for (1) healthy control, (2) mild blast-induced TBI, (3) mild non-blast-induced TBI, and (4) moderate TBI groups. The y-axis is in logarithm scale.



**Figure 3** MEG source imaging in beta and gamma bands shows hyperactivities (PTSD > Ctrl, red-hot color) from amygdala/anterior hippocampus and hypoactivities (PTSD < Ctrl, blue-cold color) from the vmPFC, with corrected  $p < 0.05$  in beta-gamma band.

MEG low-frequency source imaging as potential biomarker to assist in the clinical diagnosis of mild TBI.

Recently, we expanded the above ROI-based approach by developing a voxel-based whole-brain MEG slow-wave imaging approach, Fast-VESTAL (Huang et al., 2014a), for detecting abnormality in patients with mTBI on a single-subject basis (Huang et al., 2014b). A normative database of resting-state MEG source magnitude images (1–4 Hz) from 79 healthy control subjects (68 civilians and 11 active-duty military service members) was established for all brain voxels. The high-resolution MEG source magnitude images were obtained by our recent Fast-VESTAL method. In 84 mTBI patients with persistent post-concussive symptoms (36 from blasts, and 48 from non-blast causes), our method detected abnormalities at the positive detection rates of 84.5%, 86.1%, and 83.3% for the combined (blast-induced plus with non-blast causes), blast, and non-blast mTBI groups, respectively. We found that prefrontal, posterior parietal, inferior temporal, hippocampus, and cerebella areas were particularly vulnerable to head trauma. The results also showed that MEG slow-wave generation in prefrontal areas positively correlated with personality change, trouble concentrating, affective lability, and depression symptoms.

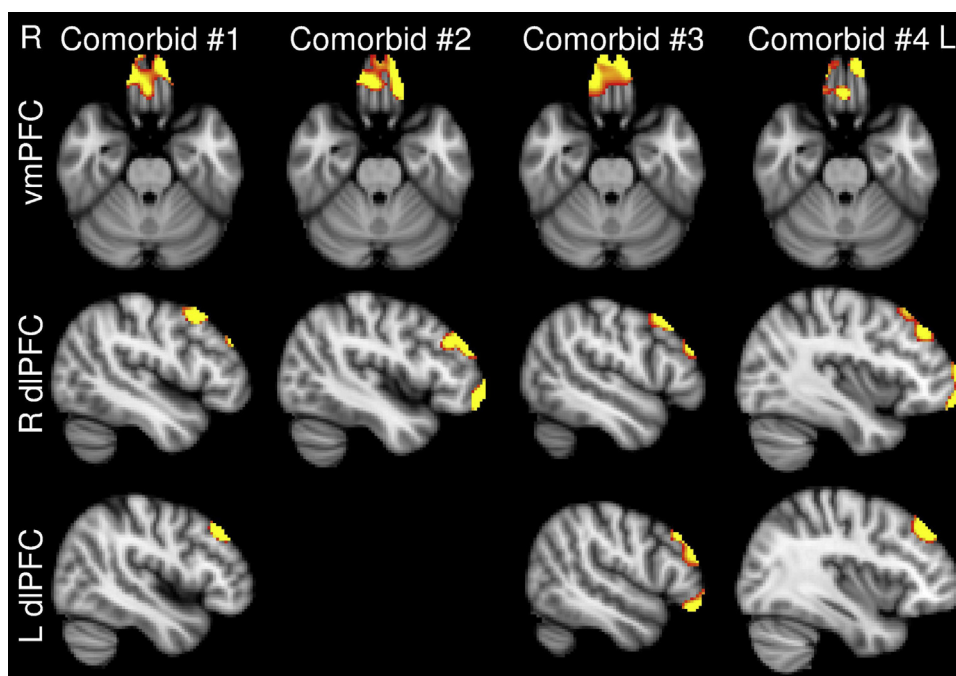
Amygdala, vmPFC, and hippocampal regions implicated in pre-clinical fear processing are thought to be dysfunctional in PTSD (Rauch et al., 1998, 2006). Functional neuroimaging findings using positron emission topography (PET) and functional magnetic resonance imaging (fMRI) suggest that individuals with PTSD exhibit hyperresponsive amygdala activity to trauma or fear-related stimuli (for review, see Shin and Liberzon, 2010), during emotionally neutral tasks (Bryant et al., 2005; Shin et al., 2004b), and even at rest (Chung et al., 2006; Semple et al., 2000). A hyperresponsive amygdala contributes to the exaggerated fear response characteristic of PTSD (Anderson et al., 2003). Conversely, PTSD has been associated repeatedly with hyporesponsive vmPFC (for review, see Hughes and Shin, 2011). Hyporesponsive PFC, as well as reduced connectivity to the amygdala (Jin et al., 2013; Shin et al., 2004a) may indicate insufficient inhibitory control over exaggerated fear responses. Lastly, abnormal hippocampal function

(Corcoran and Maren, 2001) and reduced connectivity to the amygdala (Dolcos et al., 2004; McGaugh, 2004) may underlie impairments in contextual memory processing and the ability to inhibit intrusive memories (Shin et al., 2004a), although findings have been mixed (Hughes and Shin, 2011). A recent resting-state fMRI study showed increased activity in amygdala and reduced spontaneous neural activity in the dorso-lateral PFC (DLPFC) (Yan et al., 2013). However, the authors found no evidence of abnormal resting-state fMRI signal in the vmPFC.

Recently, we used resting-state MEG to study 16 OEF/OIF active-duty military and veteran participants with PTSD, and 23 age-matched healthy control subjects. Among the control subjects, 12 were active-duty military personnel deployed to Iraq and/or Afghanistan and 11 were civilians without military training. Voxel-based whole brain MEG source magnitude images were obtained using our new Fast-VESTAL high-resolution MEG source imaging method (Huang et al., 2014a). Fig. 3 shows that for beta-gamma band (15–80 Hz), increased MEG activity in PTSD (hyperactivities, PTSD > controls) was generated from bilateral amygdala/anterior hippocampus, whereas decreased MEG activity was generated from the vmPFC. The MEG results were consistent with the theory that reduced inhibition (hypoactivity) from the vmPFC and hyperactivity in the “fear network” including the amygdala/anterior hippocampus are closely related. These data suggest that MEG imaging may accurately visualize brain evidence of PTSD, but more research is needed to fully develop MEG as a potential biomarker for PTSD.

As discussed earlier, TBI significantly potentiates PTSD development. Here we present some preliminary data of using a voxel-based MEG source imaging approach to evaluate the potentiation of PTSD by an mTBI. The new aspect of the study is to provide much needed information regarding exactly what brain regions that are part of the abnormal PTSD neurocircuitry are also particularly vulnerable to mTBI. Such information may contribute to more effective treatments for veterans with comorbid mTBI and PTSD, and guide the development of preventive strategies in PTSD.





**Figure 4** MEG source imaging showing slow-wave generation in four patients with comorbid mTBI and PTSD from vmPFC and dlPFC suggests that mTBI may potentiate the development of PTSD.

Fig. 4 shows preliminary data of abnormal MEG slow-waves from 4 patients with comorbid mTBI and PTSD. All patients showed abnormal slow-waves (1–4 Hz) from vmPFC, 3 out of 4 showed bilateral dlPFC abnormal slow-waves, and 1 showed right dlPFC abnormal slow-wave generation, indicating potential injuries due to mTBI. The slow-wave generation suggests mTBI in these PFC areas. In addition, similar to the preliminary result from the group of 25 PTSD subjects, these 4 comorbid patients also showed MEG hypoactivity from vmPFC and dlPFC in high frequency bands when compared with the HCs, similar to the findings presented in Fig. 3. In this comorbid group, the co-existence of abnormal MEG slow-wave (mTBI component) and hypoactivity from vmPFC and dlPFC in high frequency bands (PTSD component) suggests the mTBI injuries in PFC may result in a lack of inhibition from PFC to other areas of the PTSD neurocircuitry. This preliminary data, thus, provides evidence of abnormal slow-wave generation in these PFC areas due to mTBI and the potentiation of PTSD.

#### 4. Limitations of this study

There are several limitations of this study: One concern with neuroimaging studies, including many recent studies involving OIF/OEF veterans, are the reliance on convenience samples and the use of control groups that do not always provide adequate scientific comparisons (Hoge and Castro, 2011, 2014). Next, we have focused on the potentiation of PTSD development due to mTBI. Deployment to Iraq or Afghanistan, as in past wars, is certainly associated with non-specific generalized physical and cognitive health effects, and it is likely that there are multiple causes for these health concerns beyond mTBI and PTSD (e.g.

prolonged periods of sleep deprivation, combat intensity, intense physical strain on the body from harsh foot patrols, depression, repetitive load-bearing injuries, etc.) (Hoge and Castro et al., 2014). Also, deployment experiences are highly variable. Roughly two-thirds of OIF/OEF service members worked principally inside heavily fortified compounds with limited exposure to war-zone stressors (other than random indirect fire). The other one-third, mostly infantry brigades, have done the lion's share of the direct combat heavy lifting, but even in those units there is high variability of exposure experiences. Clearly service members in units that experience more direct combat, higher levels of sleep deprivation, and more non-head injuries will likely have higher rates of non-specific abnormalities on functional neuroimaging (to include vmPFC or dlPFC) than comparison groups that did not have this level of deployment intensity, and thus it is important in future studies to consider these factors when designing studies that attempt to look at the neuroimaging associated with blast, mTBI or PTSD cases. In the present study, our control group for the MEG slow-wave source imaging study contains a mix of active-duty military and civilian subjects. This mix was necessary since we assessed both subjects with blast-induced mTBI as well as civilian mTBI subjects without blast exposure. Nevertheless, the imbalance of active-duty military subjects between the control and blast mTBI groups remains a limitation.

Also, as noted previously, the focus of this paper is on mTBI and on MEG imaging, thus an exploration of the full range of biomarkers, in particular the large literature on blood-based biomarkers in PTSD, was beyond the scope of this paper. The common co-existence of mTBI and PTSD pose further significant challenges for blood-based biomarker research in both mTBI and PTSD in military and veteran populations, since co-occurrence of either must be assessed,

and considered during study enrollment, and is a limitation of current research. Since blast exposure is a risk for PTSD development, and there is significant overlap in PTSD and mTBI, an ultimate goal of the MEG research will be the development imaging biomarkers for PTSD, and for mTBI on a single subject basis, i.e. diagnostic biomarkers.

## 5. Conclusion

In summary, TBI is a highly prevalent condition, although the majority of cases of TBI are mild. While the social and fiscal impact of moderate and severe TBI has been well known, until recently, the potential negative impact of mTBI on health has been underappreciated. In contrast to tools available in the 20th century, we now have great advancements in technology that, combined with pre-clinical insights, can support development of improved approaches for clinical visualization of the mTBI injuries, which may provide a basis for a new schema for mTBI diagnosis. With more precise diagnostic approaches, such as high resolution imaging, and cerebrospinal fluid or blood testing, we may ultimately be able to develop imaging and bodily fluid biomarkers for use in prognosis, diagnosis, or as treatment outcome measures.

## Conflict of interest

All authors report no further biomedical financial interests or potential conflicts of interest.

## Acknowledgements

We gratefully acknowledge the fiscal support for our work. Acknowledgements include Veterans Affairs Health Service Research and Development project SDR 09-0128 (DGB), the Marine Corps (MXH, DGB), and the Navy Bureau of Medicine and Surgery (MXH, DGB), Merit Review Grants from the Department of Veterans Affairs (MXH, DGB, I01-CX000499, NURC-022-10F) as well as support of the VA Center of Excellence for Stress and Mental Health San Diego, CA, USA (DGB) and the Swedish Defense FoT Research funding program. We also thank the anonymous reviewers' constructive suggestions that substantially strengthen this study.

## References

Adams, J.H., Doyle, D., Ford, I., Gennarelli, T.A., Graham, D.I., McLellan, D.R., 1989. Diffuse axonal injury in head injury: definition, diagnosis and grading. *Histopathology* 15, 49–59.

Agoston, D.V., Risling, M., Bellander, B.M., 2012. Bench-to bedside and bedside back to the bench; coordinating clinical and experimental traumatic brain injury studies. *Front. Neurol.* 3, 3.

Anderson, A.K., Christoff, K., Panitz, D., De, R.E., Gabrieli, J.D., 2003. Neural correlates of the automatic processing of threat facial signals. *J. Neurosci.* 23, 5627–5633.

Antona-Makoshi, J., Davidsson, J., Risling, M., Ejima, S., Ono, K., 2014. Validation of local brain kinematics of a novel rat brain finite element model under rotational acceleration – clarification of diffuse axonal injury mechanisms. *Int. J. Autom. Eng.* 5, 31–37.

Baayen, J.C., de, J.A., Stam, C.J., De Munck, J.C., Jonkman, J.J., Trenite, D.G., Berendse, H.W., van Walsum, A.M., Heimans, J.J.,

Puligheddu, M., Castelijns, J.A., Vandertop, W.P., 2003. Localization of slow wave activity in patients with tumor-associated epilepsy. *Brain Topogr.* 16, 85–93.

Baker, D.G., Nash, W.P., Litz, B.T., Geyer, M.A., Risbrough, V.B., Nievergelt, C.M., O'Connor, D.T., Larson, G.E., Schork, N.J., Vasterling, J.J., Hammer, P.S., Webb-Murphy, J.A., MRS Team, 2012. Predictors of risk and resilience for posttraumatic stress disorder among ground combat Marines: methods of the marine resiliency study. *CDC Prev. Chron. Dis.* 9 (10), E97.

Ball, G.J., Gloor, P., Schaul, N., 1977. The cortical electromyophysiology of pathological delta waves in the electroencephalogram of cats. *Electroencephalogr. Clin. Neurophysiol.* 43, 346–361.

Basser, P.J., Pierpaoli, C., 1996. Microstructural and physiological features of tissues elucidated by quantitative-diffusion-tensor MRI. *J. Magn Reson. B* 111, 209–219.

Baxter, D., Sharp, D.J., Feeney, C., Papadopoulou, D., Ham, T.E., Jilka, S., Hellyer, P.J., Patel, M.C., Bennett, A.N., Mistlin, A., McGilloway, E., Midwinter, M., Goldstone, A.P., 2013. Pituitary dysfunction after blast traumatic brain injury: the UK BIOSAP study. *Ann. Neurol.* 74 (4), 527–536.

Bigler, E.D., Orrison, W.W., 2004. Neuroimaging in sports-related brain injury. In: Lovell, M.R., Echemendia, R.J., Barth, J.T., Collins, M.W. (Eds.), *Traumatic Brain Injury in Sports: An International Perspective*. Swets and Zeitlinger, Lisse, Netherlands, pp. 71–94.

Birnie, M., Morrison, R., Camara, R., Strauss, K.I., 2013. Temporal changes of cytochrome P450 (Cyp) and eicosanoid-related gene expression in the rat brain after traumatic brain injury. *BMC Genomics* 14, 303.

Bryant, R.A., Felmingham, K.L., Kemp, A.H., Barton, M., Peduto, A.S., Rennie, C., Gordon, E., Williams, L.M., 2005. Neural networks of information processing in posttraumatic stress disorder: a functional magnetic resonance imaging study. *Biol. Psychiatry* 58, 111–118.

Bryant, R.A., O'Donnell, M.L., Creamer, M., McFarlane, A.C., Clark, C.R., Silove, D., 2010. The psychiatric sequelae of traumatic injury. *Am. J. Psychiatry* 167 (3), 312–320.

Celander, H., Clemedson, C.J., Ericsson, U.A., Hultman, H.I., 1955. The use of a compressed air operated shock tube for physiological blast research. *Acta Physiol. Scand.* 33 (1), 6–13.

Centers for Disease Control and Prevention and National Center for Injury Prevention and Control, 2003. *Report to Congress on Mild Traumatic Brain Injury in the United States: Steps to Prevent a Serious Public Health Problem*. Centers for Disease Control and Prevention, Atlanta, GA, USA.

Cernak, I., 2010. The importance of systemic response in the pathobiology of blast-induced neurotrauma. *Front. Neurol.* 1 (151), 1–9.

Cernak, I., Merkle, A.C., Koliatsos, V.E., Bilik, J.M., Luong, Q.T., Mahota, T.M., Xu, L., Slack, N., Windle, D., Ahmed, F.A., 2011. The pathobiology of blast injuries and blast-induced neurotrauma as identified using a new experimental model of injury in mice. *Neurobiol. Dis.* 41 (2), 538–551.

Chung, Y.A., Kim, S.H., Chung, S.K., Chae, J.H., Yang, D.W., Sohn, H.S., Jeong, J., 2006. Alterations in cerebral perfusion in posttraumatic stress disorder patients without re-exposure to accident-related stimuli. *Clin. Neurophysiol.* 117, 637–642.

Clemedson, C.J., 1949. An experimental study on air blast injuries. *Acta Physiol. Scand.* 18 (Suppl. LXI).

Clemedson, C.J., Criborn, C.O., 1955. A detonation chamber for physiological blast research. *J. Aviat. Med.* 26 (5), 373–381.

Corcoran, K.A., Maren, S., 2001. Hippocampal inactivation disrupts contextual retrieval of fear memory after extinction. *J. Neurosci.* 21, 1720–1726.

Culotta, V.P., Sementilli, M.E., Gerold, K., Watts, C.C., 1996. Clinicopathological heterogeneity in the classification of mild head injury. *Neurosurgery* 38, 245–250.

- Davenport, N.D., Lim, K.O., Armstrong, M.T., Sponheim, S.R., 2012. Diffuse and spatially variable white matter disruptions are associated with blast-related mild traumatic brain injury. *Neuroimage* 59, 2017–2024.
- de Jongh, A., Baayen, J.C., De Munck, J.C., Heethaar, R.M., Vandertop, W.P., Stam, C.J., 2003. The influence of brain tumor treatment on pathological delta activity in MEG. *Neuroimage* 20, 2291–2301.
- de Kloet, C.S., Vermetten, E., Geuze, E., Kavelaars, A., Heijnen, C.J., Westenberg, H.G., 2006. Assessment of HPA-axis function in posttraumatic stress disorder: pharmacological and non-pharmacological challenge tests, a review. *J. Psychiatr. Res.* 40 (6), 550–567.
- Decker Jr., D.A., Knott, J.R., 1972. The EEG in intrinsic supratentorial brain tumors: a comparative evaluation, *Electroencephalogr. Clin. Neurophysiol.* 33, 303–310.
- Dolcos, F., LaBar, K.S., Cabeza, R., 2004. Interaction between the amygdala and the medial temporal lobe memory system predicts better memory for emotional events. *Neuron* 42, 855–863.
- Editorial, 2007. Grappling with traumatic brain injury. *Lancet* 370 (9603), 1879.
- Fulton, J.F., 1942. Blast and concussion in the present war. *N. Engl. J. Med.* 226 (1), 1–8.
- Galarneau, M.R., Woodruff, S.I., Dye, J.L., Mohrle, C.R., Wade, A.L., 2008. Traumatic brain injury during operation Iraqi freedom: findings from the United States Navy-Marine Corps Combat Trauma Registry. *J. Neurosurg.* 108 (5), 950–957.
- Garman, R.H., Jenkins, L.W., Switzer III, R.C., Bauman, R.A., Tong, L.C., Swauger, P.V., Parks, S.A., Ritzel, D.V., Dixon, C.E., Clark, R.S., Bayir, H., Kagan, V., Jackson, E.K., Kochanek, P.M., 2011. Blast exposure in rats with body shielding is characterized primarily by diffuse axonal injury. *J. Neurotrauma* 28, 947–959.
- Gennarelli, T.A., Thibault, L.E., Adams, J.H., Graham, D.I., Thompson, C.J., Marcincin, R.P., 1982. Diffuse axonal injury and traumatic coma in the primate. *Ann. Neurol.* 12, 564–574.
- Gloor, P., Ball, G., Schaul, N., 1977. Brain lesions that produce delta waves in the EEG. *Neurology* 27, 326–333.
- Glushakova, O.Y., Johnson, D., Hayes, R.L., 2014. Delayed increases in microvascular pathology after experimental traumatic brain injury are associated with prolonged inflammation, blood–brain barrier disruption, and progressive white matter damage. *J. Neurotrauma* 31 (13), 1180–1193.
- Goldstein, L.E., McKee, A.C., Stanton, P.K., 2014. Considerations for animal models of blast-related traumatic brain injury and chronic traumatic encephalopathy. *Alzheimers Res. Ther.* 6 (5), 64.
- Gunther, M., Plantman, S., Davidsson, J., Angeria, M., Mathiesen, T., Risling, M., 2015. COX-2 regulation and TUNEL-positive cell death differ between genders in the secondary inflammatory response following experimental penetrating focal brain injury in rats. *Acta Neurochir. (Wien)*.
- Guskiewicz, K.M., Marshall, S.W., Bailes, J., McCrea, M., Cantu, R.C., Randolph, C., Jordan, B.D., 2005. Association between recurrent concussion and late-life cognitive impairment in retired professional football players. *Neurosurgery* 57 (4), 719–726, discussion, 719–726.
- Hoffman, S.W., Harrison, C., 2009. The interaction between psychological health and traumatic brain injury: a neuroscience perspective. *Clin. Neuropsychol.* 23, 1400–1415.
- Hoge, C.W., McGurk, D., Thomas, J.L., Cox, A.L., Engel, C.C., Castro, C.A., 2008. Mild traumatic brain injury in U.S. soldiers returning from Iraq. *N. Engl. J. Med.* 358 (5), 453–463.
- Hoge, C.W., Goldberg, H.M., Castro, C.A., 2009. Care of war veterans with mild traumatic brain injury – flawed perspectives. *N. Engl. J. Med.* 360 (16), 1588–1591.
- Hoge, C.W., Castro, C.A., 2011. Blast-related traumatic brain injury in U.S. military personnel. *N. Engl. J. Med.* 365 (9), 860.
- Hoge, C.W., Castro, C.A., 2014. Treatment of generalized war-related health concerns: placing TBI and PTSD in context. *J. Am. Med. Assoc.* 312 (16), 1685–1686.
- Huang, M.X., Huang, C.W., Robb, A., Angeles, A., Nichols, S.L., Baker, D.G., Song, T., Harrington, D.L., Theilmann, R.J., Srinivasan, R., Heister, D., Diwakar, M., Canive, J.M., Edgar, J.C., Chen, Y.H., Ji, Z., Shen, M., El-Gabalawy, F., Levy, M., McLay, R., Webb-Murphy, J., Liu, T.T., Drake, A., Lee, R.R., 2014a. MEG source imaging method using fast L1 minimum-norm and its applications to signals with brain noise and human resting-state source amplitude images. *Neuroimage* 84, 585–604.
- Huang, M.X., Nichols, S., Baker, D.G., Robb, A., Angeles, A., Yurgil, K.A., Drake, A., Levy, M., Song, T., McLay, R., Theilmann, R.J., Diwakar, M., Risbrough, V.B., Ji, Z., Huang, C.W., Chang, D.G., Harrington, D.L., Muzzatti, L., Canive, J.M., Christopher, E.J., Chen, Y.H., Lee, R.R., 2014b. Single-subject-based whole-brain MEG slow-wave imaging approach for detecting abnormality in patients with mild traumatic brain injury. *Neuroimage Clin.* 5, 109–119.
- Huang, M.X., Nichols, S., Robb, A., Angeles, A., Drake, A., Holland, M., Asmussen, S., D’Andrea, J., Chun, W., Levy, M., Cui, L., Song, T., Baker, D.G., Hammer, P., McLay, R., Theilmann, R.J., Coimbra, R., Diwakar, M., Boyd, C., Neff, J., Liu, T.T., Webb-Murphy, J., Farinpour, R., Cheung, C., Harrington, D.L., Heister, D., Lee, R.R., 2012. An automatic MEG low-frequency source imaging approach for detecting injuries in mild and moderate TBI patients with blast and non-blast causes. *Neuroimage* 61, 1067–1082.
- Huang, M.X., Theilmann, R.J., Robb, A., Angeles, A., Nichols, S., Drake, A., D’Andrea, J., Levy, M., Holland, M., Song, T., Ge, S., Hwang, E., Yoo, K., Cui, L., Baker, D.G., Trauner, D., Coimbra, R., Lee, R.R., 2009. Integrated imaging approach with MEG and DTI to detect mild traumatic brain injury in military and civilian patients. *J. Neurotrauma* 26, 1213–1226.
- Hughes, K.C., Shin, L.M., 2011. Functional neuroimaging studies of post-traumatic stress disorder. *Expert. Rev. Neurother.* 11, 275–285.
- Jeter, C.B., Hergenroeder, G.W., Hylin, M.J., Redell, J.B., Moore, A.N., Dash, P.K., 2013. Biomarkers for the diagnosis and prognosis of mild traumatic brain injury/concussion. *J. Neurotrauma* 30, 657–670.
- Jin, C., Qi, R., Yin, Y., Hu, X., Duan, L., Xu, Q., Zhang, Z., Zhong, Y., Feng, B., Xiang, H., Gong, Q., Liu, Y., Lu, G., Li, L., 2013. Abnormalities in whole-brain functional connectivity observed in treatment-naive post-traumatic stress disorder patients following an earthquake. *Psychol. Med.*, 1–10.
- Johnston, K.M., Ptito, A., Chankowsky, J., Chen, J.K., 2001. New frontiers in diagnostic imaging in concussive head injury. *Clin. J. Sport Med.* 11, 166–175.
- Jones, E., Fear, N.T., Wessely, S., 2007. Shell shock and mild traumatic brain injury: a historical review. *Am. J. Physiol.* 164, 1641–1645.
- Luethcke, C.A., Bryan, C.J., Morrow, C.E., Isler, W.C., 2011. Comparison of concussive symptoms, cognitive performance, and psychological symptoms between acute blast-versus nonblast-induced mild traumatic brain injury. *J. Int. Neuropsychol. Soc.* 17, 36–45.
- Kamnaksh, A., Kovesdi, E., Kwon, S.K., Wingo, D., Ahmed, F., Grunberg, N.E., Long, J., Agoston, D.V., 2011. Factors affecting blast traumatic brain injury. *J. Neurotrauma* 28 (10), 2145–2153.
- Kamnaksh, A., Budde, M.D., Kovesdi, E., Long, J.B., Frank, J.A., Agoston, D.V., 2014. Diffusion tensor imaging reveals acute subcortical changes after mild blast-induced traumatic brain injury. *Sci. Rep.* 4, 4809.
- Kawa, L., Arborelius, U., Yoshitake, T., Kehr, J., Hokfelt, T., Risling, M., Agoston, D.V., 2014. Neurotransmitter systems in a mild blast traumatic brain injury model: catecholamines and serotonin.

- J. Neurotrauma, <http://dx.doi.org/10.1089/neu.2014.3669> (in press).
- Kirkwood, M.W., Yeates, K.O., Wilson, P.E., 2006. Pediatric sport-related concussion: a review of the clinical management of an oft-neglected population. *Pediatrics* 117, 1359–1371.
- Kleiven, S., 2007. Predictors for traumatic brain injuries evaluated through accident reconstructions. *Stapp Car Crash J.* 51, 81–114.
- Kovesdi, E., Gyorgy, A.B., Kwon, S.K., Wingo, D.L., Kamnaksh, A., Long, J.B., Kasper, C.E., Agoston, D.V., 2011. The effect of enriched environment on the outcome of traumatic brain injury; a behavioral, proteomics, and histological study. *Front. Neurosci.* 5, 42.
- Krystal, J.H., Neumeister, A., 2009. Noradrenergic and serotonergic mechanisms in the neurobiology of posttraumatic stress disorder and resilience. *Brain Res.* 1293, 13–23.
- Kwon, S.K., Kovesdi, E., Gyorgy, A.B., Wingo, D., Kamnaksh, A., Walker, J., Long, J.B., Agoston, D.V., 2011. Stress and traumatic brain injury: a behavioral, proteomics, and histological study. *Front. Neurol.* 2, 12.
- Lakis, N., Corona, R.J., Toshkezi, G., Chin, L.S., 2013. Chronic traumatic encephalopathy – neuropathology in athletes and war veterans. *Neurol. Res.* 35 (3), 290–299.
- Leahy, R.M., Mosher, J.C., Spencer, M.E., Huang, M.X., Lewine, J.D., 1998. A study of dipole localization accuracy for MEG and EEG using a human skull phantom. *Electroencephalogr. Clin. Neurophysiol.* 107, 159–173.
- Lee, K.Y., Nyein, M.K., Moore, D.F., Joannopoulos, J.D., Socrate, S., Imholt, T., Radovitzky, R., Johnson, S.G., 2011. Blast-induced electromagnetic fields in the brain from bone piezoelectricity. *Neuroimage* 54 (Suppl. 1), S30–S36.
- Lewine, J.D., Davis, J.T., Bigler, E.D., Thoma, R., Hill, D., Funke, M., Sloan, J.H., Hall, S., Orrison, W.W., 2007. Objective documentation of traumatic brain injury subsequent to mild head trauma: multimodal brain imaging with MEG, SPECT, and MRI. *J. Head Trauma Rehabil.* 22, 141–155.
- Lewine, J.D., Davis, J.T., Sloan, J.H., Kodituwakku, P.W., Orrison Jr., W.W., 1999. Neuromagnetic assessment of pathophysiologic brain activity induced by minor head trauma. *AJNR Am. J. Neuroradiol.* 20, 857–866.
- Lewine, J.D., Orrison Jr., W.W., 1995. Spike and slow wave localization by magnetoencephalography. *Neuroimaging Clin. N. Am.* 5, 575–596.
- O’Neil, M.E., Carlson, K., Storzbach, D., Brenner, L., Freeman, M., Quiñones, A., Motu’apuaka, M., Ensley, M., Kansagara, D., 2013. Complications of Mild Traumatic Brain Injury in Veterans and Military Personnel: A Systematic Review. Department of Veterans Affairs (US), Washington, DC, Available from: <http://www.ncbi.nlm.nih.gov/books/NBK189785/PubMedPMID:24600749> [Internet].
- MacDonald, C.L., Johnson, A.M., Cooper, D., Nelson, E.C., Werner, N.J., Shimony, J.S., Snyder, A.Z., Raichle, M.E., Witherow, J.R., Fang, R., Flaherty, S.F., Brody, D.L., 2011. Detection of blast-related traumatic brain injury in U.S. military personnel. *N. Engl. J. Med.* 364, 2091–2100.
- MacDonald, C.L., Johnson, A.M., Nelson, E.C., Werner, N.J., Fang, R., Flaherty, S.F., Brody, D.L., 2014. Functional status after blast-plus-impact complex concussive traumatic brain injury in evacuated United States military personnel. *J. Neurotrauma* 31 (10), 889–898.
- MacGregor, A.J., Dougherty, A.L., Galarneau, M.R., 2011. Injury-specific correlates of combat-related traumatic brain injury in operation Iraqi freedom. *J. Head Trauma Rehabil.* 26 (4), 312–318.
- Mayou, R.A., Black, J., Bryant, B., 2000. Unconsciousness, amnesia and psychiatric symptoms following road traffic accident injury. *Br. J. Psychiatry* 177, 540–545.
- McFarlane, A.C., Barton, C.A., Briggs, N., Kennaway, D.J., 2010. The relationship between urinary melatonin metabolite excretion and posttraumatic symptoms following traumatic injury. *J. Affect. Disord.* 127 (1–3), 365–369.
- McGaugh, J.L., 2004. The amygdala modulates the consolidation of memories of emotionally arousing experiences. *Annu. Rev. Neurosci.* 27, 1–28.
- Myers, C.S., 1915. A contribution to the study of shell shock. *Lancet* 185 (4772), 316–320.
- Nagata, K., Gross, C.E., Kindt, G.W., Geier, J.M., Adey, G.R., 1985. Topographic electroencephalographic study with power ratio index mapping in patients with malignant brain tumors. *Neurosurgery* 17, 613–619.
- Naviaux, R.K., 2014. Metabolic features of the cell danger response. *Mitochondrion* 16, 7–17.
- Petraglia, A.L., Plog, B.A., Dayawansa, S., Chen, M., Dashnaw, M.L., Czerniecka, K., Walker, C.T., Viterise, T., Hyrien, O., Iliff, J.J., Deane, R., Nedergaard, M., Huang, J.H., 2014a. The spectrum of neurobehavioral sequelae after repetitive mild traumatic brain injury: a novel mouse model of chronic traumatic encephalopathy. *J. Neurotrauma* 31 (13), 1211–1224.
- Petraglia, A.L., Plog, B.A., Dayawansa, S., Dashnaw, M.L., Czerniecka, K., Walker, C.T., Chen, M., Hyrien, O., Iliff, J.J., Deane, R., Huang, J.H., Nedergaard, M., 2014b. The pathophysiology underlying repetitive mild traumatic brain injury in a novel mouse model of chronic traumatic encephalopathy. *Surg. Neurol. Int.* 5, 184.
- Petrie, E.C., Cross, D.J., Yarnykh, V.L., Richards, T., Martin, N.M., Pagulayan, K., Hoff, D., Hart, K., Mayer, C., Tarabochia, M., Raskind, M.A., Minoshima, S., Peskind, E.R., 2014. Neuroimaging, behavioral, and psychological sequelae of repetitive combined blast/impact mild traumatic brain injury in Iraq and Afghanistan war veterans. *J. Neurotrauma* 31 (5), 425–436.
- Rauch, S.L., Shin, L.M., Phelps, E.A., 2006. Neurocircuitry models of posttraumatic stress disorder and extinction: human neuroimaging research—past, present, and future. *Biol. Psychiatry* 60, 376–382.
- Rauch, S.L., Shin, L.M., Whalen, P.J., Pitman, R.K., 1998. Neuroimaging and the neuroanatomy of PTSD. *CNS Spectrums* 3 (Suppl. 2), 30–41.
- Raymont, V., Salazar, A.M., Krueger, F., Grafman, J., 2011. Studying injured minds – the Vietnam head injury study and 40 years of brain injury research. *Front. Neurol.* 2 (15), 1–13.
- Risling, M., Plantman, S., Angeria, M., Rostami, E., Bellander, B.M., Kirkegaard, M., Arborelius, U., Davidsson, J., 2011. Mechanisms of blast induced brain injuries, experimental studies in rats. *Neuroimage* 54 (Suppl. 1), S89–S97.
- Roitman, P., Gilad, M., Ankri, Y.L., Shalev, A.Y., 2013. Head injury and loss of consciousness raise the likelihood of developing and maintaining PTSD symptoms. *J. Trauma Stress* 26 (6), 727–734.
- Rosenfeld, J.V., McFarlane, A.C., Bragge, P., Armonda, R.A., Grimes, J.B., Ling, G.S., 2013. Blast-related traumatic brain injury. *Lancet Neurol.* 12, 882–893.
- Rostami, E., Krueger, F., Plantman, S., Davidsson, J., Agoston, D., Grafman, J., Risling, M., 2014. Alteration in BDNF and its receptors, full-length and truncated TrkB and p75(NTR) following penetrating traumatic brain injury. *Brain Res.* 1542, 195–205.
- Rostami, E., Krueger, F., Zoubak, S., Dal Monte, O., Raymont, V., Pardini, M., Hodgkinson, C.A., Goldman, D., Risling, M., Grafman, J., 2011. BDNF polymorphism predicts general intelligence after penetrating traumatic brain injury. *PLoS ONE* 6 (11), e27389.
- Schaul, N., 1998. The fundamental neural mechanisms of electroencephalography. *Electroencephalogr. Clin. Neurophysiol.* 106, 101–107.
- Schaul, N., Gloor, P., Ball, G., Gotman, J., 1978. The electromicrophysiology of delta waves induced by systemic atropine. *Brain Res.* 143, 475–486.

- Schneiderman, A.I., Braver, E.R., Kang, H.K., 2008. Understanding sequelae of injury mechanisms and mild traumatic brain injury incurred during the conflicts in Iraq and Afghanistan: Persistent postconcussive symptoms and posttraumatic stress disorder. *Am. J. Epidemiol.* 167 (12), 1446–1452.
- Seifman, M.A., Gomes, K., Nguyen, P.N., Bailey, M., Rosenfeld, J.V., Cooper, D.J., Morganti-Kossmann, M.C., 2014. Measurement of serum melatonin in intensive care unit patients: changes in traumatic brain injury, trauma, and medical conditions. *Front. Neurol.* 5, 237.
- Selden, N.R., Gitelman, D.R., Salamon-Murayama, N., Parrish, T.B., Mesulam, M.M., 1998. Trajectories of cholinergic pathways within the cerebral hemispheres of the human brain. *Brain* 121 (Pt 12), 2249–2257.
- Semple, W.E., Goyer, P.F., McCormick, R., Donovan, B., Muzic Jr., R.F., Rugle, L., McCutcheon, K., Lewis, C., Liebling, D., Kowaliw, S., Vapenik, K., Semple, M.A., Flener, C.R., Schulz, S.C., 2000. Higher brain blood flow at amygdala and lower frontal cortex blood flow in PTSD patients with comorbid cocaine and alcohol abuse compared with normals. *Psychiatry* 63, 65–74.
- Shenton, M.E., Hamoda, H.M., Schneiderman, J.S., Bouix, S., Pasternak, O., Rathi, Y., Vu, M.A., Purohit, M.P., Helmer, K., Koerte, I., Lin, A.P., Westin, C.F., Kikinis, R., Kubicki, M., Stern, R.A., Zafonte, R., 2012. A review of magnetic resonance imaging and diffusion tensor imaging findings in mild traumatic brain injury. *Brain Imaging Behav.* 6, 137–192.
- Shin, L.M., Liberzon, I., 2010. The neurocircuitry of fear, stress, and anxiety disorders. *Neuropsychopharmacology* 35, 169–191.
- Shin, L.M., Orr, S.P., Carson, M.A., Rauch, S.L., Macklin, M.L., Lasko, N.B., Peters, P.M., Metzger, L.J., Dougherty, D.D., Cannistraro, P.A., Alpert, N.M., Fischman, A.J., Pitman, R.K., 2004a. Regional cerebral blood flow in the amygdala and medial prefrontal cortex during traumatic imagery in male and female Vietnam veterans with PTSD. *Arch. Gen. Psychiatry* 61, 168–176.
- Shin, L.M., Shin, P.S., Heckers, S., Krangel, T.S., Macklin, M.L., Orr, S.P., Lasko, N., Segal, E., Makris, N., Richert, K., Levering, J., Schacter, D.L., Alpert, N.M., Fischman, A.J., Pitman, R.K., Rauch, S.L., 2004b. Hippocampal function in posttraumatic stress disorder. *Hippocampus* 14, 292–300.
- Stein, T.D., Alvarez, V.E., McKee, A.C., 2014. Chronic traumatic encephalopathy: a spectrum of neuropathological changes following repetitive brain trauma in athletes and military personnel. *Alzheimers Res. Ther.* 6 (1), 4.
- Tate, C.M., Wang, K.K., Eonta, S., Zhang, Y., Carr, W., Tortella, F.C., Hayes, R.L., Kamimori, G.H., 2013. Serum brain biomarker level, neurocognitive performance, and self-reported symptom changes in soldiers repeatedly exposed to low-level blast: a breacher pilot study. *J. Neurotrauma* 30 (19), 1620–1630.
- Teasdale, G., Jennett, B., 1974. Assessment of coma and impaired consciousness. A practical scale. *Lancet* 2, 81–84.
- Van Boven, R.W., Harrington, G.S., Hackney, D.B., Ebel, A., Gauger, G., Bremner, J.D., D’Esposito, M., Detre, J.A., Haacke, E.M., Jack Jr., C.R., Jagust, W.J., Le, B.D., Mathis, C.A., Mueller, S., Mukherjee, P., Schuff, N., Chen, A., Weiner, M.W., 2009. Advances in neuroimaging of traumatic brain injury and post-traumatic stress disorder. *J. Rehabil. Res. Dev.* 46, 717–757.
- van Liempt, S., Arends, J., Cluitmans, P.J., Westenberg, H.G., Kahn, R.S., Vermetten, E., 2013. Sympathetic activity and hypothalamo-pituitary-adrenal axis activity during sleep in post-traumatic stress disorder: a study assessing polysomnography with simultaneous blood sampling. *Psychoneuroendocrinology* 38 (1), 155–165.
- Vasterling, J.J., Brailey, K., Proctor, S.P., Kane, R., Heeren, T., Franz, M., 2012. Neuropsychological outcomes of mild traumatic brain injury, post-traumatic stress disorder and depression in Iraq-deployed US Army soldiers. *Br. J. Psychiatry* 201, 186–192.
- Vieth, J.B., Kober, H., Grummich, P., 1996. Sources of spontaneous slow waves associated with brain lesions, localized by using the MEG. *Brain Topogr.* 8, 215–221.
- Xu, J., Rasmussen, I.A., Lagopoulos, J., Haberg, A., 2007. Diffuse axonal injury in severe traumatic brain injury visualized using high-resolution diffusion tensor imaging. *J. Neurotrauma* 24, 753–765.
- Yan, X., Brown, A.D., Lazar, M., Cressman, V.L., Henn-Haase, C., Neylan, T.C., Shalev, A., Wolkowitz, O.M., Hamilton, S.P., Yehuda, R., Sodickson, D.K., Weiner, M.W., Marmar, C.R., 2013. Spontaneous brain activity in combat related PTSD. *Neurosci. Lett.* 547, 1–5.
- Yurgil, K.A., Barkauskas, D.A., Vasterling, J.J., Nievergelt, C.M., Larson, G.E., Schork, N.J., Litz, B.T., Nash, W.P., Baker, D.G., Marine Resiliency Study Team, 2014. Association between traumatic brain injury and risk of posttraumatic stress disorder in active-duty Marines. *JAMA Psychiatry* 71 (2), 149–157.