

# **UCLA**

## **Proceedings of UCLA Health**

### **Title**

A Hidden Danger: A 20-Year-Old Female with Recurrent Urinary Tract Infections Due to Underlying Vesicoureteral Reflux Resulting in Chronic Pyelonephritis and Chronic Pain

### **Permalink**

<https://escholarship.org/uc/item/2pz5b7qj>

### **Journal**

Proceedings of UCLA Health, 22(1)

### **Authors**

Sun, Shih-Fan

Hanna, Ramy M

### **Publication Date**

2018-08-28

## CLINICAL VIGNETTE

---

# A Hidden Danger: A 20-Year-Old Female with Recurrent Urinary Tract Infections Due to Underlying Vesicoureteral Reflux Resulting in Chronic Pyelonephritis and Chronic Pain

---

Shih-Fan Sun, MD and Ramy M. Hanna, MD

### Introduction

Patients with chronic urinary tract infections (UTIs) and recurrent urinary tract infections may have underlying susceptibilities. Immunosuppressed patients and female patients have increased risk for urinary tract infections due to immunosuppression and shorter urethral length. Behavioral and hygienic causes for recurrent urinary infections may be identified, and hygiene technique and increased post coital risk are two factors that can easily be modified to decrease risk.

Managing recurrent UTIs may also include prophylactic antibiotics.<sup>1</sup> While internal medicine largely avoid treating asymptomatic bacteriuria, the urological literature does make evidence based allowances for treating recurrent UTIs with antibiotic prophylaxis. One important part of evaluation is the need to have a full urological assessment of the anatomy of the genitourinary system. One important anatomical issue is the risk of vesicoureteral reflux.<sup>2</sup> This is a risk factor for recurrent urinary infections, renal injury, and renal scarring often presenting in later stages as secondary focal and segmental sclerosis (FSGS).<sup>3</sup> In patients with unrecognized congenital reflux, can have Chronic Kidney Disease (CKD) (decline of glomerular filtration rate GFR), proteinuria, and progression to End Stage Renal Disease (ESRD) before adult hood. Another danger is chronic pyelonephritis, sometimes resulting in xanthogranulomatous pyelonephritis, which often requires surgical nephrectomy.<sup>4</sup> We present a case that illustrates some of these complications and highlights the importance of considering reflux nephropathy in a young patient with recurrent urinary tract infections.

### Case Report

A 20-year-old female with history of seizure disorder, multiple kidney stones and recurrent pyelonephritis presented to clinic with bilateral flank pain for 2 weeks. She also reported prior suprapubic pain, but denied fever, chills, dysuria or hematuria. Two week prior she was evaluated at urgent care and diagnosed with urinary tract infection, and treated with 7 days of nitrofurantoin. Her suprapubic pain resolved, but bilateral flank pain persisted. Her chronic medications include lamotrigine for seizure disorder, norethindrone, and ethinyl estradiol tablets for birth control. On exam, her blood pressure was 124/81, pulse was 64, respiratory rate was 12, temperature was 35.7 °C, and

oxygen saturation was 100%. Her physical exam was notable for right-sided costovertebral angle tenderness.

Her urinalysis was negative for blood, protein, leukocyte esterase, nitrite, and white blood cells. Her creatinine was 0.88 mg/dL, urea nitrogen was 6 mg/dL, with estimate GFR of > 89, and electrolytes were within normal limits. Complete blood count was within normal limits. Uric acid was 3.8 mg/dL, cystatin C was 0.7 mg/L and bacterial urine culture showed no growth at 1:1000 dilution.

CT urogram with and without contrast showed marked right renal atrophy with multifocal cortical scarring and striated nephrogram, diffuse urothelial thickening of the right renal collecting system extending to the level of the mid right ureter, with the distal right ureter poorly visualized. Findings were suggestive of chronic infection/inflammation of the right kidney and proximal collecting system. A few punctate non-obstructing renal stones, the largest measuring 2 mm, were also seen without hydronephrosis. The left kidney and renal collecting system appeared normal. (Figure 1A)

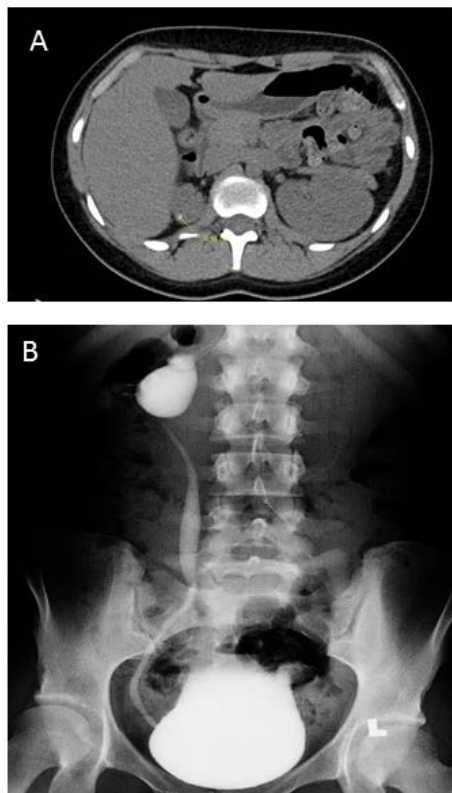
She was referred to nephrology and pediatric urology. Fluoro urethrocytogram showed severe reflux into the right renal collecting system, with dilatation of the right ureter, calyceal blunting, and pronounced pelviectasis. There was no reflux on the left. (Figure 1B) Nuclear medicine renal function imaging with furosemide showed decreased renal function of the right kidney with some initial tracer pooling in the right upper collecting system, which is likely related to pelviectasis. Post furosemide imaging demonstrates sufficient response to furosemide with clearing of most of the tracer the collecting system without evidence of obstruction. Left kidney showed normal renal flow and function without evidence of obstruction. Her right renal function provided 14% of GFR and left renal function 86% of GFR. Diagnosis of vesicoureteral reflux was made and she was offered nephrectomy or a trial of Deflux (hyaluronic acid/dextranome) as an initial approach, with possible future right nephrectomy if she continues to have recurrent UTIs. Patient decided to pursue Deflux trial.

## Discussion

This case demonstrated the importance of thorough evaluation of repeated urinary tract infections. Evaluation of urinary habits, immune status, and importantly, a review of the anatomy of the urinary collecting systems. Obstructing stones, vesicoureteral reflux, certain cystic disease (like polycystic kidney disease) may all harbor nidus for ongoing infections. This can result in serious infections such as xanthogranulomatous pyelonephritis, as well as chronic renal damage leading to CKD and ESRD.

It is especially important to be aware of this possible diagnosis in young patients who may develop premature renal dysfunction, need for renal replacement therapy (RRT), or severe chronic infections with risk factors for resistant bacteria that will become increasingly difficult to treat. Correction of the underlying anatomical defect is key. Proteinuria and focal and segmental sclerosis do occur with chronic reflux and correction of this defect can prevent future renal dysfunction.<sup>5</sup>

Figure 1



**Figure 1:** Imaging Findings in Case of Chronic Right Reflux and Atrophied Right Kidney

A) Coronal CT urogram scan showing an atrophied right kidney with fat stranding concerning for chronic infection.

B) Voiding-Cysto-Uretero-Gram (VCUG) confirming right renal vesicoureteral reflux.

## REFERENCES

1. **Dason S, Dason JT, Kapoor A.** Guidelines for the diagnosis and management of recurrent urinary tract infection in women. *Can Urol Assoc J.* 2011 Oct;5(5):316-22. doi: 10.5489/cuaj.11214. PubMed PMID: 22031610; PubMed Central PMCID: PMC3202002.
2. **Lee H, Lee YS, Im YJ, Han SW.** Vesicoureteral reflux and bladder dysfunction. *Transl Androl Urol.* 2012 Sep; 1(3):153-9. doi: 10.3978/j.issn.2223-4683.2012.06.09. Review. PubMed PMID: 26816705; PubMed Central PMCID: PMC4708245.
3. **Mattoo TK.** Vesicoureteral reflux and reflux nephropathy. *Adv Chronic Kidney Dis.* 2011 Sep;18(5):348-54. doi: 10.1053/j.ackd.2011.07.006. Review. PubMed PMID: 21896376; PubMed Central PMCID: PMC3169795.
4. **Li L, Parwani AV.** Xanthogranulomatous pyelonephritis. *Arch Pathol Lab Med.* 2011 May;135(5):671-4. doi: 10.1043/2009-0769-RSR.1. Review. PubMed PMID: 21526966.
5. **Matsuoka H, Oshima K, Sakamoto K, Taguchi T, Takebayashi S.** Renal pathology in patients with reflux nephropathy. The turning point in irreversible renal disease. *Eur Urol.* 1994;26(2):153-9. PubMed PMID: 7957472.

Submitted August 2, 2018