

UC Riverside

UC Riverside Previously Published Works

Title

Venous Thromboembolism in Metastatic Uterine Leiomyosarcoma: A Case Report and Review of the Literature

Permalink

<https://escholarship.org/uc/item/2k71f8qd>

Journal

Case Reports in Oncology, 16(1)

ISSN

1662-6575

Authors

Swisher, Austin R

Ornelas, Denise

Ornelas, Diana

et al.

Publication Date

2023

DOI

10.1159/000531761

Peer reviewed

Case Report

Venous Thromboembolism in Metastatic Uterine Leiomyosarcoma: A Case Report and Review of the Literature

Austin R. Swisher^a Denise Ornelas^a Diana Ornelas^a Golnaz Namazi^a
Bassam Theodory^a Akshit Chitkara^b Aditya Desai^b Prabhdeep Sethi^b

^aMinimally Invasive Gynecologic Surgery, University of California, Riverside, CA, USA;

^bDepartment of Internal Medicine, University of California, Riverside School of Medicine, Riverside, CA, USA

Keywords

Metastasis · Uterine · Leiomyosarcoma · Thrombosis · Embolism

Abstract

We report an unusual case of extensive deep vein thrombosis (DVT) and pulmonary embolism (PE) in the setting of metastatic uterine leiomyosarcoma. Recognition of the associated sequelae of this condition may improve short- and long-term outcomes. A 56-year-old black female with a history of uterine leiomyosarcoma diagnosed incidentally after total abdominal hysterectomy for fibroid uterus without initiation of chemoradiation treatment presented to the emergency department complaining of generalized weakness and progressively worsening stridor for 2 weeks. The patient was experiencing shortness of breath, dysphagia, and hoarseness. Physical exam was remarkable for rhonchi but was otherwise normal. Diagnostic imaging via CT of the abdomen, pelvis, and chest revealed DVTs of the left common and external iliac veins, the superior mesenteric artery, multiple pulmonary emboli of the right pulmonary artery, several nodular lesions within the lungs, and scattered peritoneal necrotic lesions, which were suspicious for metastatic disease. Additionally, CT of the neck showed an exophytic mass protruding into the airway from the subglottic region and thyromegaly with bilateral thyroid lobe nodules. The patient was subsequently started on Eliquis and chemotherapy. The rarity of this case is rooted in the extent of the patient's DVTs and PEs secondary to hypercoagulability in metastatic cancer. This presentation should be further evaluated to exclude thrombophilias or underlying malignancies. Drawing from the lessons of this case will help guide future clinical management regarding the care of metastatic uterine leiomyosarcoma.

© 2023 The Author(s).

Published by S. Karger AG, Basel

Presentation: Abstract was presented virtually at the European Congress of Internal Medicine 2022 Meeting in Malaga, Spain.

Correspondence to:
Austin R. Swisher, austin.swisher@medsch.ucr.edu

Introduction

Uterine leiomyosarcoma (LMS) is a rare uterine malignancy that arises from the myometrium of the uterine wall. LMS accounts for about 2% of uterine malignancies [1]. Black patients have a twofold higher incidence of LMS than white patients. LMS is a histologic diagnosis and is most often diagnosed after myomectomy or hysterectomy for presumed benign fibroids. When compared to other types of uterine cancers, LMS presents as an aggressive tumor and has a poor prognosis, with high rates of recurrence and mortality regardless of stage at presentation. The 5-year uterine LMS survival rate for overall and stage IV disease is estimated to be 66% and 29%, respectively. Risk factors associated with poor prognosis are higher tumor grade, advanced disease stage, and black race [2].

Up to 33% of patients with newly diagnosed uterine LMS present with distant metastatic disease, most commonly involving the lungs, liver, abdomen, and pelvis [3]. Women with advanced disease, like those with intra-abdominal involvement (stage III) or distant metastases (stage IV) who have undergone complete resection, have a higher risk of progression following surgery and are therefore offered chemotherapy and radiation. If hysterectomy is not an option in cases of metastatic disease, palliative care is recommended.

Cancer can lead to thrombotic complications due to a hypercoagulable state. In fact, thrombotic events are found to be the second leading cause of death in adult patients with cancer – second only to death from cancer itself [4]. From tumor type to resection magnitude, several risk factors play a role in the development of thrombotic events in patients with cancer, which usually present as deep vein thrombosis (DVT) or pulmonary embolism (PE). Anatomic factors can impact the hypercoagulable state accompanying cancer. For instance, some tumors may externally compress or directly invade large vessels, leading to an increased risk of venous thromboembolism (VTE). Patient-specific factors must also be considered as contributing to an increased risk, including prior history of VTE, advanced age, obesity, and genetic or acquired thrombophilias. Additionally, patients with gynecologic cancer, ages between 40 and 80 years, and metastatic disease have a greater risk of VTE compared to patients with other cancer subtypes and demographics [5]. Comorbidities such as diabetes, hypertension, and liver disease are also risk factors for thromboembolism in uterine cancer [6].

The patient in this case embodied several of the factors that increase the risk of VTE, including age 56, black race, female sex, comorbid hypertension and obesity, history of major surgery, and metastases at the time of diagnosis. To the authors' knowledge, the extent of our patient's widespread distribution of VTEs due to uterine LMS has not been described elsewhere in the literature. The CARE Checklist has been completed by the authors for this case report, attached as online supplementary material (for all online suppl. material, see <https://doi.org/10.1159/000531761>).

Case

A 56-year-old black female with a past medical history of obesity and uncontrolled hypertension presented to the ED with severe abdominal pain and abnormal uterine bleeding. On further evaluation, a pelvic ultrasound showed a 17-cm uterus with fibroids. She underwent hysteroscopy with dilation and curettage that showed a proliferative-appearing endometrium; no intraluminal lesions were seen. Tissue sampling results were negative. The patient underwent TAH with bilateral salpingectomy to treat uterine fibroids and relieve her symptoms. The operative pathology report revealed evidence of high-grade LMS. It exhibited marked nuclear atypia, up to 25 mitoses per 10 high-powered fields, and coagulative tumor

cell necrosis. Careful scrutiny revealed that the mass abutted soft tissue, including adipose tissue. The fact that this mass was received separately and that it abutted adipose tissue raises the possibility that it represented a broad ligament LMS. However, the staging was unclear as the patient was supposedly in denial about her diagnosis and lost to follow-up.

Six months later, the patient returned to the ED with similar complaints of abdominal pain. She was found to have a perforated viscus with sepsis and underwent exploratory laparotomy for perforation secondary to tumor invasion. Metastatic lesions into the fourth portion of the duodenum ultimately required small bowel resection and duodenectomy of the fourth and part of the third portion of the duodenum, as well as retroperitoneal debulking with multiple retroperitoneal small excisions and resection of an abdominal wall mass. The pathologic, histologic, and immunohistochemical findings from her surgeries supported the diagnosis of high-grade LMS in the small bowel and retroperitoneal space. During her hospital course, the patient complained of left arm pain. Ultrasound was negative for DVT but did show a superficial thrombus in the cephalic vein. Given this was superficial vein thrombosis, no anticoagulation was started. The patient was discharged with outpatient follow-up with hematology-oncology for systematic chemotherapy.

Two months later (a total of 8 months post-TAH), the patient presented to the ED with generalized weakness and progressively worsening stridor for several weeks. Upon evaluation, she endorsed bilateral weakness in her legs with the assistance of a wheelchair, intermittent non-exertional shortness of breath, nausea and vomiting, progressive dysphagia for solid food with swallowing of liquids only, and hoarseness. Physical examination revealed rhonchi on auscultation and the patient's inability to raise her lower extremities against gravity.

CT imaging of the abdomen and pelvis with intravenous contrast revealed a large filling defect within the left common iliac vein and left external iliac vein, compatible with positive DVT (Fig. 1). Several peritoneal metastatic necrotic nodules were noted, including a left pelvis nodule measuring 4.0 cm, a left upper midline pelvis nodule measuring 2.0 cm, and a cystic collection at the midline subcutaneous infraumbilical region measuring 5.0 by 3.0 cm. Lymph nodes in the abdominal region were evaluated for metastases, including several 0.8–1.6 cm left superficial inguinal lymph nodes and several small left para-aortic lymph nodes.

CT angiography of the chest revealed a large thrombus in the distal right main pulmonary artery extending into the base of the right upper lobe apical subsegment as well as the right lower lobe posterior and medial basilar subsegmental branches of the pulmonary artery. Additionally, several nodular lesions concerning for metastatic disease, including a left medial lower lobe nodule measuring 17.0 mm, a left lateral upper lobe nodule measuring 23.0 × 15.0 mm, and a subpleural nodule of the right lateral lung base measuring 4.0 mm, were discovered.

CT of the neck revealed a 1.4 × 1.2 × 1.2 cm exophytic mass protruding into the airway from the subglottic region (Fig. 2). Thyromegaly with bilateral thyroid lobe nodules was also found on imaging (Fig. 3). Esophagogram showed a patent esophagus.

After initiation of anticoagulation therapy in the ED, the patient was continued on enoxaparin therapy 1 mg/kg twice daily and discharged on apixaban 5 mg twice daily. Radiation oncology and ENT were consulted for further recommendations. Metastatic high-grade LMS was treated with doxorubicin/ifosfamide/mesna (AIM) therapy. Palliative radiation was considered in the setting of acute worsening of airway patency.

In our most recent encounter with the patient, we learned that she continues to experience a complicated disease course of confirmed metastatic LMS. Her nausea and vomiting due to chemotherapy led to a TPN requirement. The patient is currently on neoadjuvant AIM with plans for radiation therapy after ENT biopsy of the subglottic mass.

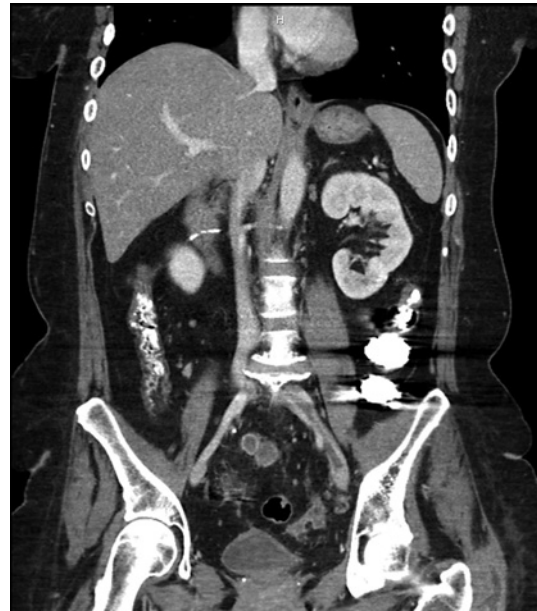

Fig. 1. DVT of the iliac vein. A large filling defect is shown within the left common iliac vein and left external iliac vein, compatible with DVT. An intraluminal filling defect is also noted within the superior mesenteric vein, also compatible with DVT.

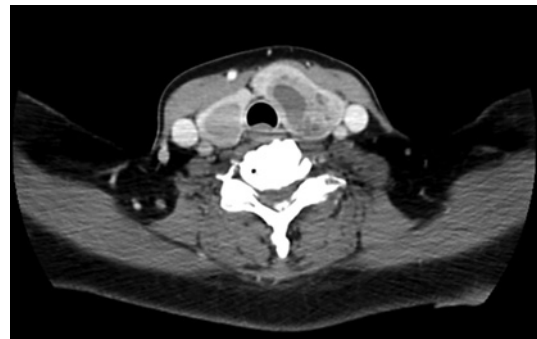


Fig. 2. Thyroid mass with patent esophagus. An exophytic mass protruding into the airway is identified in the subglottic region, suspicious for primary tumor.

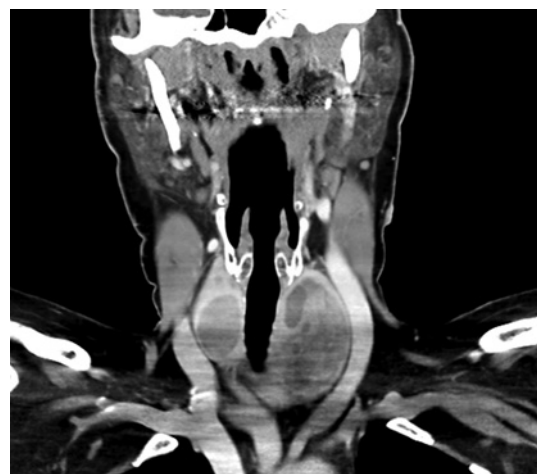


Fig. 3. Coronal view of thyroid mass.

Discussion

While DVT is a known risk in soft tissue sarcomas, the authors are not aware of any reports in the literature describing extensive VTE in patients with malignant uterine LMS. Tafur et al. [7] in a population-based study found that intra-abdominal VTE events were related to gastrointestinal cancers. Additionally, a study of East Asians explored the characteristics of thromboembolism and found pancreatic cancer to be most commonly associated with VTEs, reporting an incidence of 30 percent [8]. When analyzing the anatomical sites of these VTEs, the majority were incidental intra-abdominal rather than symptomatic VTEs. Another study by Lee et al. [9] revealed that VTEs presenting as extremity and pulmonary thromboembolism were more likely to occur during the chemotherapy period, whereas intra-abdominal VTEs occurred more frequently during treatment-refractory periods. This is consistent with our patient's case, as her intra-abdominal DVTs were found incidentally on imaging post-TAH but before consulting oncology for chemotherapy. Together, these studies suggest that gastrointestinal cancers are more likely to present with VTE and support the infrequent nature of our patient's case presentation with extensive intra-abdominal DVTs and PEs due to metastatic uterine LMS.

The development of DVT and PE is relatively common in adult patients with cancer. However, given the paucity of literature regarding the manifestation of DVT and PE in patients with metastatic uterine LMS, it is worth comparing it to another cancer subtype with similar demographic and anatomic characteristics. The closest diagnostic and prognostic parallel to our patient's case is ovarian cancer, for which thromboembolic events are also common. Wagner et al. [10] in a large cohort of 860 ovarian cancer patients found the cumulative incidence of VTE was 7.5% by 30 days and 13.8% by 6 months following surgery. Several other studies corroborate these findings, with VTEs found in up to 26.8% of patients undergoing neoadjuvant chemotherapy (and nearly half of these diagnosed during chemotherapy cycles before interval debulking surgery) [11, 12].

Our patient's risk factors for thromboembolism – being of female sex between the ages of 40–80, a history of hypertension and obese body habitus, her status post-TAH and debulking surgery with a prolonged and complicated post-operative hospital course, immobilization, and presentation with metastatic disease – led to a relatively rare diagnosis. Indeed, various studies have found that LMS of vascular origin can sometimes be mistaken for DVTs and PEs due to their similar clinical presentations and radiographic appearance. LMS can present as an intravenous tumor of the deep veins. Although vascular LMS is rare, accounting for less than 2% of all LMSs, limited case reports do exist [13–16]. Most vascular LMS cases are located in the iliac vein, as was observed in our patient [17]. LMS of pulmonary vascular origin was also considered in the differential diagnosis; however, only two such cases have been reported in the literature [17–19].

Clinical presentation and radiography are unable to distinguish between a VTE and LMS of vascular origin. Rather, excisional biopsy and histological examination of the thrombus are used to confirm the diagnosis [19]. However, there is a concern for delayed diagnosis of soft tissue sarcomas because they can be masked as VTEs. This necessitates the consideration of associated tumors when evaluating a patient for suspected DVT or PE [20]. Clinicians must also consider atypical findings, such as a patient's D-dimer level remaining low despite a hypercoagulable state. Thus, when cancer patients present with multiple VTEs, a D-dimer level should be ordered to rule out the possibility of LMS of vascular origin.

Our patient was ultimately diagnosed with DVT and PE secondary to metastatic uterine LMS. Not only is our patient a rare case of uterine LMS with uncommon metastasis to the thyroid, but she may also represent a case of LMS metastasis to the iliac and pulmonary vessels. Due to our patient's extensive metastasis and widespread VTEs, it is worth

investigating whether such findings may actually be metastatic LMS of vascular origin. Regardless, the distribution of VTEs in this patient could be used as a prognostic marker or to predict more aggressive tumor behavior (e.g., thyroid metastasis).

Conclusion

Early identification and treatment of metastatic disease for patients with LMS is crucial. There are no guidelines regarding prophylactic anticoagulation for patients with uterine LMS. However, as delineated in this case report, patients with an elevated risk profile should be screened and potentially placed on thromboembolism prophylaxis.

Acknowledgments

Contributing author Prabhdeep Sethi was not available to confirm co-authorship, but the corresponding author, Austin Swisher, affirms that Dr. Sethi contributed to the paper, had the opportunity to review the final version to be published, and guarantees Prabhdeep Sethi's co-authorship status and the accuracy of the author contribution and conflict of interest statements.

Statement of Ethics

Written informed consent was obtained from the patient for the publication of this case report and accompanying images. This study protocol was reviewed, and the need for approval was waived by the University of California, Riverside Institutional Review Board.

Conflict of Interest Statement

The authors declare that they have no conflicts of interest.

Funding Sources

No funds, grants, or other support were received.

Author Contributions

A.R.S., Denise O., Diana O., B.T., A.C., A.D., G.N., and P.S. worked collaboratively to analyze and interpret the case history, document the relevant facts, review the literature, and write the manuscript. P.S. conceived the original idea for the article. All authors read and approved the final manuscript.

Data Availability Statement

All data generated or analyzed during this study are included in this article and its online supplementary material. Further inquiries can be directed to the corresponding author.

References

- 1 Hensley ML, Blessing JA, Degeest K, Abulafia O, Rose PG, Homesley HD. Fixed-dose rate gemcitabine plus docetaxel as second-line therapy for metastatic uterine leiomyosarcoma: a Gynecologic Oncology Group phase II study. *Gynecol Oncol*. 2008;109(3):323–8.
- 2 Kapp DS, Shin JY, Chan JK. Prognostic factors and survival in 1,396 patients with uterine leiomyosarcomas: emphasis on impact of lymphadenectomy and oophorectomy. *Cancer*. 2008;112(4):820–30.
- 3 Goff BA, Rice LW, Fleischhacker D, Muntz HG, Falkenberry SS, Nikrui N, et al. Uterine leiomyosarcoma and endometrial stromal sarcoma: lymph node metastases and sites of recurrence. *Gynecol Oncol*. 1993;50(1):105–9.
- 4 Khorana AA, Francis CW, Culakova E, Kuderer NM, Lyman GH. Thromboembolism is a leading cause of death in cancer patients receiving outpatient chemotherapy. *J Thromb Haemost*. 2007;5(3):632–4.
- 5 Merkow RP, Bilimoria KY, McCarter MD, Cohen ME, Barnett CC, Raval MV, et al. Post-discharge venous thromboembolism after cancer surgery: extending the case for extended prophylaxis. *Ann Surg*. 2011;254(1):131–7.
- 6 Rodriguez AO, Gonik AM, Zhou H, Leiserowitz GS, White RH. Venous thromboembolism in uterine cancer. *Int J Gynecol Cancer*. 2011;21(5):870–6.
- 7 Tafur AJ, Kalsi H, Wysokinski WE, McBane RD, Ashrani AA, Marks RS, et al. The association of active cancer with venous thromboembolism location: a population-based study. *Mayo Clin Proc*. 2011;86(1):25–30.
- 8 Lee JC, Ro YS, Cho J, Park Y, Lee JH, Hwang JH, et al. Characteristics of venous thromboembolism in pancreatic adenocarcinoma in East Asian ethnics: a large population-based observational study. *Medicine*. 2016;95(17):e3472.
- 9 Lee KW, Bang SM, Kim S, Lee HJ, Shin DY, Koh Y, et al. The incidence, risk factors and prognostic implications of venous thromboembolism in patients with gastric cancer. *J Thromb Haemost*. 2010;8(3):540–7.
- 10 Wagner BE, Langstraat CL, McGree ME, Weaver AL, Sarangi S, Mokri B, et al. Beyond prophylaxis: extended risk of venous thromboembolism following primary debulking surgery for ovarian cancer. *Gynecol Oncol*. 2019;152(2):286–92.
- 11 Li S, Bercow AS, Falzone M, Kalyanaraman R, Worley MJ, Feltmate CM, et al. Risk of venous thromboembolism for ovarian cancer patients during first-line therapy after implementation of an Enhanced Recovery After Surgery (ERAS) protocol. *Gynecol Oncol*. 2021;162(2):353–9.
- 12 Greco PS, Bazzi AA, McLean K, Reynolds RK, Spencer RJ, Johnston CM, et al. Incidence and timing of thromboembolic events in patients with ovarian cancer undergoing neoadjuvant chemotherapy. *Obstet Gynecol*. 2017;129(6):979–85.
- 13 Rojas Sayol R, Trullols Tarragó L, Grau Blanes A, Martínez Zaragoza J, Britez Altamirano E, Peiró Ibañez A, et al. Leiomyosarcomas affecting main vessels in the lower extremities. *Rev Esp Cir Ortop Traumatol*. 2018;62(6):401–7.
- 14 Tripodi E, Zanfagnin V, Fava C, Zola P, Ferrero A. Leiomyosarcoma of the right iliac veins presenting as a pelvic mass: a case report. *Obstet Gynecol Cases Rev*. 2015;2:40–4.
- 15 Ozluk E, Wei EX, Cotelingam J, Shackelford RE. Primary pulmonary leiomyosarcoma in a forty-year-old woman. *Case Rep Oncol*. 2021;14(3):1333–6.
- 16 Sahu R, Aggarwal R, Kumar P, Mittal S, Sood V, Sarin J. Primary external iliac vein leiomyosarcoma. *Ann Vasc Surg*. 2019;57:274.e5–9.
- 17 Kado S, Goto M, Yamao H, Tsukada T, Sato M, Uekusa Y. Pulmonary embolism caused by intravenous leiomyosarcoma of the lower limb. *Intern Med*. 2018;57(10):1425–8.
- 18 Xie X, Chen Y, Ding C, Yu X, Zou L, Xu B, et al. Primary pulmonary leiomyosarcoma: a case report. *Oncol Lett*. 2016;11(3):1807–10.
- 19 Perisano C, Maffulli N, Colelli P, Marzetti E, Panni AS, Maccauro G. Misdiagnosis of soft tissue sarcomas of the lower limb associated with deep venous thrombosis: report of 2 cases and review of the literature. *BMC Musculoskelet Disord*. 2013;14:64.
- 20 Bennis M, Dalsing M, Sawchuck A, Wurtz LD. Soft tissue sarcomas may present with deep vein thrombosis. *J Vasc Surg*. 2006;43(4):788–93.