

# UC Davis

## UC Davis Previously Published Works

### Title

Comparison of 2-Octylcyanoacrylate Versus 5-0 Fast-Absorbing Gut During Linear Wound Closures and the Effect on Wound Cosmesis.

### Permalink

<https://escholarship.org/uc/item/2j59z40v>

### Journal

Dermatologic Surgery, 46(5)

### ISSN

1076-0512

### Authors

Zhuang, Anne R  
Beroukhim, Kouros  
Armstrong, April W  
[et al.](#)

### Publication Date

2020-05-01

### DOI

10.1097/dss.0000000000002076

Peer reviewed

# Comparison of 2-Octylcyanoacrylate Versus 5-0 Fast-Absorbing Gut During Linear Wound Closures and the Effect on Wound Cosmesis

ANNE R. ZHUANG, MD,\*† KOUROSH BEROUKHIM, MD,\* APRIL W. ARMSTRONG, MD, MPH,‡  
RAJA K. SIVAMANI, MD, MS, AP,\* AND DANIEL B. EISEN, MD\*

**BACKGROUND** Although the use of 2-octylcyanoacrylate (OCA) in cutaneous surgery offers increased efficiency, there is scant data comparing scar outcomes achieved with OCA versus 5-0 fast-absorbing gut suture (FG).

**OBJECTIVE** To compare scar cosmesis achieved with OCA versus FG for surgical wound closure.

**MATERIALS AND METHODS** A total of 44 patients with postoperative defects of at least 3 cm were included. Half of each wound was randomized to receive closure with either OCA or FG. At 3 months, patients and 2 blinded observers evaluated each scar using the Patient and Observer Scar Assessment Scale (POSAS).

**RESULTS** The total observer POSAS score (mean [SD]) for the side repaired with OCA (12.3 [4.72]) and the side that received FG (11.6 [4.36]) did not differ significantly ( $p = .40$ ). There was no significant difference in the total patient POSAS scores between closure with OCA (14.9 [8.67]) and FG (14.6 [8.90]) ( $p = .70$ ). Based on observer POSAS scores, scar pigmentation was significantly worse on the scar half repaired with OCA (1.98 [0.91]) compared with FG (1.79 [0.80]) ( $p = .05$ ).

**CONCLUSION** With the exception of inferior scar pigmentation with OCA, there was no statistically significant difference in wound cosmesis after linear wound closure with OCA versus FG.

*Supported by the National Center for Advancing Translational Sciences (NCATS), National Institutes of Health (NIH), through grant UL1 TR000002, which funded the REDCap database used for management of the study's data. The study was otherwise supported by the Department of Dermatology, University of California, Davis. The authors have indicated no significant interest with commercial supporters. Trial registration: ClinicalTrials.gov Identifier NCT02547077, <https://clinicaltrials.gov/ct2/show/NCT02547077>.*

Two-Octylcyanoacrylate (OCA) is a medical-grade tissue adhesive that was initially used as an alternative to sutures for superficial lacerations.<sup>1-6</sup> It polymerizes upon contact with tissue and forms a flexible film that maintains apposition of wound edges while providing tensile strength.<sup>7,8</sup> Tissue adhesives have several purported advantages to conventional sutures, as they can improve efficiency during surgical wound closure, obviate the need for suture removal, and provide a protective barrier that may impede wound infection.<sup>9</sup> More recently, cyanoacrylate tissue

adhesives have been used for more extensive incisional repairs on the head and neck, with comparable cosmetic results when compared with standard methods.<sup>10,11</sup>

Despite its increasing popularity in repair of surgical wounds and lacerations, the use of OCA or other tissue adhesives in dermatologic surgery remains limited. The few randomized controlled trials (RCTs) investigating the use of tissue adhesives in linear closure of Mohs or dermatologic surgical excision defects have

\*Department of Dermatology, University of California, Davis, School of Medicine, Sacramento, California; †Laser and Skin Surgery Center of Northern California, Sacramento, California; ‡Department of Dermatology, Keck School of Medicine at University of Southern California, Los Angeles, California

© 2019 by the American Society for Dermatologic Surgery, Inc. Published by Wolters Kluwer Health, Inc. All rights reserved.  
ISSN: 1076-0512 • Dermatol Surg 2019;00:1-7 • DOI: 10.1097/DSS.0000000000002076

mixed results and are limited in their sample sizes.<sup>12–15</sup> Thus, larger studies are required to better delineate the use of OCA and its outcomes in cutaneous surgery. In this study, we used a split-wound/split-scar model to determine whether the use of OCA during primary closure of cutaneous surgical wounds improves scar cosmesis compared with wound closure with 5-0 fast-absorbing gut (FG).

## Methods

### Study Design

This is a prospective, single-center, evaluator-blinded, randomized split-scar comparison trial conducted between August 2015 and December 2015. This study was approved by the University of California, Davis Institutional Review Board (ClinicalTrials.gov Identifier: NCT02547077). All patients provided written informed consent before enrollment.

### Power Analysis and Randomization

We enrolled 50 patients into our study to detect a difference of 3 points on the 60-point Patient and Observer Scar Assessment Scale (POSAS) using an alpha of 0.05, 90% power, SD of 6, and dropout rate of 15%.

Study data were collected and managed using REDCap (Research Electronic Data Capture) electronic data capture tools hosted at University of California Davis Medical Center.<sup>16</sup> REDCap is a secure, web-based application designed to support data capture for research studies, providing (1) an intuitive interface for validated data entry, (2) audit trails for tracking data manipulation and export procedures, (3) automated export procedures for seamless data downloads to common statistical packages, and (4) procedures for importing data from external sources. A randomization list was generated before study recruitment from a freely available web service (<https://www.random.org/>). A nurse not involved in the study uploaded the table onto the randomization module of REDCap.

After subcuticular closure of each surgical wound, a nurse requested the allocation assignment from REDCap. The instructed intervention was then per-

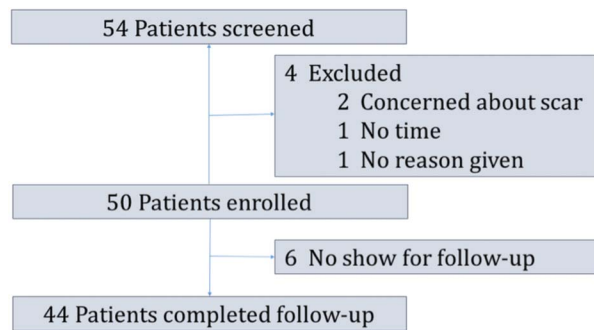
formed to the appropriate side of the wound by a surgeon not involved in the 3-month scar assessment. The allocation sequence-recording page remained separate from the other aspects of the study on REDCap to maintain concealment.

### Patients

Patients were enrolled if they were 18 years of age or older, had a projected scar length of at least 3 cm resulting from either Mohs micrographic surgery or surgical excision, were able to provide informed consent, and were willing to return for a follow-up visit. Exclusion criteria included pregnancy, incarceration, mental impairment, inability to understand English, and nonlinear closures. Postoperative defects were not limited to an anatomical location, and surgeons of different experience levels (residents, fellows, and attending physicians) participated in the surgical repairs to improve external validity.

### Interventions

Half of the wound was labeled as “A” and the other half as “B.” By convention, side A was always superior or on the left side of the wound, from the surgeon’s perspective. Side A was then randomized to receive closure with either 2-octylcyanoacrylate (Dermabond Mini Topical Skin Adhesive, Ethicon, Inc., Somerville, NJ) or 5-0 fast-absorbing plain gut (Ethicon, Inc.) in a simple running suture. Side B received the other intervention. To approximate the wound, a single subcuticular polyglactin 910 suture was used at the midpoint of the wound. More sutures were placed equidistant from the midpoint of the wound on both sides such that each side of the wound had the same number of buried subcuticular sutures. In general, this resulted in at least one buried vertical mattress suture placed every 2 centimeters along the course of the wound. After placement of subcuticular sutures, the wound edges were manually pushed together.<sup>17</sup> All blood and other liquids were removed from the wound edges with a sterile 4” × 4” cotton sponge pad. A thin layer of OCA was then applied to the top of the designated wound half and allowed to dry, with care taken to keep OCA out of the wound bed. Two or 3 more applications were similarly applied until the vial was exhausted. Petroleum jelly ointment was applied



**Figure 1.** CONSORT diagram. Screening, enrollment, and follow-up of study patients.

only to the wound half treated with sutures, and a pressure bandage was applied to the entire wound. Patients were asked to leave the pressure bandage on for 24 hours. Thereafter, they were instructed to apply petroleum jelly only to the sutured half, but not to the side treated with OCA, twice daily for 1 week with a cotton-tipped applicator.

### Assessments

The primary outcome of scar cosmesis was performed at 3 months postoperatively, with an acceptable window of 1 month before or after the assessment period. A 3-month follow-up interval was selected to minimize patient dropout and provide an appropriate postoperative period to perform scar evaluation. Previous data indicate a good correlation between 3- and 12-month postoperative outcomes.<sup>18</sup> Because an intention-to-treat approach was used, there was no shorter-term follow-up (i.e., 5–10 days postoperatively) to assess whether the applied OCA remained intact. Secondary outcomes included scar width 1 cm from the midpoint of the scar for both halves, as well as the incidence of hematomas, suture abscesses, seromas, necrosis, or dehiscence.

For the primary end point, the patient and 2 blinded dermatologists who were not present during the intervention evaluated the scar using the validated POSAS scar assessment instrument.<sup>19</sup> The POSAS consists of separate assessment surveys for the blinded observer and the patient, where criteria (observer = vascularity, pigmentation, thickness, relief, pliability, surface area, and overall opinion; patient = color, stiffness, thickness, irregularity, and overall opinion)

are graded on a 10-point scoring system. A score of 1 represents normal-appearing skin and 10 represents the worst scar imaginable.<sup>20</sup> Total scores may range from 6 to 60, with lower scores representative of normal-appearing skin. The primary outcome measure was the mean of the sum of the observer scores.

### Statistical Analysis

Pairwise comparisons were used to analyze the differences between the use of OCA versus simple running FG in surgical complications, investigator scar assessment, and patient scar assessment. Wilcoxon matched-pairs signed-rank test was used to determine the equality of matched pairs of observations for binary surgical outcome variables. For continuous outcomes of investigator scar assessment and patient scar assessment, a paired *t*-test was used to compare differences between OCA versus FG. Results achieving  $p < .05$  (2-tailed) were considered statistically significant. Primary analyses used an intention-to-treat approach, and thus, sensitivity analysis was not performed. Statistical analyses were conducted using STATA/MP, version 13 (StataCorp LP) or R statistical computing software (R Foundation for Statistical Computing, Vienna, Austria).

### Results

A total of 54 patients were screened for this study at the University of California, Davis Department of Dermatology between August 2015 and December 2015 (Figure 1). Four patients were excluded, and 50 patients were enrolled. The majority of enrolled patients were white men (74%), with an average age of 64.5 years (Table 1). Thirty-eight patients (76%) were enrolled at the time of a Mohs procedure and the remainder (12 patients, 24%) at the time of a standard excision. Surgeons of various training levels performed surgical repairs, with 46% of cases repaired by the Mohs fellow. Most cases were located on the head and neck ( $n = 35$ , 70%), followed by the trunk ( $n = 8$ , 16%) and the extremities ( $n = 7$ , 14%). The average length of repair was 5.87 cm (SD = 2.14).

Forty-four patients (88%) completed the 3-month follow-up visit, with a mean assessment time of

**TABLE 1. Baseline Characteristics of Study Population and Surgical Procedure Data**

Characteristic	Value*
Age, mean (SD), y	64.5 (13)
Male sex, n (%)	37 (74)
Race, n (%)	
White	50 (100)
Other	0
Training level of surgeon, n (%)	
Faculty	14 (28)
Mohs fellow	23 (46)
Resident	13 (26)
Anatomical location, n (%)	
Cheek	6 (12)
Temple	5 (10)
Forehead	3 (6)
Preauricular	4 (8)
Postauricular	9 (18)
Neck	4 (8)
Scalp	2 (4)
Lip	1 (2)
Chin	1 (2)
Arm	6 (12)
Leg	1 (2)
Chest	4 (8)
Back	4 (8)
Indication, n (%)	
Mohs	38 (76)
Standard excision	12 (24)
Assessment time, mean (SD), m	3.18 (0.36)
Excision length, mean (SD), cm	5.87 (2.14)

\*Data are given as number (percentage) unless otherwise noted.

3.14 months (SD = 0.36). Scar pigmentation was significantly worse on the scar half repaired with OCA ( $p = .05$ ), as evidenced by mean POSAS scores from blinded observers (Table 2). However, there was no significant difference in mean POSAS scores from blinded observers between the side treated with OCA and that treated with FG in any other outcome measures—vascularity, thickness, relief, pliability, surface area, overall opinion, and sum of components. Similarly, no statistically significant difference was seen in mean patient POSAS scores for pain, itching, color, stiffness, thickness, irregularity, overall opinion, and sum of components between the 2 scar halves (Figures 2A,B).

The scar was wider on the side treated with FG (2.12 mm, SD = 2.35) compared with OCA (1.97 mm,

SD = 1.85), although this was not statistically significant. The total number of complications was significantly increased on the scar side treated with OCA ( $p = .01$ ) compared with the scar half repaired with FG. Most complications were attributable to wound dehiscence, which occurred 7 times on the OCA side and twice on the FG side. Notably, many cases of wound dehiscence occurred in wounds located on the trunk or extremities. Two cases of hematoma and 1 case of wound infection also occurred, affecting both sides of the wounds equally.

## Discussion

This randomized clinical trial demonstrated no statistically significant differences in scar cosmesis after closure with OCA compared with FG, with the exception of scar pigmentation, which was significantly more noticeable on the side treated with OCA. This difference may be explained by increased surface wound tension on the scar side treated with the dermal adhesive, leading to dyspigmentation in a mechanism similar to formation of striae distensae.<sup>21</sup> Although not statistically significant, scars treated with OCA trended toward being narrower than those repaired with FG. Postoperative complications, including wound dehiscence, were more commonly seen on the scar half treated with OCA.

A search of the MEDLINE database revealed 4 RCTs and 1 nonrandomized study that compared wound closure with OCA versus sutures in dermatologic surgery. One RCT found scar dyspigmentation to be significantly worse on the wound half treated with OCA, consistent with our results.<sup>12</sup> The remaining 3 RCTs found no statistically significant differences between OCA and sutures in terms of overall scar cosmesis.<sup>13–15</sup> In contrast to our study, these trials used a 10-point visual analog scale, which provides only an overall scar assessment rather than distinguishing individual scar characteristics as in the POSAS. In addition, scar assessments in these studies were performed by means of digital photography, which may limit the ability to distinguish minor cosmetic differences between scars compared with live examination. A

**TABLE 2. Scar Width, Observer and Patient POSAS Scores, and Complications at 3-Month Follow-up**

<i>Outcome Measure</i>	<i>OCA</i>	<i>Fast-Absorbing Gut</i>	<i>p-Value</i>
Evaluable patients, <i>n</i> (%)	44 (88)	44 (88)	—
Scar width, mean (SD), mm	1.97 (1.85)	2.12 (2.35)	.44
Observer POSAS score, mean (SD)			
Vascularity	2.39 (1.37)	2.22 (1.33)	.38
Pigmentation	1.98 (0.91)	1.79 (0.80)	<b>.05</b>
Thickness	1.75 (1.00)	1.73 (0.95)	.89
Relief	1.87 (0.81)	1.73 (0.73)	.35
Pliability	1.92 (0.91)	1.84 (0.85)	.64
Surface area	2.4 (1.28)	2.31 (1.51)	.67
Overall opinion	2.5 (1.28)	2.26 (1.37)	.29
Sum of components	12.3 (4.72)	11.6 (4.36)	.4
Patient POSAS score, mean (SD)			
Pain	1.32 (1.29)	1.32 (1.29)	—
Itching	1.48 (1.37)	1.27 (0.79)	.29
Color	4.07 (2.71)	4.14 (2.68)	.85
Stiffness	2.91 (2.21)	2.59 (2.29)	.28
Thickness	2.48 (1.81)	2.41 (2.01)	.81
Irregularity	3.02 (3.17)	3.16 (2.71)	.67
Overall opinion	3.45 (2.34)	3.43 (2.36)	.73
Sum of components	14.9 (8.67)	14.6 (8.90)	.7
Complications, <i>n</i>			
Dehiscence	7	2	<b>.02</b>
Suture abscess	2	1	.32
Hematoma	2	2	—
Infection	1	1	—
Total (incidence, %)	12 (27)	6 (14)	<b>.01</b>

Bold indicates statistically significant outcomes.

OCA, 2-octylcyanoacrylate; POSAS, Physician and Observer Scar Assessment Scale.

nonrandomized study found the use of sutures to be cosmetically superior to OCA.<sup>22</sup> However, the nonrandomized, non-split-scar design of the study raises questions about the validity of the comparison.

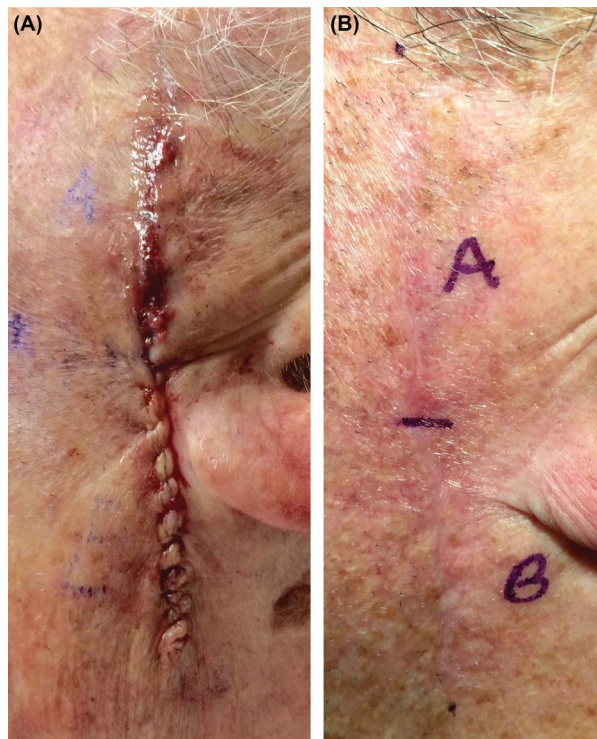
Our findings are consistent with studies from the nondermatologic literature that have compared scar outcomes and complication rates between wounds repaired with OCA and those repaired with sutures. A large, multicenter trial randomized 924 wounds to repair either with OCA or standard closure methods and found the cosmetic outcomes to be similar between the 2 treatment arms.<sup>23</sup> Similarly, several recent trials have demonstrated that wound closure with OCA offers comparable scar cosmesis compared to repair with sutures.<sup>24–29</sup> In accord with our results, a 2014 Cochrane review

and meta-analysis found that wound closure with tissue adhesives resulted in significantly more episodes of wound dehiscence than sutures.<sup>30</sup>

Strengths of this study include its use of a validated scar assessment tool by blinded observers, a priori data analysis, and larger sample size relative to similar published studies. In addition, the split-wound model negates confounders such as location, sex, age, and wound tension because each side is exposed to similar intrinsic and extrinsic factors, making differences in outcomes much more likely to be due to the study intervention.

Our study does have limitations. OCA can be removed and rendered ineffective by exposure to ointment.<sup>31</sup> Thus, petroleum jelly ointment was applied only to the sutured half of the wound after surgery, and patients





**Figure 2.** (A and B) Postoperative wound and surgical scar. (A) Immediate postoperative wound. (B) Surgical scar at 3-month follow-up. Two-Octylcyanoacrylate applied to side A of this wound (sum POSAS score = 7); fast-absorbing gut used to repair side B (sum POSAS score = 9). POSAS, Patient and Observer Scar Assessment Scale.

were instructed to do the same during dressing changes. However, we cannot rule out the possibility that some ointments may have leached over to the side treated with OCA during occlusion of the wound, contributing to the higher level of superficial dehiscence observed on that side. This is a single-center study with a homogeneous patient population, and thus the results may not be generalizable across a diverse patient base. Furthermore, most of our wounds were on the head and neck. Other sites may heal differently.

## Conclusion

With the exception of inferior scar pigmentation with OCA, there was no statistically significant difference in wound cosmesis after linear wound closure with OCA versus FG. Therefore, surgeons may consider OCA as a comparable and potentially more efficient option for closure of Mohs or dermatologic surgical excision defects.

**Acknowledgments** The authors thank Dr. Victoria Sharon and Dr. Baran Ho for their contributions to this study.

## References

1. Quinn J, Wells G, Sutcliffe T, Jarmuske M, et al. A randomized trial comparing octylcyanoacrylate tissue adhesive and sutures in the management of lacerations. *JAMA* 1997;277:1527–30.
2. Singer AJ, Hollander JE, Valentine SM, Turque TW, et al. Prospective, randomized, controlled trial of tissue adhesive (2-octylcyanoacrylate) vs standard wound closure techniques for laceration repair: Stony Brook Octylcyanoacrylate Study Group. *Acad Emerg Med* 1998;5:94–9.
3. Saxena AK, Willital GH. Octylcyanoacrylate tissue adhesive in the repair of pediatric extremity lacerations. *Am Surg* 1999;65:470–2.
4. Resch KL, Hick JL. Preliminary experience with 2-octylcyanoacrylate in a pediatric emergency department. *Pediatr Emerg Care* 2000;16:328–31.
5. Bruns TB, Robinson BS, Smith RJ, Kile DL, et al. A new tissue adhesive for laceration repair in children. *J Pediatr* 1998;132:1067–70.
6. Osmond MH, Quinn JV, Sutcliffe T, Jarmuske M, et al. A randomized, clinical trial comparing butylcyanoacrylate with octylcyanoacrylate in the management of selected pediatric facial lacerations. *Acad Emerg Med* 1999;6:171–7.
7. Bhende S, Rothenburger S, Spangler DJ, Dito M. In vitro assessment of microbial barrier properties of Dermabond topical skin adhesive. *Surg Infect (Larchmt)* 2002;3:251–7.
8. Singer AJ, Thode HC Jr. A review of the literature on octylcyanoacrylate tissue adhesive. *Am J Surg* 2004;187:238–48.
9. Chow A, Marshall H, Zacharakis E, Paraskeva P, et al. Use of tissue glue for surgical incision closure: a systematic review and meta-analysis of randomized controlled trials. *J Am Coll Surg* 2010;211:114–25.
10. Maw JL, Quinn JV, Wells GA, Ducic Y, et al. A prospective comparison of octylcyanoacrylate tissue adhesive and suture for the closure of head and neck incisions. *J Otolaryngol* 1997;26:26–30.
11. Toriumi DM, O'Grady K, Desai D, Bagal A. Use of octyl-2-cyanoacrylate for skin closure in facial plastic surgery. *Plast Reconstr Surg* 1998;102:2209–19.
12. Tierney EP, Moy RL, Kouba DJ. Rapid absorbing gut suture versus 2-octylethylcyanoacrylate tissue adhesive in the epidermal closure of linear repairs. *J Drugs Dermatol* 2009;8:115–9.
13. Sniezek PJ, Walling HW, DeBloom JR III, Messingham MJ, et al. A randomized controlled trial of high-viscosity 2-octyl cyanoacrylate tissue adhesive versus sutures in repairing facial wounds following Mohs micrographic surgery. *Dermatol Surg* 2007;33:966–71.
14. Kim J, Singh Maan H, Cool AJ, Hanlon AM, et al. Fast absorbing gut suture versus cyanoacrylate tissue adhesive in the epidermal closure of linear repairs following Mohs micrographic surgery. *J Clin Aesthet Dermatol* 2015;8:24–9.
15. Bartenstein DW, Cummins DL, Rogers GS. A prospective, randomized, single-blind study comparing cyanoacrylate adhesives to sutures for wound closure in skin cancer patients. *Dermatol Surg* 2017;43:1371–8.
16. Harris PA, Taylor R, Thielke R, Payne J, et al. Research electronic data capture (REDCap)—a metadata-driven methodology and workflow process for providing translational research informatics support. *J Biomed Inform* 2009;42:377–81.
17. Zitelli JA, Moy RL. Buried vertical mattress suture. *J Dermatol Surg Oncol* 1989;15:17–9.

18. Quinn J, Wells G, Sutcliffe T, Jarmuske M, et al. Tissue adhesive versus suture wound repair at 1 year: randomized clinical trial correlating early, 3-month, and 1-year cosmetic outcome. *Ann Emerg Med* 1998; 32:645–9.
19. van der Wal MB, Tuinebreijer WE, Bloemen MC, Verhaegen PD, et al. Rasch analysis of the Patient and Observer Scar Assessment Scale (POSAS) in burn scars. *Qual Life Res* 2012;21:13–23.
20. Draaijers LJ, Tempelman FR, Botman YA, Tuinebreijer WE, et al. The patient and observer scar assessment scale: a reliable and feasible tool for scar evaluation. *Plast Reconstr Surg* 2004;113:1960–5; discussion 66–7.
21. Al-Himdani S, Ud-Din S, Gilmore S, Bayat A. Striae distensae: a comprehensive review and evidence-based evaluation of prophylaxis and treatment. *Br J Dermatol* 2014;170:527–47.
22. Bernard L, Doyle J, Friedlander SF, Eichenfield LF, et al. A prospective comparison of octyl cyanoacrylate tissue adhesive (dermabond) and suture for the closure of excisional wounds in children and adolescents. *Arch Dermatol* 2001;137:1177–80.
23. Singer AJ, Quinn JV, Clark RE, Hollander JE, et al. Closure of lacerations and incisions with octylcyanoacrylate: a multicenter randomized controlled trial. *Surgery* 2002;131:270–6.
24. Buchweitz O, Frye C, Moeller CP, Nugent W, et al. Cosmetic outcome of skin adhesives versus transcutaneous sutures in laparoscopic port-site wounds: a prospective randomized controlled trial. *Surg Endosc* 2016;30:2326–31.
25. Chen CT, Choi CL, Suen DT, Kwong A. A prospective randomised controlled trial of octylcyanoacrylate tissue adhesive and standard suture for wound closure following breast surgery. *Hong Kong Med J* 2016;22:216–22.
26. Daykan Y, Sharon-Weiner M, Pasternak Y, Tzadikvitch-Geffen K, et al. Skin closure at cesarean delivery, glue vs subcuticular sutures: a randomized controlled trial. *Am J Obstet Gynecol* 2017;216:406.e1–e5.
27. Koonce SL, Eck DL, Shaddix KK, Perdakis G. A prospective randomized controlled trial comparing N-butyl-2 cyanoacrylate (Histoacryl), octyl cyanoacrylate (Dermabond), and subcuticular suture for closure of surgical incisions. *Ann Plast Surg* 2015;74: 107–10.
28. Lee JC, Ishtihar S, Means JJ, Wu J, et al. In search of an ideal closure method: a randomized, controlled trial of octyl-2-cyanoacrylate and adhesive mesh versus subcuticular suture in reduction mammoplasty. *Plast Reconstr Surg* 2018;142:850–6.
29. Martin JG, Hollenbeck ST, Janas G, Makar RA, et al. Randomized controlled trial of octyl cyanoacrylate skin adhesive versus subcuticular suture for skin closure after implantable venous port placement. *J Vasc Interv Radiol* 2017;28:111–6.
30. Dumville JC, Coulthard P, Worthington HV, Riley P, et al. Tissue adhesives for closure of surgical incisions. *Cochrane Database Syst Rev* 2014:CD004287.
31. Singer AJ, Quinn JV, Hollander JE. The cyanoacrylate topical skin adhesives. *Am J Emerg Med* 2008;26:490–6.

---

Address correspondence and reprint requests to: Daniel B. Eisen, MD, Department of Dermatology, University of California, Davis, School of Medicine, 3301 C St, Suite 1400, Sacramento, CA 95816, or e-mail: deisen123@gmail.com