

# UC Irvine

## UC Irvine Previously Published Works

### Title

Full-thickness skin grafts for neovaginal construction in Mayer-Rokitansky-Kuster-Hauser syndrome. Description of surgical technique and early results.

### Permalink

<https://escholarship.org/uc/item/2hw7r1ws>

### Authors

Tewari, KS  
Tewari, KK  
Tracy, L  
[et al.](#)

### Publication Date

2014

### Copyright Information

This work is made available under the terms of a Creative Commons Attribution License, available at <https://creativecommons.org/licenses/by/4.0/>

Peer reviewed

# Full-Thickness Skin Grafts for Neovaginal Construction in Mayer–Rokitansky–Küster–Hauser Syndrome

Krishnansu S. Tewari, MD,<sup>1,2</sup> Lauren Tracy, BA,<sup>1</sup> and Philip J. DiSaia, MD<sup>1</sup>

## Abstract

**Background:** Mayer–Rokitansky–Küster–Hauser (MRKH) syndrome is characterized by vaginal agenesis, the treatment of which typically involves neovaginal construction using split-thickness skin grafts. While successful in many patients, this method may result in vaginal contracture or foreshortening. Neovaginal construction using full-thickness skin grafts (FTSGs) is an underutilized surgical technique associated with decreased rate of contracture and improved functional outcomes. **Cases:** FTSGs were used for neovaginal construction in 5 patients with MRKH syndrome. This report describes the surgical technique and the current authors' experience when using it. There was a mean follow-up time of 39.4 months (range: 9–111 months). **Results:** All 5 grafts have remained patent, and all of the patients who desired vaginal intercourse are now capable of achieving this. None of the 5 patients had vaginal contraction or foreshortening. **Conclusions:** Neovaginal construction using FTSGs is an underutilized and underreported technique in the gynecologic literature. Surgical planning, dilator use, and management of granulation tissue are important considerations when applying this technique. In the current authors' experience, the use of FTSGs in neovaginal construction for patients with MRKH has been successful, with no incidence of vaginal contraction or foreshortening. (J GYNECOL SURG 31:52)

## Introduction

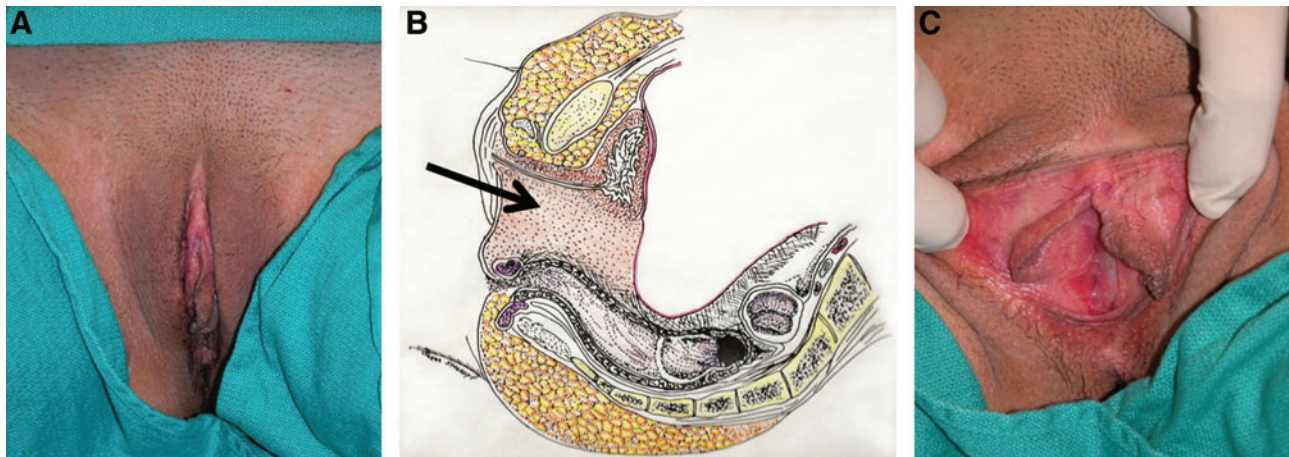
**R**EALDUS COLUMBUS (1516–1559 AD) first described congenital absence of the vagina in 1572.<sup>1</sup> The German anatomist and physiologist, August Franz Joseph Karl Mayer (1787–1865 AD), reported the congenital absence of the vagina as one of the abnormalities found in stillborn infants with multiple birth defects.<sup>2</sup> Although Mayer was a very prolific writer, with the exception of vaginal agenesis and a few other conditions, most of his work deserves oblivion, as it was written in the tradition of the natural philosophers. Karl Freiherr von Rokitansky, MD (1804–1878 AD), was a Bohemian physician, pathologist, humanist philosopher, and liberal politician. In 1838, von Rokitansky described a condition in which the vagina was absent, a small bipartite uterus was present, the ovaries were normal, and anomalies of other organ systems—especially renal and skeletal—were commonly observed.<sup>3</sup> These findings were also described in 1910 by the German gynecologist Hermann Küster, MD (1879–1964 AD).<sup>4</sup> Finally, the Swiss gynecologist, Georges Andre Hauser, MD (1921–), linked the condition to failure of the Müllerian ducts to develop in the presence of a normal 46 XX karyotype.<sup>5,6</sup> The

disorder has come to be known as the *Mayer–Rokitansky–Küster–Hauser* syndrome (MRKH).

Mayer–Rokitansky–Küster–Hauser syndrome (MRKH) affects ~1 in 4500 female births and is characterized by failure of fetal Müllerian-duct development, resulting in congenital absence of the upper portion of the vagina and Fallopian tubes, with a rudimentary-to-absent uterus (Fig. 1).<sup>7</sup> These patients usually present with primary amenorrhea, or less-commonly after a failed attempt at intercourse. The inability to pass menstrual fluid can result in cyclic pelvic pain and endometriosis in the ~50% women with MRKH who have uterine remnants.<sup>8</sup> More commonly, however, the anatomical deformities of MRKH affect the psychosocial well-being of these women as their sexual function and fertility may be limited.<sup>9</sup>

Nonsurgical reconstruction of the vagina (or neovaginal construction) is the preferred first-line treatment and is possible for highly motivated patients through self-dilation with continuous external perineal pressure. This method can be unwieldy and takes many months to achieve a functional neovagina, with a mean of 11.8 months' dilation needed to create an adequate vaginal canal in one case

<sup>1</sup>Division of Gynecologic Oncology, Department of Obstetrics & Gynecology, University of California Medical Center, Orange, CA.  
<sup>2</sup>The Center for Cancer Prevention and Treatment, St. Joseph's Medical Center, Orange, CA.



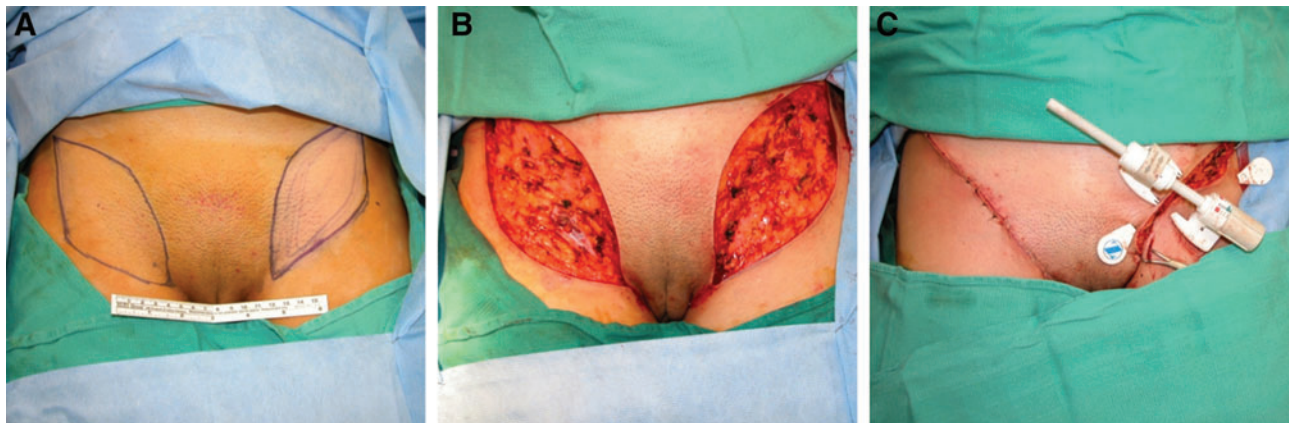
**FIG. 1.** Vaginal agenesis with blind vaginal pouch: (A) Photograph from Case #1 showing the normal appearance of the external genitalia. (B) Pelvis in sagittal section showing vaginal agenesis (arrow). (C) Photograph from Case #1 showing blind vaginal pouch. Visit [www.liebertpub.com/gyn](http://www.liebertpub.com/gyn) to view figure in color.

series.<sup>10</sup> Because of these constraints, noncompliance can be an issue, especially with younger women. If conservative therapy fails, surgical treatment options include applied traction using the Vecchiotti procedure; using musculocutaneous or fasciocutaneous flaps; or grafting the bowel, buccal mucosa, peritoneum, or allogeneic materials. The most common surgical procedure for vaginal reconstruction in MRKH remains the use of split-thickness skin grafts (STSGs).<sup>11</sup> However, vaginal reconstruction using STSGs in MRKH has been associated with vaginal foreshortening and stenosis, limiting the functionality of the neovagina.<sup>12,13</sup> Because of these complications, the current authors have modified this classic McIndoe-Abbe procedure, and begun using full-thickness skin grafts (FTSGs) exclusively for the construction of neovaginas in patients with MRKH syndrome. Although this technique is not novel, the current authors believe that it is underutilized and underreported in the gynecologic literature. In this brief report, the current authors discuss their experience with utilizing FTSGs for neovaginal construction in 5 patients with MRKH syndrome, with limited complications, and a mean follow-up time of 39.4 months (range: 9–111 months).

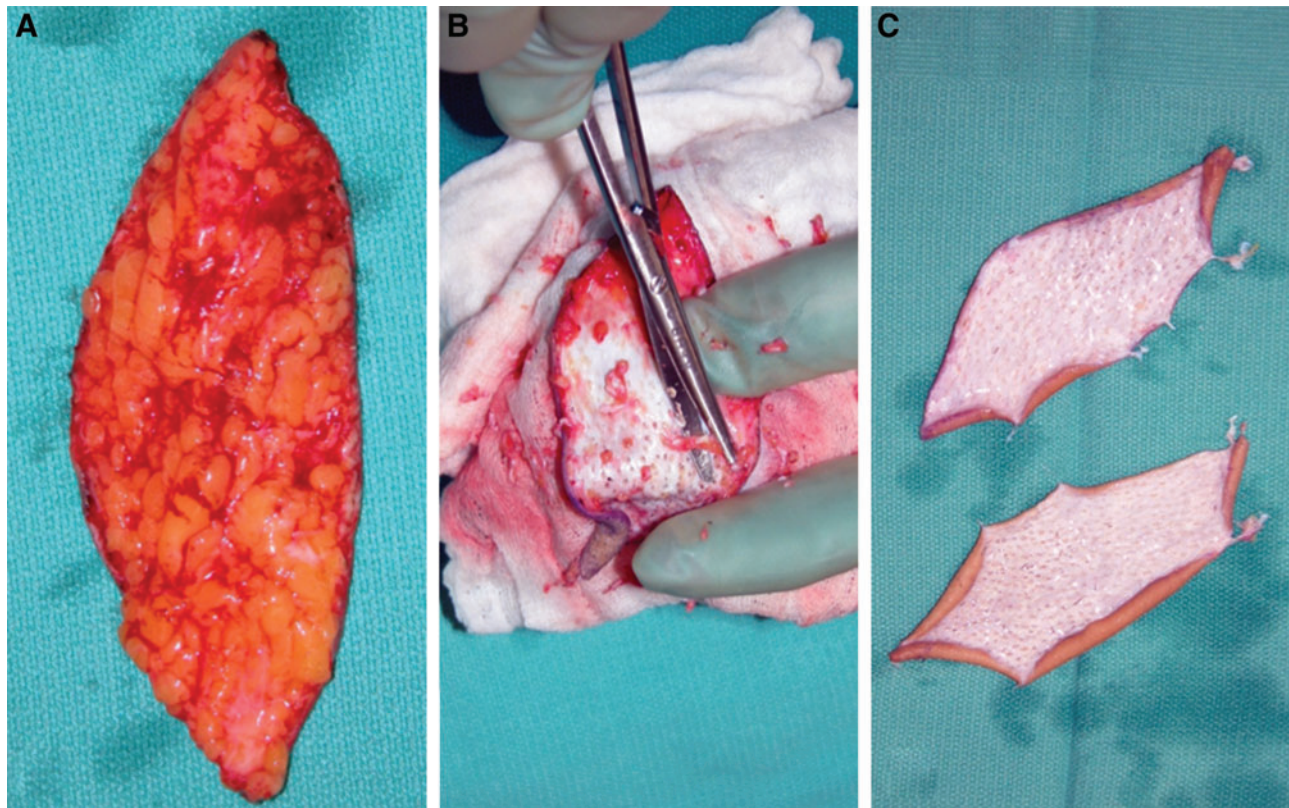
#### *Surgical technique*

After 48-hour bowel prep, prophylactic oral antibiotics, and transurethral bladder catheterization, patients are positioned in low Allen stirrups. Bilateral elliptical FTSGs measuring 15×7 cm are then marked with a surgical pen on the hairless area of the groin. To ensure that the resulting incision is not under too much tension, the marked graft sites can be pinched together along their short axes to ensure adequate tissue closure. Following harvesting, the donor sites are closed immediately (Fig. 2). If necessary, the donor area can be slightly undermined superficially to the deep fascia to ensure a tension-free closure. The subdermal fat on each graft is then debrided meticulously (Fig. 3). Defatting of each graft may require up to 45 minutes.

The vaginal stent, measuring 10.5 cm in length and 4.5 cm in diameter, is prepared from either a plastic dilator with drainage catheters, or from a foam block molded into a bullet shape. The stent is placed inside a condom and the end is ligated. Each FTSG is placed longitudinally along the stent with the epidermal surfaces in contact with the condom. The FTSG paddles are sutured together around the stent using 4-0 monocryl (Fig.



**FIG. 2.** Preparation of the full-thickness skin grafts (FTSGs): (A) FTSG paddles are designed to be 7 cm wide×15 cm long each. (B) Donor sites following harvesting of FTSGs. (C) Primary closure of donor sites. Visit [www.liebertpub.com/gyn](http://www.liebertpub.com/gyn) to view figure in color.



**FIG. 3.** Preparation of the full-thickness skin grafts (FTSGs): (A) An unprepared FTSG with underlying fat. (B) Laborious technique of de-fattening the FTSG. (C) Prepared FTSGs completely de-fatted. Visit [www.liebertpub.com/gyn](http://www.liebertpub.com/gyn) to view figure in color.

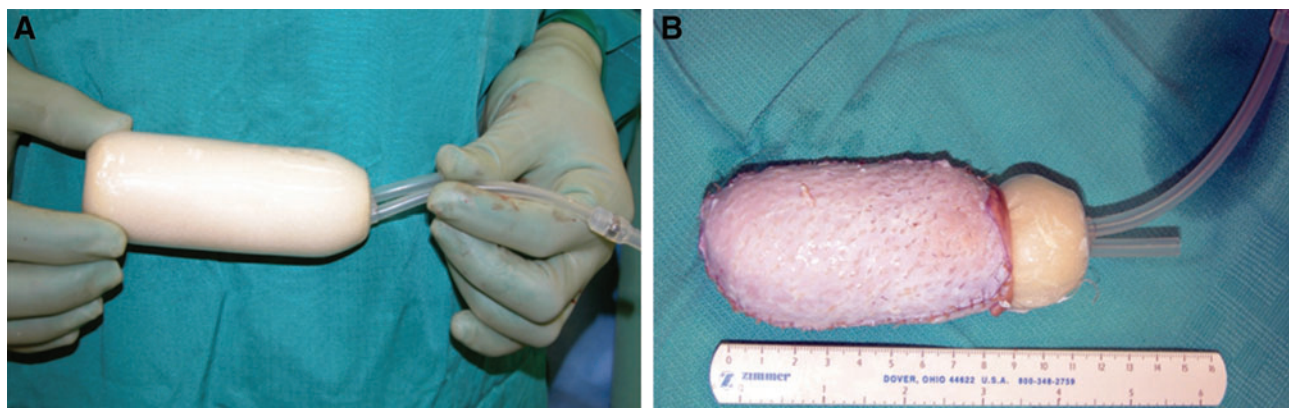
4). The tapered end of the stent, which will be in contact with the proximal vagina, (i.e., pelvic peritoneum) is covered by the skin grafts and the nontapered end is left open.

The blind vaginal pouch is grasped externally with three Allis clamps in a triangular fashion (Fig. 5A) and a horizontal curvilinear incision is made across the mucosa. Graves specula of increasing size and length are then applied within the incision and with gentle, directed pressure each speculum is opened to form a cavity 12 cm in length up to the peritoneal lining in the vesicorectal space (Fig. 5B). Meticulous hemostasis is mandatory and may be achieved with spot electrocoagulation. The skin graft-covered stent is then carefully

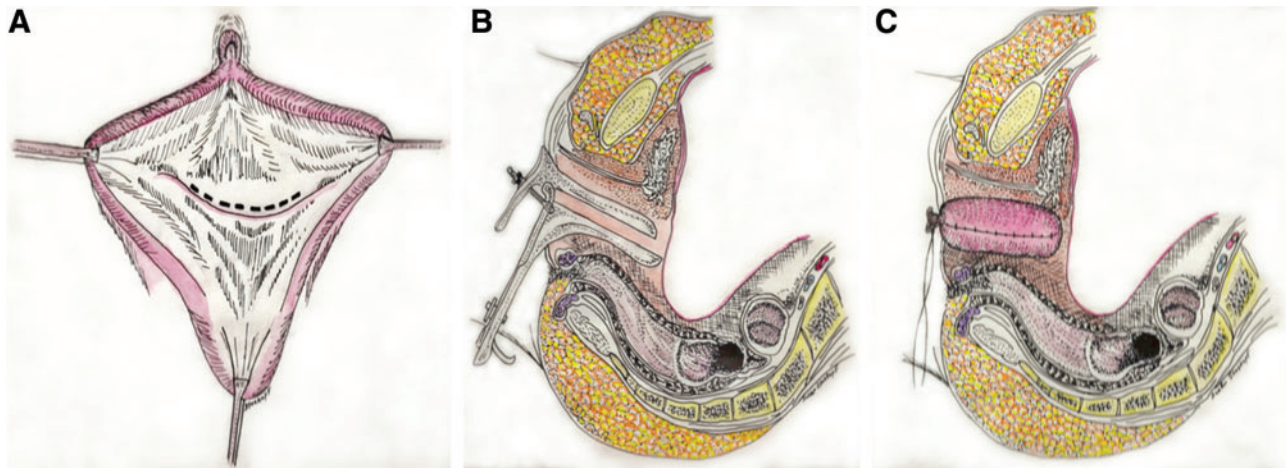
inserted into the vaginal cavity to maximal depth, and the labia minora are sutured together to maintain its position (Fig. 5C).

#### *Postsurgical protocol*

Patients are kept at bed rest with the Foley catheter in place and are given a low-residue diet stool softeners, prophylactic cephalosporin, and bilateral lower-extremity compression devices. Ideally, hip flexion should be limited in the first few postoperative days to reduce tension on the donor-site incisions. On the tenth postoperative day, the stent is removed under general anesthesia, the neovagina is irrigated, and the



**FIG. 4.** Preparation of the vaginal stent: (A) The vaginal stent measures 10.5 cm in length and has a diameter of 4.5 cm. (B) Application of the full-thickness skin grafts to the vaginal stent. Visit [www.liebertpub.com/gyn](http://www.liebertpub.com/gyn) to view figure in color.



**FIG. 5.** Surgical approach to creation of the neovaginal cavity: (A) The vulvar tissues are grasped with three Allis clamps in triangular formation and a curvilinear incision is made across the blind vaginal pouch. (B) Direct application of the speculum to create the neovaginal space between the bladder and rectum with gentle—but forceful—pressure. (C) Sagittal view showing the position of the vaginal stent (covered by the full-thickness skin grafts) in the neovaginal space. Visit [www.liebertpub.com/gyn](http://www.liebertpub.com/gyn) to view figure in color.

FTSGs are inspected for graft take and viability. A plastic vaginal dilator is then placed in the neovagina, which patients are taught to remove and instructed to clean daily with a vaginal douche. Patients are examined in the clinic within 1 week of discharge, then return to the clinic monthly for the first 6 postoperative months. After this time, patients can return to the clinic on a semiannual or annual basis to monitor progress. Patients are also offered referrals for pelvic-floor physical therapy. After 6 months, any patient who has a partner may substitute the dilator for regular sexual activity.

### Cases

All 5 patients underwent preoperative diagnostic work-ups revealing a 46XX genotype, and imaging showing normal ovaries bilaterally, absence of the vagina, and either hypoplasia or absence of the uterus consistent with a diagnosis of MRKH.

#### Case #1

Patient #1 was a 23-year-old woman who experienced 100% graft take following FTSG reconstruction after 6 months of continuous dilator usage. With the exception of recurrent urinary tract infections following the onset of sexual activity, at her 9-year follow-up she has remained asymptomatic and sexually active, without discomfort, vaginal stricture, or stenosis.

#### Case #2

Patient #2 was an 18-year-old woman who developed bothersome granulation tissue at the introitus of her neovagina 8 months after her initial surgery; this granulated tissue was successfully treated with CO<sub>2</sub> laser ablation. Although not recommended,<sup>14</sup> a Papanicolaou smear performed 2.5 years after reconstruction by another provider indicated the presence of a low-grade squamous intraepithelial lesion. A subsequent biopsy revealed that she had a vaginal intraepithelial neoplasia, stage 1. This was managed expectantly. A follow-up Papanicolaou smear test, performed 1 year later, showed no evidence of any intraepithelial lesions or malignancy. She has been successfully sexually active with no significant discomfort or stricture.

#### Case #3

Patient #3 was a 27-year-old woman who required significant undermining of the FTSG donor site on the anterior thighs bilaterally in to close the wounds primarily. On postoperative day 7, she developed some erythema and small bullae on the inferior aspect of these wounds bilaterally. By keeping her hips flexed at all times, the tension on these wounds was reduced and healed without tissue loss or necrosis. The patient is successfully sexually active and, although she is pleased with her neovagina, she did develop large cosmetically unpleasant keloid scars on her donor site incisions.

#### Case #4

Patient #4 was a 22-year-old woman who underwent neovagina reconstructive surgery using FTSGs at age 22. Because of her smaller anatomical dimensions, the planned dissection of the vesicorectal space was not possible, and a smaller temporary dilator had to be fashioned intraoperatively following stent removal, until which time a permanent dilator could be procured. On her last examination this patient had a neovagina of functional dimensions with no stenosis or contracture.

#### Case #5

Patient #5 was a 21-year-old woman who underwent uncomplicated neovaginal construction using FTSGs. Two months postoperatively, she experienced pain and spasm of the pelvic-floor musculature resulting in her inability to reinsert her dilator. This extended inability to reintroduce the dilator required a return to the operating room (OR), at which time, synechial bands of obstructing granulation tissue were discovered and dissected. The patient was referred to physical therapy for treatment of her pelvic-floor spasms but declined this therapy, and had no further complaints of spasm (which perhaps were originally related to pressure from granulation tissue in addition to the dilator). Following this, the patient experienced some serous discharge from the granulation tissue in the apex of her neovagina; this condition was managed initially with serial silver nitrate treatments, and eventually

CO<sub>2</sub> laser ablation. She has not yet had vaginal intercourse as of this writing.

## Results

In the current 5 patients with MRKH syndrome, for whom FTSGs were used, the current authors have not noted any graft loss or unacceptable contracture during a mean follow-up time of 39.4 months (range: 9–111 months). All 5 grafts remain patent, and all patients who desired vaginal intercourse are capable of achieving this.

## Discussion

Although the French military surgeon Guillome Dupuytren, MD (1777–1835 AD), gained much esteem for treating Napoleon Bonaparte's hemorrhoids, Dupuytren is also often credited with the first attempt at vaginoplasty in 1817.<sup>15</sup> The use of a split-thickness skin graft to line the cavity dissected between the bladder and the rectum was first pioneered by the world-renowned American surgeon Robert Abbe, MD (1851–1928).<sup>11</sup> The procedure was further popularized by the New Zealand plastic surgeon Sir Archibald McIndoe, MD (1900–1960).<sup>16</sup>

Sadove and Horton were the first researchers to discuss the application of FTSGs for vaginal reconstruction in 1988.<sup>17</sup> Of the cases of MRKH syndrome treated with FTSGs reported in the plastic surgery literature to date, no complication of vaginal stenosis has been described.<sup>18–20</sup> Although cases of vaginal stricture following FTSG vaginal reconstruction may be unreported to date, contracture is always a possibility following any grafting of the skin. However, the successful outcomes in the 5 patients described in this article are in accordance with the previously reported cases.

Articles in the literature describing the use of STSGs report that 6.5%–24% of the neovaginas created in this manner were unsatisfactory or were no longer functional.<sup>13,21–24</sup> Although not always functionally limiting, vaginal contraction and stricture formation remain a concern regarding the use of STSGs. Classically, STSGs contract by ~40% of their original graft size as they heal, while FTSGs undergo only a 10%–20% contracture.<sup>25</sup> Another advantage of FTSGs over STSGs is the improved preservation of normal skin charac-

teristics (e.g., texture, thickness). This is the result of conservation of the complete dermis with an intact dermal vascular plexus in FTSGs (Table 1). The glandular components of the skin are likewise preserved and may aid in vaginal lubrication. Similarly, because they preserve more intact neurilemmal sheaths, FTSGs are associated with more complete reinnervation, resulting in improved sensation of the fully healed graft, compared to STSGs.<sup>26</sup>

As noted above, the 5 current patients did not have any graft loss or unacceptable contractures; the 5 grafts remained patent, and all patients who desired vaginal intercourse were capable of achieving this. To maintain patency, it is mandatory that patients wear a vaginal dilator for at least 23 hours a day during the acute healing phase following reconstruction. The surgeon should plan to have vaginal dilators of various sizes available for use to prevent a lapse in dilator usage during the critical postsurgical period. Some surgeons advocate intermittent (rather than continuous) dilator usage following vaginal reconstruction. It is possible that the current successful outcomes were possible, in part, to the 5 patients' compliance with continuous dilator usage. Similarly, the intermittent use of dilators may be a factor in the previously reported vaginal contractures following STSG reconstruction.

Granulation tissue is a common complication of neovaginal construction whether STSGs or FTSGs are used. Managed conservatively, neovaginal granulation tissue can be expected to completely epithelialize within 12 months.<sup>27</sup> If the tissue is bothersome, it can be managed successfully with either serial treatments of silver nitrate or a single ablation in the OR with a CO<sub>2</sub> laser.

Finally, whenever FTSGs are used, it is important to consider the donor site and monitor for signs of impending tissue necrosis. When designing the skin-graft paddles, care must be taken to harvest only the minimal required tissue to aid in primary closure. Likewise, it is important to consider the native vascular supply of the donor pedicle to reduce excessive undermining in these areas that may result in ischemic necrosis. If an adequately sized skin-graft paddle cannot be safely taken in, the graduated use of tissue expanders placed under Scarpa's fascia should be considered to allow for expansion and neovascularization of the skin and surrounding soft tissue.

TABLE 1. CLINICAL INDICATIONS AND OUTCOME DIFFERENCES BETWEEN SPLIT-THICKNESS AND FULL-THICKNESS SKIN GRAFTS

<i>Characteristic</i>	<i>Split-thickness skin grafts</i>	<i>Full-thickness skin grafts</i>
Structure	100% epidermis and part of dermis	100% epidermis & 100% of dermis with a percentage of fat
Cosmetic appearance	Poor color & texture match; contraction	Better quality appearance; thicker, prevents contraction & deformation
Indications	When aesthetic outcome is less important (i.e., burn injury; large defects)	When esthetic outcome is important (e.g., facial defects)
Donor-site tissue	Abdomen, buttock, inner or outer arm, inner forearm & thigh	Groin (most common), supraclavicular fossa
Use in children/adolescents	Concern that contracture may limit graft growth as child grows	Graft will continue to grow with child
Sensation of grafted tissue	Interrupted neurilemmal sheaths hinder invasion of reinnervating nerve fibers, leading to less sensation	More accessible neurilemmal sheaths in complete skin graft allows for greater reinnervation and sensation

## Conclusions

In the current authors' experience, the use of FTSGs for neovaginal construction in patients with MRKH has been successful, with no incidence of vaginal contraction or foreshortening. However, a larger study is needed to assess the outcomes of vaginal reconstruction further for MRKH using STSGs versus FTSGs. Other techniques, including vaginal construction with labia minora flaps, acellular dermal grafts, autologous *in vitro* cultured vaginal tissue, and even allogeneic transplantation of a donor uterus are also being studied.<sup>28</sup>

## Disclosure Statement

No competing financial conflicts exist.

## References

- Goldwyn RM. History of attempts to form a vagina. *Plast Reconstr Surg* 1977;59:319.
- Mayer CAJ. Uterus malformation and its types with remarks on parenchymal types and septums [in German]. *J Chirurgie Augen-Heilkunde Berlin* 1829;13:525.
- von Rokitsansky KF. The malformations of the uterus [in German]. *Medizinische Jahrbucher Kaiserl Konigl Osterreichischen Staates, Wien* 1838;26:39.
- Küster H. Uterine didelphus with rudimentary vagina [in German]. *Zeitschrift Geburtshilfe Gynäkologie, Stuttgart* 1910;67:692.
- Hauser GA, Keller M, Koller T, et al. The Rokitsansky-Kuster syndrome: Uterine bicornus with rudimentary vagina [in German]. *Gynaecologia, Basel* 1961;151:111.
- Hauser GA, Schreiner WE. The Mayer-Rokitansky-Kuster syndrome [in German]. *Schweizerische Medizinische Wochenschrift, Basel* 1961;91:383.
- Morcel K, Guerrier D, Watrin T, Pellerin I, Levêque J. The Mayer-Rokitansky-Küster-Hauser (MRKH) syndrome: Clinical description and genetics [in French]. *J Gynecol Obstet Biol Reprod (Paris)* 2008;37:539.
- Marsh, CA, Will MA, Smorgick N, Quint EH, Hussain H, Smith YR. Uterine remnants and pelvic pain in females with Mayer-Rokitansky-Küster-Hauser syndrome. *J Pediatr Adolesc Gynecol* 2013;26:199.
- Bean EJ, Mazur T, Robinson AD. Mayer-Rokitansky-Küster-Hauser syndrome: Sexuality, psychological effects, and quality of life. *J Pediatr Adolesc Gynecol* 2009;22:339.
- Roberts CP, Haber MJ, Rock JA. Vaginal creation for Müllerian agenesis. *Am J Obstet Gynecol* 2001;185:1349; discussion:1352.
- Abbé R. New method of creating a vagina in a case of congenital absence. *Med Rec* 1898;54:836.
- Hensle TW, Reiley EA. Vaginal replacement in children and young adults. *J Urol* 1998;159:1035.
- Alessandrescu D, Peltecu GC, Buhimschi CS, Buhimschi IA. Neocolpopoiesis with split-thickness skin graft as a surgical treatment of vaginal agenesis: Retrospective review of 201 cases. *Am J Obstet Gynecol* 1996;175:131.
- Committee on Adolescent Health Care. Committee opinion: No. 562. Müllerian agenesis: diagnosis, management, and treatment. *Obstet Gynecol* 2013;121:1134.
- Dupuytren RT, Whittracé FW. The vaginal surgery. *Am J Obstet Gynecol* 1945;49:789.
- McIndoe AH, Bannister JB. An operation for the cure of congenital absence of the vagina. *J Obstet Gynaecol Br Emp* 1938;45:490.
- Sadove RC, Horton CE. Utilizing full-thickness skin grafts for vaginal reconstruction. *Clin Plast Surg* 1988;15:443.
- Chen YB, Cheng TJ, Lin HH, Yang YS. Spatial W-plasty full-thickness skin graft for neovaginal reconstruction. *Plast Reconstr Surg* 1994;94:727.
- Akn S. Experience with neovaginal construction using the full-thickness skin graft in vaginal agenesis. *Ann Plast Surg* 2004;52:391; discussion:397.
- Baytekin, C. et al. Total vaginal reconstruction with combined "Split Labia Minora Flaps" and full-thickness skin grafts. *J. Obstet. Gynaecol. Res.* 33, 524–8 (2007).
- Rock JA, Reeves LA, Retto H, Baramki TA, Zacur HA, Jones HW Jr. Success following vaginal creation for Müllerian agenesis. *Fertil Steril* 1983;39:809.
- De Souza AZ, Maluf M, Perin PM, Maluf Filho F, Perin, LF. Surgical treatment of congenital uterovaginal agenesis: Mayer-Rokitansky-Küster-Hauser syndrome. *Int Surg* 1987; 72:45.
- Buss JG, Lee RA. McIndoe procedure for vaginal agenesis: Results and complications. *Mayo Clin Proc* 1989;64: 758.
- Ozek C, Gurler T, Alper M, et al. Modified McIndoe procedure for vaginal agenesis. *Ann Plast Surg* 1999; 43:393.
- Bailey BJ, Calhoun KH, Healy GB, et al., eds. *Atlas of Head and Neck Surgery—Otolaryngology*, 2nd ed. Philadelphia: Lippincott Williams & Wilkins, 2001.
- Fitzgerald MJ, Martin F, Paletta FX. Innervation of skin grafts. *Surg Gynecol Obstet* 1967;124:808.
- Hirsch HA, Käser O, Iklé FA. Vaginal granulation tissue. In: Hirsch HA, Käser O, Iklé FK, eds. *Atlas of Gynecological Surgery: Including Breast Surgery and Related Urologic and Intestinal Surgical Operations*, 3rd ed, vol. 669. Stuttgart: Thieme, 1997:703.
- Kisu I, Banno K, Mihara M, Suganuma N, Aoki D. Uterine transplantation: Towards clinical application. *Gynecol Obstet Invest* 2013;76:74.

Address correspondence to:  
 Krishnansu S. Tewari, MD, FACOG, FACS  
 Department of Obstetrics & Gynecology  
 University of California, Irvine Medical Center  
 101 The City Drive South, Building 56  
 Orange, CA 92868

E-mail: ktewari@uci.edu