

UCLA

Proceedings of UCLA Health

Title

The Undiagnosed Exudate: Pleuroscopy and Pleural Effusions

Permalink

<https://escholarship.org/uc/item/2h30z0k1>

Journal

Proceedings of UCLA Health, 21(1)

Authors

Sumarsono, Andrew

Kim, Cynthia

Susanto, Irawan

et al.

Publication Date

2017-03-06

CLINICAL VIGNETTE

The Undiagnosed Exudate: Pleuroscopy and Pleural Effusions

Andrew Sumarsono, B.S., Cynthia Kim, M.D., Irawan Susanto, M.D., Scott Oh, M.D.

Introduction

Malignant mesothelioma is a rare neoplasm of the pleural, pericardial, and peritoneal linings that has been causally linked to asbestos exposure. The annual incidence in the United States is approximately 3,300 cases per year. Up to 70-80% of newly diagnosed mesothelioma patients have a history of asbestos exposure. Rarely, patients will develop mesothelioma decades after receiving radiation therapy for other primary malignancies, such as breast carcinoma or Hodgkin lymphoma. The following case report illustrates a new diagnosis of mesothelioma in the context of prior radiation therapy for primary breast cancer.

Case Presentation

A 60-year-old female was referred for recurrent right pleural effusion. Her past medical history was notable for N0, M0, and triple-positive infiltrating ductal carcinoma of the right breast 18 years prior. She underwent lumpectomy with all lymph nodes negative. Her adjuvant treatment included four cycles of doxorubicin and cyclophosphamide, 5940 cGy of radiation to the right breast divided into 33 fractions over 44 days, and five years of tamoxifen followed by five years of aromatase inhibitor. Her subsequent medical course was significant for a total abdominal hysterectomy and bilateral oophorectomy for ovarian cysts but was otherwise negative for recurrence.

The patient developed a new cough and dyspnea, which persisted for months prompting her to seek medical attention. Chest imaging including a CT that revealed a large right pleural effusion (Figure 1). There was no evidence of a lung mass or pleural thickening. Ultrasound guided thoracentesis removed 1.15 L of clear straw colored fluid. Pleural fluid analysis was consistent with an exudative process. Cytology was negative for carcinoma but did note large atypical mononuclear cells. Her pleural fluid recurred within a week prompting referral for medical pleuroscopy. She denied fevers, chills, night sweats, or other significant complaints. Her remaining past medical history is significant for osteopenia and thalassemia. She is a never smoker with no significant asbestos exposure. Family history was significant for maternal breast cancer at age 59 and paternal Crohn's disease.

On exam, she was afebrile with stable vital signs, saturating 98% on ambient air. Generally, the patient was well appearing. Her lung exam was clear to auscultation bilaterally with decreased breath sounds on the right, which was noted to be dull to percussion. The remainder of her exam was unremarkable.

Routine labs including a complete blood count and complete metabolic panel were also unremarkable. Outpatient right medical pleuroscopy was performed under moderate sedation with complete evacuation of the recurrent pleural fluid. Careful examination of the pleura revealed multiple pleural nodules that were biopsied (Figure 2). Pathology confirmed epithelioid malignant mesothelioma. She was referred to thoracic surgery and medical oncology for further management.

Discussion

Mesothelioma is a rare neoplasm arising from peritoneal, pericardial, and pleural linings that has been causally associated with asbestos exposure.¹ The overall incidence of mesothelioma in the United States is 3,300 cases per year, a value that reflects improvement over the last few decades given increased awareness of the long-term effects of asbestos exposure.² Approximately 300 of those cases are found in patients without a history of asbestos.² Some proportion of the 300 non-asbestos related cases are likely spontaneous events, while others are secondary to radiation therapy exposure. In our patient, we suspect her past history of breast irradiation was likely a contributory cause of her mesothelioma.

Clinical Presentation

Patients commonly present with nonspecific symptoms such as chest pain, dyspnea, cough, hoarseness, or night sweats that often leads to delayed diagnosis. If metastatic disease is present, patients may present with other systemic symptoms. Physical exam may reveal findings consistent with a pleural effusion.

Diagnosis

A tissue biopsy is necessary to confirm the diagnosis. Of note, thoracentesis has a low sensitivity and further investigation is warranted for recurrent exudative pleural effusions. A bronchoscopic or percutaneous approach may be sufficient if imaging reveals an appropriate target. However, pleuroscopy remains the gold standard. Pleuroscopy should be considered for any unexplained pleural effusion if less invasive investigations are unrevealing as it is well tolerated with a sensitivity over 90% for malignancy.³ It is important to obtain sufficient material to accurately subtype mesotheliomas as this impacts prognosis and management options.

Malignant mesotheliomas are divided into three subtypes: epithelioid, sarcomatoid, or biphasic.⁴ Because no individual

immunohistochemical marker is sufficiently specific or sensitive, a panel of two reactive and two nonreactive markers is recommended to confirm the diagnosis. Cytokeratin stains will be positive in a large proportion of mesotheliomas. For epithelioid mesotheliomas, the common positive immunohistochemical panel includes Calretinin, CK5/6, WT1, and D2-40. The common negative stains include CEA, TTF-1, Napsin A, Surfactant apoprotein, BER EP4, MOC3, and ER.

Etiology

While the literature generally supports the association between radiation therapy and the development of mesothelioma in patients with Hodgkin lymphoma, Non-Hodgkin lymphoma, and testicular cancer, the association with breast cancer is less well-established. In 1994, Hofmann identified 20 cases of malignant mesothelioma in patients who had been exposed to past radiation therapy, two of which had a primary breast carcinoma.⁵ In 1996, Cavazza identified 37 patients who had developed mesothelioma with a history of radiation therapy from two large databases, of which seven patients had received irradiation for breast carcinoma.⁶ In 1997, Neugat reviewed a database with 251,750 women diagnosed with breast cancer and identified six cases of malignant mesothelioma.⁷ In this article, only two of the six patients had a history of radiation exposure; this paper concluded no correlation between radiation therapy and the development of mesothelioma. More recently, Deutsch evaluated 22,140 patients within 11 NSABP clinical trials for primary breast cancer.⁸ They identified 3 pleural mesotheliomas, all arising in patients who had received radiation therapy in the ipsilateral thorax. This paper calculated that the relative risk for developing mesothelioma in patients who received post-operative radiotherapy was 3.74, compared to the general population.

In our literature review, 14 patients developed mesothelioma believed to be due to radiation therapy in the treatment of breast cancer. It is likely that this number is underestimated given that some clinicians and patients may dismiss any pleural imaging abnormalities as metastasis of the primary malignancy. In conclusion, we present a rare case of radiation-induced mesothelioma which highlights the importance of continued investigation for unexplained pleural effusions.

Figures

Figure 1. CT chest with moderate right pleural effusion

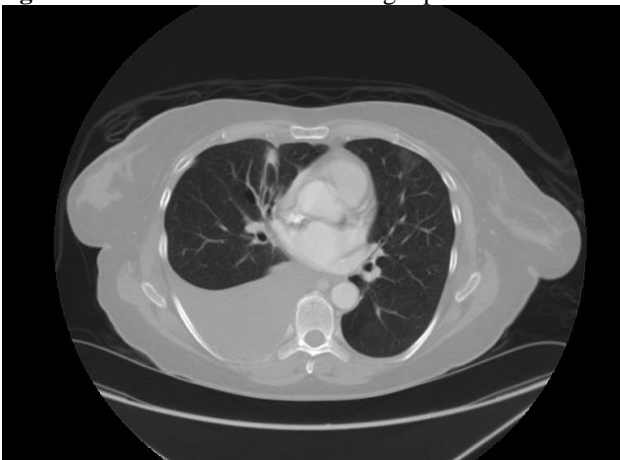
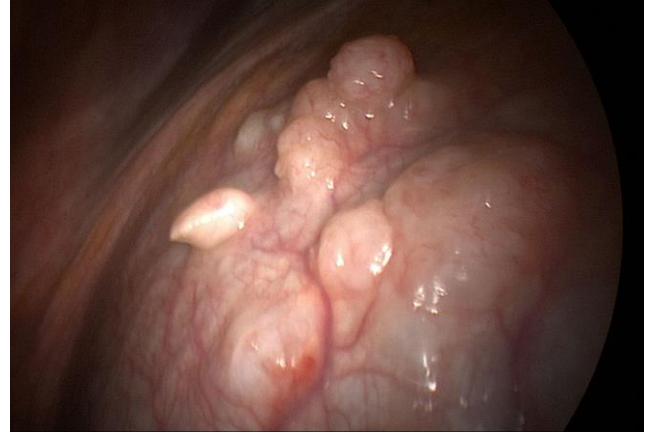

Figure 2. Pleural nodules



REFERENCES

1. **Yates DH, Corrin B, Stidolph PN, Browne K.** Malignant mesothelioma in south east England: clinicopathological experience of 272 cases. *Thorax*. 1997 Jun;52(6):507-12. Erratum in: *Thorax* 1997 Nov;52(11):1018. PubMed PMID: 9227715; PubMed Central PMCID: PMC1758573.
2. **Teta MJ, Mink PJ, Lau E, Scurman BK, Foster ED.** US mesothelioma patterns 1973-2002: indicators of change and insights into background rates. *Eur J Cancer Prev*. 2008 Nov;17(6):525-34. doi: 10.1097/CEJ.0b013e3282f0c0a2. PubMed PMID:18941374.
3. **Maskell NA, Butland RJ; Pleural Diseases Group, Standards of Care Committee, British Thoracic Society.** BTS guidelines for the investigation of a unilateral pleural effusion in adults. *Thorax*. 2003 May;58 Suppl 2:ii8-17. PubMed PMID:12728146; PubMed Central PMCID: PMC1766019.
4. **Inai K.** Pathology of mesothelioma. *Environ Health Prev Med*. 2008 Mar;13(2):60-4. doi: 10.1007/s12199-007-0017-6. PubMed PMID: 19568882; PubMed Central PMCID: PMC2698271.
5. **Hofmann J, Mintzer D, Warhol MJ.** Malignant mesothelioma following radiation therapy. *Am J Med*. 1994 Oct;97(4):379-82. Review. PubMed PMID: 7942942.
6. **Cavazza A, Travis LB, Travis WD, Wolfe JT 3rd, Foo ML, Gillespie DJ, Weidner N, Colby TV.** Post-irradiation malignant mesothelioma. *Cancer*. 1996 Apr 1;77(7):1379-85. PubMed PMID: 8608519.
7. **Neugat AI, Ahsan H, Antman KH.** Incidence of malignant pleural mesothelioma after thoracic radiotherapy. *Cancer*. 1997 Sep 1;80(5):948-50. PubMed PMID:9307196.
8. **Deutsch M, Land SR, Begovic M, Cecchini R, Wolmark N.** An association between postoperative radiotherapy for primary breast cancer in 11 National Surgical Adjuvant Breast and Bowel Project (NSABP) studies and the subsequent appearance of pleural mesothelioma. *Am J Clin Oncol*. 2007 Jun;30(3):294-6. PubMed PMID:17551308.