Title
Coronary sinus pacing for the management of right ventricular and atrial infarction with isolated right ventricular pulsus alternans.

Journal
Texas Heart Institute Journal, 40(4)

ISSN
0730-2347

Authors
Elmariah, Sammy
Shah, Ravi V
Kostis, William J
et al.

Publication Date
2013

Peer reviewed

Coronary Sinus Pacing for the Management of Right Ventricular and Atrial Infarction

with Isolated Right Ventricular Pulsus Alternans

Sammy Elmariah, MD, MPH
Ravi V. Shah, MD
William J. Kostis, PhD, MD
J. Travis Hinson, MD
Michael H. Picard, MD
Igor F. Palacios, MD

An 85-year-old man with a 4-day history of generalized fatigue presented at our emergency department with worsening symptoms of fatigue and dyspnea. Electrocardiography revealed a junctional escape rhythm at a rate of approximately 50 beats/min and ST-segment elevations in the inferior leads and in V_4R. Coronary angiography revealed proximal occlusion of the right coronary artery and nonobstructive disease in the left coronary system (Figs. 1A and 1B). Attempts to

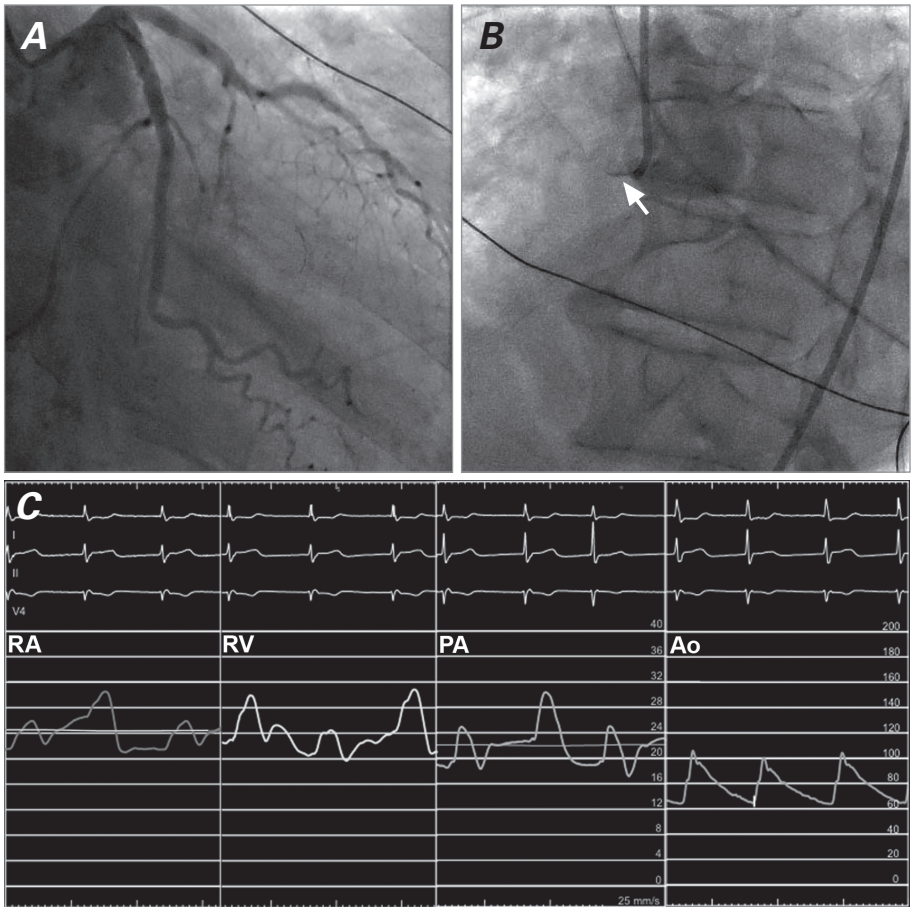

Fig. 1 *Coronary angiograms show* ***A****) nonobstructive coronary artery disease in the left system and* ***B****) proximal occlusion of the right coronary artery (arrow).* ***C****) Hemodynamic tracings show right-sided and aortic pressures. The right atrial (RA) tracing reveals large V waves consistent with severe tricuspid valve regurgitation. The right ventricular (RV) tracing exhibits depressed and broadened systolic peaks. The right atrial, right ventricular, and pulmonary artery (PA) pressure tracings show a dramatic alternating pattern within the magnitude of all systolic peaks, whereas only subtle changes are noted on the aortic (Ao) pressure tracing. The findings are consistent with RV infarction with predominantly right-sided pulsus alternans.*

Presented at the 2011 ACC Scientific Session i2 Summit in New Orleans, Louisiana, on 5 April 2011.

Section Editor:
Raymond F. Stainback, MD, Department of Adult Cardiology, Texas Heart Institute at St. Luke's Hospital, 6624 Fannin St., Suite 2480, Houston, TX 77030

From: *Cardiology Division, Massachusetts General Hospital, Harvard Medical School, Boston, Massachusetts 02114*

Address for reprints:
Igor F. Palacios, MD, Cardiology Division, GRB800, Massachusetts General Hospital, Harvard Medical School, 55 Fruit St., Boston, MA 02114

E-mail:
ipalacios@partners.org

pass a guidewire through the right coronary artery occlusion were unsuccessful. Right-sided heart catheterization revealed a severely reduced cardiac index (1.39 L/min/m^2), elevated right-sided pressures, and dramatic right ventricular (RV) pulsus alternans (Fig. 1C). Transthoracic echocardiography performed in the catheterization laboratory showed RV dilation and akinesis that spared a small segment of the RV apex (Fig. 2). Despite intra-aortic balloon pump support and high-dose dobutamine administration, the patient remained in refractory cardiogenic shock with persistent pulsus alternans. Right ventricular pacing repeatedly resulted in ventricular tachycardia, and attempts at atrial pacing from several positions failed to capture the atrium, which suggested concomitant right atrial infarction. Consequently, we advanced the pacing wire into the coronary sinus. Fluoroscopy and electrocardiography then confirmed mid-coronary sinus pacing (Fig. 3). Coronary sinus pacing substantially improved hemodynamic activity, to the extent that the pulsus alternans resolved (cardiac index, 2.4 L/min/m^2; Table I). Repeat echo-

TABLE I. Patient Hemodynamic Data Before and After Coronary Sinus Pacing

Variable	Pre-Pacing	Post-Pacing
Heart rate, beats/min	49	80
Right atrial pressure, mmHg	26/23	20
PA pressure, mmHg (mean)	24/20 (21)	34/19 (28)
PCWP, mmHg	18	17
Systemic blood pressure, mmHg	130/45	116/65
PA oxygen saturation, %	47	65
Cardiac output, L/min	2.97	5
Cardiac index, L/min/m^2	1.39	2.4
Stroke volume, mL	6.06	6.25

PA = pulmonary artery; PCWP = pulmonary capillary wedge pressure

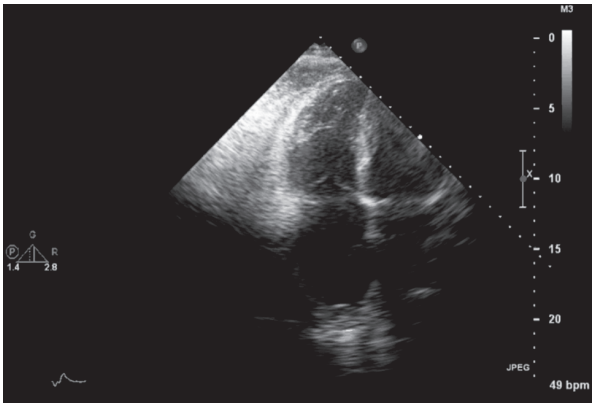

Fig. 2 *Baseline transthoracic echocardiogram (apical 4-chamber view) shows the right ventricle in systole, before coronary sinus pacing. The right ventricle is severely dysfunctional, with mildly spared contractility in the apex.*

Real-time motion image is available at www.texasheart.org/journal.

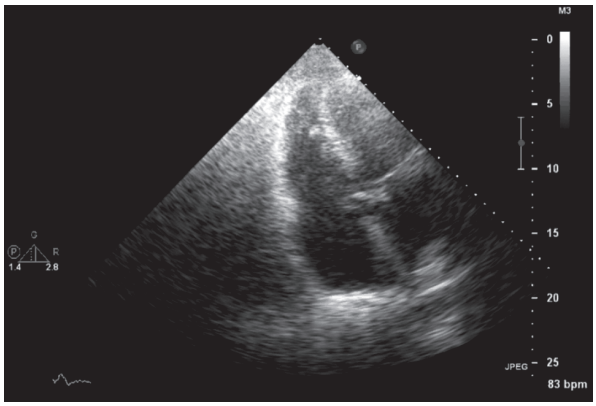

Fig. 4 *Echocardiogram (apical 4-chamber view) shows the right ventricle in systole after coronary sinus pacing. The observed improvement in right ventricular function is due mostly to increased septal contractility.*

Real-time motion image is available at www.texasheart.org/journal.

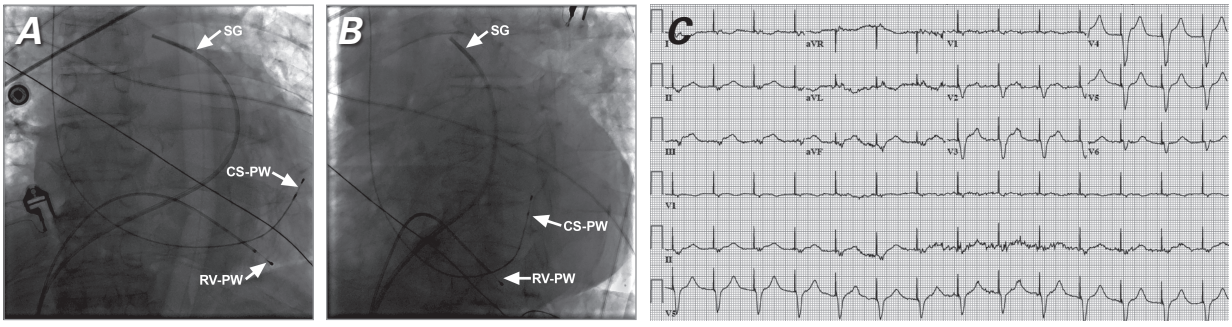

Fig. 3 *Transvenous pacemaker placement in the proximal coronary sinus.* ***A****) Posteroanterior and* ***B****) left anterior oblique views show a transvenous pacing wire from the right internal jugular vein to the mid coronary sinus.* ***C****) Electrocardiogram confirms left ventricular pacing.*

CS-PW = coronary sinus pacing wire; RV-PW = right ventricular pacing wire; SG = Swan-Ganz catheter

cardiography suggested improved RV septal function (Fig. 4).

Comment

Right ventricular infarction results in significant hemodynamic compromise that is associated with high in-hospital mortality rates.[1,2] Traditional methods to support the failing RV include volume-loading, inotropic and mechanical support, and maintenance of atrioventricular synchrony and a high heart rate.

This, to our knowledge, is the first report of the efficacy and safety of coronary sinus pacing as an alternative to atrial and ventricular pacing in patients with RV infarction. In addition, we highlight a classic teaching point (the importance of heart rate in maintaining cardiac output in RV infarction) and publish our finding of isolated RV pulsus alternans in the setting of RV infarction.[3]

References

1. Goldstein JA. Pathophysiology and management of right heart ischemia. J Am Coll Cardiol 2002;40(5):841-53.
2. Zehender M, Kasper W, Kauder E, Schonthaler M, Geibel A, Olschewski M, Just H. Right ventricular infarction as an independent predictor of prognosis after acute inferior myocardial infarction. N Engl J Med 1993;328(14):981-8.
3. Bansal RC, Johns VJ Jr, Willis WH Jr, Isaeff DM. Isolated right ventricular mechanical alternans in right ventricular infarction. Chest 1980;77(1):115-8.