

UC Davis

Dermatology Online Journal

Title

Nevus lipomatosus superficialis

Permalink

<https://escholarship.org/uc/item/2cb3c5t3>

Journal

Dermatology Online Journal, 20(12)

Authors

Kim, Randie H
Stevenson, Mary L
Hale, Christopher S
et al.

Publication Date

2015

DOI

10.5070/D32012025058

Copyright Information

Copyright 2015 by the author(s). This work is made available under the terms of a Creative Commons Attribution-NonCommercial-NoDerivatives License, available at <https://creativecommons.org/licenses/by-nc-nd/4.0/>

Peer reviewed

Case Presentation

Nevus lipomatosus superficialis

Randie H. Kim MD PhD, Mary L. Stevenson MD, Christopher S. Hale MD, Shane A. Meehan MD, Karen Chernoff MD, and Julie V. Schaffer MD

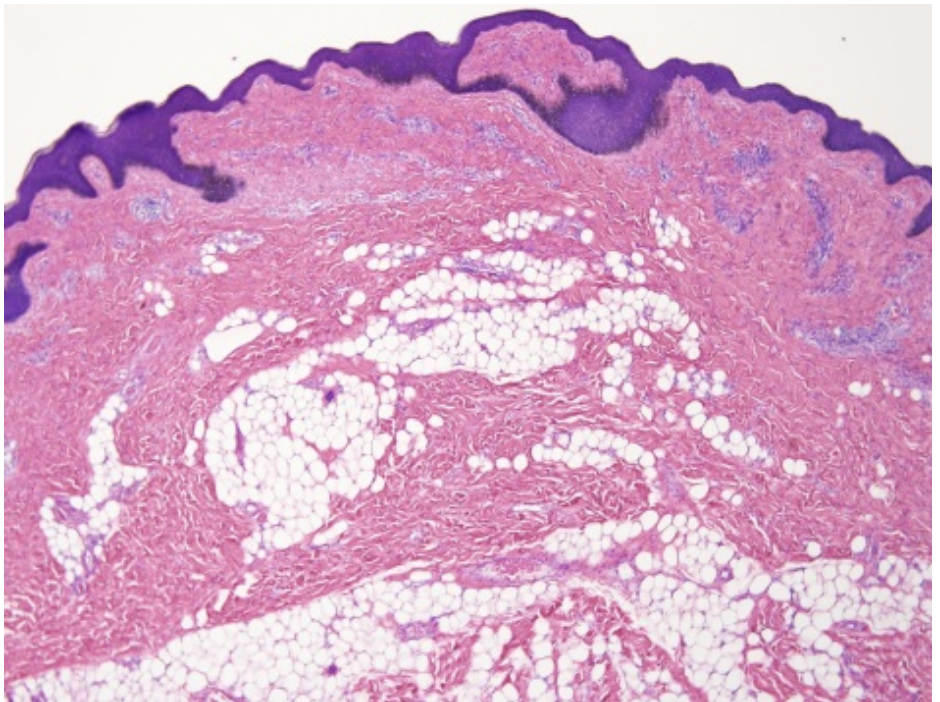
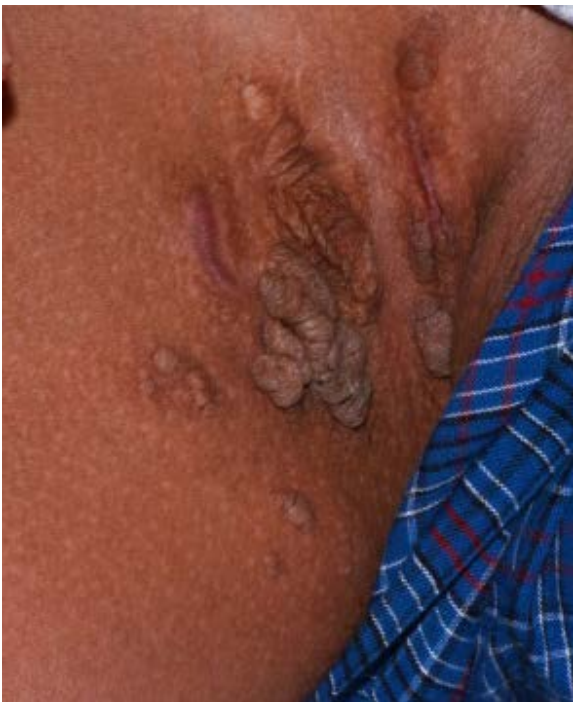Dermatology Online Journal 20 (12): 9

New York University School of Medicine

Special Guest Editor: Nicholas A. Soter, MD

Abstract

Nevus lipomatosus superficialis is an uncommon cutaneous hamartoma that is characterized by the presence of adipose tissue within the reticular dermis. We describe a 15-year-old boy with a three-year history of the classic type of nevus lipomatosus superficialis, which presented as linear arrays of soft, cerebriform papulonodules and plaques in the right inguinal fold. Investigation for chromosomal aberrations and dysregulation of Wnt signaling may provide insights into the pathogenesis of this hamartoma. Treatment is usually with surgical excision although successful use of other modalities has been described.



Case synopsis

History: A healthy 15-year-old boy presented to the Pediatric Dermatology Clinic at the Skin and Cancer Unit for evaluation and management of exophytic plaques in the right inguinal fold. These asymptomatic lesions had been slowly enlarging since they first appeared at 12 years of age.

Physical examination: In the right inguinal fold, there was a linear array of skin-colored, soft, cerebriform plaques that were surrounded by several smaller, skin-colored papulonodules. A hypertrophic scar was noted inferolaterally to the largest plaque.

Laboratory data: None

Histopathology: Within the mid-to-upper reticular dermis, there are mature adipocytes dispersed between thick collagen fibers.

Discussion

Diagnosis: Nevus lipomatosus superficialis

Comment: Nevus lipomatosus superficialis (NLS), which is an uncommon cutaneous hamartoma first described in 1921 [1], is characterized by the presence of adipose tissue within the dermis. The classic type of NLS appears as multiple, soft, cerebriform papulonodules, which typically coalesce in a linear or segmental distribution. These lesions most often are found in the pelvic girdle region or upper thigh and they are evident at birth or appear within the first two decades of life. The solitary type of NLS presents as a single, soft, pedunculated papule that may be located at any site, more commonly in older adults [2, 3].

Ectopic mature adipose tissue in the reticular dermis is the defining histopathologic feature of NLS [4]. Additional findings include increased vascularity and variable numbers of perivascular spindled and mononuclear cells [4]. Hyperkeratosis, acanthosis, and/or papillomatosis of the overlying epidermis also may be observed and adnexal structures are present.

Proposed theories for the pathogenesis of NLS include adipocyte deposition during embryological development, pericyte differentiation into adipocytes, and degeneration of connective tissue [3]. A 2p24 deletion within NLS has been reported, but the importance of this chromosomal aberration is unclear. Thus far, 2p alterations have been described in a few lipomas but have not been associated with hamartomas; no tumor suppressor genes have been identified in this chromosomal region [5]. Interestingly, NLS has been associated with dilated hair follicles and a variety of adnexal neoplasms, which include cylindromas [6], folliculosebaceous cystic hamartomas [7, 8], and fibrofolliculomas [9]. Goltz syndrome or focal dermal hypoplasia is an X-linked, dominant, genodermatosis that is characterized by replacement of the dermis by adipose tissue [10] as well as abnormal adnexal structures. Considering that the *PORCN* mutations that cause Goltz syndrome lead to decreased signaling via the Wnt pathway, it is possible that abnormal Wnt signaling also has a role in the etiology of NLS.

If desired, surgical excision is the primary method of treatment for NLS. The carbon dioxide laser was successfully employed in a child with widespread lesions [12], but rapid recurrence was observed following use of this modality in an adolescent patient [13]. Repeated intralesional phosphatidylcholine and sodium deoxycholate has also led to resolution of NLS with resulting fibrosis [14]. Our patient underwent surgical excision of several lesions, with no recurrences thus far.

References

1. Hoffman E ZE. Über einen Nävus lipomatosus cutaneus superficialis der linken Glutealgegend. Arch Dermatol 1921; 130: 327
2. Goucha S, *et al.* Nevus lipomatosus cutaneus superficialis: report of eight cases. Dermatol Ther (Heidelb) 2011; 1: 25 [PMID: 22984661]
3. Sendhil Kumaran M, *et al.* Nevus lipomatosus superficialis unseen or unrecognized: a report of eight cases. J Cutan Med Surg 2013; 17: 335 [PMID: 24067854]
4. Jones EW, *et al.* Naevus superficialis lipomatosus: a clinicopathological report of twenty cases. Br J Dermatol 1975; 93: 121 [PMID: 1235780]
5. Cardot-Leccia N, *et al.* Naevus lipomatosus superficialis: a case report with a 2p24 deletion. Br J Dermatol 2007; 156: 380 [PMID: 17223884]
6. Yu R, Alowami S. Cylindroma with stromal adipose tissue metaplasia versus arising in a background of nevus lipomatosus. Case Rep Pathol 2014; 2014: 203298 [PMID: 24744937]
7. Kang H, *et al.* Nevus lipomatosus cutaneus superficialis with folliculosebaceous cystic hamartoma. J Am Acad Dermatol 2007; 56: S55 [PMID: 17224390]
8. Brasanac D, Boricic I. Giant nevus lipomatosus superficialis with multiple folliculosebaceous cystic hamartomas and dermoid cysts. J Eur Acad Dermatol Venereol 2005; 19: 84 [PMID: 15649197]
9. Yun SJ, *et al.* The association of naevus lipomatosus with pilosebaceous abnormalities including fibrofolliculoma. Br J Dermatol 2005; 153: 209 [PMID: 16029355]
10. Gottlieb SK, *et al.* Focal dermal hypoplasia: a nine-year follow-up study. Arch Dermatol 1973; 108: 551 [PMID: 4745291]

11. Liu W, *et al.* Deletion of *Porc1* in mice leads to multiple developmental defects and models human focal dermal hypoplasia (Goltz syndrome). *PLoS One* 2012; 7: e32331 [PMID:22412863]
12. Fatah S, *et al.* Successful CO₂ laser treatment of naevus lipomatosus cutaneous superficialis. *Clin Exp Dermatol* 2010;35:559 [PMID: 20236285]
13. Kim YJ, *et al.* Recurrence of nevus lipomatosus cutaneous superficialis after CO₂ laser treatment. *Arch Plast Surg* 2012; 39: 671 [PMID: 23233898]
14. Kim HS, *et al.* Intralesional phosphatidylcholine and sodium deoxycholate: a possible treatment option for nevus lipomatosus superficialis. *Pediatr Dermatol* 2012; 29: 119