

UCSF

UC San Francisco Previously Published Works

Title

Incidental Detection of Head and Neck Squamous Cell Carcinoma on 68Ga-PSMA-11 PET/CT.

Permalink

<https://escholarship.org/uc/item/2bq3p18m>

Journal

Clinical nuclear medicine, 42(4)

ISSN

0363-9762

Authors

Lawhn-Heath, Courtney
Flavell, Robert R
Glastonbury, Christine
et al.

Publication Date

2017-04-01

DOI

10.1097/rlu.0000000000001569

Peer reviewed

Incidental Detection of Head and Neck Squamous Cell Carcinoma on ^{68}Ga -PSMA-11 PET/CT

Courtney Lawhn-Heath, MD, Robert R. Flavell, MD, PhD, Christine Glastonbury, MBBS, Thomas A. Hope, MD, and Spencer C. Behr, MD

Abstract: We present a case of an incidentally detected squamous cell carcinoma of the oropharynx on ^{68}Ga -PSMA-11 PET. A 71-year-old man's condition was diagnosed as prostate carcinoma after a year of rising serum prostate-specific antigen. The staging ^{68}Ga -PSMA PET/CT demonstrated focal radiotracer uptake in the prostate corresponding to his known primary prostate cancer. However, a PSMA-avid 3.4-cm mass was incidentally found in the right tongue base that was biopsied, confirming squamous cell carcinoma.

Key Words: PSMA, HNSCC, prostate cancer, PET

(*Clin Nucl Med* 2017;42: e218–e220)

Received for publication November 10, 2016; revision accepted December 17, 2016.

From the Department of Radiology and Biomedical Imaging, University of California, San Francisco, CA.

Conflicts of interests and sources of funding: Spencer C. Behr received a research grant from General Electric Healthcare and from Navidea Biopharmaceuticals. Thomas A. Hope received a research grant from General Electric Healthcare. The remaining authors declared no conflict of interest.

Correspondence to: Spencer C. Behr, MD, Department of Radiology and Biomedical Imaging, University of California San Francisco, 505 Parnassus Ave, San Francisco, CA 94143. E-mail: spencer.behr@ucsf.edu.

Copyright © 2017 Wolters Kluwer Health, Inc. All rights reserved.

ISSN: 0363-9762/17/4204–e218

DOI: 10.1097/RLU.0000000000001569

REFERENCES

1. Afshar-Oromieh A, Malcher A, Eder M, et al. PET imaging with a [^{68}Ga] gallium-labelled PSMA ligand for the diagnosis of prostate cancer: biodistribution in humans and first evaluation of tumour lesions. *Eur J Nucl Med Mol Imaging*. 2013;40:486–495.
2. Afshar-Oromieh A, Haberkorn U, Hadaschik B, et al. PET/MRI with a ^{68}Ga -PSMA ligand for the detection of prostate cancer. *Eur J Nucl Med Mol Imaging*. 2013;40:1629–1630.
3. Roethke M, Kuru T, Afshar-Oromieh A, et al. Letter to the Editor NOT referring to a recent journal article. *Eur Urol*. 2013;64:862–864.
4. Afshar-Oromieh A, Avtzi E, Giesel FL, et al. The diagnostic value of PET/CT imaging with the (^{68}Ga)-labelled PSMA ligand HBED-CC in the diagnosis of recurrent prostate cancer. *Eur J Nucl Med Mol Imaging*. 2015;42:197–209.
5. Nomura N, Pastorino S, Jiang P, et al. Prostate specific membrane antigen (PSMA) expression in primary gliomas and breast cancer brain metastases Prostate specific membrane antigen (PSMA) expression in primary gliomas and breast cancer brain metastases. *Cancer Cell Int*. 2014;14:1–9.
6. Sathekge M, Modiselle M, Vorster M, et al. ^{68}Ga -PSMA imaging of metastatic breast cancer. *Eur J Nucl Med Mol Imaging*. 2015;42:1482–1483.
7. Demirci E, Ocak M, Kabasakal L, et al. (^{68}Ga)-PSMA PET/CT imaging of metastatic clear cell renal cell carcinoma. *Eur J Nucl Med Mol Imaging*. 2014;41:1461–1462.
8. Sasikumar A, Joy A, Nanabala R, et al. (^{68}Ga)-PSMA PET/CT imaging in primary hepatocellular carcinoma. *Eur J Nucl Med Mol Imaging*. 2016;43:795–796.
9. Pyka T, Weirich G, Einspieler I, et al. ^{68}Ga -PSMA-HBED-CC PET for differential diagnosis of suggestive lung lesions in patients with prostate cancer. *J Nucl Med*. 2016;57:367–372.
10. Huang YT, Fong W, Thomas P. Rectal carcinoma on ^{68}Ga -PSMA PET/CT. *Clin Nucl Med*. 2016;41:e167–e168.
11. Vamadevan S, Shetty D, Le K, et al. Prostate-specific membrane antigen (PSMA) avid pancreatic neuroendocrine tumor. *Clin Nucl Med*. 2016;41:804–806.
12. Vamadevan S, Le K, Bui C, et al. Prostate-specific membrane antigen uptake in small cleaved b-cell follicular non-Hodgkin lymphoma. *Clin Nucl Med*. 2016;41:980–981.
13. Taywade SK, Damle NA, Bal C. PSMA expression in papillary thyroid carcinoma: opening a new horizon in management of thyroid cancer? *Clin Nucl Med*. 2016;41:e263–e265.
14. Kanthan GL, Hsiao E, Kneebone A, et al. Desmoid tumor showing intense uptake on ^{68}Ga PSMA-HBED-CC PET/CT. *Clin Nucl Med*. 2016;41:508–509.
15. Chan M, Schembri GP, Hsiao E. Serous cystadenoma of the pancreas showing uptake on ^{68}Ga PSMA PET/CT. *Clin Nucl Med*. 2017;42:56–57.
16. Artigas C, Alexiou J, Garcia C, et al. Paget bone disease demonstrated on (^{68}Ga)-PSMA ligand PET/CT. *Eur J Nucl Med Mol Imaging*. 2016;43:195–196.
17. Noto B, Vrachimis A, Schäfers M, et al. Subacute stroke mimicking cerebral metastasis in ^{68}Ga -PSMA-HBED-CC PET/CT. *Clin Nucl Med*. 2016;41:e449–e451.
18. Gykiere P, Goethals L, Everaert H. Healing sacral fracture masquerading as metastatic bone disease on a ^{68}Ga -PSMA PET/CT. *Clin Nucl Med*. 2016;41:e346–e347.
19. Kobe C, Maintz D, Fischer T, et al. Prostate-specific membrane antigen PET/CT in splenic sarcoidosis. *Clin Nucl Med*. 2015;40:897–898.

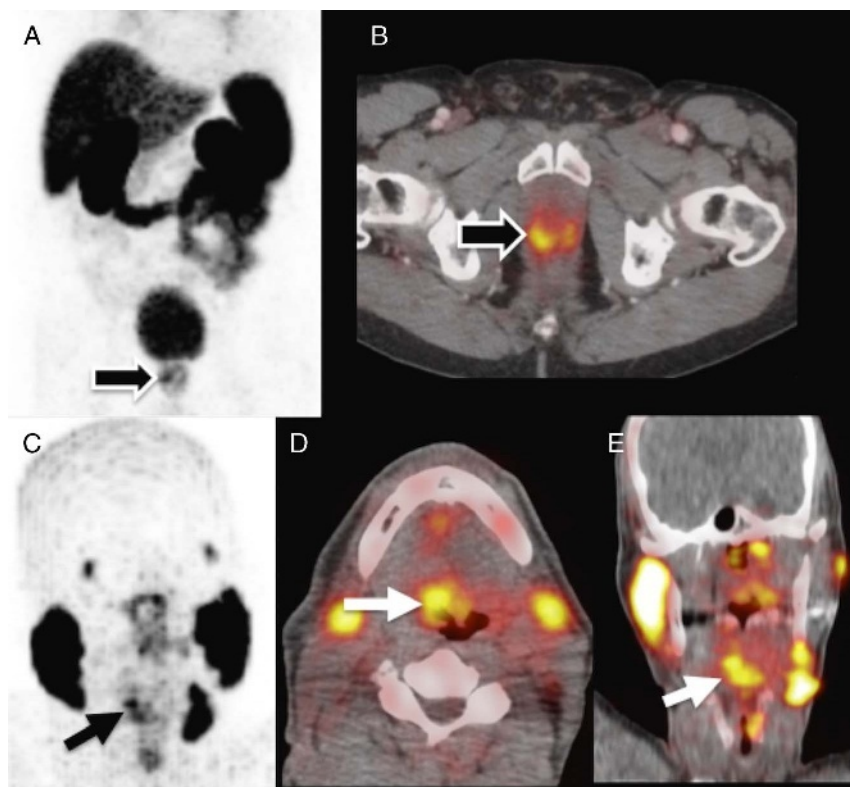


FIGURE 1. A 71-year-old man's condition was diagnosed as prostate carcinoma (Gleason 4 + 3) after a year of rising serum prostate-specific antigen (PSA) from 6.7 to 10.7 ng/mL. A ^{68}Ga -PSMA PET/CT was performed for initial staging. PET images were acquired 60 minutes after injection of 3.8 mCi (140.6 MBq). MIP PET (A) and axial fused PET/CT PET (B) images demonstrate focal radiotracer uptake (SUVmax, 6.9) in the prostate corresponding to his known primary prostate cancer (black arrow). There was no evidence of nodal or osseous PSMA avid metastatic disease. However, a PSMA avid (SUVmax, 7.9), 3.4-cm mass was incidentally found in the right oropharynx on the PET MIP images (C) that corresponded to the right base of tongue on the axial (black arrow) (D) and coronal (E) fused ^{68}Ga -PSMA PET/CT images (white arrow). Upon review of the patient's medical record, the patient's history was also significant for squamous cell carcinoma of unknown primary involving right-sided cervical lymph nodes found after right neck dissection and submandibulectomy 8 years before presentation at our institution.

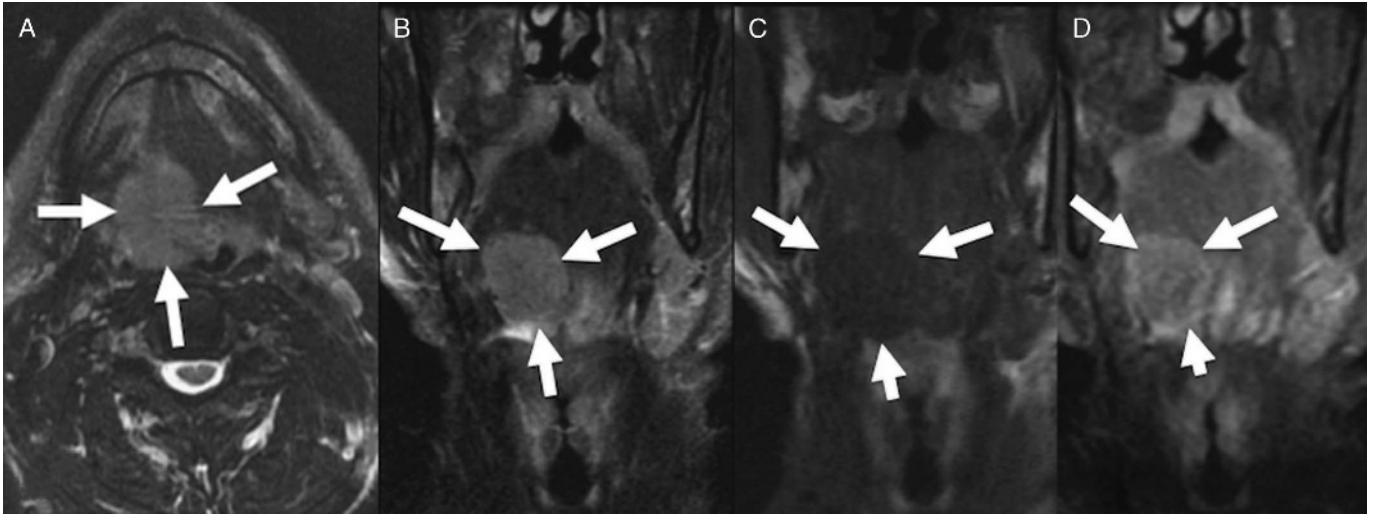


FIGURE 2. Follow-up MRI was obtained through the neck for further evaluation of the PSMA abnormality. Axial T2 (A), coronal T2 (B), coronal T1 precontrast (C), and coronal T2 postcontrast (D) MRI images demonstrate a large mass in the base of the right tongue (white arrows). Biopsy revealed invasive nonkeratinizing squamous cell carcinoma. ^{68}Ga -PSMA-11 is an investigational agent, which has been recently introduced for imaging patients with prostate cancer and shows promising results.¹⁻⁴ Whereas most PSMA imaging has been performed in prostate cancer, PSMA expression has been described in nonprostate malignancies such as breast cancer and primary gliomas,⁵ with recent case reports of [^{68}Ga]PSMA-11 uptake in breast carcinoma,⁶ clear cell renal cell carcinoma,⁷ hepatocellular carcinoma,⁸ and primary lung adenocarcinoma.⁹ The case presented here demonstrates that ^{68}Ga -PSMA-11 PET/CT can detect head and neck squamous cell carcinoma. Our case further highlights that PSMA is not as specific as originally believed and uptake can be found in many other types of neoplasms⁵⁻¹⁵ as well as benign pathologies.¹⁶⁻¹⁹