

# UC Davis

## Dermatology Online Journal

### Title

Multiple eruptive dermatofibromas associated with pregnancy- a case and literature review

### Permalink

<https://escholarship.org/uc/item/29d3q6p1>

### Journal

Dermatology Online Journal, 25(5)

### Authors

Queirós, Catarina

Uva, Luís

Soares de Almeida, Luís

et al.

### Publication Date

2019

### DOI

10.5070/D3255044074

### Copyright Information

Copyright 2019 by the author(s). This work is made available under the terms of a Creative Commons Attribution-NonCommercial-NoDerivatives License, available at

<https://creativecommons.org/licenses/by-nc-nd/4.0/>

Peer reviewed

# Multiple eruptive dermatofibromas associated with pregnancy- a case and literature review

Catarina Queirós<sup>1</sup>, Luís Uva<sup>1</sup>, Luís Soares de Almeida<sup>1,2</sup>, Paulo Filipe<sup>1,2</sup>

Affiliations: <sup>1</sup>Serviço de Dermatologia e Venereologia, Hospital de Santa Maria, Centro Hospitalar e Universitário de Lisboa Norte, Lisboa, Portugal, <sup>2</sup>Instituto de Medicina Molecular, Unidade de Investigação em Dermatologia, Faculdade de Medicina da Universidade de Lisboa, Lisboa, Portugal

Corresponding Author: Catarina Queirós, Serviço de Dermatologia do Hospital de Santa Maria, Avenida Professor Egas Moniz, 1649-035, Lisboa, Portugal, Tel: 351-918263531, Email: [catarina.squeiros@gmail.com](mailto:catarina.squeiros@gmail.com)

## Abstract

Dermatofibromas are common and asymptomatic benign histiocytic tumors. The occurrence in a small number (up to 5 lesions) is frequent. However, the expression “multiple eruptive dermatofibromas” is reserved for the appearance of more than 5 lesions in less than four months. Multiple eruptive dermatofibromas are rare and usually associated with an underlying systemic condition, the most common being autoimmune diseases or HIV infection. Herein we report multiple eruptive dermatofibromas developing in an otherwise healthy pregnant woman. Although the pathogenesis of this condition remains unknown, it is believed to be related to immunological alterations, given the strong association with states of immunosuppression or, in the case of pregnancy, with a state of immunotolerance.

*Keywords: dermatofibroma, pregnancy, immune-mediated diseases, immunosuppression*

## Introduction

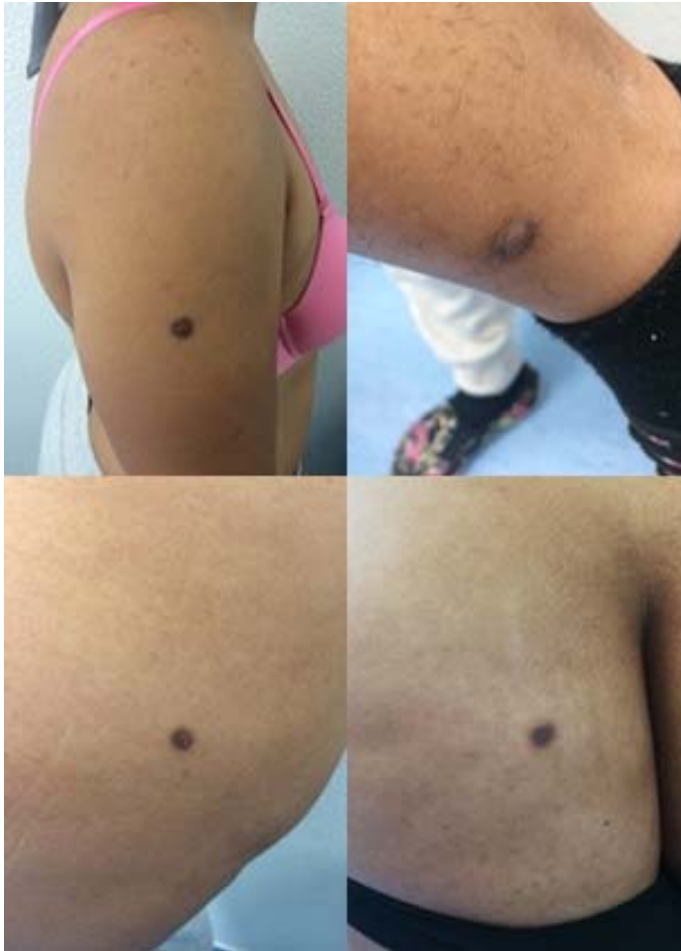Dermatofibromas (DF) are benign histiocytic tumors whose pathogenesis is not totally understood [1]. They usually present as one or a few hyperpigmented papules or nodules on the limbs, with no associated symptoms [2]. The occurrence of multiple DF is rare and has been reported mainly in association with autoimmune diseases, states of immunosuppression, and some systemic therapies

[3]. We report a woman who developed multiple dermatofibromas in association with pregnancy.

## Case Synopsis

We report a 40-year-old woman with an unremarkable past medical history, who was referred to our dermatology clinic because of the appearance of multiple asymptomatic papules and nodules over a period of one month. She denied taking any medication and there were no other associated symptoms. Physical examination revealed nine hyperpigmented dermal papules and nodules, with sizes ranging between 2 and 8mm (**Figure 1**). The “dimple sign” was observed when lateral pressure was applied to the lesions. Dermoscopy revealed a faint pigmented network surrounding a pale central amorphous area (**Figure 2**). Three of the lesions were excised and histopathologic examination revealed a proliferation of fibrohistiocytic cells in the upper half of the dermis, with presence of a Grenz zone, epidermal hyperplasia, and hyperpigmentation of the basal cell layer (**Figure 3**).

The diagnosis of multiple dermatofibromas was made based on the findings of clinical, dermoscopic, and histopathological examinations. Laboratory tests were conducted to rule out an associated systemic condition. Complete blood cell count and general biochemistry and thyroid function studies showed normal results. Serologies for human immunodeficiency virus, hepatitis B and C, anti-



**Figure 1.** Dermatofibromas. Multiple hyperpigmented papules and nodules distributed all over the skin surface.

nuclear antibodies, and double-stranded DNA antibodies were all negative.

Two weeks after the first evaluation, the patient returned to the hospital complaining of supra-pubic pain. A gynecological ultrasound was performed, revealing a gestational sac with an embryo aged 6 weeks and 6 days. The patient remained under close follow-up and some new lesions appeared during the rest of the pregnancy. After delivery, all the lesions remained stable and no new ones have developed in the following 6 months.

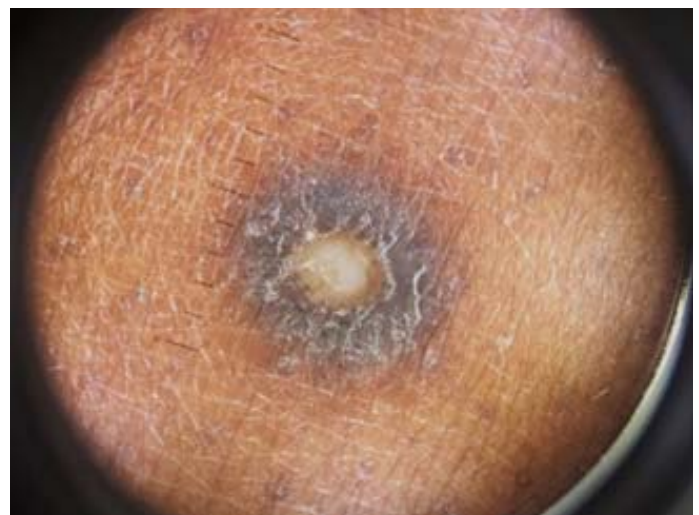
### Case Discussion

Dermatofibromas or benign fibrous histiocytomas are dermal growths usually presenting as hyperpigmented papules or nodules with no associated symptoms [3]. They are more common in women between the third and fifth decade of life

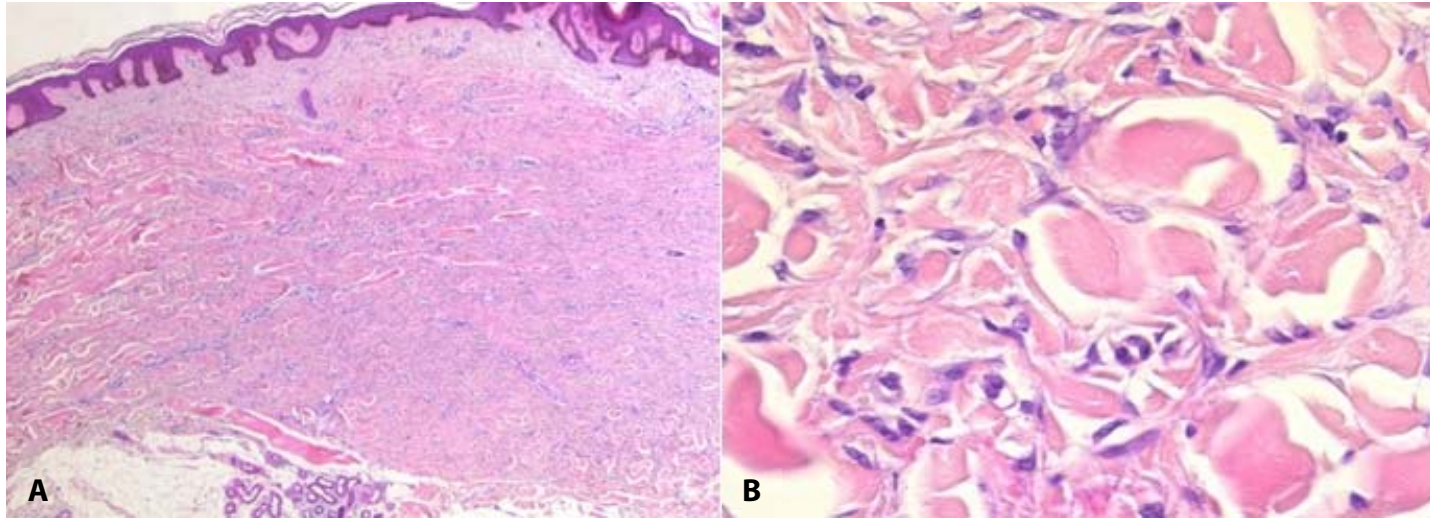
and usually arise on the legs [4-6]. The precise mechanism for the development of DF is not currently known. They may represent a neoplastic process (as demonstrated by its clonal proliferative growth and no spontaneous regression) or a reactive tissue change (secondary to trauma after an insect bite or prior folliculitis), [7, 8].

The diagnosis of DF is usually based on clinical and dermoscopic findings, but the only way of confirming it is by histopathology. On microscopic examination, DF are dermal tumors characterized by a proliferation of fibrohistiocytic cells with an overlying "Grenz" zone of sparing, without mitosis or necrosis. There is also entrapment of collagen at the periphery of the lesion and the overlying epidermis may be acanthotic with increased basal layer pigmentation. Immunohistochemistry staining for factor XIIIa is usually positive [1, 6]. This is a marker of fibrohistiocytic proliferation, usually positive in dermal dendrocytes and useful to differentiate dermatofibrosarcoma protuberans from dermatofibroma. In general, these lesions require no treatment apart from reassurance.

The presence of one or a few DF is common, as opposed to the appearance of multiple lesions over a short period of time. This variant, called multiple eruptive dermatofibromas (MEDF), was first described in 1970 [9] and is usually defined as the appearance of 5 to 8 DF within a period of four months [10]. MEDF are estimated to occur in less



**Figure 2.** Dermoscopy of a dermatofibroma showing a faint pigmented network surrounding a pale central area.



**Figure 3.** Dermatofibroma. **A)** Histopathologic examination showing a non-encapsulated nodule that occupies the upper half of the dermis. **B)** This nodule is mainly composed of spindle cells, with entrapment of collagen fibers. H&E, **A)** 40 $\times$ , **B)** 400 $\times$ .

than 1% of patients with DF [11] and are associated with an underlying systemic condition in at least two-thirds of the cases [12-14]. In 80% of the cases, this underlying condition is related to some immunologic disturbance [12].

In this sense, the most frequent associations are with autoimmune diseases (namely systemic lupus erythematosus, dermatomyositis, or Sjögren syndrome), states characterized by immune-suppression (either immunosuppressive medications or HIV infection) and hematologic malignancies [3]. Other reported underlying conditions include pulmonary hypertension, atopic dermatitis, Down syndrome, and hypertriglyceridemia [3].

To the best of our knowledge, the association of MEDF with pregnancy has been reported only in one patient [15]. This was a 25-year-old woman who presented four months postpartum complaining of the development of multiple pigmented skin lesions during her preceding pregnancy. The lesions were asymptomatic and the diagnosis of dermatofibromas was confirmed by histopathologic examination. Treatment with cryotherapy was performed and the patient remained well and with no new lesions after 17 months of follow-up [15].

The aforementioned association between MEDF and immune-mediated diseases or states of

immunosuppression strongly suggests that immune mechanisms may be involved in the development of this condition [16]. In fact, it has been proposed that MEDF may represent an abortive immunoreactive process mediated by dermal dendritic cells in the setting of an inhibition of down-regulatory T cells [16]. In other words, it is possible that in the genesis of MEDF a putative antigen is involved, which cannot be cleared from the skin by the suppressed immune system, leading to the development of these characteristic skin lesions [17]. In this way, MEDF have been described as a possible manifestation of a subjacent condition associated with immunosuppression [12].

Pregnancy has traditionally been considered "the greatest paradox of all the laws of tissue transplantation," as a human fetal allograft survives and grows in a potentially hostile immunological environment [15]. Indeed, it is known that pregnancy is associated with a state of materno-fetal tolerance comprising several mechanisms, which are just beginning to be understood. In this field, increasing attention is recently being given to the importance of regulatory T cells [18]. According to this immune mechanism, the development of MEDF in the setting of pregnancy can be considered as a manifestation of this altered immunity.

## Conclusion

Multiple eruptive dermatofibromas are rare but may be the first manifestation of several underlying conditions. Although its pathogenesis has not been completely elucidated, it is believed that impaired immune function plays an important role in their development. In any patient presenting with MEDF, it is important to search for associated conditions or

underlying diseases. Systemic lupus erythematosus and HIV infection should be sought in patients presenting with MEDF. In women, pregnancy should also be assessed.

## Potential conflicts of interest

The authors declare no conflicts of interests.

## References

1. Parish, L.C., et al., Dermatofibroma: a curious tumor. *Skinmed*, 2012. 10:268-70. [PMID: 23163067].
2. Wolff, K., et al., Fitzpatrick's Dermatology in General Medicine: Dermal hypertrophies. 7th ed.. 2008, New York: Mc Graw-Hill.
3. Beatrous, S.V., et al., Associated conditions in patients with multiple dermatofibromas: Case reports and literature review. *Dermatol Online J*, 2017. 23. [PMID: 29469716].
4. Pinto-Almeida, T., et al., Congenital multiple clustered dermatofibroma and multiple eruptive dermatofibromas--unusual presentations of a common entity. *An Bras Dermatol*, 2013. 88:63-6. [PMID: 24346882].
5. Han, T.Y., et al., A clinical and histopathological study of 122 cases of dermatofibroma (benign fibrous histiocytoma). *Ann Dermatol*, 2011. 23:185-92. [PMID: 21747617].
6. Abdellatif, E. Benign fibrous histiocytoma (superficial). *Pathology Outlines*, 2018. Available from: <http://www.pathologyoutlines.com/topic/softtissuebfh.html>. Accessed 3rd December 2018.
7. Chen, T.C., T. Kuo, and H.L. Chan, Dermatofibroma is a clonal proliferative disease. *J Cutan Pathol*, 2000. 27:36-9. [PMID: 10660130].
8. Watanabe, K., et al., Multiple dermatofibromas subsequent to folliculitis. *Eur J Dermatol*, 2013. 23:890-1. [PMID: 24185196].
9. Baraf, C.S. and L. Shapiro, Multiple histiocytomas. Report of a case. *Arch Dermatol*, 1970. 101:588-90. [PMID: 4315412].
10. Ammirati, C.T., C. Mann, and I.K. Hornstra, Multiple eruptive dermatofibromas in three men with HIV infection. *Dermatology*, 1997. 195:344-8. [PMID: 9529554].
11. Massone, C., et al., Multiple eruptive dermatofibromas in patients with systemic lupus erythematosus treated with prednisone. *Int J Dermatol*, 2002. 41:279-81. [PMID: 12100703].
12. Her, Y., S.H. Ku, and K.H. Kim, A case of multiple eruptive dermatofibromas in a healthy adult. *Ann Dermatol*, 2014. 26:539-40. [PMID: 25143694].
13. Marque, M., et al., Multiple familial "eruptive" dermatofibromas. *Ann Dermatol Venereol*, 2013. 140:452-4. [PMID: 23773744].
14. Zaccaria, E., A. Rebora, and F. Rongioletti, Multiple eruptive dermatofibromas and immunosuppression: report of two cases and review of the literature. *Int J Dermatol*, 2008. 47:723-7. [PMID: 18613883].
15. Stainforth, J. and M.J. Goodfield, Multiple dermatofibromata developing during pregnancy. *Clin Exp Dermatol*, 1994. 19:59-60. [PMID: 8313640].
16. Niiyama, S., et al., Multiple eruptive dermatofibromas: a review of the literature. *Acta Derm Venereol*, 2002. 82:241-4. [PMID: 12361125].
17. Nestle, F.O., B.J. Nickoloff, and G. Burg, Dermatofibroma: an abortive immunoreactive process mediated by dermal dendritic cells? *Dermatology*, 1995. 190:265-8. [PMID: 7655103].
18. Guleria, I. and M.H. Sayegh, Maternal acceptance of the fetus: true human tolerance. *J Immunol*, 2007. 178:3345-51. [PMID: 17339426].