

UC Irvine

UC Irvine Previously Published Works

Title

Osimertinib tolerance in a patient with Stevens Johnson syndrome during osimertinib therapy after treatment with pembrolizumab.

Permalink

<https://escholarship.org/uc/item/29c7g4w9>

Journal

Allergy Asthma and Clinical Immunology, 19(1)

ISSN

1710-1484

Authors

Lopez, Michael
Hagopian, Garo
Lee, Benjamin
et al.

Publication Date

2023-10-28

DOI

10.1186/s13223-023-00849-5

Copyright Information

This work is made available under the terms of a Creative Commons Attribution License, available at <https://creativecommons.org/licenses/by/4.0/>


Peer reviewed

CASE REPORT

Open Access



Osimertinib tolerance in a patient with Stevens Johnson syndrome during osimertinib therapy after treatment with pembrolizumab

Michael Lopez^{1†}, Garo Hagopian^{2†}, Linda Doan³, Benjamin J. Lee⁴, Nathan W. Rojek³, Janellen Smith³, Sai-Hong Ignatius Ou², Yesim Yilmaz Demirdag^{1*}  and Misako Nagasaka²

Abstract

Background Osimertinib has emerged as an important tool in the treatment of non-small cell lung cancers (NSCLC) with certain activating mutations of epidermal growth factor receptor (EGFR). However, Osimertinib may cause adverse effects, including severe cutaneous adverse reactions (SCARs) such as Stevens-Johnson syndrome (SJS) and toxic epidermal necrolysis (TEN). The risk of certain adverse effects may be increased in the setting of recent use of immune checkpoint inhibitor (ICI) therapy, although it is unclear whether recent use of ICI therapy is a risk factor for Osimertinib-induced SJS specifically.

Case presentation We present a patient with EGFR L858R mutation-positive metastatic NSCLC who developed Osimertinib-induced SJS after recent administration of eight cycles of a pembrolizumab-containing chemotherapy regimen. Osimertinib, which was the best treatment targeting his lung cancer, was avoided due to history of SJS. Four years later, because of unresponsiveness or side effects of alternative treatments, he underwent Osimertinib challenge and tolerated it.

Conclusion This case highlights the importance of multi-disciplinary care and supports the hypothesis that the risk of SJS to Osimertinib is significantly higher in the context of recent administration of ICI therapy and, patients may tolerate Osimertinib after certain time has elapsed after the last dose of ICI.

[†]Dr Lopez and Dr Hagopian contributed to this case equally.

*Correspondence:

Yesim Yilmaz Demirdag
dryesimyilmaz@gmail.com

¹Division of Basic and Clinical Immunology, Department of Medicine,
University of California, Irvine, USA

²Division of Hematology and Oncology, Department of Medicine,
University of California, Irvine, USA

³Department of Dermatology, University of California, Irvine, USA

⁴Department of Pharmacology, University of California, Irvine, USA



Case report

Osimertinib, a third-generation epidermal growth factor receptor- tyrosine kinase inhibitor (EGFR-TKI), has emerged as an important treatment for non-small cell lung cancer (NSCLC). Compared to other EGFR-TKIs, Osimertinib has been associated with less severe and less frequent dermatologic side effects such as pruritus, xerosis, acneiform rash, paronychia, although rare cases of severe cutaneous adverse reactions (SCAR) have been reported [1–3]. The risk of adverse effects may be increased in the setting of recent use of immune checkpoint inhibitors (ICIs) such as pembrolizumab [4]. Here, we report a 63-year-old Vietnamese man who tolerated Osimertinib despite having experienced Stevens Johnson Syndrome (SJS) four years prior during Osimertinib treatment which was initiated 2 weeks after the last dose of an ICI, pembrolizumab.

The patient was diagnosed with EGFR L858R mutation-positive NSCLC with bone metastasis and received

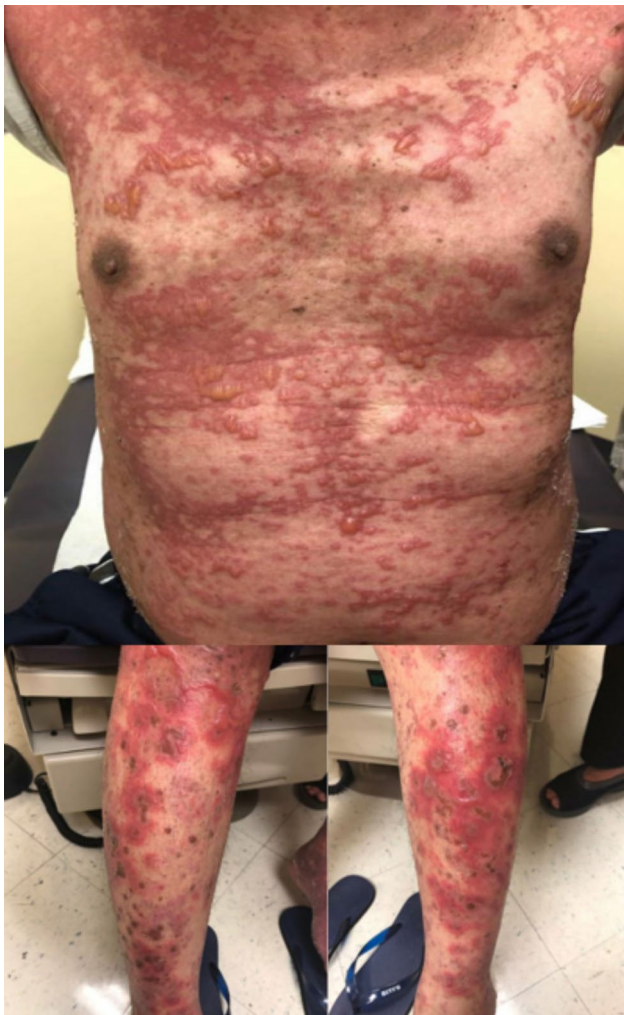

Fig. 1 Osimertinib-induced SJS/TEN in a 63-year-old man with non-small cell lung cancer

8 cycles of pemetrexed and pembrolizumab therapy. He was then transitioned to Osimertinib starting 2 weeks after the last cycle of pembrolizumab. However, 5 weeks after the initiation of Osimertinib he was hospitalized with diffuse skin eruption consistent with urticarial violaceous papules coalescing into plaques with tense bullae and erosions on his palms and soles (Fig. 1). He also developed sores on his lips and experienced painful swallowing and blurry vision. A skin biopsy demonstrated bullous eruption that was concerning for early SJS/TEN (toxic epidermal necrolysis) (Fig. 2). Osimertinib was discontinued and symptoms slowly resolved with supportive care. He received radiation, and then gemcitabine to control his cancer. Four years later, given the lack of suitable therapeutic options and disease progression, Osimertinib desensitization was attempted starting at 0.02 mg/day reaching the final dose of 80 mg in 25 days. However, 4 days after reaching 80 mg/day dose, patient developed erythematous papules and irritation feeling inside of his lips without any objective mucosal findings. Given concern for a possible early SJS, Osimertinib was discontinued, intramuscular methylprednisolone was administered, and the patient was prescribed a short course of prednisone. The rash and mucosal symptoms resolved within 2 weeks. His cancer, however, continued to progress, requiring radiation therapy for painful lymphadenopathy in the bilateral cervical and left axillary regions. Due to the mild reaction observed during the desensitization, and lack of treatment alternatives, five weeks after the last dose of Osimertinib, a shared decision was made for the patient to undergo an outpatient Osimertinib challenge. The starting dose was 40 mg daily reaching the goal dose of 80 mg daily over 5 weeks. At the time of the preparation of this manuscript, the patient has been tolerating Osimertinib 80 mg daily for approximately 6 months without any signs or symptoms of SJS or other SCARs.

Discussion and conclusions

Significant immune-related adverse events such as pneumonitis have been reported during EGFR-TKI treatment. Osimertinib, a third generation EGFR-TKI, is associated with less severe and less frequent adverse events although the risk is increased after exposure to ICIs [4]. Osimertinib tolerance was reported about 8 months after the development of pneumonitis during Osimertinib treatment which was preceded by an ICI therapy in a patient with lung cancer [5]. Interestingly, successful Osimertinib rechallenges have also been observed in 8 patients who developed Osimertinib-induced pneumonitis and in 1 patient who developed Osimertinib-induced hepatotoxicity without prior ICI therapy [6, 7]. According to these studies, in patients who experienced Osimertinib-induced pneumonitis, the median interval from the first

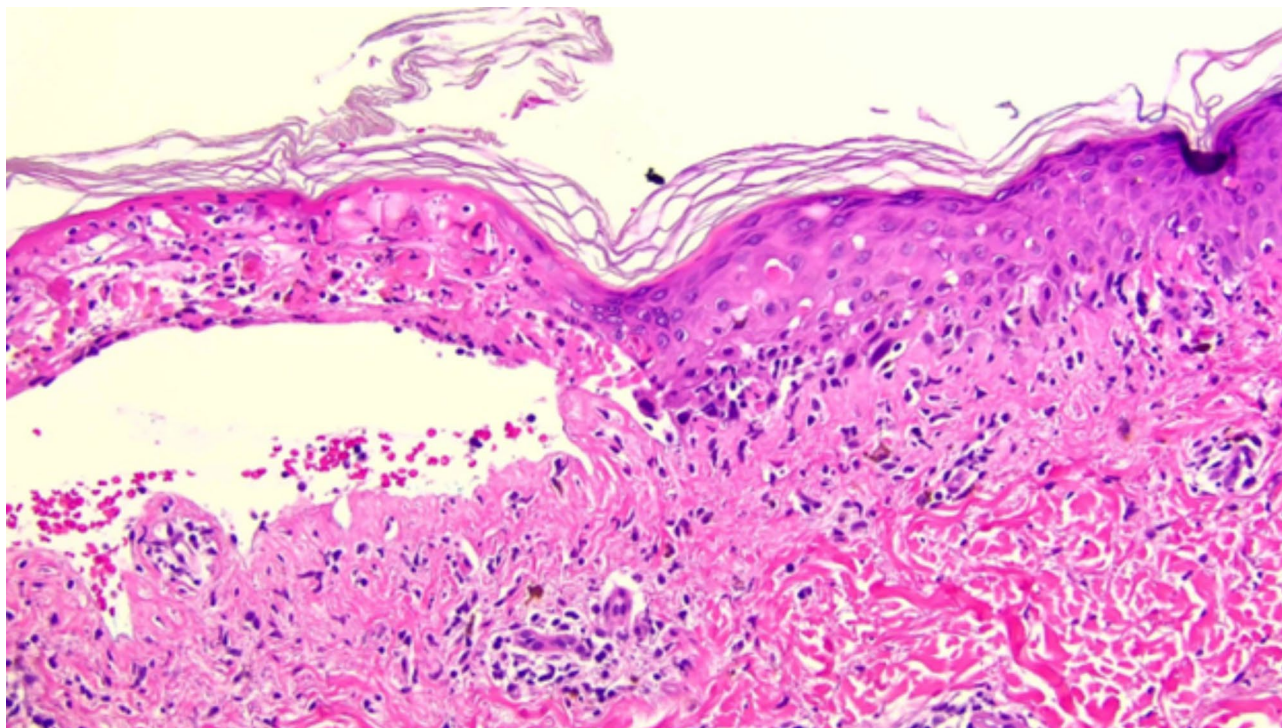


Fig. 2 200x magnification. Skin biopsy demonstrating interface dermatitis with eosinophils, necrotic keratinocytes, and full-thickness epidermal necrosis, compatible with SJS/TEN in a 63-year-old man with non-small cell lung cancer

Osimertinib course and Osimertinib re-challenge was 6.3 months. In the case of Osimertinib-induced hepatotoxicity, Osimertinib was restarted at 8 mg/day which was considered as desensitization dose, about 5 weeks after it was discontinued due to worsening of liver function. These reports suggest that the duration between treatments may play a role in tolerability of Osimertinib re-challenge.

SCARs associated with Osimertinib with or without prior ICI exposure have been reported in only a few cases [2, 3, 8, 9]. Successful reintroduction of Osimertinib in our patient may suggest that prior ICI therapy contributed to the development of SJS during Osimertinib treatment. However, we cannot exclude the potential contribution of other factors, such as the time elapsed (four years) since the initial reaction. To our knowledge, this is the first successful reintroduction of Osimertinib in a patient with a remote history of Osimertinib-induced SJS in the setting of recent ICI therapy.

Acknowledgements

The authors would like to thank the patient and his family.

Authors' contributions

ML, GH, YYD, MN, LD, NWR, JS and SIO performed the clinical evaluation of the patient. ML and YYD prepared the drug desensitization protocol. BL carried out drug preparation. ML, GH, YYD and MN wrote the manuscript.

Funding

None.

Data Availability

All materials are included in this article.

Declarations

Ethics approval and consent to participate

Not applicable.

Consent for publication

Written consent was obtained from the patient to publish this case report including the figures.

Competing interests

There are no known conflicts of interest associated with this publication.

Received: 27 August 2023 / Accepted: 7 October 2023

Published online: 28 October 2023

References

1. Chu CY, Choi J, Eaby-Sandy B, Langer CJ, Lacouture ME. Osimertinib: a novel dermatologic adverse event Profile in patients with Lung Cancer. *Oncologist*. 2018;23(8):891–9.
2. Sato I, Mizuno H, Kataoka N, Kunimatsu Y, Tachibana Y, Sugimoto T et al. Osimertinib-Associated toxic epidermal necrolysis in a Lung Cancer Patient harboring an EGFR Mutation-A Case Report and a review of the literature. *Med (Kaunas)*. 2020;56(8).
3. Lin YT, Chu CY. Osimertinib-induced Stevens-Johnson syndrome in a patient with EGFR T790M mutation-positive non-small cell Lung cancer. *Lung Cancer*. 2019;129:110–1.
4. Schoenfeld AJ, Arbour KC, Rizvi H, Iqbal AN, Gadgeel SM, Girshman J, et al. Severe immune-related adverse events are common with sequential PD-(L)1 blockade and Osimertinib. *Ann Oncol*. 2019;30(5):839–44.

5. Mamesaya N, Kenmotsu H, Takahashi T. Successful Osimertinib rechallenge in a patient with advanced non-small cell Lung cancer following Osimertinib-induced interstitial lung Disease after treatment with nivolumab. *Invest New Drugs*. 2017;35(6):839–41.
6. Kodama H, Wakuda K, Yabe M, Nishioka N, Miyawaki E, Miyawaki T, et al. Retrospective analysis of Osimertinib re-challenge after Osimertinib-induced interstitial lung Disease in patients with EGFR-mutant non-small cell lung carcinoma. *Invest New Drugs*. 2021;39(2):571–7.
7. Yoshida H, Kim YH. Successful Osimertinib rechallenge after severe Osimertinib-Induced Hepatotoxicity. *J Thorac Oncol*. 2017;12(5):e61–e3.
8. Gianni C, Bronte G, Delmonte A, Burgio MA, Andrikou K, Monti M, et al. Case Report: Stevens-Johnson Syndrome and Hepatotoxicity Induced by Osimertinib Sequential to Pembrolizumab in a patient with EGFR-Mutated lung adenocarcinoma. *Front Pharmacol*. 2021;12:672233.
9. Cui W, Cotter C, Sreter KB, Heelan K, Creamer D, Basu TN, et al. Case of Fatal Immune-related skin toxicity from sequential use of Osimertinib after Pembrolizumab: lessons for drug sequencing in Never-Smoking Non-small-cell Lung Cancer. *JCO Oncol Pract*. 2020;16(12):842–4.

Publisher's Note

Springer Nature remains neutral with regard to jurisdictional claims in published maps and institutional affiliations.