

# UC Davis

## Dermatology Online Journal

### Title

Acne agminata: dermoscopic features and a short review

### Permalink

<https://escholarship.org/uc/item/29b1f3np>

### Journal

Dermatology Online Journal, 28(6)

### Authors

Tan, Wen Hao  
Goh, Jia Yi  
Busmanis, Inny  
et al.

### Publication Date

2022

### DOI

10.5070/D328659725

### Copyright Information

Copyright 2022 by the author(s). This work is made available under the terms of a Creative Commons Attribution-NonCommercial-NoDerivatives License, available at <https://creativecommons.org/licenses/by-nc-nd/4.0/>

Peer reviewed

# Acne agminata: dermoscopic features and a short review

Wen Hao Tan<sup>1\*</sup> MBBS MRCP, Jia Yi Goh<sup>1\*</sup> MBBS, Inny Busmanis<sup>2</sup> MBBS FRCPA, Choon Chiat Oh<sup>1</sup> MBBS FRCP

\*Authors contributed equally

Affiliations: <sup>1</sup>Department of Dermatology, Singapore General Hospital, Singapore, <sup>2</sup>Department of Anatomical Pathology, Singapore General Hospital, Singapore

Corresponding Author: Choon Chiat Oh, 20 College Road, Singapore 168856, Tel: 65-6326 6866, Email: [oh.choon.chiat@singhealth.com.sg](mailto:oh.choon.chiat@singhealth.com.sg)

## Abstract

Acne agminata is a rare idiopathic inflammatory dermatosis. Treatment is variable with no clear consensus. We herein report a case of a 31-year-old man with sudden onset papulonodular eruptions on his face over two months. Histopathological examination revealed superficial granuloma composed of epithelioid histiocytes and scattered multinucleated giant cells, confirming acne agminata. Dermoscopy showed focal orangish structureless areas with follicular openings with white keratotic plugs. He achieved complete clinical resolution with oral prednisolone in 6 weeks. We also reviewed the literature regarding the reported treatment regimens used.

*Keywords: acne agminata, corticosteroid, facial nodules, granuloma, papulonodular eruption*

## Introduction

Acne agminata is a rare idiopathic inflammatory dermatosis first reported by Fox in 1878 [1]. As reported in the literature, treatment is variable with inconsistent results. There is also no clear consensus on therapeutics. Herein, we report a successful case of acne agminata treated with oral prednisolone. We also discuss the various treatment options reported in the literature.

## Case Synopsis

A healthy, 31-year-old man presented with a persistent 2-month history of papulo-nodular eruptions on his central face. He had no systemic

symptoms otherwise. Physical examination revealed scattered pink non-blanching, firm papules and nodules over the perioral, nasolabial, and periorbital regions (Figure 1A, B). Dermoscopy showed focal orangish structureless areas with follicular openings filled with round, white keratotic plugs (Figure 2). Skin punch biopsy demonstrated granuloma formation within the superficial dermis. The granulomas, composed of epithelioid histiocytes and scattered multinucleated giant cells were surrounded by a moderate, predominantly lymphocytic chronic inflammatory cell response which also partly extended around the hair follicles (Figure 3). There was central caseation seen. Skin direct immunofluorescence showed positive staining at the dermo-epidermal junction with IgG (1-2+), C3 (1-2+), and fibrin (1+). IgM was negative. Tissue microbiology results for tuberculosis and fungal infection were negative. Routine blood tests and chest radiograph were normal. Autoimmune screen including antinuclear antibody, extractable nuclear antigen antibodies, and anti-double-stranded DNA antibody was negative. In view of the clinical features of facial involvement and

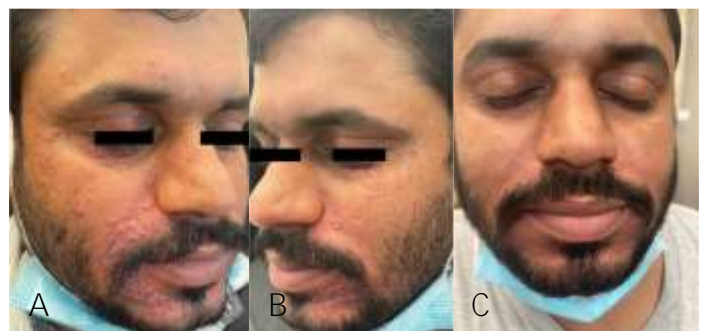

Figure 1. A) Right perioral, nasolabial, and periorbital papules on presentation. B) Similar findings over the left profile of the face. C) Complete resolution after six weeks of oral prednisolone.

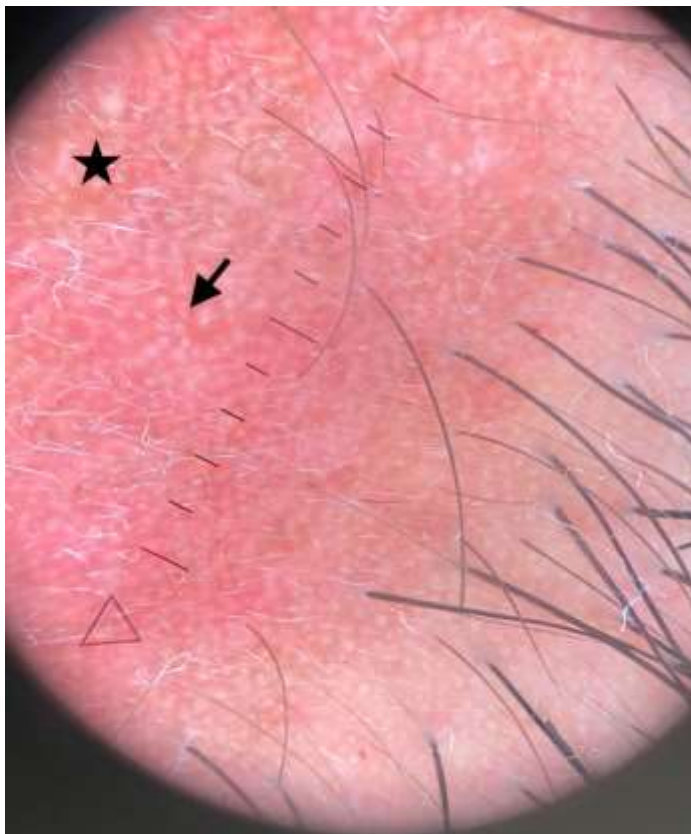


Figure 2. Dermoscopy of the left chin papules showing focal orange structureless areas (star) with follicular openings filled with round and white keratotic plugs (arrow). Dermoscope: Heine DELTAone.

characteristic histopathological features, the diagnosis of acne agminata was made. He was initiated on daily oral prednisolone 40mg (0.5mg/kg) with a tapering course of 5mg every week. Follow-up after six weeks showed almost complete resolution (Figure 1C). Further review at six months showed no recurrence.

## Case Discussion

Acne agminata, also known as lupus miliaris disseminatus faciei (LMDF) or Facial Idiopathic Granulomas with Regressive Evolution (FIGURE), is characterized by multiple, discrete dome-shaped brown-red or brown to yellowish papules distributed over the central face, typically involving the eyelids [2,3]. It commonly presents in young adults, although it has also been reported in children and elderly patients [2]. Cases involving extrafacial areas have been reported, albeit rarely [4]. The duration generally lasts between 12 to 24 months before

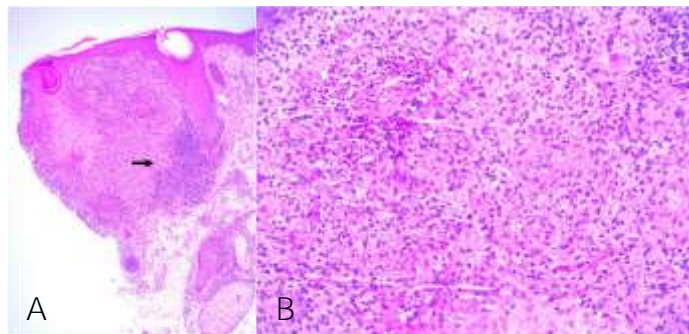


Figure 3. H&E-stained skin biopsy specimens from the right perioral papules showed granuloma formation within the superficial dermis. A) low power, 40 $\times$ ; B) high power, 200 $\times$ .

resolving spontaneously, leaving disfiguring scars but is not associated with systemic involvement [2].

The characteristic dermatoscopic features found in acne agminata include discrete, focal orangish structureless areas located around follicular openings. These openings are often filled with round or elongated, white or yellow keratotic plugs [5]. This pattern arises from the perifollicular granulomatous infiltration with follicular hyperkeratosis. Other less frequent findings are linear and hairpin-like vessels and central ulceration [5].

The pathogenesis is unclear. Although acne agminata was initially believed to be related to tuberculosis because of similar histopathologic features of epithelioid cell granulomas with central necrosis, many studies do not support this association. Acid-fast bacilli (AFB) cultures from these biopsies did not reveal AFB and polymerase chain reaction failed to detect *Mycobacterium tuberculosis* DNA in these cases. *Demodex folliculorum* was also considered a possible cause but not found in most cases [2]. It has been proposed that acne agminata is an expression of an immune response to the pilosebaceous units. It may be an allergic granulomatous reaction to hair follicle destruction or epithelial cysts, although the trigger is unknown [2].

There are various histological stages [6]. The early stage shows infiltrate comprising lymphocytes, few histiocytes, with occasional neutrophils around the blood vessels or appendages. Developed lesions showing perifollicular epithelioid cell granulomas invading the hair follicle are divided into first, second, and third stages. The first stage involves only

Table 1. Comparison between acne agminata and granulomatous rosacea [7].

	Acne agminata	Granulomatous rosacea
Sex	Predominantly male	Predominantly female
Symptoms	Asymptomatic	Flushing, burning sensation
Clinical findings	Discrete erythematous or flesh-colored papules, symmetrically distributed across the face	Discrete, firm, yellow-ish red papules, symmetrically distributed over the face
	Face: Eyelids, nose, upper lips. Extrafacial cases have been reported: axilla, neck, genitalia	Predominantly involving the forehead and cheeks, sparing eyelids
	Absent telangiectasia	Presence of telangiectasia
Histopathology	Caseating granulomas with central necrosis, invading the hair follicle	Non-caseating granulomas in the superficial and mid dermis, adjacent to hair follicles. May manifest as a large, central empty space or may be small palisaded, elastolytic or diffuse
Aggravating factors	None	Sunlight, alcohol, heat
Response to treatment	Mixed response to tetracyclines. Generally responsive to corticosteroid	Responsive to tetracyclines. Corticosteroids may aggravate
Prognosis	Spontaneous resolution in 12-24 months, often with residual scarring	Persistent, chronic. Absent scarring

sarcoid (epithelioid) granulomas. The second stage shows epithelioid granulomas with neutrophilic abscesses, whereas the third stage shows caseation necrosis. Conspicuous hyalinized collagen is found in the late stage [6].

A key entity in the differential diagnosis to acne agminata is granulomatous rosacea. Although the two diseases are distinct entities, they share overlapping features. Both conditions typically involve the face, with acne agminata localizing to the eyelids and periorbital areas with a potential for extra-facial involvement. Granulomatous rosacea, however, generally spares the eyelids and may be a distinguishing feature between the two. The overlapping histopathologic features are epithelioid cell granulomas on the dermis involving the pilosebaceous units. However, caseating necrosis in the granulomas are characteristic of acne agminata and are often lacking in granulomatous rosacea [7]. In our case, the clinical and histological features of central caseation supported our early diagnosis of acne agminata. Table 1 shows the distinguishing features between the two diseases [7].

A table of case reports regarding acne agminata and the proposed therapies is summarized in [Table 2](#). Oral prednisolone, tetracyclines, isotretinoin, and topical tacrolimus are reported as possible options for treatment, although with inconsistent results [2].

Alternative therapies include injectable corticosteroids, erythromycin, dapsone, clofazimine, and 595nm pulsed-dye laser [2,8]. Dapsone has also been reported to shorten the course of the disease, reducing the risk of disfiguring scars [2].

In recent years, apremilast, a phosphodiesterase 4 inhibitor that downregulates pro-inflammatory mediators (tumor necrosis factor, interferon  $\gamma$ , and interleukins IL2, IL12, and IL23), has shown to be an emerging therapeutic option with reported clinical improvement within four weeks [9]. TNF inhibitor infliximab was also recently reported to be effective in refractory acne agminata, suggesting the role of TNF and Th1-driven IFN gamma pathways as treatment targets for refractory cases [10].

## Conclusion

This case demonstrates the dermoscopic features of acne agminata, with a good clinical response to oral prednisolone. This case report also provides an updated review of various therapeutic strategies for this condition.

## Potential conflicts of interest

The authors declare no conflicts of interest.

## References

1. Fox T. Disseminated follicular lupus (simulating acne). *Lancet*. 1878;112:5–76. [DOI: 10.1016/S0140-6736(02)42942-X].
2. Al-Mutairi N. Nosology and therapeutic options for Lupus miliaris disseminatus faciei. *J Dermatol*. 2011;38:864-873. [PMID: 21714812].
3. Rocas D, Kanitakis J. Lupus miliaris disseminatus faciei: report of a new case and brief literature review. *Dermatol Online J*. 2013;19:4. [PMID: 23552001].
4. Nemer KM, McGirt LY. Extrafacial lupus miliaris disseminatus. *JAAD Case Rep*. 2016;2:363-365. [PMID: 27699199].
5. Ayhan E, Alabalik U, Avci Y. Dermoscopic evaluation of two patients with lupus miliaris disseminatus faciei. *Clin Exp Dermatol*. 2014;39:500-502. [PMID: 24825140].
6. Sehgal VN, Srivastava G, Aggarwal AK, Belum VR, Sharma S. Lupus miliaris disseminatus faciei. Part I: Significance of histopathologic undertones in diagnosis. *Skinmed*. 2005;4:151-156. [PMID: 15891251].
7. Seo Ji, Shin MK. Lupus miliaris disseminatus faciei versus granulomatous rosacea: a case report. *Case Rep Dermatol*. 2021;13:321-329. [PMID: 34248540].
8. Ma D, Li Q, Jin D, Sun M, Nie X. A case of lupus miliaris disseminatus faciei that was successfully treated with 595 nm pulsed-dye laser combined with drugs. *Dermatol Ther*. 2020;33:e13373. [PMID: 32246556].
9. Kaushik A, Kumaran MS, Chatterjee D, De D. The search for a uniformly effective treatment in patients with lupus miliaris disseminatus faciei. *JAMA Dermatol*. 2020;156:841-842. [PMID: 28710244].
10. Alexanian C, Liakos W, Toussi A, et al. Immune profiling of lupus miliaris disseminatus faciei and successful management with anti-tumour necrosis factor therapy. *Clin Exp Dermatol*. 2021;46:910-914. [PMID: 33864395].
11. Dekio S, Jidoi J, Imaoka C. Lupus miliaris disseminatus faciei--report of a case in an elderly woman. *Clin Exp Dermatol*. 1991;16:295-296. [PMID: 1794175].
12. Moloney FJ, Egan CA. Case 3. Acne agminata (lupus miliaris disseminatus faciei). *Clin Exp Dermatol*. 2003;28:685-686. [PMID: 14616852].
13. Goh BK, Tan HH. Doxycycline in the treatment of acne agminata. *Clin Exp Dermatol*. 2003;28:677-679. [PMID: 14616848].
14. Litaïem N, Chamli A, Bacha T, et al. Dermoscopic features of lupus miliaris disseminatus faciei: Distinct aspects depending on disease stage. *Clin Case Rep*. 2020;8:1793-1796. [PMID: 32983497].
15. Uesugi Y, Aiba S, Usuba M, Tagami H. Oral prednisone in the treatment of acne agminata. *Br J Dermatol*. 1996;134:1098-1100. [PMID: 8763432].
16. Esteves T, Faria A, Alves R, et al. Lupus miliaris disseminatus faciei: a case report. *Dermatol Online J*. 2010;16:10. [PMID: 20492827].
17. granulomatous eruption. *BMJ Case Rep*. 2017;2017:bcr2017221118. [PMID: 28710244].
18. van de Scheur MR, van der Waal RI, Starink TM. Lupus miliaris disseminatus faciei: a distinctive rosacea-like syndrome and not a granulomatous form of rosacea. *Dermatology*. 2003;206:120-123. [PMID: 12592078].
19. Daneshpazhoo M, Ehsani A, Toosi S, Robati RM. Isotretinoin in acne agminata. *Saudi Med J*. 2007;28(10):1600-1602. [PMID: 17914528].
20. Schaarschmidt ML, Schlich M, Staub J, et al. Lupus Miliaris Disseminatus Faciei: Not Only a Facial Dermatitis. *Acta Derm Venereol*. 2017;97:655-656. [PMID: 28119995].
21. with complete response to isotretinoin. *Dermatol Online J*. 2021;27:13030/qt2c42p7q0. [PMID: 33560791].
22. Bedlow AJ, Otter M, Marsden RA. Axillary acne agminata (lupus miliaris disseminatus faciei). *Clin Exp Dermatol*. 1998;23:125-128. [PMID: 9861743].
23. Ganzetti G, Giuliadori K, Campanati A, et al. Doxycycline-isoniazid: a new therapeutic association for recalcitrant acne agminata. *Dermatol Ther*. 2012;25:207-209. [PMID: 22741939].
24. Goh WS, Tey KE, Choon SE, Vasavan Y. A case report of acne agminata. *Malaysian J Dermatology*. 2017;38:87-90. <https://www.dermatology.org.my/pdf/MJD%20June%202017%20Issue%2038.pdf>.
25. Toda-Brito H, Aranha JMP, Tavares ES. Lupus miliaris disseminatus faciei. *An Bras Dermatol*. 2017;92:851-853. [PMID: 29364447].
26. Sardana K, Chugh S, Ranjan R, Khurana N. Lupus miliaris disseminatus faciei: A resistant case with response to cyclosporine. *Dermatol Ther*. 2017;30:10.1111/dth.12496. [PMID: 28447377].
27. Ferguson L, Fearfield L. Topical dapsone gel is a new treatment option for acne agminata. *Clin Exp Dermatol*. 2019;44:453-455. [PMID: 30246349].
28. Yin S, Sun L. Case report: A successful combined treatment of severe lupus miliaris disseminatus faciei with oral isotretinoin and methylprednisolone. *Dermatol Ther*. 2020;33:e13267. [PMID: 32052550].
29. Zhang S, Liu XY, Cai L, Zhou C, Zhang JZ. A case of lupus miliaris disseminatus faciei after allogeneic hematopoietic stem cell transplantation. *Chin Med J (Engl)*. 2019;132:2133-2134. [PMID: 31460900].
30. Seukeran DC, Stables GI, Cunliffe WJ, Sheehan-Dare RA. The treatment of acne agminata with clofazimine. *Br J Dermatol*. 1999;141:596-597. [PMID: 10583095].
31. Tokunaga H, Okuyama R, Tagami H, Aiba S. Intramuscular triamcinolone acetonide for lupus miliaris disseminatus faciei. *Acta Derm Venereol*. 2007;87:451-452. [PMID: 17721664].
32. El Benaye J, Oumakhir S, Ghfir M, Sedrati O. Efficacité de la dapsonne dans deux cas de lupus miliaire disséminé de la face [Dapsone efficacy in lupus miliaris disseminatus faciei: two cases]. *Ann Dermatol Venereol*. 2011;138:597-600. [PMID: 21893234].
33. Koike Y, Hatamochi A, Koyano S, et al. Lupus miliaris disseminatus faciei successfully treated with tranilast: report of two cases. *J Dermatol*. 2011;38:588-592. [PMID: 21623898].
34. Nomura H, Egami S, Kasai H, et al. A patient with lupus miliaris disseminatus faciei treated successfully with a combination of oral metronidazole and topical tacrolimus. *J Dermatol*. 2014;41:645-646. [PMID: 24931738].
35. Kim WB, Mistry N. Lupus Miliaris Disseminatus Faciei With Isolated Axillary Involvement. *J Cutan Med Surg*. 2016;20:153-154. [PMID: 26471742].
36. Borgia F, Giuffrida R, Vaccaro M, Lentini M, Cannavò SP. Photodynamic therapy in lupus miliaris disseminatus faciei's scars. *Dermatol Ther*. 2016;29:320-324. [PMID: 27356779].
37. Shimizu A, Funasaka Y, Ueno T, Kanzaki A, Saeki H. Case of lupus miliaris disseminatus faciei associated with marked formation of cysts, successfully treated with intralesional injections of triamcinolone acetonide. *J Dermatol*. 2017;44:e164-e165. [PMID: 28342206].
38. Çerman AA, Karabay EA, Yalçın Ö, Altunay IK. Lupus Miliaris Disseminatus Faciei: A Case Report and Brief Literature Review. *Sisli Etfal Hastan Tip Bul*. 2018;52:142-144. [PMID: 32595389].
39. Radi G, Campanati A, Brisigotti V, et al. Acne agminata in Crohn's disease: A diagnostic and therapeutic challenge case for

dermatologists. *Dermatol Ther.* 2020;33:e13935. [PMID:  
32602634].

Table 2. Treatment of acne agminata in the literature.

No	Reference	Age	Sex	Prior Treatment	Eventual Treatment	Duration	Clinical Response
Tetracyclines							
1	Dekio 1991 [11]	71	F	Nil	Minocycline 150mg OD	Not specified	Partial resolution
2	Moloney 2003 [12]	38	M	Nil	Minocycline 100mg OD	6 months	Gradual resolution
3	Goh 2003 [13]	30	F	Nil	Doxycycline 100mg BD	5 months	Complete resolution with pitted scars
4	Rocas 2013 [3]	29	M	Nil	Doxycycline 100mg OD	Several months	Moderate improvement
5	Nemer 2016 [4]	48	F	Nil	Minocycline 100mg OD	12 months	Near-complete resolution
6	Litaiem 2020 [14]	50	F	Nil	Doxycycline 100mg OD	Not specified	Good response
Steroids							
1	Uesugi 1996 [15]	22	M	Minocycline 200mg/day, 0.12% betamethasone valerate ointment	PO prednisolone 10mg OD for 2 weeks, decreasing to 5mg daily	3 months	Resolved without scar formation
2		40	F	Minocycline 200mg/day, ketotifen fumarate 2mg/day for 5 months	PO prednisolone	9 months	Complete resolution
3		39	F	Nil	PO prednisolone 10mg daily for 2 weeks, then 5mg OM	3 months	Complete resolution without scars
4		18	F	Failed minocycline 200mg/day	PO prednisolone	5 months	No improvement
5	Esteves 2010 [16]	33	M	Minocycline treatment (100mg/day) for 4 months	Oral deflazacort	7 months	Near-complete resolution
6	Dev 2017 [17]	35	M	Failed minocycline 50mg BD + topical tacrolimus 0.1% for a period of 2 months	Oral mini pulse (OMP-Tab betamethasone 5mg on 2 consecutive days in a week)	6 weeks	Improvement – flattening of lesions
Vitamin A derivatives							
1	van de Scheur 2003 [18]	26	M	Failed sulfasalazine 1,000mg/day after 4 month	Switched to isotretinoin 60mg/day	12 months	Resolution with scarring
2	Daneshpazhooh 2007 [19]	25	M	Failed PO doxycycline 200mg/day, topical erythromycin, tretinoin cream for 4 months	Isotretinoin 40mg daily (0.6mg/kg/day)	6 months	1 month – no new papules 4 months – papules subsided 6 months – complete resolution
3		28	M	Failed PO doxycycline 200mg/day, ketoconazole, clindamycin for 6 months.	Isotretinoin 40mg daily (0.5mg/kg/day)	6 months	1 month – no new papules 3 months – complete resolution 6 months to 1 year – no recurrence

4	Schaarschmidt 2017 [20]	28	M	Failed ciprofloxacin 500mg twice daily for 2 weeks	Switched to isotretinoin 30mg/day (0.4mg/kg)	12 months	Complete resolution with residual scars on face, axillary lesions remain
5	Litaïem 2020 [14]	22	M	Nil	Isotretinoin 20mg daily	5 months	Significant improvement
6		37	M	Nil	Isotretinoin 20mg daily	Not specified	Not specified
7	Rogel-Vence 2021 [21]	43	F	Nil	Isotretinoin 20mg/day for 6 months, tapered to 5mg/day for 6 months	12 months	Complete resolution without scars
Combination therapies							
1	Bedlow 1998 [22]	55	F	Minocycline, flucloxacillin and dapsone	Switched to rifampicin and isoniazid	2 months	No response to minocycline, flucloxacillin, dapsone
2	van de Scheur 2003 [18]	48	F	Failed minocycline 200mg/day for 3 months, followed by clofazimine 200mg/day for 4 month	Sulfasalazine 1,500mg/day and isotretinoin 20mg/day	5 months	Gradual resolution without scarring
3		44	M	Failed minocycline 200mg/day after 2 months	Prednisolone 40mg/day, followed by tapered dosages over several weeks to 5mg/day, and dapsone 100mg/day	3 months	Complete resolution
4	Ganzetti 2012 [23]	24	M	Doxycycline 100mg BD for 2 months	Added isoniazid (7mg/kg per day) in addition to doxycycline	6 months	Complete regression at 6 months
5	Goh 2017 [24]	51	F	Dapsone (minimal improvement)	Prednisolone with isotretinoin 20mg OD (able to wean steroid after 1 month)	Not specified	Significant improvement with steroid initially, but required isotretinoin to wean off steroid
6	Toda-Brito 2017 [25]	43	F	Minocycline 100mg/day	Minocycline + PO prednisolone 5mg/day	16 weeks	Flattening of lesions after 3 weeks, moderate improvement at 16 weeks
7	Sardana 2017 [26]	46	F	Failed doxycycline 100mg BD, isotretinoin 1mg/kg/day, HCQS 6mg/kg/day, and dapsone 100mg, each for 5 weeks	Oral cyclosporine 50mg twice a day	2 months	Dramatic improvement in 5 weeks (lesion morphology) No recurrence after 12 months
8	Ferguson 2018 [27]	31	M	PO prednisolone 10mg/day for 1 month, then lymecycline (408mg/day) for 3 months. Added isotretinoin 40mg x 12 months slight reduction in papules size	Added 5% Dapsone gel	3 months with topical 5% dapsone	Improvement in size and inflammation after added dapsone gel
9	Yin 2020 [28]	55	F	Failed minocycline 100mg BD after 2 months, switched to isotretinoin 10mg BD	Added oral methylprednisolone 12mg OD	2 months	Improvement with flattening of lesions
10	Zhang 2019 [29]	43	M	Nil	Isotretinoin 10mg/day and topical tacrolimus BD	6 months	Improvement



Others							
1	Seukeran 1999 [30]	19	F	Potent topical steroid (some improvement), then minocycline 100mg daily for 9 months (but worsened)	Switched to clofazimine 100mg 3x/week	8 weeks	Complete resolution
2	Tokunaga 2007 [31]	68	F	Failed doxycycline, 100mg/day after 1 month	Intramuscular injection of triamcinolone acetonide 40mg once a month	3 injections	Complete resolution
3	El Benaye 2011 [32]	46	F	Nil	Dapsone 100mg per day	2 weeks	Improvement but with scars
4		18	M	Failed tetracyclines and to topical retinoids	Dapsone 100mg per day	1 month	Improvement but with scars
5	Koike 2011 [33]	33	F	<b>Failed azithromycin 1500mg/day after 5 months, roxithromycin for 6 months, minocycline 150mg/day for 4 months</b>	<b>Tranilast 300mg/day</b>	1 month	Complete resolution
6		39	M	Failed minocycline 150mg/day (1 month) and doxycycline 100mg/day (2 months)	<b>Tranilast 300mg/day</b>	1 month	Complete resolution
7	Nomura 2014 [34]	37	F	Failed oral roxithromycin (150mg twice daily) and topical tacrolimus after 1 month	Oral metronidazole (250mg twice daily) with topical tacrolimus	2 weeks	Complete resolution
8	Kim 2016 [35]	41	F	Failed doxycycline 100mg BD due to side effect	Added topical tacrolimus 0.1% BD	Not specified	Improvement (number and intensity)
9	Borgia 2016 [36]	54	M	Failed oral tetracycline, itraconazole, topical and systemic corticosteroids. Switched to rifampicin, ethambutol, and clarithromycin with response after 6 months	Trial of PDT, using 5- aminolaevulinic acid (ALA) as topical porphyrin precursor	3 months	Improved
10	Shimizu 2017 [37]	57	F	Failed diaminodiphenyl sulfone, tacrolimus ointment, oral tranilast and non-ablative fractional laser treatment	Local injection of triamcinolone acetonide 10mg/mL was injected intradermal into the cysts once every 3 weeks	20 sets of 34 injections	Flattening of cysts
11	Çerman 2018 [38]	20	M	Failed doxycycline 200mg OD (1 month)	Switched to PO dapsone 50mg/day + topical tacrolimus	1 month	Improvement with marked regression of lesions
12	Ma 2020 [8]	28	F	Weaning dose of 15mg/day oral prednisone (15mg/day then to 10mg/day), isotretinoin, hydroxychloroquine, and thymosin enteric-coated tablet for 4 weeks	595 nm pulsed-dye laser used on 5 <sup>th</sup> week onwards at interval of 2 weeks – 1 month	28 weeks	Complete resolution
13	Radi 2020 [39]	32	M	Doxycycline 100mg BD for 2 months	PO isoniazid 400mg/day (7mg/kg/day)	2 months	Lesions resolved after 4 weeks
14	Kaushik 2020 [9]	40s	M	Failed doxycycline after 4 months	Apremilast at a dose of 30mg twice daily	4 weeks	Improvement with flattening
15	Alexanian 2021 [10]	20	M	Imiquimod, topical tacrolimus, tetracyclines, topical clindamycin, oral corticosteroids, dapsone, isotretinoin, cyclosporin 250mg OD. Trial of adalimumab 40mg weekly - stopped due to injection site reactions.	Switched to infliximab 5mg/kg at weeks 0, 2, and 6, and then every 8 weeks, combined with methotrexate 10mg weekly	8 months	Complete resolution