

UCSF

UC San Francisco Previously Published Works

Title

Delineating the expanding phenotype associated with SCAPER gene mutation

Permalink

<https://escholarship.org/uc/item/28q3v47s>

Journal

American Journal of Medical Genetics Part A, 179(8)

ISSN

1552-4825

Authors

Fasham, James
Arno, Gavin
Lin, Siying
et al.

Publication Date

2019-08-01






DOI

10.1002/ajmg.a.61202

Peer reviewed

RESEARCH LETTER

Delineating the expanding phenotype associated with SCAPER gene mutation

James Fasham^{1,2}  | Gavin Arno^{3,4}  | Siying Lin¹  | Mingchu Xu^{5,6} |
 Keren J. Carss^{7,8} | Sarah Hull^{3,4} | Amelia Lane³ | Anthony G. Robson^{3,4} |
 Olivia Wenger⁹ | Jay E. Self¹⁰ | Gaurav V. Harlalka¹ | Claire G. Salter¹ |
 Lynn Schema¹¹ | Timothy J. Moss¹² | Michael E. Cheetham³ |
 Anthony T. Moore^{3,4,13} | F. Lucy Raymond^{8,14} | Rui Chen^{5,6} | Emma L. Baple^{1,2}  |
 Andrew R. Webster^{3,4}  | Andrew H. Crosby¹ | NIHR Bioresource Rare Diseases
 Consortium⁸

¹Medical Research, RILD Wellcome Wolfson Centre, University of Exeter Medical School, Royal Devon and Exeter NHS Foundation Trust, Exeter, United Kingdom

²Peninsula Clinical Genetics Service, Royal Devon and Exeter Hospital (Heavitree), Exeter, United Kingdom

³UCL Institute of Ophthalmology, University College London, London, United Kingdom

⁴Moorfields Eye Hospital, London, United Kingdom

⁵Department of Molecular and Human Genetics, Baylor College of Medicine, Houston, Texas

⁶Human Genome Sequencing Center, Baylor College of Medicine, Houston, Texas

⁷Department of Haematology, NHS Blood and Transplant Centre, University of Cambridge, Cambridge, United Kingdom

⁸NIHR BioResource – Rare Diseases, Cambridge University Hospitals NHS Foundation Trust, Cambridge, United Kingdom

⁹New Leaf Center, Clinic for Special Children, Mount Eaton, Ohio

¹⁰Clinical and Experimental Sciences, Faculty of Medicine, University of Southampton, Southampton, United Kingdom

¹¹Division of Genetics and Metabolism, University of Minnesota Medical Center – Fairview, Minneapolis, Minnesota

¹²Division of Genetics and Metabolism, Department of Pediatrics, University of Minnesota, Minneapolis, Minnesota

¹³Ophthalmology Department, UCSF School of Medicine, Koret Vision Centre, San Francisco, California

¹⁴Department of Medical Genetics, Cambridge Institute for Medical Research, University of Cambridge, Cambridge, United Kingdom

Correspondence

Andrew Crosby and Emma Baple, Medical Research, RILD Wellcome Wolfson Centre, University of Exeter Medical School, Royal Devon and Exeter NHS Foundation Trust, Barrack Road, Exeter EX2 5DW, United Kingdom.

Emails: a.h.crosby@exeter.ac.uk, e.baple@exeter.ac.uk

Andrew R. Webster, UCL Institute of Ophthalmology, University College London, London EC1V 9EL, United Kingdom.

Email: andrew.webster@ucl.ac.uk

Funding information

Fight for Sight UK, Grant/Award Numbers: 1511/1512 to AL, 2027 to ELB AHC, Early Career Investigator award to GA; Foundation Fighting Blindness; Medical Research Council, Grant/Award Numbers: G1001931 to ELB, G1002279 to AHC; Moorfields Eye Charity; National Centre for the Replacement, Refinement and Reduction of Animals in Research, Grant/Award Number: to AL; National Institute for Health Research, Grant/Award Numbers: Academic Clinical Fellowship to JF, NIHR BioResource - Rare Diseases project RG65966; Newlife Foundation for Disabled Children, Grant/Award Number: to AC EB; Retina UK; University of Exeter, Grant/Award Number: Vice Chancellor Scholarship to SL

KEYWORDS: Brachydactyly, CCNA2-CDK2, Intellectual disability, Retinitis pigmentosa, SCAPER

This is an open access article under the terms of the Creative Commons Attribution License, which permits use, distribution and reproduction in any medium, provided the original work is properly cited.

© 2019 The Authors. *American Journal of Medical Genetics Part A* published by Wiley Periodicals, Inc.

A potential role for the cyclin A2–cyclin-dependent kinase 2 complex regulator S-phase cyclin A-associated protein residing in the endoplasmic reticulum (SCAPER) in human disease was first suggested by Najmabadi et al. (2011), who identified a candidate homozygous frameshift SCAPER variant as the cause of nonsyndromic intellectual disability (ID) in a small Iranian family. We subsequently reported a single patient with biallelic loss of function (LOF) SCAPER variants associated with retinal disease (Carss et al., 2017). Biallelic LOF variants have since been associated with ID with or without retinitis pigmentosa (RP) in seven individuals from five families from Spain, Israel, and Iran (Hu et al., 2018; Tatour et al., 2017); in one individual from a Jordanian Arab family, a homozygous SCAPER gene variant was identified as the cause of nonsyndromic RP (Jauregui et al., 2019). More recently, Wormser et al. (2019) described a SCAPER gene variant associated with a Bardet–Biedl syndrome (BBS)-like presentation comprising of ID, RP, short stature, obesity, and brachydactyly in eight individuals from two consanguineous Bedouin families belonging to the same tribe in southern Israel, alongside preliminary functional studies suggesting a possible role for SCAPER in ciliary dynamics and disassembly. In the current study, we describe clinical and genetic findings, including seven novel SCAPER variants, in six individuals of Amish, Caucasian, and South Asian descent. Together with our molecular data, our comprehensive phenotypic assessments enable a more detailed clinical comparison to be drawn between the patient cohort described here (including previously published individual G001284; Patient 3 in this study, (Carss et al., 2017) with the 17 individuals in whom SCAPER variants were recently defined (Hu et al., 2018; Jauregui et al., 2019; Najmabadi et al., 2011; Tatour et al., 2017; Wormser et al., 2019), permitting a more precise definition of the clinical phenotype arising from pathogenic SCAPER variation.

Samples were taken with informed consent (study approved by the Ethics Committee of Akron Children's Hospital, Moorfields Eye Hospital and Baylor College of Medicine, in compliance with the Declaration of Helsinki) for deoxyribonucleic acid (DNA) extraction. Single nucleotide polymorphism (SNP) genotyping was performed (Patients 1 and 2) using the HumanCytoSNP-12 v2.1 beadchip array (Illumina, Cambridge, UK). In Patients 1 and 3–5, whole exome or whole genome sequencing (WES or WGS), variant alignment, calling, filtering, and prioritization was performed as previously described (Carss et al., 2017; Rawlins et al., 2019; Xu et al., 2015). Allele-specific primers were designed using Primer3 web software to evaluate segregation of the candidate SCAPER gene variants identified via dideoxy sequencing. Patient 6 underwent WES at GeneDx and was identified via GeneMatcher (Sobreira, Schietecatte, Valle, & Hamosh, 2015) as part of the Matchmaker Exchange Repositories (Philippakis et al., 2015). All variants identified in the study have been submitted to ClinVar (<https://www.ncbi.nlm.nih.gov/clinvar/>).

Patients 1 and 2 are Ohio Amish siblings. Candidate variants identified through WES of DNA from Patient 1 were cross-referenced with regions of autozygosity common to both affected siblings, identified through whole genome SNP genotyping. This identified only a single plausible candidate variant, located within the largest (18 Mb) shared region of autozygosity on chromosome 15 (rs1509805–rs4243078;

chr15(GRCh38):g. 60281446–78374545), a novel homozygous duplication in Exon 18 of the SCAPER gene, predicted to result in a frameshift (NM_020843.2: c.2236dupA, p.(Ile746Asnfs*6) Chr15(GRCh38):g.76705914dupT; Figure 1). Dideoxy sequencing confirmed the presence and co-segregation of this variant in both siblings. This variant was detected in heterozygous form in five unrelated individuals in a database of 116 regional Amish controls, corresponding to an estimated allele frequency of ~0.04, not uncommon for founder mutations within this population. WES/WGS performed in Patients 3–6, identified compound heterozygous SCAPER variants; c.1116delT, p.(Val373Serfs*21) (Chr15(GRCh38):g.76771874delA) and c.2179C>T, p.(Arg727*) (Chr15(GRCh38):g.76705971G>A) in Patient 3, c.1495+1G>A (Chr15(GRCh38):g.76765562C>T) and c.3224delC, p.(Pro1075Glnfs*11) (Chr15(GRCh38):g.76434165delG) in Patient 4, c.829C>T, p.(Arg277*) (Chr15(GRCh38):g.76775061G>A) and c.3707_3708delCT, p.(Ser1236Tyrfs*28) (Chr15(GRCh38):g.76376309_76376310delAG) in Patient 5, and c.2377C>T, p.(Gln793*) (Chr15(GRCh38):g.76702873G>A) and c.2166-3C>G (Chr15(GRCh38):g.76705987G>C) in Patient 6. The SCAPER variants in each of these patients were confirmed to be biallelic by familial segregation analysis using dideoxy sequencing. None of these variants are present in the genome aggregation (gnomAD) or 1,000 genomes databases and those in Patients 1, 2, and 4–6 are novel.

Table 1 summarizes the core phenotypical features of individuals not previously reported, aged between 18 months and 31 years (Patients 1, 2, and 4–6), provides additional clinical details for Patient 3 (Carss et al., 2017), and compares these to the clinical features of all SCAPER syndrome patients described to date. ID and developmental delay was present in all six affected individuals, and four patients also exhibited hyperactivity and attention deficit hyperactivity disorder (ADHD). Autism and dyspraxia were each noted in one individual. Neuroimaging performed in Patients 1, 3, 5, and 6 revealed no abnormalities. Additional dysmorphic features noted in both Amish siblings (Patients 1 and 2) included inverted nipples, brachydactyly, camptodactyly, proximally placed thumbs (Figure 1), and a characteristic facial appearance with frontal bossing and almond-shaped eyes; growth parameters were all normal. Patients 1, 3, and 4–6 all presented between the ages of 10–23 with a reduction in night vision and visual field deficits; Patient 2 (18 months) described no visual symptoms at the time of presentation. Fundus examination in Patients 3–6 revealed findings typical of RP including optic disc pallor, attenuated retinal vessels and intraretinal mid-peripheral bone-spicule pigmentation, and loss of photoreceptor outer segments with retained central macular structure on optical coherence tomography imaging (Figure 1; Table S1). Additional variable ocular features described in some patients with SCAPER syndrome include cataracts (in two individuals) and myopia and keratoconus in one individual each.

Our clinical and genetic studies in six affected individuals, including additional new clinical details for Patient 3, (Carss et al., 2017) take the total number of SCAPER syndrome patients described to date to 23. Although the extent for which clinical data is available for the previously reported patients is variable, our detailed clinical phenotyping allows a more comprehensive clinical comparison to be made with the previously reported cases, confirming the presence of a variable

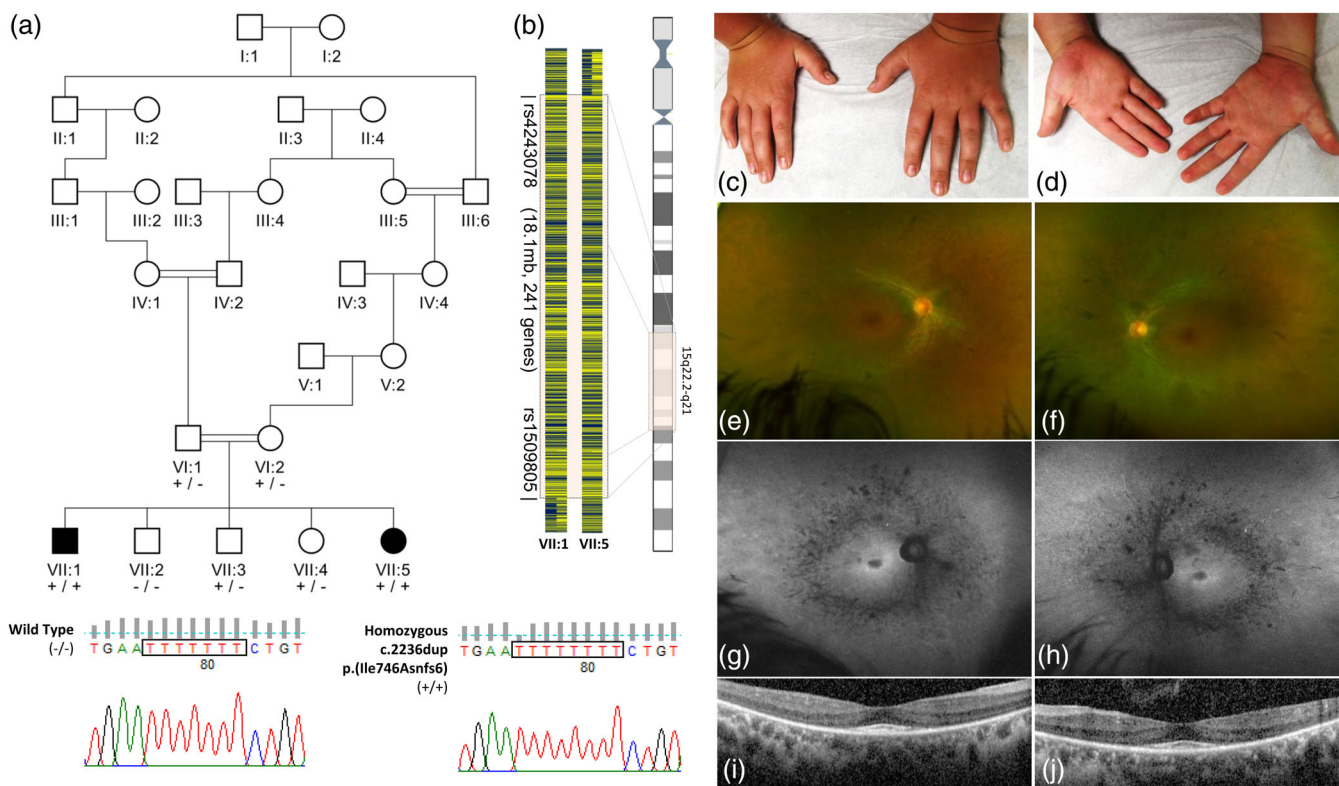


FIGURE 1 (a) Simplified pedigree of the Amish family investigated, with electropherograms showing the *SCAPER* c.2236dupT sequence variant in all affected and unaffected individuals in generations VI and VII (black arrow identifies the duplicated nucleotide). (b) Pictorial representation of the single nucleotide polymorphism (SNP) genotypes across the ~18.1 Mb chromosome 15q21-22 region identified in this family. (c–j) Clinical features of *SCAPER* syndrome patients. (c, d) Brachydactyly, camptodactyly, and proximally placed thumbs identified on examination of patient 1. (e, f) ocular imaging and investigations from patient 3 illustrating features of RP (e: Right eye, f: Left eye) fundus photograph (Optos plc, Dunfermline, UK) showing optic disc pallor, attenuated retinal vessels and mid-peripheral bone spicule pigmentation (g: Right eye, h: Left eye) FAF imaging showing mid-peripheral hypofluorescence with a central ring of hyperautofluorescence demarcating the surviving outer retinal structures. (i: Right eye, j: Left eye) optical coherence tomography (Spectralis-OCT, Heidelberg Engineering, Heidelberg, Germany) of the central retina demonstrating loss of photoreceptor outer segments with retained central macular structure corresponding to FAF findings. FAF, fundus autofluorescence; OCT, optical coherence tomography; *SCAPER*, S-phase cyclin A-associated protein residing in the endoplasmic reticulum

pattern of dysmorphic features associated with *SCAPER* syndrome. It is now clear that the cardinal clinical features of the disorder include mild/moderate ID and developmental delay particularly affecting speech and language and motor milestones. Hyperactivity appears to be a common feature, with some affected individuals receiving a formal diagnosis of ADHD. Early adult onset RP is also a key clinical finding, and the retinal phenotype appears remarkably consistent. In all individuals for whom we have data, progressive loss of night vision begins in first or second decade of life. Together with studies in mice demonstrating expression of *SCAPER* in multiple retinal layers, particularly in the retinal pigment epithelium and photoreceptor inner and outer segments, this supports a role for *SCAPER* in photoreceptor function and/or maintenance (Tatour et al., 2017).

Tapering fingers, brachydactyly and proximally placed thumbs, described in eight individuals from two consanguineous Bedouin families of the same tribe in southern Israel, were also identified as a consistent feature in the two Amish siblings, confirming the association of this feature with the *SCAPER* syndrome. Short stature and obesity were also a common feature amongst the affected Bedouin patients, and this constellation of clinical features including RP, obesity, short

stature, ID, developmental delay, and brachydactyly has consequently led to a suggested diagnosis of BBS in these individuals. Although there is some overlap between the clinical features characteristic of ciliopathies and those seen in *SCAPER* syndrome, the Amish siblings (who are of normal height and weight for age) demonstrate that the digital, retinal, and cognitive abnormalities may occur independently of short stature and obesity. The other common primary features of BBS, including renal anomalies, postaxial polydactyly, hypogonadism (males), and genital abnormalities (females) have not been reported in association with *SCAPER* mutation (Forsythe & Beales, 2013). The dysmorphic facial features and inverted nipples, noted on examination of both Amish siblings, have not been previously noted in other individuals with *SCAPER* variants.

Recently, a single individual homozygous for a c.2023-2A>G *SCAPER* variant presenting with nonsyndromic RP and no evidence of ID was reported in this journal (Jauregui et al., 2019). The same c.2023-2A>G *SCAPER* gene variant has also been reported previously in association with RP, ADHD, and mild ID (Tatour et al., 2017) indicating the variability in the presence and severity of the extraocular features associated with the *SCAPER* syndrome

TABLE 1 A comparison of clinical findings of all affected individuals with biallelic pathogenic SCAPER variants

Genotype	Ethnicity	Sex	Age (years) ^a	Weight (kg, SDS)	Height (cm, SDS)	OFC (cm, SDS)	BMI (SDS)	Walked (months)	Speech delay	ID	Behavior issues	Abnormal neuroimaging	RP	Brachydactyly	Other clinical findings
Najmabadi p.(Tyr118fs*)/p.(Tyr118fs*)	Iran	NA	NA	NA	NA	NA	NA	NA	NA	✓	NA	NA	NA	NA	NA
Tatour (A:II:1) c.2023-2A>G/ c.2023-2A>G	Arab	F	24	NA	NA	NA	NA	Normal	NA	Mild (IQ 64)	ADHD	MRI: Normal	✓	NA	Nil
Tatour (A:II:2) c.2023-2A>G/ c.2023-2A>G	Arab	F	23	NA	NA	NA	NA	Normal	NA	Mild (IQ 56)	ADHD	NA	✓	NA	Nil
Tatour (B:II:1) p.(Ile991fs*)/ p.(Ile991fs*)	Spanish	F	34	NA	NA	NA	NA	24	NA	Mod	None reported	CT: Normal	✓	NA	Alopecia areata
Tatour (C:II:4) p.(Glu620del)/ p.(Ser1219Asn)	Spanish	M	15	NA	NA	NA	NA	Delayed	NA	✓	None reported	NA	✓	NA	NA
Hu (family 166; 3 individuals) p.(Arg120*)/ p.(Arg120*)	Baloch	NA	NA	NA	NA	Normal	NA	NA	NA	✓	NA	NA	NA	NA	NA
Jauregui c.2023-2A>G/ c.2023-2A>G	Arab	M	11	NA	NA	NA	NA	NA	NA	No	No	NP	✓	NA	NA
Womser (P1:V5) p.(Leu936*)/ p.(Leu936*)	Bedouin	F	34	78 (+1.9)	145 (−3.1)	Not reduced	37.1 (+3.1)	NA	✓	Mod	NA	NP	✓	✓	Genu valgum/genu varum
Womser (P1:V6) p.(Leu936*)/ p.(Leu936*)	Bedouin	M	28	78 (+0.7)	157 (−3.1)	Not reduced	31.6 (+2.3)	NA	✓	Mod	NA	NP	✓	✓	Genu valgum/genu varum
Womser (P1:V7) p.(Leu936*)/ p.(Leu936*)	Bedouin	M	24	98 (+2.2)	163 (−2.2)	Not reduced	36.9 (+3.0)	NA	✓	Mod	NA	NP	✓	✓	Genu valgum/genu varum
Womser (P1:V8) p.(Leu936*)/ p.(Leu936*)	Bedouin	M	17	92 (+2.2)	155 (−2.9)	Not reduced	38.3 (+3.3)	NA	✓	Mod	NA	NP	✓	✓	Genu valgum/genu varum
Womser (P2:III1) p.(Leu936*)/ p.(Leu936*)	Bedouin	F	48	86.6 (+2.5)	146 (−3.0)	Not reduced	40.6 (+3.5)	NA	✓	Sev	NA	NP	✓	✓	Nil
Womser (P2:III2) p.(Leu936*)/ p.(Leu936*)	Bedouin	F	47	62 (+0.4)	149 (−2.5)	Not reduced	27.9 (+1.6)	NA	✓	Sev	NA	NP	✓	✓	Genu valgum/genu varum
Womser (P2:III7) p.(Leu936*)/ p.(Leu936*)	Bedouin	F	29	57.8 (+0.1)	132 (−5.2)	Not reduced	33.2 (+2.8)	NA	✓	Sev	NA	NP	✓	✓	Nil
Womser (P2:IV1) p.(Leu936*)/ p.(Leu936*)	Bedouin	M	10	29.5 (−0.38)	129 (−1.5)	Not reduced	17.7 (+0.7)	NA	✓	Mod	ADHD	MRI: abnormal ^b	Suspected	✓	Genu valgum/genu varum
Patient 1 p.(Ile746fs*)/ p.(Ile746fs*)	Amish	M	13.7	68.9 (+1.9)	166.3 (+0.7)	56.4 (+0.39)	24.9 (+2.0)	24	✓	Mod	Hyperactivity	MRI: Normal	No	✓	Proximally placed thumbs, short fifth fingers, pes planus, frontal bossing, almond-shaped eyes, and inverted nipples
Patient 2 p.(Ile746fs*)/ p.(Ile746fs*)	Amish	F	1.5	8.6 (−2.2)	78.5 (−0.7)	47 (−0.92)	14 (−2.5)	22	✓	Mild	Hyperactivity	NP	NA (age)	✓	Proximally placed thumbs, short fifth fingers, pes planus, frontal bossing, almond-shaped eyes, and inverted nipples

(Continues)

TABLE 1 (Continued)

Patient	Genotype	Ethnicity	Sex	Age (years) ^a	Weight (kg, SDS)	Height (cm, SDS)	OFC (cm, SDS)	BMI (SDS)	Walked (months)	Speech delay	ID	Behavior issues	Abnormal neuroimaging	RP	Brachydactyly	Other clinical findings
Patient 3 ^c (GC17206)	p.(Arg727*)/p.(Val873fs*)	South Asian	F	28	25th centile	3rd centile	NA	NA	11	✓	Mod	ADHD, autism, and self-harm	MRI: Normal	✓	NA	Nil
Patient 4 (GC15572)	c.1495+1G>A/p.(Pro1075fs*)	Caucasian	F	31	NA	NA	57 (95th centile)	NA	15	✓	Mild	Dyspraxia	NP	✓	NA	Nil
Patient 5	p.(Arg277*)/p.(Ser1236fs*)	NA (United States)	F	17	NA	NA	NA	Obese	NA	NA	✓	NA	MRI: Normal	✓	NA	Nil
Patient 6	p.(Gln793*)/c.2166-3C>G	NA (United States)	F	24	63.6 (+0.6)	162.6 (-0.2)	NA	24 (+0.63)	15-18	Yes	Mild (IQ 50-60s)	ADHD	MRI: Normal	✓	NA	Moderate eczema with severe skin-picking behavior
Summary					8/12 obese				12/12	20/21	8/11	All normal	16/17	10/10		

Abbreviations: ADHD, attention-deficit hyperactivity disorder; BMI, body mass index; CT, computerized tomography; F, female; ID, intellectual disability; IQ, intelligence quotient (Wechsler Adult Intelligence Scale); M, male; Mod, moderate; MRI, magnetic resonance imaging; NA, not available; NP, not performed; OFC, occipitofrontal circumference; RP, retinitis pigmentosa; SDS, standard deviation scores; Sev, severe.

Note. Adults with a BMI >25 are classified as overweight, those >30 are classified as obese; the ✓ symbol indicates the presence of a feature in an affected subject.

Height, weight, BMI and OFC Z-scores were calculated using a Microsoft Excel add-in to access growth references based on the LMS method (Pan & Cole, 2012) using a reference European population (Cole, Freeman, & Preece, 1998).

^aRefers to age of examination.

^bAbnormal MRI findings include mildly enlarged lateral ventricles and several loci of irregular signal in the brain parenchyma above the tentorium, in the posterior white matter and along the ependyma.

^cAlso patient G001284 (Carss et al., 2017).

(Table 1). However, this may also be accounted for by the difficulties in conclusively defining milder developmental delay in some situations, when more subtle clinical findings may not be identified if not specifically assessed. Conversely, associated ocular pathology may remain undetected or unrecognized in individuals with ID, as such individuals often have difficulty recognizing or articulating their visual symptoms. This highlights the importance of visual screening and ophthalmological assessment in these patients. Other common ocular features include cataracts (in particular posterior subcapsular cataracts, which are commonly associated with RP; (Pruett, 1983) and strabismus, with nystagmus and keratoconus noted in a single patient. The high incidence of cataracts, a potentially treatable cause of sight loss, again supports the case for screening in early childhood.

The allele frequency (~0.04) of the Ohio Amish SCAPER founder mutation suggests that, despite no previous reports, this disorder represents an underrecognized cause of RP and mild ID within this community. This further highlights the importance of careful clinical evaluation in children and adults with ID and enables targeted genetic testing for this SCAPER variant for Amish individuals with this clinical presentation. Together with our clinical review of all previously published patients, this study expands the molecular spectrum of disease-causing SCAPER variants and enables a clearer delineation of the core (and variable) phenotypical features of SCAPER syndrome to be characterized. Our findings also highlight the importance of prompt visual screening and ophthalmic assessment in all individuals with SCAPER-associated disease. Despite the increasing numbers of individuals identified with SCAPER syndrome, the precise functions of SCAPER in human growth and development are not fully understood. Further studies to elucidate the precise molecular and developmental roles of this molecule in human growth and skeletal, retinal, and brain development and function, will yield important insights into the clinical heterogeneity increasingly observed in SCAPER-associated disease.

ACKNOWLEDGMENTS

First and foremost, we would like to thank the patients and their families for their participation in and support of this study. We thank Kirsty McWalter at GeneDx (GeneMatcher and Matchmaker Exchange). This work was supported by the Medical Research Council (MRC Grants G1001931 to ELB and G1002279 to AHC). This paper presents independent research funded by the National Institute for Health Research (NIHR) through the NIHR BioResource – Rare Diseases project [grant number RG65966] and NIHR Academic Clinical Fellowship to J.F.) The views expressed are those of the author(s) and not necessarily those of the NHS, the NIHR or the Department of Health and Social Care. Fight For Sight (Grants 1511/1512 to A. L., 2027 to E. L. B. and A. H. C., and Early Career Investigator award to G. A.), Newlife Foundation for Disabled Children (grant to E. L. B. and A. H. C.). Further support was provided by NIHR Biomedical Centre of UCL Institute of Ophthalmology and Moorfields Eye Hospital, National Health Service Foundation Trust, and UCL Institute of Ophthalmology, Moorfields Eye Hospital Special

Trustees, Moorfields Eye Charity, The Foundation Fighting Blindness (United States), and Retina UK. S. L. is supported by the University of Exeter Vice Chancellor Scholarship and F. L. R. is supported by Cambridge NIHR Biomedical Research Centre and National Centre for the Replacement Refinement and Reduction of Animals in Research (NC3Rs).

AUTHOR CONTRIBUTIONS

J. F., G. A., S.L. contributed equally to this work. E. L. B., A. R. W., and A. H. C. contributed equally to this work.

ORCID

James Fasham  <https://orcid.org/0000-0002-7614-9202>

Gavin Arno  <https://orcid.org/0000-0002-6165-7888>

Siyang Lin  <https://orcid.org/0000-0003-1122-8396>

Emma L. Baple  <https://orcid.org/0000-0002-6637-3411>

Andrew R. Webster  <https://orcid.org/0000-0001-6915-9560>

REFERENCES

- Carss, K. J., Arno, G., Erwood, M., Stephens, J., Sanchis-Juan, A., Hull, S., ... Raymond, F. L. (2017). Comprehensive rare variant analysis via whole-genome sequencing to determine the molecular pathology of inherited retinal disease. *American Journal of Human Genetics*, 100(1), 75–90. <https://doi.org/10.1016/j.ajhg.2016.12.003>
- Cole, T. J., Freeman, J. V., & Preece, M. A. (1998). British 1990 growth reference centiles for weight, height, body mass index and head circumference fitted by maximum penalized likelihood. *Statistics in Medicine*, 17(4), 407–429.
- Forsythe, E., & Beales, P. L. (2013). Bardet–Biedl syndrome. *European Journal of Human Genetics*, 21(1), 8–13. <https://doi.org/10.1038/ejhg.2012.115>
- Hu, H., Kahrizi, K., Musante, L., Fattahi, Z., Herwig, R., Hosseini, M., ... Najmabadi, H. (2018). Genetics of intellectual disability in consanguineous families. *Molecular Psychiatry*. <https://doi.org/10.1038/s41380-017-0012-2>
- Jauregui, R., Thomas, A. L., Liechty, B., Velez, G., Mahajan, V. B., Clark, L., & Tsang, S. H. (2019). SCAPER-associated nonsyndromic autosomal recessive retinitis pigmentosa. *American Journal of Medical Genetics. Part A*, 179(2), 312–316. <https://doi.org/10.1002/ajmg.a.61001>
- Najmabadi, H., Hu, H., Garshasbi, M., Zemojtel, T., Abedini, S. S., Chen, W., ... Ropers, H. H. (2011). Deep sequencing reveals 50 novel genes for recessive cognitive disorders. *Nature*, 478(7367), 57–63. <https://doi.org/10.1038/nature10423>
- Pan H, Cole TJ. 2012 *LMS growth, a Microsoft Excel add-in to access growth references based on the LMS method*. Version 2.77. Retrieved from <http://www.healthforallchildren.co.uk/>
- Philippakis, A. A., Azzariti, D. R., Beltran, S., Brookes, A. J., Brownstein, C. A., Brudno, M., ... Rehm, H. L. (2015). The matchmaker exchange: A platform for rare disease gene discovery. *Human Mutation*, 36(10), 915–921. <https://doi.org/10.1002/humu.22858>
- Pruett, R. C. (1983). Retinitis pigmentosa: Clinical observations and correlations. *Transactions of the American Ophthalmological Society*, 81, 693–735.

- Rawlins, L. E., Jones, H., Wenger, O., Aye, M., Fasham, J., Harlalka, G. V., ... Baple, E. L. (2019). An Amish founder variant consolidates disruption of CEP55 as a cause of hydranencephaly and renal dysplasia. *European Journal of Human Genetics*, 27, 657–662. <https://doi.org/10.1038/s41431-018-0306-0>
- Sobreira, N., Schiettecatte, F., Valle, D., & Hamosh, A. (2015). GeneMatcher: A matching tool for connecting investigators with an interest in the same gene. *Human Mutation*, 36(10), 928–930. <https://doi.org/10.1002/humu.22844>
- Tatour, Y., Sanchez-Navarro, I., Chervinsky, E., Hakonarson, H., Gawi, H., Tahsin-Swafiri, S., ... Ben-Yosef, T. (2017). Mutations in SCAPER cause autosomal recessive retinitis pigmentosa with intellectual disability. *Journal of Medical Genetics*. 54(10), 698–704. <https://doi.org/10.1136/jmedgenet-2017-104632>
- Wormser, O., Gradstein, L., Yogev, Y., Perez, Y., Kadir, R., Goliand, I., ... Birk, O. S. (2019). SCAPER localizes to primary cilia and its mutation affects cilia length, causing Bardet–Biedl syndrome. *European Journal of Human Genetics*, 27, 928–940. <https://doi.org/10.1038/s41431-019-0347-z>
- Xu, M., Gelowani, V., Eblimit, A., Wang, F., Young, M. P., Sawyer, B. L., ... Chen, R. (2015). ATF6 is mutated in early onset photoreceptor degeneration with macular involvement. *Investigative Ophthalmology & Visual Science*, 56(6), 3889–3895. <https://doi.org/10.1167/iops.15-16778>

SUPPORTING INFORMATION

Additional supporting information may be found online in the Supporting Information section at the end of this article.

How to cite this article: Fasham J, Arno G, Lin S, et al. Delineating the expanding phenotype associated with SCAPER gene mutation. *Am J Med Genet Part A*. 2019;179A: 1665–1671. <https://doi.org/10.1002/ajmg.a.61202>