

# UC Irvine

## UC Irvine Previously Published Works

### Title

Reliability Assessment of Various Sonographic Techniques for Evaluating Carpal Tunnel Syndrome

### Permalink

<https://escholarship.org/uc/item/2784n6t0>

### Journal

Journal of Ultrasound in Medicine, 34(11)

### ISSN

0278-4297

### Authors

Junck, Anthony D  
Escobedo, Eva M  
Lipa, Bethany M  
[et al.](#)

### Publication Date

2015-11-01

### DOI

10.7863/ultra.15.01069

Peer reviewed



Published in final edited form as:

*J Ultrasound Med.* 2015 November ; 34(11): 2077–2088. doi:10.7863/ultra.15.01069.

## Reliability Assessment of Various Sonographic Techniques for Evaluating Carpal Tunnel Syndrome

**Anthony D. Junck, MD, Eva M. Escobedo, MD, Bethany M. Lipa, MD, Michael Cronan, RT, Colleen Anthonisen, BA, Eduard Poltavskiy, MS, Heejung Bang, PhD, and Jay J. Han, MD**

Departments of Radiology (A.D.J., E.M.E., M.C.) and Physical Medicine and Rehabilitation (B.M.L., C.A., J.J.H.), University of California Davis School of Medicine, Sacramento, California USA; and Department of Public Health Sciences, University of California at Davis, Davis, California USA (E.P., H.B.).

### Abstract

**Objectives**—The aim of this study was to determine the intra- and inter-rater reliability of sonographic measurements of the median nerve cross-sectional area in individuals with carpal tunnel syndrome and healthy control participants.

**Methods**—The median nerve cross-sectional area was evaluated by sonography in 18 participants with carpal tunnel syndrome (18 upper extremities) and 9 control participants (18 upper extremities) at 2 visits 1 week apart. Two examiners, both blinded to the presence or absence of carpal tunnel syndrome, captured independent sonograms of the median nerve at the levels of the carpal tunnel inlet, pronator quadratus, and mid-forearm. The cross-sectional area was later measured by each examiner independently. Each also traced images that were captured by the other examiner.

**Results**—Both the intra- and inter-rater reliability rates were highest for images taken at the carpal tunnel inlet (radiologist,  $r = 0.86$ ; sonographer,  $r = 0.87$ ; inter-rater,  $r = 0.95$ ; all  $P < .0001$ ), whereas they were lowest for the pronator quadratus ( $r = 0.49, 0.29, \text{ and } 0.72$ , respectively; all  $P < .0001$ ). At the mid-forearm, the intra-rater reliability was lower for both the radiologist and sonographer, whereas the inter-rater reliability was relatively high ( $r = 0.54, 0.55, \text{ and } 0.81$ ; all  $P < .0001$ ). Tracing of captured images by different examiners showed high concordance for the median cross-sectional area at the carpal tunnel inlet ( $r = 0.96\text{--}0.98$ ;  $P < .0001$ ).

**Conclusions**—The highest intra- and inter-rater reliability was found at the carpal tunnel inlet. The results also demonstrate that tracing of the median nerve cross-sectional area from captured images by different examiners does not contribute significantly to measurement variability.

### Keywords

carpal tunnel syndrome; cross-sectional area; median nerve; musculoskeletal ultrasound; reliability; sonography

Carpal tunnel syndrome is the most frequently occurring peripheral nerve entrapment disorder (median nerve at the wrist) and is also one of the most prevalent modern-age upper limb musculoskeletal ailments, affecting approximately 3.8% to 5.8% of the population, with a greater prevalence among women and in certain occupational groups.<sup>1,2</sup> The diagnosis of carpal tunnel syndrome is usually based on clinical findings and may be supported by electrodiagnostic studies.

Sonography of the median nerve has been rapidly gaining popularity and credibility as a useful diagnostic tool for evaluation of carpal tunnel syndrome. As a noninvasive and painless method, sonography has clinical advantages over electrodiagnostic tests (nerve conduction and electromyography), which are most often considered the diagnostic reference standard methods in the appropriate clinical context.<sup>3,4</sup> In addition, Ziswiler et al<sup>5</sup> found that diagnostic sonography can achieve sensitivity (82%) and specificity (87%) that are comparable to those of electrodiagnostic tests for the diagnosis of carpal tunnel syndrome.

Although various anatomic locations within the forearm and wrist as well as different sonographic techniques for examination of the median nerve are being explored, there is no uniformly adopted standard for sonographic evaluation of the median nerve for carpal tunnel syndrome. A meta-analysis by Tai et al<sup>6</sup> and literature reviews by Roll et al<sup>7</sup> and Beekman and Visser<sup>8</sup> demonstrated that the median nerve cross-sectional area at the carpal tunnel inlet (at the level of the pisiform) was the best single diagnostic criterion for evaluating patients with suspected carpal tunnel syndrome. As research has progressed, some assessments, such as observations of nerve flattening and retinacular bowing, have not been determined to be consistently useful.<sup>9,10</sup> Other techniques to account for variability in median nerve sizes between different individuals have been proposed (including wrist-to-forearm median cross-sectional area ratios,<sup>11,12</sup> wrist-to-forearm cross-sectional area difference,<sup>12,13</sup> and nerve tunnel index<sup>14</sup>) and have shown promising results but have not been extensively evaluated further. Overall, the largest cross-sectional area measurement of the median nerve within the carpal tunnel region appears to be the most useful.<sup>10</sup> Normal and pathologic reference values for the cross-sectional area of the median nerve have been suggested, with the upper limit of normal generally approximating 9 mm<sup>2</sup> at the carpal tunnel.<sup>15-18</sup>

However, a review of the literature reveals that a systematic approach to assessing and comparing both the intra- and inter-rater reliability of median nerve cross-sectional area measurements at various commonly performed locations is still lacking.<sup>9</sup> Therefore, we sought to determine the intra- and inter-rater reliability of sonographic measurements of the median nerve cross-sectional area at the carpal tunnel inlet, pronator quadratus, and mid-forearm in both participants with carpal tunnel syndrome and control participants. Furthermore, it is unknown to what degree tracing of the median nerve by independent examiners contributes to the variance of the cross-sectional area measurement. Therefore, we wanted to compare the concordance of measured median cross-sectional areas from the same captured images that were traced independently by 2 examiners who were blinded to each other's data.

## Materials and Methods

### Participants

This prospective study protocol was approved by the University Institutional Review Board. Written and verbal consent for participation in the study was obtained from all participants. Eighteen participants with carpal tunnel syndrome (cases; 10 female and 8 male) and 9 healthy control participants (controls; 4 female and 5 male) were enrolled in the study to evaluate their median nerve with sonography. Participants with carpal tunnel syndrome were recruited on the basis of their electrodiagnostic results (median motor distal latency at 8 cm  $\geq 4.5$  milliseconds or combined sensory index  $>0.9$ ), and healthy control participants with no carpal tunnel syndrome symptoms were recruited from the general population. The case or control status was kept unknown to the sonographers, who performed bilateral sonographic examinations on all participants. For controls, bilateral data were collected and used for analysis (18 upper extremities). For each participant with carpal tunnel syndrome, data from both wrists were collected (for blinding purposes); however, only one side with carpal tunnel syndrome meeting the inclusion criteria was used for analysis (18 upper extremities). Participants were deidentified for data entry, and the examiners were blinded to the carpal tunnel syndrome status of the participants.

### Study Design

All case and control participants attended 2 study visits 1 week apart. At both visits, bilateral examinations were performed independently by a senior staff radiologist (E.M.E.) with greater than 10 years of musculoskeletal ultrasound experience and also by a sonographer (M.C.) with greater than 20 years of experience. The examiners captured their own sets of images for tracing, and each examiner also traced the other examiner's captured images.

### Sonographic Evaluations

Both examiners received the same initial orientation and training regarding the measurements being collected before initiation of the study. Both examiners were blinded to the clinical status of the participants (whether case or control). All examinations were performed by high-resolution sonography using the same MyLab 25 Gold ultrasound machine and settings with an 18-MHz linear transducer (Esaote North America, Indianapolis, IN). Participants were in the supine position with their wrists in a neutral position lying down next to their bodies.

The median nerve was localized, and images were taken at the following locations. Three static cross-sectional images were acquired at the level of the carpal tunnel inlet (deep to the proximal flexor retinaculum and between the scaphoid tubercle and pisiform). Three images were then also similarly acquired at the levels of the pronator quad-ratus and the mid-forearm. The mid-forearm location was determined as the midpoint of the measured distance between the distal wrist crease and the antecubital fossa. The median nerve wrist-to-forearm ratio was determined by dividing the distal median nerve cross-sectional area at the carpal tunnel inlet by the median nerve cross-sectional area at the mid-forearm.

The images were saved and later uploaded to our research database. The images were accessed independently by the examiners and freehand traced using iSite version 3.6.144 software (Philips Healthcare, Mountain View, CA). The cross-sectional area of the median nerve was determined by tracing the periphery with an electronic caliper. The periphery of the nerve was considered the collective margin of the hypoechoic nerve fascicles, excluding the hyperechoic nerve sheath (epineurium). The area was automatically calculated by the software. Although it would have been possible for the examiners to alternatively measure the nerve at the time of imaging, for practical purposes of standardization and double blinding, measurements were performed independently on a picture archiving and communication system workstation at a later time.

### Statistical Methods

The normality of distributions was assessed by the Shapiro-Wilks test. An unpaired *t* test was used to compare differences between cases and controls. A paired *t* test was performed to determine whether there were significant differences between baseline and follow-up or between the examiners. The Pearson correlation coefficient was used for assessing correlations. Significant differences were noted at  $P < .05$ . Bland-Altman plots were used to depict agreement between baseline and follow-up and between the sonographer and radiologist. Limits of agreement were defined as the mean difference  $\pm 1.96$  SD. Statistical analyses were conducted with SAS version 9.4 software (SAS Institute Inc, Cary, NC).

## Results

### Study Participants

The characteristics of the study participants are shown in Table 1. There were no significant differences between the ages of the cases and controls (male, female, and combined groups). There were also no significant difference in the body mass index (BMI) between the male cases and controls and, similarly, no difference in the BMI between the female cases and controls. However, there was a significant group difference in the BMI between the case and control groups (mean  $\pm$  SD,  $30.4 \pm 6.38$  versus  $25.0 \pm 3.22$ ;  $P = .025$ ), which was consistent with the well-established association between an increased BMI and carpal tunnel syndrome.

### Median Cross-sectional Areas for the Control and Case Groups

The mean median nerve cross-sectional area  $\pm$  SD at the carpal tunnel inlet, pronator quadratus, and mid-forearm for the control and case groups are shown for both examiners (sonographer and radiologist) in Table 2. As expected, there was a significant difference in the mean cross-sectional area at the carpal tunnel inlet between the control and case groups for both examiners, whereas no difference in the mean cross-sectional area at the level of the mid-forearm between the control and case groups was noted. For the mean cross-sectional area at the pronator quadratus, one of the examiners had a significant difference between the case and control groups, whereas the other did not.

## Intra- and Inter-Rater Reliability

Correlation plots of the median nerve cross-sectional area at the carpal tunnel inlet, pronator quadratus, and mid-forearm as well as the wrist-to-forearm ratio are shown in Figures 1–5. These plots show in sequence: (1) test-retest (1 week apart) intra-rater reliability for the sonographer and radiologist, respectively; and (2) inter-rater reliability of respective measured parameters between the examiners at both baseline and follow-up visits combined. Respective Bland-Altman plots showing analysis of agreement between measurements are also shown.

**Median Nerve Cross-sectional Area at the Carpal Tunnel Inlet**—The intra-rater reliability for the median nerve cross-sectional area at the carpal tunnel inlet measured by the sonographer had a combined Pearson  $r$  of 0.87 ( $P < .0001$ ; Figure 1A), whereas the value was 0.86 ( $P < .0001$ ) for measurements done by the radiologist (Figure 1B). The  $r$  values for inter-rater reliability were 0.93 for cases, 0.87 for controls, and 0.95 combined ( $P < .0001$ ; Figure 1C). The Bland-Altman plot showed a difference of  $\pm 1.72 \text{ mm}^2$  between the sonographer and radiologist while centering around  $-0.24 \text{ mm}^2$ .

**Median Nerve Cross-sectional Area at the Pronator Quadratus**—The intra-rater reliability for the median nerve cross-sectional area at the level of the pronator quadratus measured by the sonographer had a Pearson  $r$  of 0.29 ( $P < .0001$ ; Figure 2A), whereas the value was 0.49 ( $P < .0001$ ) for measurements done by the radiologist (Figure 2B). The  $r$  values for inter-rater reliability were 0.85 for cases, 0.48 for controls, and 0.72 combined ( $P < .0001$ ; Figure 2C). The Bland-Altman plot showed a difference of  $\pm 2.64 \text{ mm}^2$  between the sonographer and radiologist while centering around  $-0.6 \text{ mm}^2$ .

**Median Nerve Cross-sectional Area at the Mid-Forearm**—The intra-rater reliability for the median nerve cross-sectional area at the mid-forearm measured by the sonographer had a Pearson  $r$  of 0.55 ( $P < .0001$ ; Figure 3A), whereas the value was 0.57 ( $P < .0001$ ) for measurements done by the radiologist (Figure 3B). The  $r$  values for inter-rater reliability were 0.89 for cases, 0.58 for controls, and 0.81 combined ( $P < .0001$ ; Figure 3C). The Bland-Altman plot showed a difference of  $\pm 1.79 \text{ mm}^2$  between the sonographer and radiologist while centering around  $-0.26 \text{ mm}^2$ .

**Wrist-to-Forearm Ratio**—The intra-rater reliability for the wrist-forearm ratio measured by the sonographer had a Pearson  $r$  of 0.65 ( $P < .0001$ ; Figure 4A), whereas the value was 0.54 ( $P < .0001$ ) for measurements done by the radiologist (Figure 4B). The  $r$  values for inter-rater reliability were 0.73 for cases, 0.69 for controls, and 0.8 combined ( $P < .0001$ ) (Figure 4C). The Bland-Altman plot showed a difference of  $\pm 0.70 \text{ mm}^2$  between the sonographer and radiologist while centering around  $-0.04 \text{ mm}^2$ .

**Radiologist and Sonographer Tracing Images Acquired by the Other Examiner**—We also looked at whether having different examiners tracing the same image could potentially contribute to variability. No significant difference in the median nerve cross-sectional area (at the carpal tunnel inlet) was found whether the images were captured by the

sonographer and traced by the radiologist and sonographer (Figure 5A) or captured by the radiologist and traced by the sonographer and radiologist (Figure 5B).

### Comparison of Reliability for Various Sonographic Locations Used for Carpal Tunnel Syndrome

All Pearson correlation coefficient values from the study are compiled into a summary in Table 3. The highest Pearson  $r$  value for inter-rater reliability was at the level of the carpal tunnel inlet ( $r = 0.95$ ;  $P < .0001$ ).

## Discussion

Although the diagnosis of carpal tunnel syndrome has traditionally relied on clinical findings and electrodiagnostic studies, sonography is becoming an increasingly popular modality because of its greater accessibility, noninvasiveness, relatively low cost, and short examination times. Some have suggested that sonography may be even more sensitive than electrodiagnostic testing for some patients.<sup>19</sup> Wong et al<sup>4</sup> proposed an algorithm in which sonography was the initial study for patients suspected of having carpal tunnel syndrome, with electrodiagnostic tests performed only if the sonographic results were nonconfirmatory. The results of a meta-analysis by Descatha et al<sup>20</sup> suggested that sonography would be an efficient complement to nerve conduction studies for diagnosing carpal tunnel syndrome. In addition to its use in making an initial diagnosis of carpal tunnel syndrome, the practical applications for sonographic evaluation of the median nerve also include follow-up evaluation after conservative treatment and surgical intervention. For carpal tunnel syndrome of moderate severity or less, Kim et al<sup>21</sup> demonstrated a concurrent improvement in symptoms and a reduction in the median nerve size after carpal tunnel release, whereas Vögelin et al<sup>22</sup> demonstrated a concurrent improvement among patients with mild, moderate, and severe neurologic disease. As more radiologists and clinicians collectively become familiar with the sonographic technique, clinical examination combined with sonography will likely become an ever more routine approach for evaluating carpal tunnel syndrome. Spurred on by positive experience in the clinical realm and through evidence in research studies demonstrating its usefulness, sonography is becoming a more prominent diagnostic tool for evaluation of carpal tunnel syndrome.

However, a review of the literature reveals wide variability in techniques used for evaluation of carpal tunnel syndrome as well as different locations for imaging the median nerve, each with its own reliability testing results. Wilkinson et al<sup>23</sup> showed good intra-rater reliability for measuring the median nerve cross-sectional area in 24 wrists of 12 healthy volunteers at various levels of the wrist. However, only a single experienced sonographer was used to capture and measure the images; thus, the inter-rater reliability and reliability pertaining to carpal tunnel syndrome were not measured. Impink et al<sup>3</sup> evaluated the intra- and inter-rater reliability of various median nerve measurements in 15 able-bodied participants and 5 wheelchair users and found intra-rater reliability to be good and inter-rater reliability to be moderate to poor, except for the median nerve cross-sectional area at the distal radius; they recommended that a single evaluator capture images for median nerve measurement. Unlike our study, no participants with electrodiagnostic evidence of carpal tunnel syndrome were

included. Alemán et al<sup>24</sup> evaluated 2 forms of measurement, indirect and direct, of the median nerve cross-sectional area in 22 participants with carpal tunnel syndrome and found inter-rater reliability rates of 83.3% and 80.2%, respectively. However, all of the participants had symptoms of carpal tunnel syndrome, and no control participants were included. Filius et al<sup>25</sup> studied shape and displacement measurements of the median nerve in 20 healthy participants using dynamic sonographic cine images, including the cross-sectional area of the median nerve at the carpal tunnel inlet, and showed moderate to excellent intra- and inter-rater reliability of median nerve cross-sectional area measurements. However, all of the participants were healthy individuals again. Thus, the reliability for patients with carpal tunnel syndrome was not verified. In addition, the study evaluated only a single set of images without comparing each examiner's ability to obtain the images. Similarly, Tagliafico and Martinoli<sup>18</sup> showed good intra- and inter-rater reliability of median nerve cross-sectional area measurements, but again, the study was limited to healthy participants. Kim et al<sup>26</sup> reported inter-rater reliability between a radiologist and physiatrist (with a sample size of 30), with correlation coefficients of 0.84 and 0.81 for the proximal median nerve and distal median nerve cross-sectional areas, respectively. Again, only healthy participants were studied. Thus, in our review of the literature, there was a distinct lack of a systematic evaluation of both intra- and inter-rater reliability of commonly used sonographic techniques for carpal tunnel syndrome that was based on examination of both patients with carpal tunnel syndrome and healthy controls participants.

This lack of reliability data for commonly used sonographic techniques, as well as reliability information for different locations to capture the median nerve cross-sectional area in the carpal tunnel syndrome evaluation, served as our motivation for this study (to contribute this information to the existing body of literature). In our study design, we attempted to determine both the intra- and the inter-rater reliability of median nerve cross-sectional area measurements at 3 separate locations (carpal tunnel inlet, pronator quadratus, and mid-forearm) in a group of participants that included both those with clinical carpal tunnel syndrome (with electrodiagnostic confirmation) and healthy control participants who were age and sex matched. The study sonographers were blinded to the case or control status of the participants.

Our results demonstrate that, overall, both intra- and inter-rater reliability rates were highest for images taken at the carpal tunnel inlet compared to the other locations. The inter-rater reliability for the median nerve cross-sectional area at the pronator quadratus ( $r=0.72$ ) and at the mid-forearm ( $r=0.81$ ) was not as high as for the carpal tunnel inlet ( $r=0.95$ ). At the level of the pronator quadratus, one of the contributing factors for decreased reliability may be the relatively close proximity of the median nerve to muscle, which decreases the ease of isolating it. Subjectively, both examiners remarked about having some difficulty identifying the margins of the median nerve at the level of the pronator quadratus. Furthermore, the relative, albeit slight, obliquity of the nerve to the skin surface at the pronator quadratus level can limit accurate measurement. These factors may have contributed to the reduced reliability at the pronator quadratus compared to carpal tunnel inlet. At the mid-forearm, inter-rater reliability was 0.81. The lower reliability of this measurement compared to the carpal tunnel inlet may be accounted for by the increased depth of the nerve and the nerve's relatively smaller size. Although adequately visualized, the smaller cross-sectional area



would subject the measuring process to greater proportional inaccuracy. In addition, the reliability of the median nerve cross-sectional area using the wrist-to-forearm ratio was not as high as for the carpal tunnel inlet, with an inter-rater reliability value of 0.80. This finding was to be expected, as the wrist-to-forearm ratio is dependent on data from the mid-forearm.

Interestingly, and contrary to what may be expected, we found that a 1-week separation between test-retest sonography in fact resulted in higher inter-rater reliability than intra-rater reliability for cross-sectional area measurements of the median nerve at all locations.

Overall, the inter-rater reliability of the median nerve cross-sectional area at the level of the carpal tunnel inlet was the highest ( $r = 0.95$ ), whereas the intra-rater reliability rates for the sonographer and radiologist were lower ( $r = 0.88$  and  $0.86$ , respectively). This finding may suggest that a 1-week separation between test and retest may make a difference and that the median nerve cross-sectional area may fluctuate during this span of time.

Our findings also demonstrated different reliability between those individuals with carpal tunnel syndrome and healthy control participants. Overall, higher reliability was seen in the carpal tunnel syndrome cohort than the healthy control cohort. This finding was observed with median nerve cross-sectional area measurements at any of the 3 locations and reinforces the importance of reporting on the reliability of both cohorts rather than reporting on one cohort (either control or affected) and extrapolating that similar reliability would be achieved in the other population. As mentioned previously, to our knowledge, this study represents the first systematic examination to assess the inter- and intra-rater reliability for both those with diagnosed carpal tunnel syndrome and healthy control participants (sex and age matched).

In this study, both examiners individually captured their own images and traced them, but each examiner also separately traced the median nerve cross-sectional area of the other's captured images. Thus, with regard to the median nerve cross-sectional area at the carpal tunnel inlet, tracing of the captured image did not contribute significantly to variance of the measurements. Essentially, given an image, both the study sonographer and radiologist traced out the same cross-sectional area for the median nerve at the carpal tunnel inlet location. In fact, the very strong correlation between the examiners' tracings of the same image ( $r = 0.96-0.98$ ) indicates that accurate image acquisition plays a bigger role than who is tracing. The high reliability potentially suggests that images may be captured and measurements can be traced by those with varying levels of experience (but adequately trained on proper tracing parameters), thus allowing for greater efficiency and flexibility.

Limitations of the study included its relatively small sample size and reliability testing that was between 2 sonographers. In terms of the number of years of experience of our examiners, both might be considered to be experienced with sonography. However, for one examiner, the experience with carpal tunnel imaging was limited. Thus, the reliability results of this study may encompass the spectrum of sonographer experience levels that can be found across practice environments and can be generalizable.

In conclusion, we found both high intra- and inter-rater reliability for measurements of the cross-sectional area of the median nerve at the level of the carpal tunnel inlet, with lower

reliability seen at the level of the pronator quadratus and mid-forearm. In addition, the results also demonstrate that tracing of the median nerve cross-sectional area from captured images by different examiners does not contribute significantly to measurement variability.

## Acknowledgments

We thank Nancy Lane, MD, and Ellen Gold, PhD, for project support; Jeffrey Katz, MD, for expertise in the area of carpal tunnel syndrome; and John McGahan, MD, for assistance with manuscript preparation. This research was supported by funds from the National Institutes of Health (grant P50AR063043).

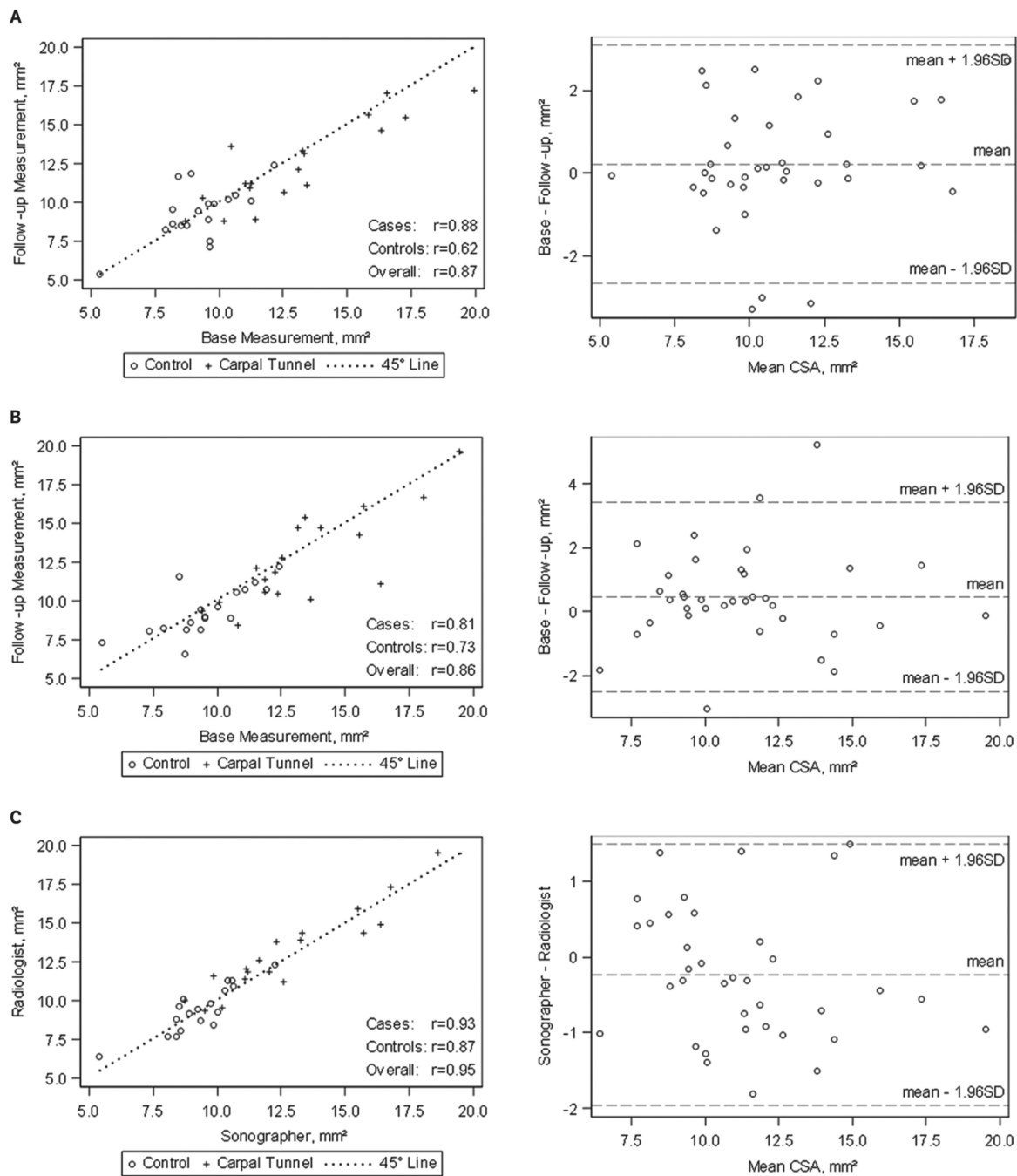
## Abbreviations

**BMI**      body mass index

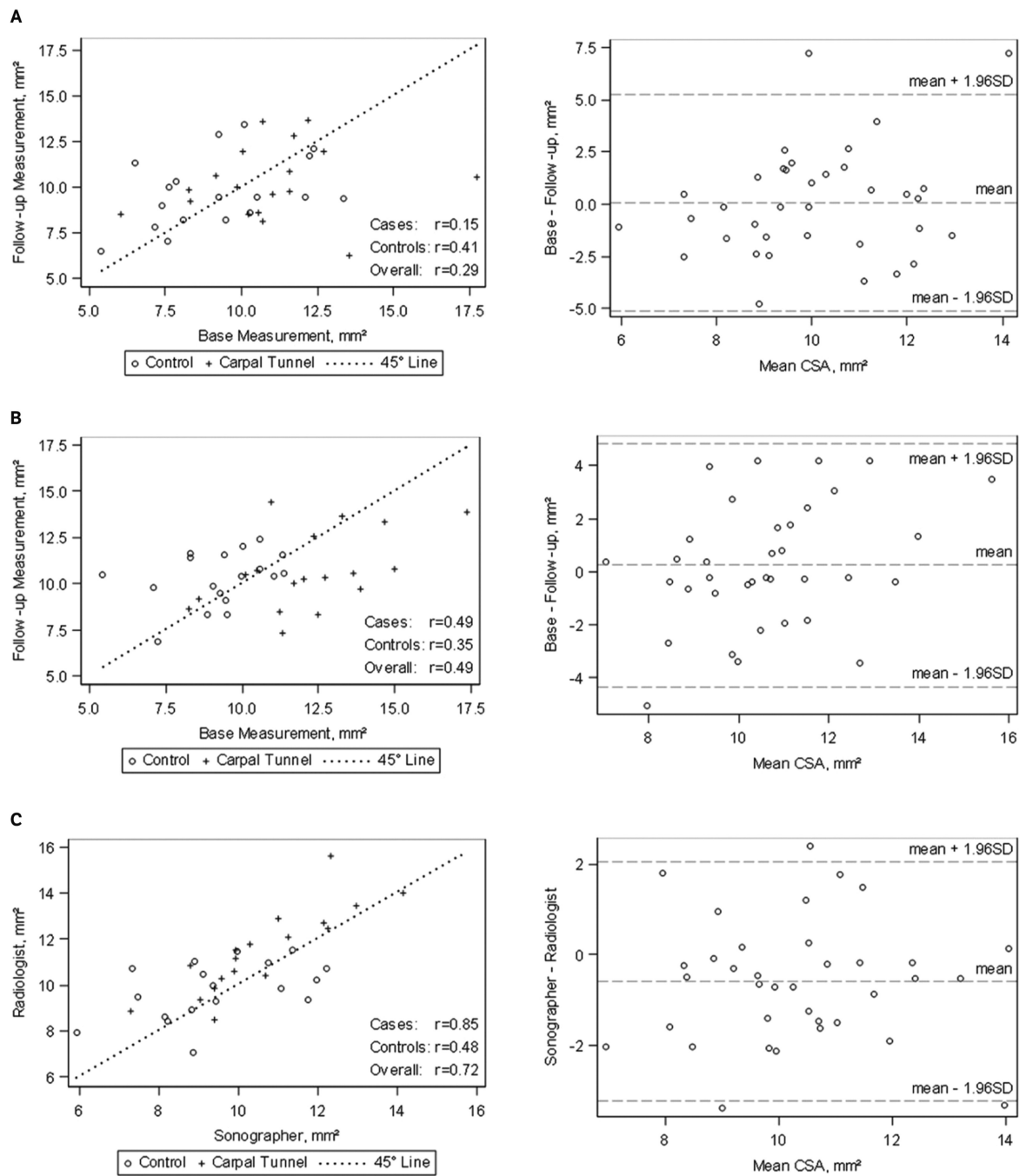
## References

1. Atroshi I, Gummesson C, Johnsson R, Ornstein E, Ranstam J, Rosén I. Prevalence of carpal tunnel syndrome in a general population. *JAMA*. 1999; 282:153–158. [PubMed: 10411196]
2. de Krom MC, Knipschild PG, Kester AD, Thijs CT, Boekkooi PF, Spaans F. Carpal tunnel syndrome: prevalence in the general population. *J Clin Epidemiol*. 1992; 45:373–376. [PubMed: 1569433]
3. Impink BG, Gagnon D, Collinger JL, Boninger ML. Repeatability of ultra-sonographic median nerve measures. *Muscle Nerve*. 2010; 41:767–773. [PubMed: 20513104]
4. Wong SM, Griffith JF, Hui AC, Lo SK, Fu M, Wong KS. Carpal tunnel syndrome: diagnostic usefulness of sonography. *Radiology* 2004. 232:93–99.
5. Ziswiler HR, Reichenbach S, Vögelin E, Bachmann LM, Villiger PM, Jüni P. Diagnostic value of sonography in patients with suspected carpal tunnel syndrome: a prospective study. *Arthritis Rheum*. 2005; 52:304–311. [PubMed: 15641050]
6. Tai TW, Wu CY, Su FC, Chern TC, Jou IM. Ultrasonography for diagnosing carpal tunnel syndrome: a meta-analysis of diagnostic test accuracy. *Ultrasound Med Biol*. 2012; 38:1121–1128. [PubMed: 22542258]
7. Roll SC, Case-Smith J, Evans KD. Diagnostic accuracy of ultrasonography vs electromyography in carpal tunnel syndrome: a systematic review of literature. *Ultrasound Med Biol*. 2011; 37:1539–1553. [PubMed: 21821353]
8. Beekman R, Visser LH. Sonography in the diagnosis of carpal tunnel syndrome: a critical review of the literature. *Muscle Nerve*. 2003; 27:26–33. [PubMed: 12508291]
9. Wong SM, Griffith JF, Hui ACF, Tang A, Wong KS. Discriminatory sono-graphic criteria for the diagnosis of carpal tunnel syndrome. *Arthritis Rheum*. 2002; 46:1914–1921. [PubMed: 12124876]
10. Roll SC, Evans KD, Li X, Freimer M, Sommerich CM. Screening for carpal tunnel syndrome using sonography. *J Ultrasound Med*. 2011; 30:1657–1667. [PubMed: 22124001]
11. Hobson-Webb LD, Massey JM, Juel VC, Sanders DB. The ultrasono-graphic wrist-to-forearm median nerve area ratio in carpal tunnel syndrome. *Clin Neurophysiol*. 2008; 119:1353–1357. [PubMed: 18387336]
12. Hunderfund AN, Boon AJ, Mandrekar JN, Sorenson EJ. Sonography in carpal tunnel syndrome. *Muscle Nerve*. 2011; 44:485–491. [PubMed: 21922467]
13. Klausner AS, Halpern EJ, De Zordo T, et al. Carpal tunnel syndrome assessment with US: value of additional cross-sectional area measurements of the median nerve in patients versus healthy volunteers. *Radiology*. 2009; 250:171–177. [PubMed: 19037017]
14. Kim HS, Joo SH, Cho HK, Kim YW. Comparison of proximal and distal cross-sectional areas of the median nerve, carpal tunnel, and nerve/tunnel index in subjects with carpal tunnel syndrome. *Arch Phys Med Rehabil*. 2013; 94:2151–2156. [PubMed: 23727345]

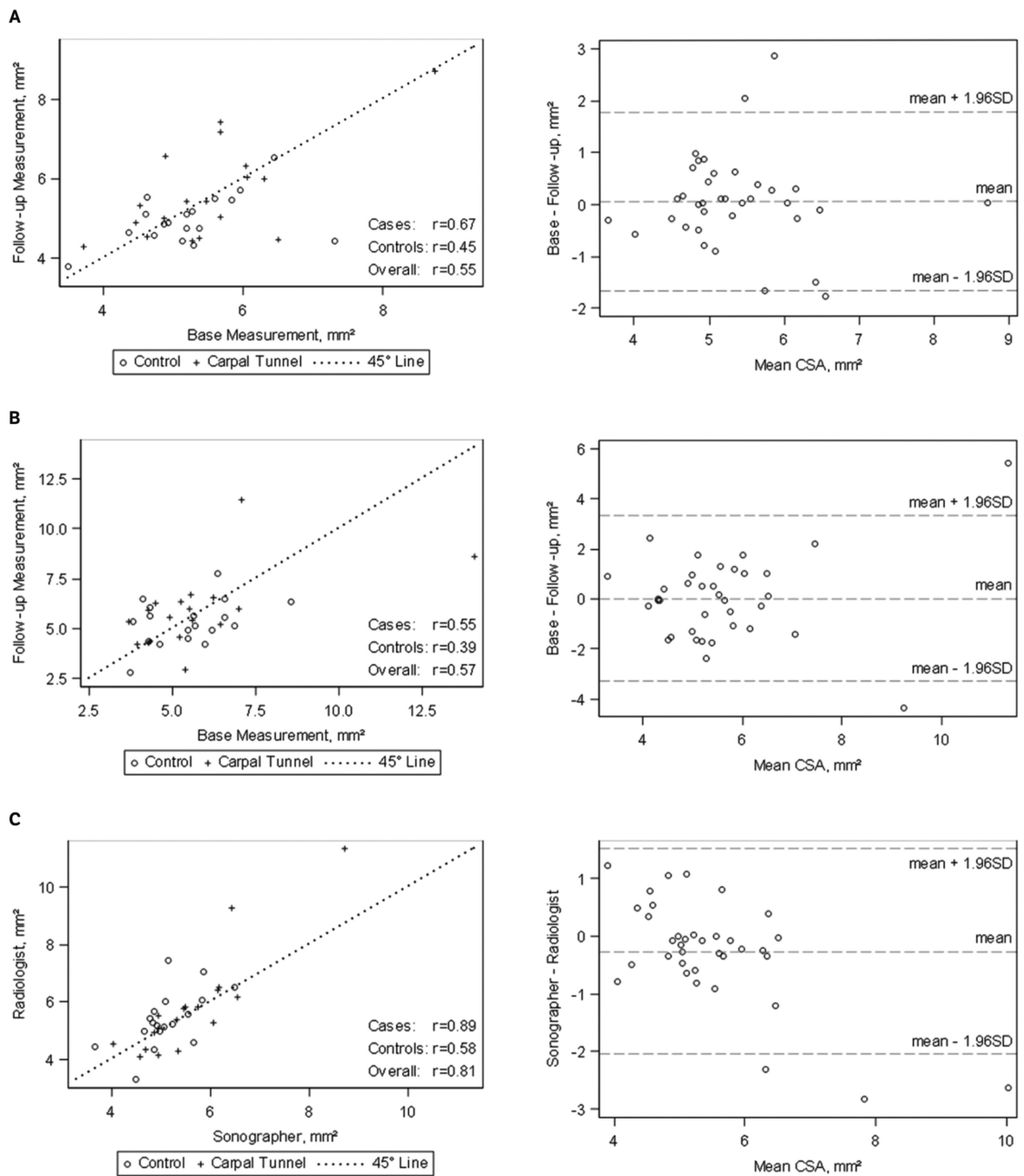
15. Mohammadi A, Ghasemi-Rad M, Mladkova-Suchy N, Ansari S. Correlation between the severity of carpal tunnel syndrome and color Doppler sonography findings. *AJR Am J Roentgenol.* 2012; 198:W181–W184. [PubMed: 22268209]
16. Evans KD, Roll SC, Volz KR, Freimer M. Relationship between intra-neural vascular flow measured with sonography and carpal tunnel syndrome diagnosis based on electrodiagnostic testing. *J Ultrasound Med.* 2012; 31:729–736. [PubMed: 22535720]
17. Mani B, Sarawagi R, Cherian RA. Review of the dimensions of the median nerve and carpal tunnel using sonography in asymptomatic adults. *J Med Imaging Radiat Oncol.* 2011; 55:126–131. [PubMed: 21501400]
18. Tagliafico A, Martinoli C. Reliability of side-to-side sonographic cross-sectional area measurements of upper extremity nerves in healthy volunteers. *J Ultrasound Med.* 2013; 32:457–462. [PubMed: 23443186]
19. Koyuncuoglu HR, Kutluhan S, Yesildag A, Oyar O, Guler K, Ozden A. The value of ultrasonographic measurement in carpal tunnel syndrome in patients with negative electrodiagnostic tests. *Eur J Radiol.* 2005; 56:365–369. [PubMed: 15994046]
20. Descatha A, Huard L, Aubert F, Barbato B, Gorand O, Chastang JF. Meta-analysis on the performance of sonography for the diagnosis of carpal tunnel syndrome. *Semin Arthritis Rheum.* 2012; 41:914–922. [PubMed: 22244369]
21. Kim DH, Marquardt TL, Gabra JN, et al. Pressure-morphology relationship of a released carpal tunnel. *J Orthop Res.* 2013; 31:616–620. [PubMed: 23184493]
22. Vögelin E, Nüesch E, Jüni P, Reichenbach S, Eser P, Ziswiler HR. Sonographic follow-up of patients with carpal tunnel syndrome undergoing surgical or nonsurgical treatment: prospective cohort study. *J Hand Surg Am.* 2010; 35:1401–1409. [PubMed: 20807617]
23. Wilkinson M, Grimmer K, Massy-Westropp N. Ultrasound of the carpal tunnel and median nerve: a reproducibility study. *J Diagn Med Sonogr.* 2001; 17:323–328.
24. Alemán L, Berná JD, Reus M, Martínez F, Doménech-Ratto G, Campos M. Reproducibility of sonographic measurements of the median nerve. *J Ultrasound Med.* 2008; 27:193–197. [PubMed: 18204009]
25. Filius A, Korstanje JW, Selles RW, Hovius SE, Slijper HP. Dynamic sono-graphic measurements at the carpal tunnel inlet: reliability and reference values in healthy wrists. *Muscle Nerve.* 2013; 48:525–531. [PubMed: 23897643]
26. Kim HS, Joo SH, Han ZA, Kim YW. The nerve/tunnel index: a new diagnostic standard for carpal tunnel syndrome using sonography—a pilot study. *J Ultrasound Med.* 2012; 31:23–29. [PubMed: 22215765]



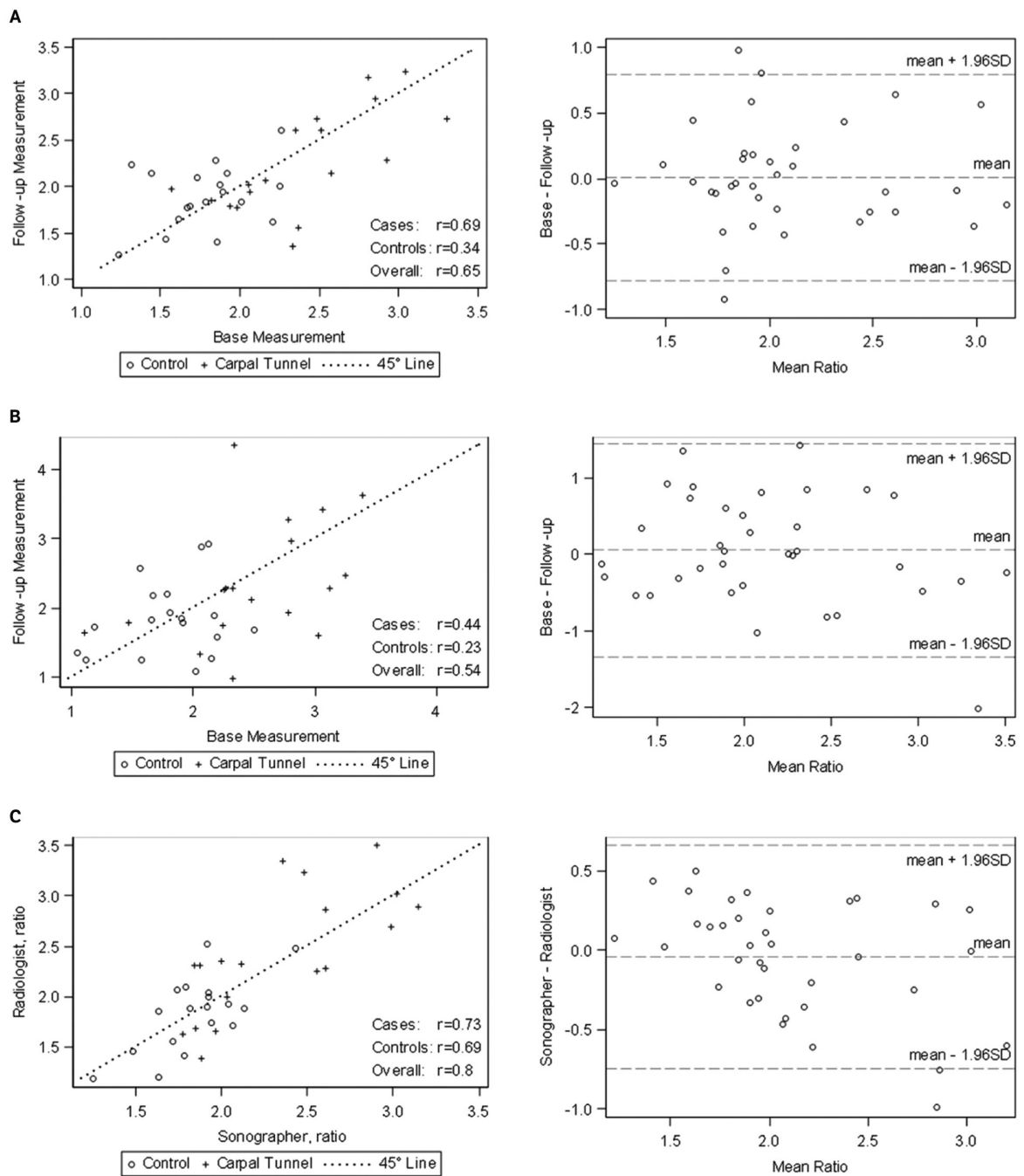
**Figure 1.** Scatterplots for median nerve cross-sectional area (CSA) at the carpal tunnel inlet by different raters and time points and Bland-Altman plots for intra- and inter-rater reliability. **A**, Sonographer: baseline versus follow-up. **B**, Radiologist: baseline versus follow-up. **C**, Sonographer versus radiologist: baseline and follow-up.



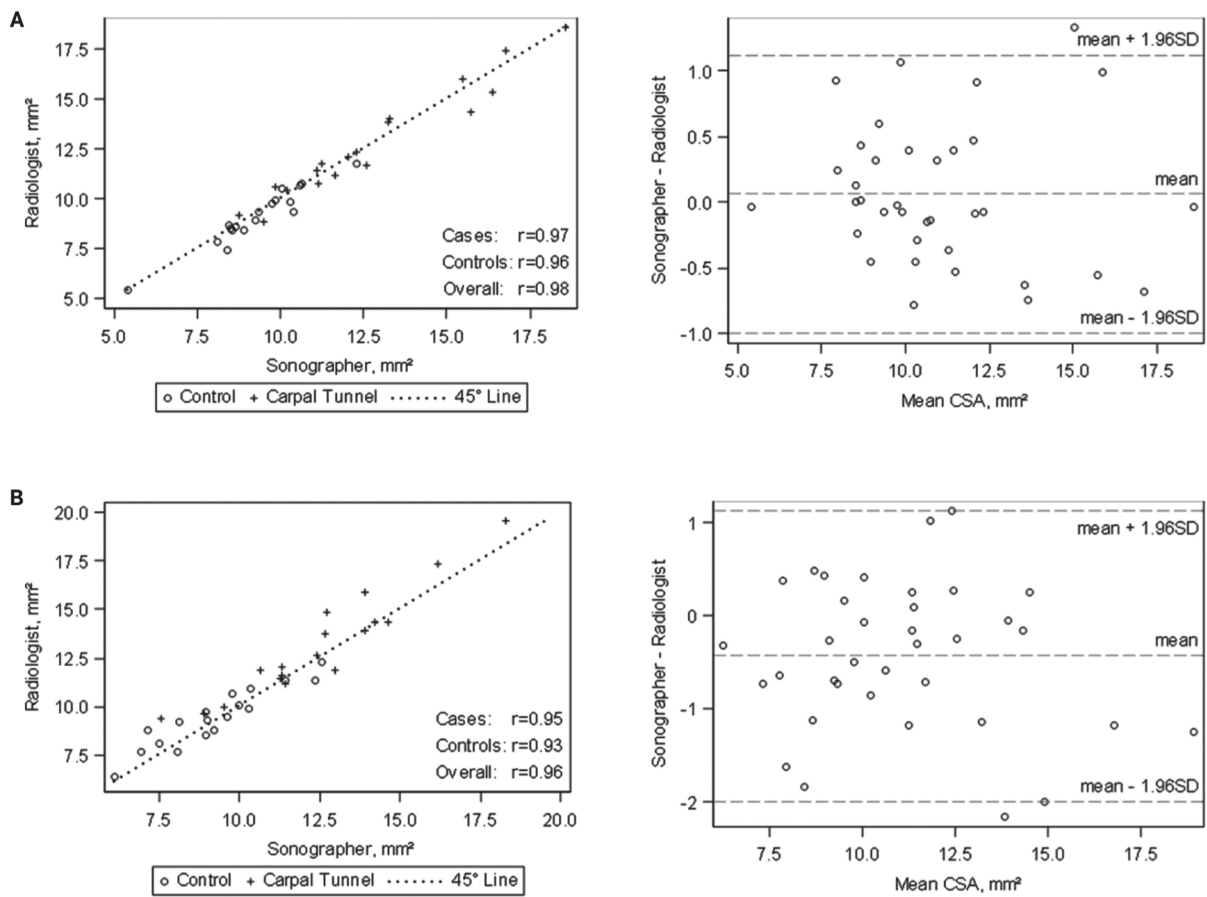
**Figure 2.** Scatterplots for median nerve cross-sectional area (CSA) at the pronator quadratus by different raters and time points and Bland-Altman plots for intra- and inter-rater reliability. **A**, Sonographer: baseline versus follow-up. **B**, Radiologist: baseline versus follow-up. **C**, Sonographer versus radiologist: baseline and follow-up.



**Figure 3.** Scatterplots for median nerve cross-sectional area (CSA) at the mid-forearm by different raters and time points and Bland-Altman plots for intra- and inter-rater reliability. **A**, Sonographer: baseline versus follow-up. **B**, Radiologist: baseline versus follow-up. **C**, Sonographer versus radiologist: baseline and follow-up.



**Figure 4.** Scatterplots for wrist-to-forearm ratio of the median nerve cross-sectional area by different raters and time points and Bland-Altman plots for intra- and inter-rater reliability. **A**, Sonographer: baseline versus follow-up. **B**, Radiologist: baseline versus follow-up. **C**, Sonographer versus radiologist: baseline and follow-up.



**Figure 5.**

**A**, Scatterplot and Bland-Altman plot for median nerve cross-sectional area (CSA) at the carpal tunnel inlet acquired by the sonographer and traced by the radiologist and sonographer. **B**, Scatterplot and Bland-Altman plot for median nerve cross-sectional area at the carpal tunnel inlet acquired by the radiologist and traced by the sonographer and radiologist.



**Table 1**

## Participant Characteristics for Control and Case Groups

Characteristic	Controls (n = 9)	Cases (n = 18)	P
Age, y (male)	45.8 ± 6.2	55.4 ± 5.6	.289
Age, y (female)	44.8 ± 9.5	55.3 ± 4.0	.243
Age, y (combined)	45.3 ± 15.2	55.3 ± 13.7	.096
Female, n (%)	4 (44.4)	10 (55.6)	.695
BMI, kg/m <sup>2</sup> (male)	25.9 ± 1.22	32.0 ± 2.46	.091
BMI, kg/m <sup>2</sup> (female)	23.9 ± 1.91	29.1 ± 1.87	.129
BMI, kg/m <sup>2</sup> (combined)	25.0 ± 3.22	30.4 ± 6.38	.025

Data are presented as mean ± SD where applicable; n indicates number of participants.

**Table 2**

Median Nerve Cross-sectional Areas at Different Locations for Control and Case Groups

Measurement	Controls (n = 18)	Cases (n = 18)	P
Sonographer			
Median nerve CSA at carpal tunnel inlet, mm <sup>2</sup>	9.3 ± 1.4	12.8 ± 2.8	<.001
Median nerve CSA at pronator quadratus, mm <sup>2</sup>	9.5 ± 1.8	10.6 ± 1.7	.068
Median nerve CSA at mid-forearm, mm <sup>2</sup>	5.1 ± 0.6	5.6 ± 1.1	.113
Radiologist			
Median nerve CSA at carpal tunnel inlet, mm <sup>2</sup>	9.4 ± 1.5	13.1 ± 2.7	<.001
Median nerve CSA at pronator quadratus, mm <sup>2</sup>	9.8 ± 1.3	11.5 ± 1.9	.003
Median nerve CSA at mid-forearm, mm <sup>2</sup>	5.4 ± 1.0	5.8 ± 1.8	.402

Data are presented as mean ± SD; CSA indicates cross-sectional area; and n, number of wrists.

**Table 3**

Intra- and Inter-Rater Reliability Coefficients for Case, Control, and Combined Case and Control Groups

Measurement	Intra-Rater Reliability, Sonographer			Intra-Rater Reliability, Radiologist			Inter-Rater Reliability		
	Cases	Controls	Cases & Controls	Cases	Controls	Cases & Controls	Cases	Controls	Cases & Controls
Median nerve CSA at carpal tunnel inlet	0.88	0.62	0.87	0.81	0.73	0.86	0.93	0.87	0.95
Median nerve CSA at pronator quadratus	0.15	0.41	0.29	0.49	0.35	0.49	0.85	0.48	0.72
Median nerve CSA at mid-forearm	0.67	0.45	0.55	0.55	0.39	0.57	0.89	0.58	0.81
Wrist-to-forearm ratio	0.69	0.34	0.65	0.44	0.23	0.54	0.73	0.69	0.80
Median nerve CSA at carpal tunnel inlet, image captured by sonographer and traced by radiologist (vs sonographer's own tracing)							0.97	0.96	0.98
Median nerve CSA at carpal tunnel inlet, image captured by radiologist and traced by sonographer (vs radiologist's own tracing)							0.95	0.93	0.96

CSA indicates cross-sectional area.