

# UC Davis

## Dermatology Online Journal

### Title

Extensive unilateral nevus comedonicus without genetic abnormality

### Permalink

<https://escholarship.org/uc/item/26w5j4cv>

### Journal

Dermatology Online Journal, 22(9)

### Authors

Chiriac, Anca  
Paduraru, Luminita  
Eusebiu, Gorduza Vlad  
et al.

### Publication Date

2016

### DOI

10.5070/D3229032509

### Copyright Information

Copyright 2016 by the author(s). This work is made available under the terms of a Creative Commons Attribution-NonCommercial-NoDerivatives License, available at <https://creativecommons.org/licenses/by-nc-nd/4.0/>

Peer reviewed

**Photo vignette**

**Extensive unilateral nevus comedonicus without genetic abnormality**

Anca Chiriac<sup>1</sup>, Luminita Paduraru<sup>2</sup>, Gorduza Vlad Eusebiu<sup>2</sup>, Constantine A Stratakis<sup>3</sup>, Christos C Zouboulis<sup>4</sup>

**Dermatology Online Journal 22 (9): 14**

<sup>1</sup> Apollonia University. Nicolina Medical Center, Dept.of Dermatology , Iasi, Romania

<sup>2</sup> University of Medicine and Pharmacy "Gr.T.Popa" Iasi , Iasi, Romania

<sup>3</sup> Section on Genetics & Endocrinology (SEGEN), Program on Developmental Endocrinology and Genetics (PDEGEN), NICHD, NIH, Bethesda, MD

<sup>4</sup> Departments of Dermatology, Venereology, Allergology and Immunology, Dessau Medical Center , Dessau,Germany

**Correspondence:**

Anca Chiriac  
ancachiriac@yahoo.com

---

**Abstract**

Nevus comedonicus is considered a genodermatosis characterized by the presence of multiple groups of dilated pilosebaceous orifices filled with black keratin plugs, with sharply unilateral distribution mostly on the face, neck, trunk, upper arms. Lesions can appear at any age, frequently before the age of 10 years, but they are usually present at birth.

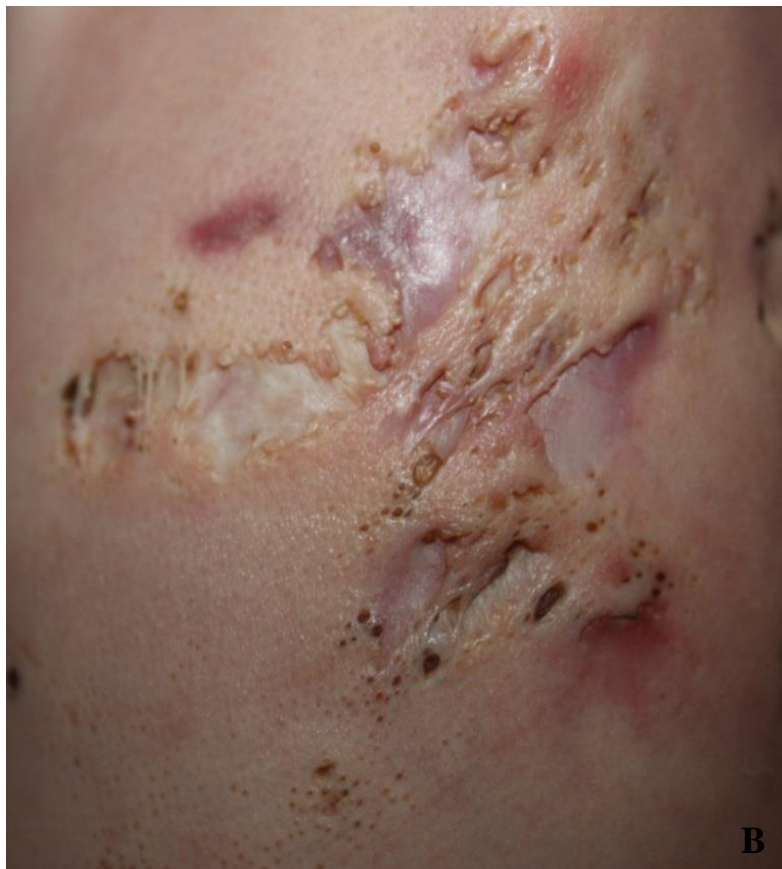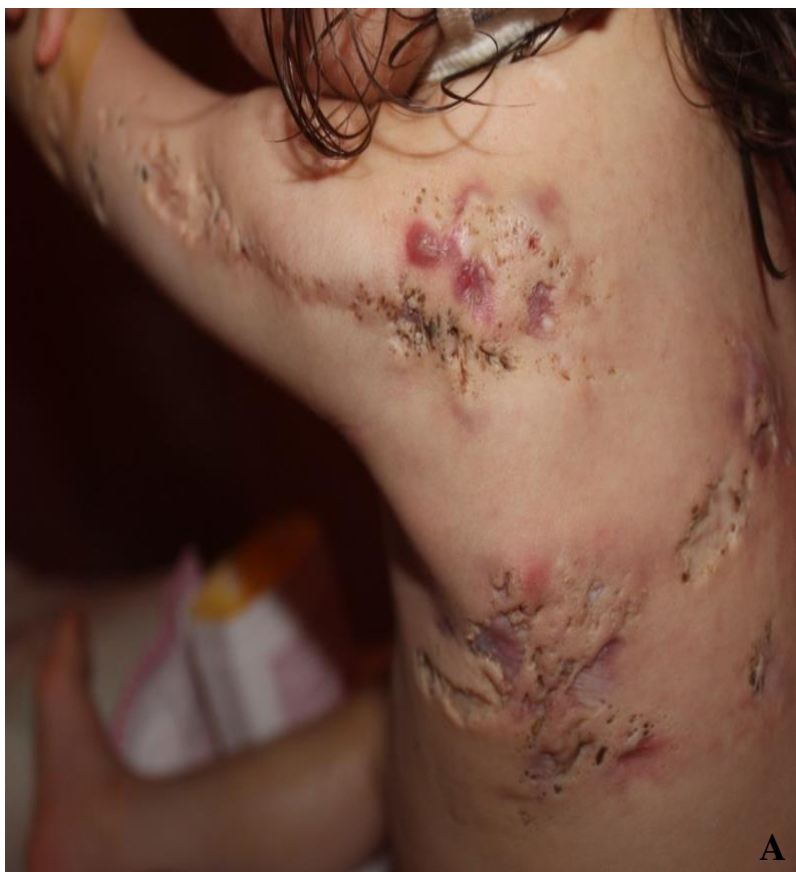We present a 2.7-year-old girl with a very severe form of nevus comedonicus. She exhibited lesions located initially at the left side of the body with a linear characteristic, following Blascko lines T1/T2, T5, T7, S1 /S2, but progressively developed lesions on the right side of the scalp and left gluteal area.

**Introduction**

Nevus comedonicus is considered to be a genodermatosis characterized by the presence of multiple groups of dilated pilosebaceous orifices filled with keratin plugs, with a sharply unilateral distribution located mostly on the face, neck, trunk, and upper arms. Lesions can appear at any age, frequently before the age of 10 years, but they are usually present to some extent at birth.

**Case synopsis**

A 2 year and 7 months old girl born of a non-consanguinous marriage was seen in the Dermatology Unit for mutiple nodulocystic swellings associated with intermittent pus discharge since birth, atrophic scars, fibrous tracts and grouped comedo-like pits scattered on the left side of the trunk, superior limb, retro-auricular area, left buttock and on the right side parietal part of the scalp.(Figure 1)



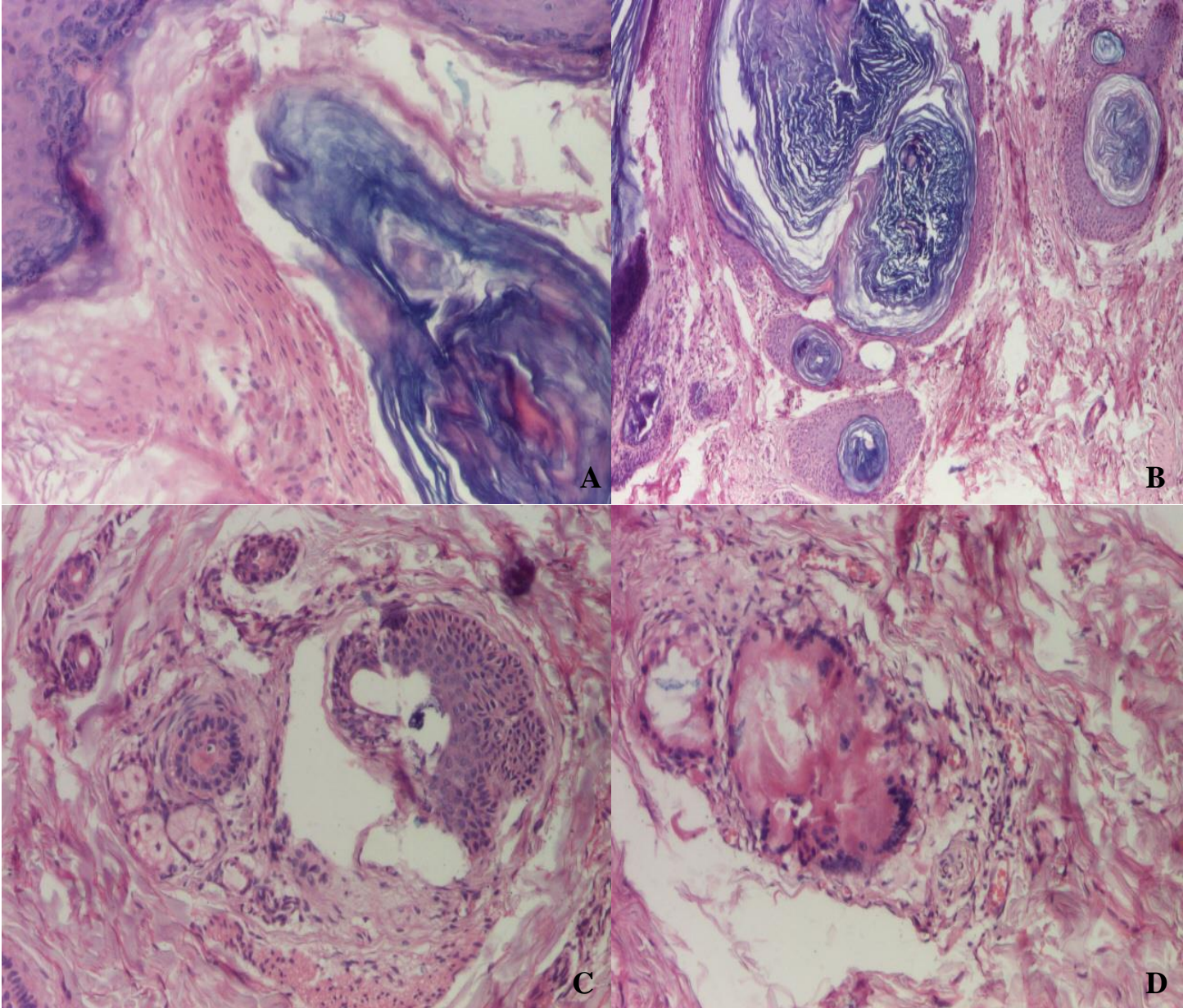
**Figure 1.** A) Multiple nodulocystic lesions, atrophic scars, fibrous tracts and grouped comedo-like pits scattered on the left side of the trunk, superior limb and the retro-auricular area, B) Close-up of the lesions on the left back

The first lesions were noticed on the left periareolar area. These progressively enlarged during the recent years and multiple similar lesions developed on the left side of the neck, trunk, arm, forearm, left buttock, and retro-auricular left area as well as right parietal region. Family history was negative, no present or history of systemic involvement was noticed since birth.



Examination revealed multiple groups of dilated pilo-sebaceous ostia filled with keratin plugs, which were very difficult to remove mechanically. In addition, infected cysts, scars, fibrotic masses, fistulae, and purulent discharge, and inflammatory papules were exhibited. Repeated routine laboratory investigations suggested a mild anemia.

Skin biopsies were performed and the histological report revealed hyperkeratosis and acanthosis of the epidermis (Figure 2A), large grouped, dilated follicular ostia filled with keratin (Figure 2B), absent of sebaceous glands or minimalized/hypoplastic sebaceous gland (Figure 2C), small cysts, cystic invaginations, and occasionally large cysts (Figure 2D). A severe nevus comedonicus was diagnosed and genetic counselling was requested. Genetic analysis of the normal and abnormal tissue found no significant abnormalities.



**Figure 2.** a) Hyperkeratosis and acanthosis of the epidermis (H & E, 100x), b) large grouped, dilated follicular ostia filled with keratin (H & E, 40x), c) atrophic sebaceous gland (H & E, 100x), d) cyst formation (H & E, 100x)

Since birth to present the child had received topical and systemic antibiotics and steroids with minimal impact on the progression of the disease or on the inflammatory component of skin lesions. Oral isotretinoin treatment has not been started yet owing to the young age of the patient.

## Discussion

Nevus comedonicus is caused by a defect in the development of the hair follicle [1]. The follicular structure that results is not able to form matrix cells or hair but just soft keratin that plugs the adnexal orifices and induces the formation of comedones [2]. Lesions may be present at birth or develop later, usually before the age of 10 years [1,3].

Based on the existence of inflammatory changes two types of nevus comedonicus have been described: non-pyogenic/comedonal type and inflammatory/pyogenic type with purulent discharge, atrophic scars, keloids, fistulae, and cysts [4]. Classically nevus comedonicus is described as unilateral, but reports of bilateral involvement are not rare [3-5]. The distribution of the lesions can be linear, interrupted, segmental, dermatomal, and along Blaschko lines, with contralateral involvement of the face and scalp [3]. Most commonly lesions are located on the face, neck, upper arms, trunk, and abdomen [1], but involvement of the scalp, female genital area, glans penis, and lower limbs, as well as of the pilosebaceous unit-free palms and soles have been reported [1,2,4,6,7]. Moreover, extensive nevus comedonicus affecting the whole half of the body has been documented [8].

## Conclusion

Interestingly, despite the severity and the extent of the lesions no molecular changes could be detected through means of clinical tests performed on the normal and abnormal tissue of the young patient.

## References

1. Chhabra N, Pandhi D, Verma P, Sharma S. Inflammatory nevus comedonicus with epidermoid cyst. *Indian J Dermatol* 2014;59:422. [PMID: 25071281]
2. Wood MG, Thaw MA, et al. Nevus comedonicus: A case with palmar involvement and review of the literature. *Arch Dermatol* 1968;98:111-116. [PMID: 5667222]
3. Sharma RP, Singh S P. Extensive unilateral nevus comedonicus with bilateral involvement of face. *Indian J Dermatol Venereol Leprol* 2001;67:195-196. [PMID: 23328782]
4. Paige TN, Mendelson CG. Bilateral nevus comedonicus. *Arch Dermatol* 1967;96:172-175. [PMID: 6043616]
5. Wakahara M, Kiyohara T, Kumakiri M, Kuwahara H, Fujita T. Bilateral nevus comedonicus: Efficacy of topical tacalcitol ointment. *Acta Derm Venereol* 2003;83:51. [PMID: 12636024]
6. Beerman H, Homan J. Nevus comedonicus. *Arch Klin Exp Dermatol* 1959;208:325-341.]
7. Gonzalez-Martinez R, Marin-Bertolin S, Martinez-Escribano J, Amorrortu-Velayos J. Nevus comedonicus. Report of a case with genital involvement. *Cutis* 1996;58:418-419. [PMID: 8970780]
8. Kirtak N, Inaloz HS, Karakok M, Erguven HG, Ozgoztasi O. Extensive inflammatory nevus comedonicus involving half of the body. *Int J Dermatol* 2004;43:434-436. [PMID: 15186225]