

UC Irvine

UC Irvine Previously Published Works

Title

An imaging-based approach to the evaluation of xerostomia

Permalink

<https://escholarship.org/uc/item/2658j9rz>

Journal

Lasers in Surgery and Medicine, 44(6)

ISSN

0196-8092

Authors

Duong, Steven
Youssef, Joseph
Pimenta, Paloma
et al.

Publication Date

2012-08-01

DOI

10.1002/lsm.22039

Copyright Information

This work is made available under the terms of a Creative Commons Attribution License, available at <https://creativecommons.org/licenses/by/4.0/>

Peer reviewed

Published in final edited form as:

Lasers Surg Med. 2012 August ; 44(6): 482–489. doi:10.1002/lsm.22039.

An Imaging-Based Approach to the Evaluation of Xerostomia

Steven Duong, BS^{1,2}, Joseph Youssef, BS^{1,2}, Paloma Pimenta, PhD³, Holly Aguigam, BS^{1,2}, Jun Zhang, PhD^{1,2}, Alden Calantog^{1,2}, Shira Pilch, PhD³, James G. Masters, PhD³, and Petra Wilder-Smith, DDS, PhD^{1,2,*}

¹Beckman Laser Institute, University of California, Irvine, California 92612

²University of California at Irvine, Irvine, California 92612

³Colgate-Palmolive Technology Center, 909 River Rd., Piscataway, New Jersey 08854

Abstract

Background and Objective—Goal was to evaluate the potential of *in vivo* optical coherence tomography (OCT) imaging to determine the response of patients with xerostomia to a dry mouth toothpaste versus fluoride tooth-paste placebo.

Study Design/Materials and Methods—Ten subjects with xerostomia participated in this double-blind, crossover, placebo-controlled study. After examination and OCT imaging, subjects used the first product for 15 days, followed by a 7-day washout period, and then they used the second product for 15 days. Data were acquired at 5-day intervals, also before and after the washout.

Results—Visual examination and tongue blade adhesion test did not reflect response to the product. Two imaging-based markers were identified: (1) In OCT images, epithelial thickness increased significantly ($P < 0.05$) after use of the dry mouth toothpaste, but did not change significantly ($P > 0.05$) after the use of a fluoride toothpaste and (2) Optical backscattering data showed progressive characteristic changes from baseline with use of the active product.

Conclusions—In this pilot study using *in vivo* OCT imaging, it was possible to detect and measure oral epithelial response to the dry mouth product versus placebo in patients with xerostomia.

Clinical Implications—This approach may permit site-specific assessment of xerostomia, individualized treatment planning and monitoring, and sequential mucosal mapping in patients with dry mouth.

Keywords

dry mouth intervention; imaging; optical coherence tomography

© 2012 Wiley Periodicals, Inc.

*Corresponding to: Dr. Petra Wilder-Smith, DDS, PhD, Associate Professor and Director of Dentistry, Beckman Laser Institute, University of California at Irvine, 1002 Health Sciences Rd East, Irvine, CA 92612. pwsmith@uci.edu.

Conflict of Interest Disclosures: All authors have completed and submitted the ICMJE Form for Disclosure of Potential Conflicts of Interest and none were reported.

Author's contribution: S.D. and J.Y.: imaging, data extraction; P.P.: study design, data interpretation, manuscript preparation; H.A., A.C.: imaging, data extraction, manuscript preparation; J.Z.: imaging, data extraction, and interpretation; S.P. and J.G.M.: study design, data interpretation and analysis, manuscript preparation; P.W.S.: study design and oversight, imaging, clinical examinations, data interpretation, manuscript preparation.

INTRODUCTION

Dry mouth is a common oral condition, with an estimated prevalence in 20–40% of the population [1,2]. Higher levels are documented in the elderly and in women [3]. Causes include the following:

- A common side effect of many prescription and non-prescription drugs, including drugs used to treat depression, anxiety, pain, allergies, colds, obesity, acne, epilepsy, hypertension, diarrhea, nausea, psychotic disorders, urinary incontinence, asthma, and Parkinson's disease. Muscle relaxants and sedatives, as well as tobacco use, are also implicated. The list of drugs includes >400 agents [1].
- Many medical conditions, including diabetes, Sjögren's syndrome (SS), HIV/AIDS, Alzheimer's disease, anemia, cystic fibrosis, rheumatoid arthritis, hypertension, Parkinson's disease, stroke, and mumps [1].
- Salivary gland damage, for example, from radiation to the head and neck, or from chemotherapy for cancer [1].
- A result of nerve damage to the head and neck area from an injury or surgery [1].

Saliva serves important functions in the mouth including remineralization of teeth [4,5], lubricating the oral mucosa of the mouth, facilitating speech, eating, swallowing, and preventing mechanical injury to the surfaces of the mouth. Saliva and salivary flow also help prevent the accumulation of microorganisms in the mouth [4,5] including cavity-causing bacteria. Salivary flow and constituents, such as amylase, initiate digestion of foods and help dissolve and remove food particles from the mouth and salivary components have antibacterial, antifungal, and antiviral properties [6]. Current standard of care for evaluating dry mouth includes mucosal appearance, tongue blade adhesion test, saliva collection over a fixed time period and patient self-evaluation using a standard questionnaire [1,2,7]. These approaches, although generally accepted and frequently used have significant limitations. They are subjective in nature and often require a large patient sample size in order to maximize chances of obtaining useful results [1,2]. Additionally, current methodologies are not sensitive to small, subtle changes that may take place within the oral mucosa at the microstructural level, as a result of xerostomia and/or during the course of its treatment.

The inability to assess xerostomia on an individual basis, in a quantifiable and non-subjective manner, to individualize treatment planning or to evaluate the effectiveness of dry mouth interventions using existing conventional approaches is a significant clinical problem and a limiting factor in the validation of outcome measures in interventional clinical studies. Although some useful information may be obtained using current evaluation approaches with a large enough patient sample size, methodologies that enable the assessment and quantification of small changes within the microstructure of the oral mucosa are desired, in order to improve upon the limitations of current approaches by allowing accurate and reproducible assessment of xerostomia and treatment effect on an individual basis.

Optical coherence tomography (OCT) is an emergent imaging modality that generates high-resolution microstructural images, which can also be analyzed for site-specific backscattering data based on coherence-domain optical technology. OCT has most often been compared to ultrasound imaging. Both technologies employ backscattered signals reflected from different layers within the tissue to reconstruct structural images, with the latter measuring sound rather than light. The resulting OCT image is a two-dimensional representation of the optical reflection within a tissue sample. Cross-sectional images of tissues are constructed in real time, at near histologic resolution (approximately 5–15 μm with current technology). These images can be stacked to generate 3D reconstructions of the target tissue, such as epithelial and subepithelial structures.

OCT was first introduced as an imaging technique in biological systems in 1991 [8]. The non-invasive nature of this imaging modality coupled with (i) a penetration depth of 2–3 mm, (ii) high resolution (5–15 μm), (iii) real-time image viewing, and (iv) capability for cross-sectional as well as 3D tomographic images, provide excellent prerequisites for *in vivo* oral diagnosis. Several studies have sought to investigate the diagnostic utility of *in vivo* OCT in the oral cavity, for applications including oral soft tissue lesions [9,10–14], oral mucositis [15,16], periodontal disease [17], orthodontics [18], hard dental tissues [19–25], and endodontics [26,27]. Studies investigating somewhat different OCT approaches, such as polarization-sensitive OCT, have also been published [28–34].

Several OCT systems have received FDA approval for clinical use, and OCT is deemed by many as an essential imaging modality in ophthalmology. *In vivo* image acquisition is facilitated through the use of a flexible fiber-optic OCT probe, which is placed on the surface of the tissue to generate real-time, immediate surface and sub-surface images of tissue microanatomy.

Goal of this pilot study was to (i) evaluate the potential of *in vivo* OCT imaging and (ii) identify potential markers to determine the response of patients with clinically diagnosed moderate to severe dry mouth to the use of a dry mouth toothpaste versus a placebo.

MATERIALS AND METHODS

Protocol

This research was executed in full compliance with UCI IRB approval #2002–2805. Informed consent was obtained from all subjects prior to their enrollment in the study. Ten subjects previously diagnosed with moderate to severe dry mouth (7 female, 3 male; age from 37 to 53 with a mean age of 48) were enrolled in this randomized, double-blind, crossover, placebo-controlled study. Two products that were packaged identically and coded for content were tested. One product was a dry mouth tooth-paste and the other was a placebo (regular fluoride tooth-paste). After a baseline clinical exam consisting of photographs and OCT imaging, subjects used their first assigned dentifrice to brush their teeth for 15 days. A 7-day wash out period using Colgate Cavity Protection toothpaste was followed by a second 15-day period using the second assigned dentifrice. The sequence of product use was randomized. Standard toothbrushes and floss were also provided to the subjects; no other form of oral healthcare (rinses, gels, gum, etc.) was permitted. Subjects were required to inform the investigators about any potential new medications that might interfere with the study, including but not limited to antibiotics, antiseptics, decongestants, and antihistamines. OCT imaging and a clinical examination, a dry mouth questionnaire and photographs were acquired at 5-day intervals during use of the investigational dentifrices, and at the beginning and end of the 7-day washout period.

Clinical Examination

Adhesion of a standard wooden tongue blade to the left and right buccal mucosa, the dorsal and ventral surfaces of the tongue and the lip was determined by one blinded clinician (PWS) at each time point. Adhesion was scored as “yes” (score 1) or “no” (score 0) for each site; the lower the cumulative score, the more moist was the mouth, and the higher the score, the drier was the mouth. Scores were added up for each time point to generate an overall semi-quantitative tongue blade adhesion score on each evaluation day for each subject.

Self-Evaluation Questionnaire

At each time point of the study, subjects’ responses to a standard dry mouth questionnaire [7] were semi-quantified on a scale of 0–5, with 5 representing the most severe perception of

the specific symptom, and 0 representing the absence of each specific symptom. Questionnaire scores were added up for each time point to generate an overall semi-quantitative dry mouth score for each evaluation day; the higher the score, the worse were the perceived symptoms of dry mouth.

OCT Imaging

All subjects were imaged using the same commercially available Niris[®] OCT console and imaging probe (Fig. 1; Imalux Corporation, Cleveland, OH), which allows real-time video rate imaging speed, simultaneous OCT and CCD imaging channels, 3D volumetric imaging and surface profiling capability at an imaging depth of up to 50 μm . The imaging system has approximately 8–15- μm depth resolution and 20- μm lateral resolution. For each subject, the flexible fiberoptic probe was disinfected by immersion in CIDEX and then covered with a new, sterile probe sheath. OCT images were acquired at each time point at 11 standard oral sites: left and right buccal mucosa, left and right floor of mouth, left, and right side of tongue approximately 3 cm from tip, dorsal, and ventral surfaces of tongue approximately 3 cm from tip, left and right vermillion border of lower lip half way between center and angle of mouth, and highest point of palate. Prior to imaging, photographs of the oral cavity were recorded, and during imaging, OCT scan lines were marked on the photographic images using Photoshop to ensure accurate re-localization of scans at subsequent visits.

Imaging Data

From each image, at four standardized locations per image, epithelial thickness was measured, by superimposing a grid on the OCT image and measuring at 1 mm intervals across the width of the scan. A backscattering signal was determined directly from the optical scan data by using proprietary software from the Imalux[®] system to quantify the optical signal at 1 pixel increments on individual images. Optical measurements were made at the same locations as the epithelial thickness determinations. All measurements were performed by two blinded scorers pre-standardized to 95% accuracy from our OCT image databank. This process was repeated after 1 month to evaluate intra-scorer and inter-scorer variability.

Analysis

The predefined primary efficacy variable was the change in thickness of the epithelium at four specific landmark locations for each imaging site, at each time point. A secondary variable for analysis was the optical reflectance changes at the epithelial surface and at depth intervals of 1 pixel down to 2 mm, measured at the four standardized locations. For microstructural measurements, data for each patient were averaged across all scan sites for each time point. For the optical data, ratios between specific points on the line graphs of intensity versus depth were used (Fig. 2). Data were compared using repeated measures ANOVA with one within-group factor (before vs. after) and one between-group factor (treatment). After adjusting for any between-subject differences, the significance of the interaction factor for time by treatment (F -test with 1 df) provides a test for differences over time between the active and placebo groups.

RESULTS

Clinical Evaluation

The tongue blade adhesion test did not detect changes in oral dryness in a meaningful way. Improvements in dryness were detected in 4/10 subjects after use of the dry mouth toothpaste and in 5/10 subjects after use of the placebo and/or washout. Thus, upon

evaluation of a sample size of ten patients, measurements were not sufficiently consistent to be useful in evaluating a specific dry mouth intervention.

Self-Evaluation Questionnaire

Dry mouth questionnaire responses among the 10 patients were not consistent and therefore did not provide a meaningful evaluation of patient response to dry mouth treatments. In one subject, based on the dry mouth questionnaire, the active product and the washout toothpaste were deemed to be ineffective, whereas the placebo product was perceived to progressively worsen the symptoms of dry mouth, especially after >10 days of use. No trends could be identified based on subject questionnaire data in six subjects. Throughout the course of the study, a feeling of progressive improvement was expressed by two subjects, whereas a perceived progressive worsening was expressed in another subject. In these three subjects, this observation was unrelated to the product used, be it active, placebo, or washout product.

OCT Imaging Data

The OCT imaging required <1 second per scan. Using a simple fiberoptic probe that resembles a pen, images were produced almost immediately and the procedure was very well tolerated by patients.

- A. Based on the OCT images, average, epithelial thickness increased significantly ($P < 0.05$) after use of the dry mouth toothpaste for 15 days (Table 1), but did not change significantly ($P > 0.05$) after use of a regular fluoride toothpaste placebo or washout product. In the OCT images, epithelial and subepithelial tissues subjectively appeared thicker, denser, and plumper after the use of the dry mouth toothpaste than after regular fluoride toothpaste used as washout and placebo (Fig. 2).
- B. In the baseline log plots of backscattering intensity (y-axis) versus tissue depth (x-axis) images, there was at first an intense backscattered signal at the air-epithelial interface, with the rest of the signal becoming progressively less intense with increasing depth into the sample (Fig. 3). With use of the dry mouth product, optical scattering data showed progressive and characteristic changes from baseline. The signal ratio between epithelial surface and overlying air (Ratio B:A) decreased significantly ($P < 0.05$) after 5 days use of the active product, with another significant decrease ($P < 0.05$) after 15 days use. A similar, but somewhat weaker trend was observed for the ratio between epithelial surface and subsurface epithelium (Ratio B:C). Treatment-related changes in backscatter were confined to the most superficial 750–1,000 μm of the oral mucosa.

Figure 4 is a compilation of representative data for subject 1 showing a measureable increase in epithelial thickness and a considerable reduction in the B/A ratio in response to the active dry mouth toothpaste. However, no discernible responses to the toothpastes are apparent using self-scoring and tongue blade test.

DISCUSSION

Current techniques are limited in their ability to diagnose and quantitatively measure dry mouth with the necessary precision and reproducibility. Furthermore, these current approaches cannot quantify, map and track specific mucosal changes during the course of xerostomia or its treatment [1,2]. Results from this study were in agreement with the literature, determining that standard dry mouth questionnaires and clinical examinations are not well suited to quantify oral response to dry mouth treatments on an individual basis.

Using *in vivo* OCT imaging, we were able to establish two markers for response to dry mouth intervention: mucosal microarchitecture and the depth-resolved backscattering signal intensity from the mucosa. The progression of specific microstructural events occurring at specific sites to a depth of 2 mm within the oral mucosa was successfully quantified and mapped in these subjects. OCT images showed reversal of xerostomia-induced mucosal thinning including a more consistent surface keratinized layer of the epithelium, a thicker epithelial layer and a denser subepithelial layer resulting from treatment using dry mouth toothpaste (the active). Additionally, characteristic, quantifiable, simple optical measures of mucosal rehydration were identified and validated using backscattering data extracted from OCT images. One possible explanation for the change in optical backscatter seen as a result of dry mouth treatment may be that the more hydrated tissues absorb more of the OCT light at 1,310 nm [35], resulting in a smaller signal that is returned to the detection fiber of the OCT system.

Because this was a very limited feasibility study, we did not analyze the data for gender-based differences, nor did we evaluate the hormonal status of the four younger women enrolled in this study. It is known that hormonal status can influence epithelial thickness, including oral epithelia and this will be an interesting concept to pursue in future, larger studies.

Recent studies have indicated that complex microstructural and vascular components of xerostomia-related mucosal damage exists [36–38]. However, there is little specific *in vivo* information regarding pathways of mucosal damage in xerostomia patients. The approach outlined in these *in vivo* studies for the first time provides a means of tracking these events in patients to gain a better understanding of the process, which can lead to the development of superior, more specific interventions for specific categories of xerostomia. Important applications for clinical research include cancer-therapy-induced xerostomia, medication-induced dry mouth, as well as a diverse range of medical conditions (such as diabetes, Sjögren's syndrome, HIV/AIDS, rheumatoid arthritis, hypertension, Parkinson's disease, stroke, and mumps).

CONCLUSIONS

In this pilot study, the authors identified markers and established the basis for developing and validating a novel, non-invasive, *in vivo* imaging approach to clinically (i) evaluating dry mouth, (ii) quantifying the effectiveness of specific interventions for this condition, and (iii) mapping at high resolution the surface and subsurface mucosal effects of dry mouth and its mitigation. Using *in vivo* OCT imaging, the authors were able to detect and measure oral epithelial response to the use of a dry mouth tooth-paste in patients diagnosed with moderate to severe xerostomia.

CLINICAL IMPLICATIONS

Current techniques are not able to quantify adequately the effects of dry mouth on the oral mucosa during the course of xerostomia and its treatment. This pilot study demonstrated a novel *in vivo* imaging approach, which will potentially permit:

- Accurate site-specific assessment of dry mouth.
- Individualized treatment planning and monitoring.
- *In vivo* evaluation of the effects of dry mouth and of interventional effectiveness in individuals and specific populations using two sets of indicators.
- Optical indices of hydration.

- Microstructural analysis of the oral mucosa.
- A sequential site-specific high-resolution map of mucosal and events as components of mucosal damage and potential therapy-induced mitigation in patients with xerostomia.

Thus, these preliminary studies provide the basis for a clinical imaging approach that may potentially overcome (i) our current inability to evaluate and quantify the effects of dry mouth accurately and in a non-subjective manner, (ii) our very limited ability to validate outcome measures in interventional clinical studies of xerostomia, and (iii) an important barrier to clinical research.

Acknowledgments

Contract grant sponsor: NIH; Contract grant numbers: 5P41RR001192-32; K25HL-102055; Contract grant sponsor: The Tobacco-Related Disease Research Program; Contract grant number: 19KT-0034; Contract grant sponsor: Colgate Palmolive Company.

References

1. Atkinson JC, Grisius M, Massey W. Salivary hypofunction and xerostomia: Diagnosis and treatment. *Dent Clin North Am.* 2005; 49:309–326. [PubMed: 15755407]
2. Cho MA, Ko JY, Kim YK, Kho HS. Salivary flow rate and clinical characteristics of patients with xerostomia according to its aetiology. *J Oral Rehabil.* 2010; 37(3):185–193. [PubMed: 20002531]
3. NIDCR/CDC. [February 8, 2012] Dental, Oral and Craniofacial Data Resource Center. http://drc.hhs.gov/report/14_1.htm
4. Nederfors T, Isaksson R, Mornstad H, Dahlof C. Prevalence of perceived symptoms of dry mouth in an adult Swedish population-relation to age, sex and pharmacotherapy. *Community Dent Oral Epidemiol.* 1997; 25:211–216. [PubMed: 9192149]
5. Narhi TO, Meurman JH, Ainamo A. Xerostomia and hyposalivation: Causes, consequences and treatment in the elderly. *Drugs Aging.* 1999; 15:103–116. [PubMed: 10495070]
6. Astor FC, Hanft KL, Ciocon JO. Xerostomia: A prevalent condition in the elderly. *Ear Nose Throat J.* 1999; 78:476–479. [PubMed: 10429321]
7. Ami S, Wolff A. Implant-supported electrostimulating device to treat xerostomia: A preliminary study. *Questionnaire Clin Implant Dent Relat Res.* 2010; 12:1.
8. Huang D, Swanson EA, Lin CP. Optical coherence tomography. *Science.* 1991; 254:178–1181.
9. Tsai MT, Lee CK, Lee HC, Chen HM, Chiang CP, Wang YM, Yang CC. Differentiating oral lesions in different carcino-genesis stages with optical coherence tomography. *J Biomed Opt.* 2009; 14(4):044028. [PubMed: 19725739]
10. Tsai MT, Lee HC, Lee CK, Yu CH, Chen HM, Chiang CP, Chang CC, Wang YM, Yang CC. Effective indicators for diagnosis of oral cancer using optical coherence tomography. *Opt Expr.* 2008; 16(20):15847–15862.
11. Wilder-Smith P, Lee K, Guo S, Zhang J, Osann K, Chen Z, Messadi D. In-vivo diagnosis of oral dysplasia and malignancy using optical coherence tomography: Preliminary studies in 50 patients. *Lasers Surg Med.* 2009; 41:353–357. [PubMed: 19533765]
12. Ozawa N, Sumi Y, Chong C, Kurabayashi T. Evaluation of oral vascular anomalies using optical coherence tomography. *Br J Oral Maxillofac Surg.* 2009; 47(8):622–626. [PubMed: 19398253]
13. Jerjes W, Upile T, Conn B, Hamdoon Z, Betz CS, McKenzie G, Radhi H, Vourvachis M, El Maaytah M, Sandison A, Jay A, Hopper C. In vitro examination of suspicious oral lesions using optical coherence tomography. *Br J Oral Maxillofac Surg.* 2010; 48(1):18–25. [PubMed: 19726114]
14. Wilder-Smith P, Holtzman J, Epstein J, Le A. Optical diagnosis in the oral cavity: An overview. *Oral Dis.* 2010; 16:717–728. [PubMed: 20561224]

15. Kawakami-Wong H, Guo S, Hammer-Wilson MJ, Epstein JB, Chen Z, Wilder-Smith P. In vivo optical coherence tomography-based scoring of oral mucositis in human subjects: A pilot study. *J Biomed Opt.* 2007; 12:051702. [PubMed: 17994875]
16. Muanza TM, Cotrim A, McAuliffe M, Sowers A, Baum B, Cook J, Feldchtein F, Amazeen P, Coleman CN, Mitchel JB. Evaluation of radiation-induced oral mucositis by optical coherence tomography. *Clin Cancer Res.* 2005; 11:5121–5127. [PubMed: 16033826]
17. Colston BW Jr, Everett MJ, Da Silva LB, Otis LL, Stroeve P, Nathel H. Imaging of hard- and soft-tissue structure in the oral cavity by optical coherence tomography. *Appl Opt.* 1998; 37(16):3582–3585. [PubMed: 18273327]
18. Baek JH, Na J, Lee BH, Choi E, Son WS. Optical approach to the periodontal ligament under orthodontic tooth movement: A preliminary study with optical coherence tomography. *Am J Orthod Dentofacial Orthop.* 2009; 135(2):252–259. [PubMed: 19201333]
19. Brezinski, ME. *Optical coherence tomography: Principles and applications.* Burlington, San Diego, London: Academic Press; 2006.
20. Colston BW, Sathyam US, DaSilva LB, Everett MJ, Stroeve P. Dental OCT. *Opt Express.* 1998; 3:230–238. [PubMed: 19384365]
21. Feldchtein FI, Gelikonov GV, Gelikonov VM, Iksanov RR, Kuranov RV, Sergeev AM, Gladkova ND, Ourutina MN, Warren JA, Reitze DH. In vivo OCT imaging of hard and soft tissue of the oral cavity. *Opt Express.* 1998; 3:239–251. [PubMed: 19384366]
22. Otis LL, Everett MJ, Sathyam S, Colston BW. Optical coherence tomography: A New imaging technology for dentistry. *JADA.* 2000; 131:511–514. [PubMed: 10770016]
23. Li J, Bowman C, Fazel-Rezai R, Hewko M, Choo-Smith LP. Speckle reduction and lesion segmentation of OCT tooth images for early caries detection. *Conf Proc IEEE Eng Med Biol Soc.* 2009; 1:1149–1452.
24. Holtzman JS, Osann K, Pharar J, Lee K, Ahn Y-C, Tucker T, Sabet S, Chen Z, Gukasyan R, Wilder-Smith P. Ability of optical coherence tomography to detect caries beneath commonly used dental sealants. *Lasers Surg Med.* 2010; 42:752–759. [PubMed: 20848554]
25. Wilder-Smith C, Wilder-Smith P, Kawakami-Wong H, Voronets J, Osann K, Lussi A. Quantification of dental erosions in patients with GERD using Optical Coherence Tomography before and after double-blind, randomised treatment with esomeprazole or placebo. *Am J Gastroenterol.* 2009; 104:2788–2795. [PubMed: 19654570]
26. Shemesh H, van Soest G, Wu MK, van der Sluis LW, Wesselink PR. The ability of optical coherence tomography to characterize the root canal walls. *J Endod.* 2007; 33(11):1369–1373. [PubMed: 17963966]
27. Todea C, Balabuc C, Sinescu C, Filip L, Kerezsi C, Calniceanu M, Negrutiu M, Bradu A, Hughes M, Podoleanu AG. En face optical coherence tomography investigation of apical microleakage after laser-assisted endodontic treatment. *Lasers Med Sci.* 2010; 25(5):629–639. [PubMed: 19455366]
28. Manesh SK, Darling CL, Fried D. Polarization-sensitive optical coherence tomography for the nondestructive assessment of the remineralization of dentin. *J Biomed Opt.* 2009; 14(4):044002. [PubMed: 19725714]
29. Chen Y, Otis L, Piao D, Zhu Q. Characterization of dentin, enamel, and carious lesions by a polarization-sensitive optical coherence tomography system. *Appl Opt.* 2005; 44:2041–2048. [PubMed: 15835353]
30. Jones RS, Darling CL, Featherstone JD, Fried D. Remineralization of in vitro dental caries assessed with polarization-sensitive optical coherence tomography. *J Biomed Opt.* 2006; 11:014016. [PubMed: 16526893]
31. Jones RS, Fried D. Remineralization of enamel caries can decrease optical reflectivity. *J Dent Res.* 2006; 85(9):804–808. [PubMed: 16931861]
32. Ngaotheppitak P, Darling CL, Fried D. Measurement of the severity of natural smooth surface (interproximal) caries lesions with polarization sensitive optical coherence tomography. *Lasers Surg Med.* 2005; 37:78–88. [PubMed: 15889402]

33. Chong SL, Darling CL, Fried D. Nondestructive measurement of the inhibition of demineralization on smooth surfaces using polarization-sensitive optical coherence tomography. *Lasers Surg Med.* 2007; 39:422–427. [PubMed: 17565731]
34. Jones RS, Staninec M, Fried D. Imaging artificial caries under composite sealants and restorations. *J Biomed Opt.* 2004; 9(6):1297–1304. [PubMed: 15568951]
35. Tuan, V-D., editor. *Biomedical photonics handbook*. London: CRC Press; p. 28-32.
36. Gerli R, Vaudo G, Bocci EB, Schillaci G, Alunno A, Luccioli F, Hijazi R, Mannarino E, Shoenfeld Y. Functional impairment of the arterial wall in primary Sjögren's syndrome: Combined action of immunologic and inflammatory factors. *Arthritis Care Res (Hoboken)*. 2010; 62(5):712–718. [PubMed: 20191479]
37. Scardina GA, Ruggieri A, Messina P. Evaluation of labial microvessels in Sjogren syndrome: A videocapillaroscopic study. *Ann Anat.* 2009; 191(3):273–279. [PubMed: 19269146]
38. De Rossi SS, Slaughter YA. Oral changes in older patients: A clinician's guide. *Quintessence Int.* 2007; 38(9):773–780. [PubMed: 17873984]

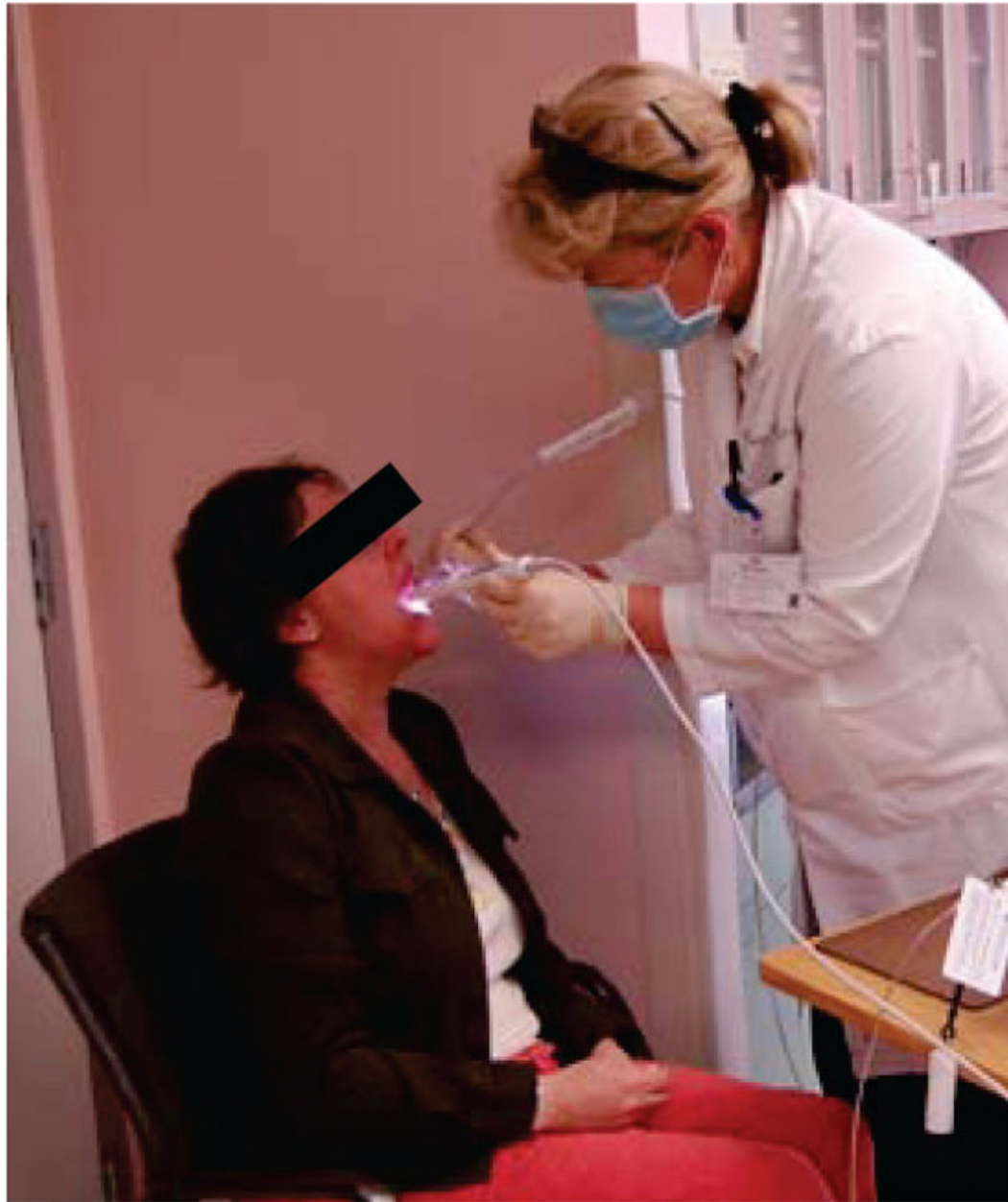

Fig. 1. OCT imaging using flexible fiberoptic probe. [Color figure can be seen in the online version of this article, available at <http://wileyonlinelibrary.com/journal/lsm>]

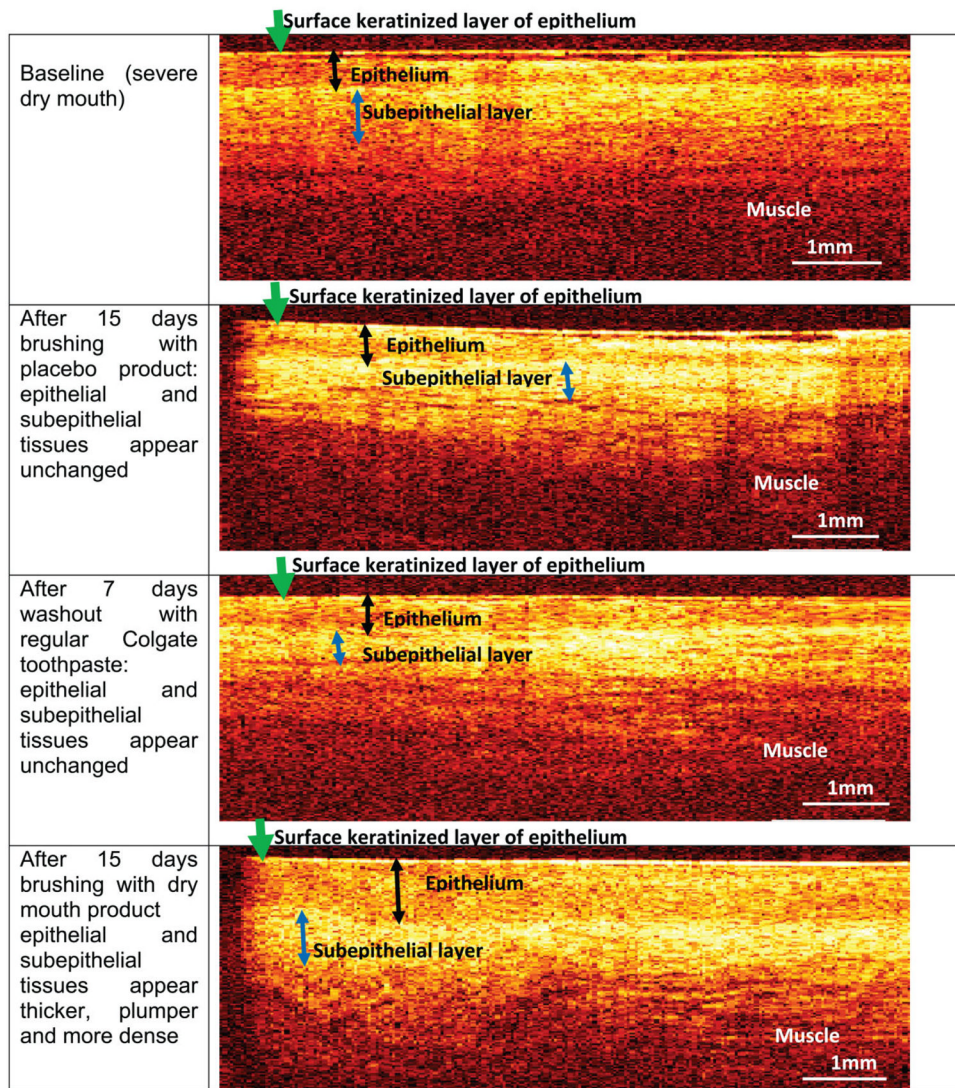


Fig. 2. Representative OCT images of right buccal mucosa in Subject 3 throughout the study showing improved epithelial surface integrity, and greater epithelial and subepithelial thickness, density and plumpness after use of the active dry mouth product. The placebo product and regular Colgate toothpaste had no measurable effect. [Color figure can be seen in the online version of this article, available at <http://wileyonlinelibrary.com/journal/lsm>]

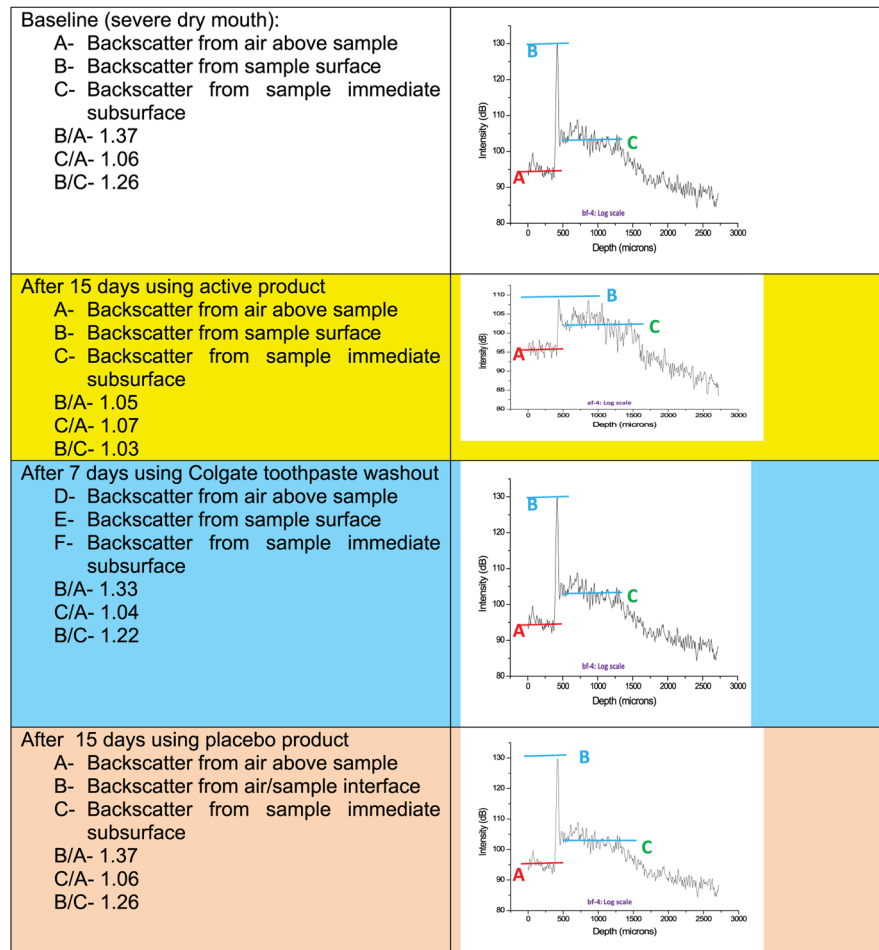


Fig. 3. Representative log plots of backscattering intensity (y-axis) versus tissue depth (x-axis) in Subject 7. Plots after using placebo did not differ in essence form baseline. However, after using active dry mouth product the plot differed markedly from baseline. Treatment-related changes in backscatter were confined to the most superficial 750–1,000 μm of the oral mucosa. [Color figure can be seen in the online version of this article, available at <http://wileyonlinelibrary.com/journal/lsm>]

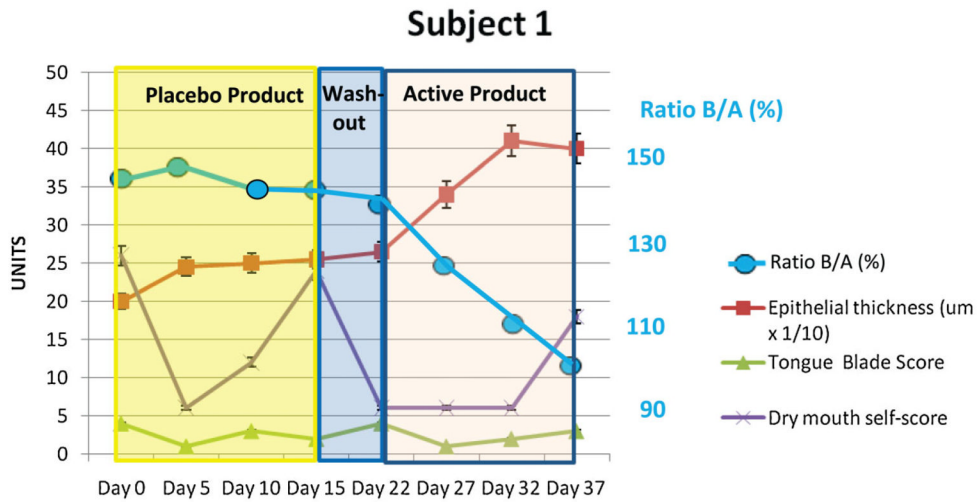


Fig. 4. Representative collated data from Subject 1. No discernible responses to the tooth-pastes are apparent using self-scoring and tongue blade test. However, a measurable increase in epithelial thickness and a considerable reduction in the B/A ratio were determined in response to the active dry mouth toothpaste. [Color figure can be seen in the online version of this article, available at <http://wileyonlinelibrary.com/journal/lsm>]

TABLE 1

Mean Epithelial Thickness in All Subjects and Sites Increased Significantly ($P < 0.05$) After 15 Days' Use of the Active Product, but did not Change Significantly After Placebo or Washout

	Baseline (moderate-severe dry mouth) $n = 330$	After 15 days placebo product ($n = 330$)	After 7 days washout ($n = 330$)	After 15 days active product ($n = 330$)
Mean epithelial thickness of all subjects and imaging sites combined [SD]	210 μm [50]	245 μm [60]	255 μm [50]	395 μm [80]