

# **UCLA**

## **Proceedings of UCLA Health**

### **Title**

Pulsatile Tinnitus – Follow the Beat

### **Permalink**

<https://escholarship.org/uc/item/256737h0>

### **Journal**

Proceedings of UCLA Health, 26(1)

### **Authors**

Gunn, Nazanin Izadpanah

Tateshima, Satoshi

### **Publication Date**

2022-12-02

## CLINICAL VIGNETTE

# Pulsatile Tinnitus – Follow the Beat

Nazanin Izadpanah Gunn, MD and Satoshi Tateshima, MD

A 65-year-old female with hypertension and hyperlipidemia presented for follow up after initiation of atorvastatin. She tolerated her medication well and LDL improved from 124 to 110. BMI increased 5% over three months due to poor diet and lack of exercise while grieving the loss of her husband. Her blood pressure was stable on losartan 25mg and she had no concerns about uncontrolled hypertension. She reported gradually decreasing right-vision and had seen an ophthalmologist one day prior with no concerning findings. She also complained of hearing a constant pulse in right ear for the past month. The sound was described as “whooshing”. She denied associated hearing loss, ear pain, ear discharge, focal weakness, seizure, paresthesia, or recent infection. The symptom was more notable at night laying in bed, and was aggravated with positional changes. Surgical, medical, and social history were otherwise unremarkable, including no tobacco use.

On physical exam, vital signs were within normal limits. Exam was significant for obesity and cerumen impaction in the right ear canal. Her extraocular movements were intact, with normal conjunctivae and sclerae, pupils equal round and reactive to light. Her left EAC and left tympanic membrane were normal and there was no cervical lymphadenopathy. Hearing was grossly intact bilaterally. Ear lavage was performed to improve visualization of right tympanic membrane. One week after successful ear lavage, her constant pulsatile tinnitus was unchanged. She noted the sound was louder if she slept on the unaffected side, and shifting position transiently increased the pulse rate. Due to concern for unilateral pulsatile tinnitus, magnetic resonance imaging angiography (MRA) of neck and brain and magnetic resonance imaging (MRI) brain were ordered. Due to scheduling delays related to COVID pandemic, her MRI imaging was obtained two months later.

Imaging revealed a right-sided AV dural fistula with predominant contribution through the right external carotid artery branches. There is no acute infarction, intracranial hemorrhage or intracranial mass. No evidence of significant segmental stenosis or aneurysm involving the proximal intracranial arteries. No evidence of segmental stenosis or dissection. (See Figure 1.)

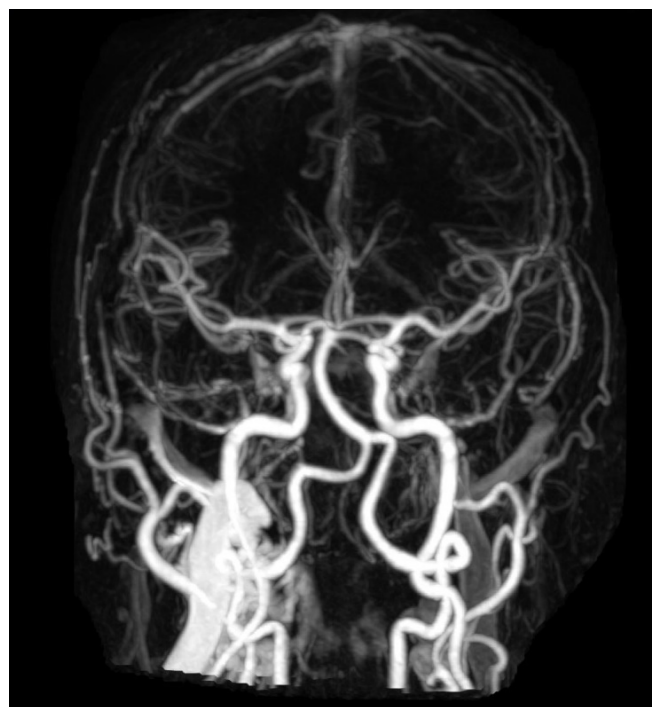

Figure 1. Brain MRI and MRA report and image.

She was referred to an interventional neuroradiologist. Since her initial visit three months prior, her right visual acuity initially worsened then stabilized. She also noted onset of mild to moderate right sided headaches which were gradually increasing in frequency and severity. Her pain was controlled with ibuprofen as needed. On exam, the interventional neuro-radiologist noted right cranial VI nerve partial palsy and bruit behind right ear. Her history and exam now suggested signs of right cavernous sinus venous hypertension. The MRI/MRA findings suggested a hypoglossal canal DAVF or an inferior clival DAVF. Embolization was recommended for treatment and cure of DAVF. A month later, patient underwent cerebral angiogram confirming diagnosis of DAVF with a Cognard grade IIa right-sided transverse sigmoid junction DAVF with involvement of the right middle cerebral artery as a feeder (See Figure 2). There was retrograde opacification of the superior ophthalmic vein indicating venous hypertension in the cavernous sinus and ophthalmic vein. She was treated with transvenous embolization of the transverse sigmoid DAVF using MR compatible coils and Onyx-34 liquid embolic material without complication.

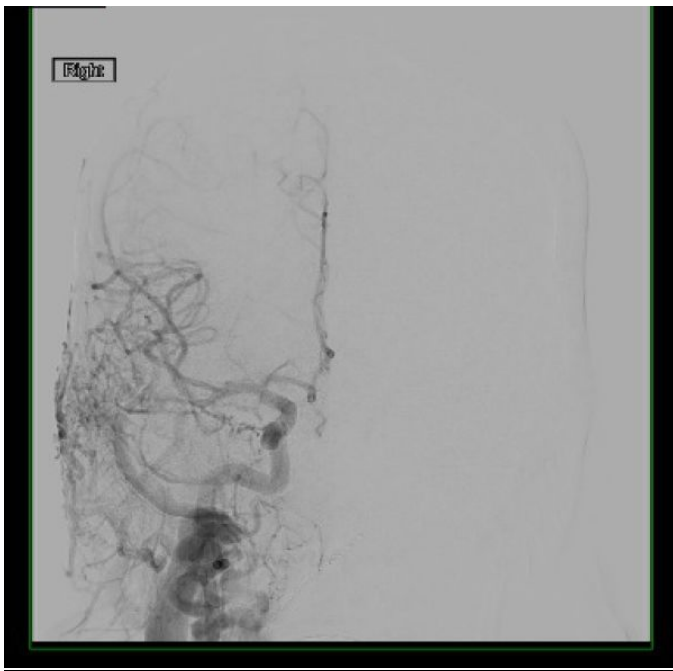


Figure 2. Cerebral angiogram.

## Discussion

### Pulsatile tinnitus

Tinnitus is derived from Latin word *tinnire*, meaning “to ring.”<sup>1</sup> It is the perception of sound in one or both ears, in absence of an external source.<sup>1</sup> Tinnitus may be pulsatile or non-pulsatile. Pulsatile sounds are typically unilateral and synchronous to the heartbeat.<sup>2</sup> Pulsatile tinnitus are likely generated from vascular structures.<sup>2</sup> Asynchronous pulsatile tinnitus are suggestive of musculoskeletal etiology.<sup>2</sup> Differential diagnoses for pulsatile tinnitus include vasculare, neurologic, and musculoskeletal etiologies include: arterial bruits, arteriovenous fistulas, vascular tumors such as paraganglioma, carotid stenosis, venous sinus diverticulum, and venous hums; neurological and musculoskeletal pathologies include multiple sclerosis; patulous eustachian tube dysfunction, and or stapedia myoclonus.<sup>2,3</sup>

Evaluation of the patient risk factors, history and physical exam are essential part of the initial evaluation. Pertinent history may include prior HEENT pathology including ear disease, head injuries, hearing loss, vision changes, headaches, and temporomandibular joint syndrome. Past medical history of anxiety and depression is worth noting. A review of ototoxic medications is also important, such as antibiotics, aspirin, nonsteroidal anti-inflammatory drugs, atorvastatin, and proton pump inhibitors. The patient’s description of the tinnitus should be detailed including onset, location, pattern, and alleviating/aggravating factors.<sup>3</sup> Vascular etiologies, such as DAVF, would typically be synchronous pulsatile, unilateral, persistent low pitch “whooshing” sound, aggravated by positional changes<sup>2</sup> in the neck due to internal jugular vein, compression was reported by our patient. A nonvascular etiology of pulsatile tinnitus, such as patulous eustachian tube dysfunction, may be described as

chronically or intermittently bilateral; or even a unilateral asynchronous pulsatile hissing/blowing sound that may decrease with Valsalva maneuvers.<sup>3</sup> Physical examination should include full head and neck exam, cranial nerve exam and careful auscultation of bruits in carotid mastoid and orbital areas.<sup>2</sup>

When exam and history are consistent with frequent pulsatile tinnitus, particularly unilateral, the patient should be referred to an otolaryngologist or neuro subspecialist as it could be life-threatening condition. In our patient, the MRA was ordered to initiate the process of evaluation. MRA or computed tomographic angiography (CTA) are noninvasive and can diagnose intracranial vascular lesions, however low-grade lesions may be missed. In a retrospective review of patients with DAVF diagnosis between 1990 and 2006, MRA was more sensitive compared to CTA for the diagnosis of DAVF (50% vs 15%).<sup>4</sup> Nevertheless, a “normal” MRA alone does not rule out DAVF,<sup>4</sup> as the gold standard for diagnosis of DAVF is cerebral angiography.

### Dural Arteriovenous Fistulas

DAVFs are abnormal connections between arteries and venous sinuses in the dural matter. DAVFs are usually supratentorial with transverse-sigmoid region being the most common.<sup>5</sup> Complications of DAVFs and presenting symptoms are dependent on venous drainage patterns.<sup>4-8</sup> Symptoms may include headache, vomiting, seizures, pulsatile tinnitus, weakness, paresthesia, vision problems, and proptosis.<sup>5</sup> Exam findings may include bruit, papilledema, glaucoma, intracerebral hemorrhage, intracranial hypertension, and cranial neuropathies.<sup>5</sup>

Most DAVFs have no known cause, however are thought to be acquired from thrombosis, trauma, infection, or prior surgery. Estimated incidence is 0.15-0.20 per 100,000 persons per year.<sup>5</sup> DAVFs are typically encountered in patients between the ages of 40-60 and more often found in women.<sup>5</sup> DAVF accounts for 10-15% of all cerebral vascular malformations.<sup>5,6</sup>

The treatment plan is developed after cerebral angiogram, which allows for a definite diagnosis of the fistula, the extent of external carotid contribution and identification of high-risk features including cortical venous drainage, vascular stenosis, and aneurysms. Two different classification systems of DAVF severity may be used: Borden and Cognard.

The Borden classification involves three categories based on direction of flow at lesion and presence of cortical venous reflux.<sup>5,7</sup>

- Type I: antegrade flow into dural venous sinus, no cortical venous reflux/drainage
- Type II: antegrade flow into dural venous sinus with retrograde cortical venous reflux
- Type III: direct retrograde flow from fistula into cortical veins

Type I Borden classification are usually benign whereas Type III cause venous hypertension and have aggressive neurological deficits or hemorrhage majority of time.<sup>5,7</sup>

The Cognard classification includes seven categories based on the direction of flow at lesion, the presence of cortical venous drainage and ectasia.<sup>5,8</sup> Our patient was Cognard type IIa, which means DAVF was confined to the sinus with retrograde flow into the sinus, and no cortical drainage. This category is associated with 20% risk of intracranial hypertension.<sup>5,8</sup>

Management is based on location of lesion, drainage pattern of DAVF, symptoms and concerns for comorbid conditions. Asymptomatic patients with low grade benign lesions may be monitored closely whereas aggressive types or symptomatic patients are treated with either endovascular embolization, open surgery, or stereotactic radiosurgery. Typically, endovascular embolization is the first line treatment if the patient is an appropriate candidate. Endovascular surgery may be performed with an embolic material or coil to effectively plug the fistula and disconnect the shunt. Some procedures include a combination of coil or balloon assisted embolization with an embolic liquid.<sup>9</sup> Onyx which was used in this case, is a non-adhesive embolic liquid which consists of ethylene-vinyl alcohol copolymer. In embolization procedures, Onyx is dissolved in dimethyl-sulfoxide (DMSO) and typically mixed with micronized tantalum powder for radiopaque visualization.<sup>10</sup> One potential risk of the Onyx embolic system is the direct neurotoxicity of DMSO or inadvertent retrograde arterial embolization.

Surgery is indicated when endovascular embolization is not an option or have previously failed treatment. Stereotactic radiosurgery is effective for low grade lesions, typically reserved for patients that are poor candidates for other treatments due to their anatomy or other significant comorbidities. The area is irradiated with 20-30 gray, which eventually leads to vessel thrombosis and “plugging” the fistula.<sup>5</sup> This process may take many months to years.<sup>5</sup>

### Prognosis

Prognosis depends on symptoms and degree of dysfunction. In most patients, associated symptoms of DAVFs, particularly pulsatile tinnitus, resolve with treatment. Higher grade DAVFs may have non-reversible sequelae of stroke with treatment preventing new events. Mortality and morbidity from DAVF vary widely due to the small number of patients affected.<sup>6</sup> DAVF is a dynamic lesion. A low grade benign DAVF could transform to a high grade DAVF with high-risk features including cortical venous reflux. Importantly, the volume or intensity of the tinnitus does not correlate with the angiographic high-risk features. Careful surveillance imaging with follow up by a specialist is necessary when conservative management is chosen.

### REFERENCES

1. Tinnitus. *Merriam-Webster.com Dictionary*, Merriam Webster. [Internet]. Available at: <https://www.merriam-webster.com/dictionary/tinnitus>.
2. **Dinces EA**. Etiology and diagnosis of tinnitus. In: *UpToDate*, Post, TW (Ed), UpToDate, Waltham, MA, 2022.
3. **Crummer RW, Hassan GA**. Diagnostic approach to tinnitus. *Am Fam Physician*. 2004 Jan 1;69(1):120-6. PMID: 14727828.
4. **Cohen SD, Goins JL, Butler SG, Morris PP, Browne JD**. Dural arteriovenous fistula: diagnosis, treatment, and outcomes. *Laryngoscope*. 2009 Feb;119(2):293-7. doi: 10.1002/lary.20084. PMID: 19172609.
5. **Zyck S, De Jesus O, Gould GC**. Dural Arteriovenous Fistula. 2022 May 9. In: *StatPearls* [Internet]. Treasure Island (FL): StatPearls Publishing; 2022 Jan-. PMID: 30335307.
6. **Miller TR, Gandhi D**. Intracranial Dural Arteriovenous Fistulae: Clinical Presentation and Management Strategies. *Stroke*. 2015 Jul;46(7):2017-25. doi: 10.1161/STROKEAHA.115.008228. Epub 2015 May 21. PMID: 25999384.
7. **Borden JA, Wu JK, Shucart WA**. A proposed classification for spinal and cranial dural arteriovenous fistulous malformations and implications for treatment. *J Neurosurg*. 1995 Feb;82(2):166-79. doi: 10.3171/jns.1995.82.2.0166. Erratum in: *J Neurosurg*. 1995 Apr;82(4):705-6. PMID: 7815143.
8. **Cognard C, Gobin YP, Pierot L, Bailly AL, Houdart E, Casasco A, Chiras J, Merland JJ**. Cerebral dural arteriovenous fistulas: clinical and angiographic correlation with a revised classification of venous drainage. *Radiology*. 1995 Mar;194(3):671-80. doi: 10.1148/radiology.194.3.7862961. PMID: 7862961.
9. **Piechowiak E, Zibold F, Dobrocky T, Mosimann PJ, Bervini D, Raabe A, Gralla J, Mordasini P**. Endovascular Treatment of Dural Arteriovenous Fistulas of the Transverse and Sigmoid Sinuses Using Transarterial Balloon-Assisted Embolization Combined with Transvenous Balloon Protection of the Venous Sinus. *AJNR Am J Neuroradiol*. 2017 Oct;38(10):1984-1989. doi: 10.3174/ajnr.A5333. Epub 2017 Aug 17. PMID: 28818827; PMCID: PMC7963627.
10. **Siekman R**. Basics and Principles in the Application of Onyx LD Liquid Embolic System in the Endovascular Treatment of Cerebral Arteriovenous Malformations. *Interv Neuroradiol*. 2005 Oct 5;11(Suppl 1):131-40. doi: 10.1177/15910199050110S117. Epub 2005 Oct 27. PMID: 20584468; PMCID: PMC3404755.