

**UCLA**

**Proceedings of UCLA Health**

**Title**

A Case Report of Pseudoxanthoma Elasticum-like Papillary Dermal Elastolysis

**Permalink**

<https://escholarship.org/uc/item/2445587x>

**Journal**

Proceedings of UCLA Health, 22(1)

**Authors**

Chao, Kevin

Sorenson, Eric

Young, Lorraine

**Publication Date**

2019-01-16

## CLINICAL VIGNETTE

# A Case Report of Pseudoxanthoma Elasticum-like Papillary Dermal Elastolysis

Kevin Chao, BS<sup>1</sup>, Eric Sorenson, MD<sup>2</sup> and Lorraine Young, MD<sup>2</sup>

<sup>1</sup>David Geffen School of Medicine at UCLA, Los Angeles California

<sup>2</sup>Department of Medicine, Division of Dermatology, David Geffen School of Medicine at UCLA, Los Angeles, California

### Abstract

Pseudoxanthoma elasticum-like papillary dermal elastolysis (PXE-PDE) is a rare acquired fibroelastolytic disorder characterized by soft, white-yellow papules located primarily on the neck, supraclavicular region, and axillae. Affected patients are almost exclusively elderly women. The pathogenesis of PXE-PDE has been speculated to involve various factors including ultraviolet radiation, aging, and abnormal elastogenesis. Here we present a rare case of PXE-PDE in a 73-year-old woman and review the differential diagnosis, pathophysiology, and current treatment options of this disease.

**Keywords:** Elastolysis; elastic tissue disorders; pseudoxanthoma elasticum-like papillary dermal elastolysis; PXE-PDE

### Introduction

Pseudoxanthoma elasticum-like papillary dermal elastolysis (PXE-PDE) is a rare acquired fibroelastolytic disorder characterized by soft, white-yellow papules coalescing into “cobblestone” plaques located primarily on the lateral and posterior neck, supraclavicular region, and axillae. On histology, there is a reduction of elastic fibers in the papillary dermis.<sup>1,2</sup> Pseudoxanthoma elasticum-like papillary dermal elastolysis occurs almost exclusively in elderly, postmenopausal women although few cases have been reported in younger patients. Since it was first described in 1992 by Rongioletti and Rebora, only approximately 60 cases have been reported to date. Here we present a rare case of PXE-PDE in a 73-year-old woman who presented with typical clinical and pathologic findings.

### Case Synopsis

A 73-year-old menopausal Caucasian woman presented with a four-year history of multiple progressive, asymptomatic papules around her neck. In the past year, the papules had spread to the superior chest, shoulders, and antecubital fossae. No other areas were involved. She had no known history of excessive sun exposure. She reports that mother had similar lesions on her back.

Her medications included rosuvastatin 20 milligrams daily, vitamin D 2000 units daily, and omega-3 fish oil 1200 milligrams daily. She had a past medical history of hypercholesterolemia, bilateral cataracts, and osteoporosis. She was otherwise healthy without any cardiovascular, bleeding diathesis, or gastrointestinal problems. An echocardiogram performed two years ago and ophthalmology exam performed several months ago were normal. She had no history of systemic steroid exposure or high-dose steroid injections.

Physical exam revealed yellowish-to-skin colored papules coalescing to form pebbly plaques on the bilateral neck (Figure 1A) extending to the anterior neck, upper chest, bilateral trapezii, and bilateral antecubital fossae (Figure 1B). A skin biopsy revealed a decrease in elastic fibers in the papillary dermis supported by a Verhoeff-van Gieson stain (Figure 2).

Based on the clinical exam and histologic findings, a diagnosis of PXE-PDE was made.

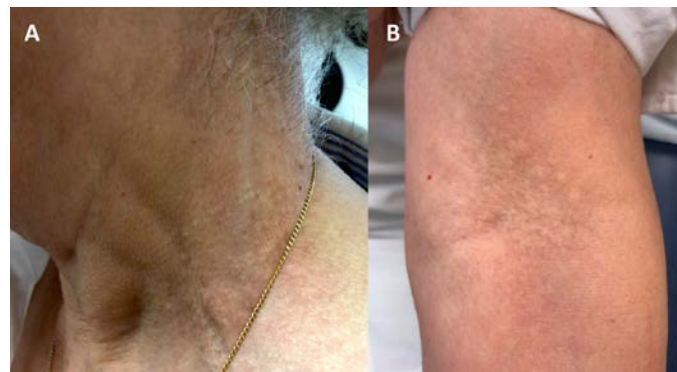


Figure 1: Clinical photographs of (A) yellowish-to-skin colored papules coalescing to form pebbly plaques on the lateral neck. (B) Similar appearing lesions were present on the bilateral antecubital fossa.

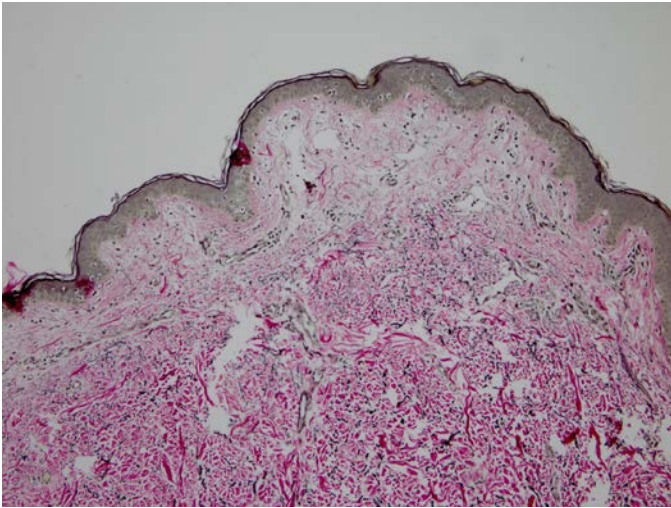


Figure 2: Verhoeff-van Gieson stain of punch biopsy specimen from neck revealed decreased elastic fibers in the papillary dermis consistent with pseudoxanthoma elasticum-like papillary dermal elastolysis (PXE-PDE).

### Case Discussion

Acquired disorders of elastic tissue can be divided into those involving an increase (elastosis) or decrease (elastolysis) of elastic tissue in the dermis. The diseases of elastolysis include PXE-PDE, nevus anelasticus, papular elastorrhesis, perifollicular elastolysis, anetoderma, acquired cutis laxa, post-inflammatory elastolysis and cutis laxa, white fibrous papulosis of neck (WFPN), mid- and upper dermal elastolysis, granulomatous slack skin, and acrokeratoelastoidosis.<sup>3</sup> Various fibroelastolytic diseases of the skin share some common clinical features, so histopathologic analysis may be necessary for definitive diagnosis. Special stains for elastic tissue such as the Verhoeff-van Gieson stain are helpful given that the routine hematoxylin and eosin stain lacks the specificity required for diagnosis.

In particular, PXE-PDE and WFPN can both present as asymptomatic white-to-yellow papules on the neck. Clinically, WFPN is distinguished by the lack of confluent lesions, paler appearance of lesions, and occurrence predominantly in elderly men.<sup>3</sup> The histologic hallmark of PXE-PDE is marked reduction or absence of oxytalan and elaunin fibers in the papillary dermis. There is no increase in fibers of the reticular dermis and dermal fibrosis is not seen, distinguishing PXE-PDE from WFPN.<sup>2,3</sup> However, it has been proposed that PXE-PDE and WFPN exist on the same spectrum of disease, encompassed by the term fibroelastolytic papulosis of the neck (FEPN), based on several cases with similar clinical and histologic features.<sup>4-6</sup>

The pathophysiology of PXE-PDE is speculated to be due to a combination of factors including ultraviolet radiation, aging, and abnormal elastogenesis.<sup>2</sup> Ultraviolet radiation has been implicated given the frequent involvement of the posterior neck, upper back, and supraclavicular areas.<sup>2,3</sup> A suggested mechanism is ultraviolet-induced activation of matrix metalloproteinases in keratinocytes and fibroblasts that degrade

collagen.<sup>2,7</sup> However, ultraviolet light is unlikely to be an independent factor as many patients do not report a history of excessive sun exposure and lesions can present in sun-protected skin such as the axilla.<sup>8-12</sup> Additionally, only one case of PXE-PDE has been reported with solar elastosis and actinic damage.<sup>13</sup>

Intrinsic aging is thought to be contributory given that affected patients are typically elderly with an average age of 61.8 years.<sup>2</sup> Aging results in a decrease of oxytalan fibers in the papillary dermis, similar to that seen in PXE-PDE.<sup>14</sup> However, several cases of PXE-PDE have been reported in younger females, the two youngest at 28 years of age, suggesting that aging may play a smaller role than previously thought.<sup>8,15,16</sup> This is supported by an immunohistochemical study demonstrating loss of both elastin and fibrillin-1 in PXE-PDE in contrast to loss of fibrillin-1 alone in normal aged skin.<sup>17</sup>

To date, all 52 reported cases of PXE-PDE have been in women. The reason for this sexual bias is unknown, but may indicate the presence of some unidentified genetic, hereditary, or hormonal factor. Our patient reported her mother had similar lesions on her back. While this assertion cannot be confirmed, a familial case of PXE-PDE in two sisters has been reported, providing further evidence for genetic factor.<sup>18</sup> Alternatively, some have suggested that the predisposition for one sex is due to women more frequently seeking medical care for cosmetic concerns than men, rather than related to the pathophysiology of the disease.<sup>17,19</sup> Given that the disease is asymptomatic and has subtle manifestations, it is likely that the true incidence of PXE-PDE is underreported.

Steroid therapy is currently the only drug exposure implicated in PXE-PDE. A case series of four patients all had been exposed to long-term systemic methylprednisolone or intralesional triamcinolone for rheumatologic conditions during which they developed the lesions of PXE-PDE.<sup>20</sup> The proposed mechanism involves decreased expression of the elastin gene and elastin messenger ribonucleic acid as demonstrated in cultured human skin fibroblasts.<sup>21</sup>

At present, there are no effective treatments for PXE-PDE. Tretinoin has been shown to decrease the activity of matrix metalloproteinases and collagenase and improve the appearance of photoaged skin.<sup>7</sup> However, the reported efficacy of topical retinoids in PXE-PDE is minimal.<sup>2</sup> Despite the implication of steroids in the pathogenesis of PXE-PDE, low-dose intralesional steroid injections have been attempted given their reported efficacy in papular elastorrhesis, another elastolytic disorder.<sup>20,22</sup> Unfortunately, no clinical improvement was noted.<sup>19</sup> There are several case reports of successful treatment with non-ablative fractional resurfacing (NAFR) and fractionated carbon dioxide lasers.<sup>16,23,24</sup> However, additional studies are required to ensure the results are replicable. As such, patients with PXE-PDE should be counseled on the absence of definitive treatment.

## Conclusion

Pseudoxanthoma elasticum-like papillary dermal elastolysis is an underreported cutaneous fibroelastolytic disorder that occurs exclusively in women. Multiple pathogenic mechanisms have been proposed, including aging, ultraviolet light, abnormal elastogenesis, and genetic or hereditary factors although further studies are required to elucidate the details. Treatment is cosmetic with no effective therapies to date.

## REFERENCES

1. **Rongioletti F, Rebora A.** Pseudoxanthoma elasticum-like papillary dermal elastolysis. *J Am Acad Dermatol.* 1992 Apr;26(4):648-50. PubMed PMID: 1597557.
2. **Rongioletti F, Izakovic J, Romanelli P, Lanuti E, Miteva M.** Pseudoxanthoma elasticum-like papillary dermal elastolysis: a large case series with clinicopathological correlation. *J Am Acad Dermatol.* 2012 Jul;67(1):128-35. doi: 10.1016/j.jaad.2011.09.008. Epub 2011 Oct 22. PubMed PMID: 22018757.
3. **Lewis KG, Bercovitch L, Dill SW, Robinson-Bostom L.** Acquired disorders of elastic tissue: Part II. decreased elastic tissue. *J Am Acad Dermatol.* 2004 Aug;51(2):165-85; quiz 186-8. Review. PubMed PMID: 15280835.
4. **Balus L, Amantea A, Donati P, Fazio M, Giuliano MC, Bellocchi M.** Fibroelastolytic papulosis of the neck: a report of 20 cases. *Br J Dermatol.* 1997 Sep;137(3):461-6. Review. PubMed PMID: 9349351.
5. **Patterson AT, Beasley KJ, Kobayashi TT.** Fibroelastolytic papulosis: histopathologic confirmation of disease spectrum variants in a single case. *J Cutan Pathol.* 2016 Feb;43(2):142-7. doi: 10.1111/cup.12569. Epub 2015 Sep 3. PubMed PMID: 26260852.
6. **Jagdeo J, Ng C, Ronchetti IP, Wilkel C, Bercovitch L, Robinson-Bostom L.** Fibroelastolytic papulosis. *J Am Acad Dermatol.* 2004 Dec;51(6):958-64. PubMed PMID: 15583589.
7. **Fisher GJ, Wang ZQ, Datta SC, Varani J, Kang S, Voorhees JJ.** Pathophysiology of premature skin aging induced by ultraviolet light. *N Engl J Med.* 1997 Nov 13;337(20):1419-28. PubMed PMID: 9358139.
8. **Byun JY, DO MO, Kim SH, Choi HY, Myung KB, Choi YW.** Pseudoxanthoma elasticum-like papillary dermal elastolysis developed in early middle age. *J Dermatol.* 2007 Oct;34(10):709-11. PubMed PMID: 17908144.
9. **el-Charif MA, Mousawi AM, Rubeiz NG, Kibbi AG.** Pseudoxanthoma elasticum-like papillary dermal elastolysis: a report of two cases. *J Cutan Pathol.* 1994 Jun;21(3):252-5. PubMed PMID: 7962827.
10. **Patrizi A, Neri I, Trevisi P, Varotti C.** Pseudoxanthoma-elasticum-like papillary dermal elastolysis: another case. *Dermatology.* 1994;189(3):289-91. PubMed PMID: 7949487.
11. **López V, Revert A, Santonja N, Jordá E.** Pseudoxanthoma elasticum-like dermal elastolysis: a case report. *Dermatol Online J.* 2011 Apr 15;17(4):13. PubMed PMID: 21549088.
12. **Revelles JM, Machan S, Pielasinski U, Camacho D, Vallés L, Santonja C, Kutzner H, Requena L.** Pseudoxanthoma elasticum-like papillary dermal elastolysis: immunohistochemical study using elastic fiber cross-reactivity with an antibody against amyloid P component. *Am J Dermatopathol.* 2012 Aug;34(6):637-43. doi: 10.1097/DAD.0b013e318257be63. Review. PubMed PMID: 22722462.
13. **Lee HS, Song HJ, Hong WK, Shin JH, Choi GS.** Pseudoxanthoma elasticum-like papillary dermal elastolysis with solar elastosis. *J Eur Acad Dermatol Venereol.* 2008 Mar;22(3):368-9. doi: 10.1111/j.1468-3083.2007.02318.x. PubMed PMID: 18269608.
14. **Tsuji T, Hamada T.** Age-related changes in human dermal elastic fibres. *Br J Dermatol.* 1981 Jul;105(1):57-63. PubMed PMID: 7259979.
15. **Vázquez-Osorio I, Rosón E, Suárez-Peñaranda JM, Vázquez-Veiga H.** Pseudoxanthoma elasticum-like papillary dermal elastolysis. *Actas Dermosifiliogr.* 2015 May;106(4):333-6. doi: 10.1016/j.ad.2014.10.002. Epub 2014 Nov 28. Review. English, Spanish. PubMed PMID: 25435063.
16. **Foering K, Torbeck RL, Frank MP, Saedi N.** Treatment of pseudoxanthoma elasticum-like papillary dermal elastolysis with nonablative fractional resurfacing laser resulting in clinical and histologic improvement in elastin and collagen. *J Cosmet Laser Ther.* 2017 Jul 31:1-3. doi: 10.1080/14764172.2017.1358457. [Epub ahead of print] PubMed PMID: 28759289.
17. **Ohnishi Y, Tajima S, Ishibashi A, Inazumi T, Sasaki T, Sakamoto H.** Pseudoxanthoma elasticum-like papillary dermal elastolysis: report of four Japanese cases and an immunohistochemical study of elastin and fibrillin-1. *Br J Dermatol.* 1998 Jul;139(1):141-4. PubMed PMID: 9764167.
18. **Orlandi A, Bianchi L, Nini G, Spagnoli LG.** Familial occurrence of pseudoxanthoma-elasticum-like papillary dermal elastolysis. *J Eur Acad Dermatol Venereol.* 1998 Mar;10(2):175-8. PubMed PMID: 9553919.
19. **Valbuena V, Assaad D, Yeung J.** Pseudoxanthoma Elasticum-Like Papillary Dermal Elastolysis: A Single Case Report. *J Cutan Med Surg.* 2017 Jul/Aug;21(4):345-347. doi: 10.1177/1203475417699407. Epub 2017 Mar 10. PubMed PMID: 28282240.
20. **Pranteda G, Muscianese M, Marmo G, Fidanza L, Pranteda G, Tamburi F, Bottoni U, Nisticò S.** Role of steroid therapy in pseudoxanthoma elasticum-like papillary dermal elastolysis. *Int J Immunopathol Pharmacol.* 2013 Oct-Dec;26(4):1013-8. PubMed PMID: 24355240.
21. **Kähäri VM.** Dexamethasone suppresses elastin gene expression in human skin fibroblasts in culture. *Biochem Biophys Res Commun.* 1994 Jun 30;201(3):1189-96. PubMed PMID: 8024561.
22. **Lee SH, Park SH, Song KY, Yoon TJ, Kim TH.** Papular elastorrhexis in childhood improved by intralesional injections of triamcinolone. *J Dermatol.* 2001 Oct;28(10):569-71. PubMed PMID: 11732727.

23. **Ho D, Jagdeo J.** Fractionated Carbon Dioxide Laser Treatment of Fibroelastolytic Papulosis With Excellent Cosmetic Result and Resolution of Pruritus. *J Drugs Dermatol.* 2015 Nov;14(11):1354-7. PubMed PMID: 26580887.
24. **Chong SP, Woodley DT, Kim GH, Shim EK.** Treatment of fibroelastolytic papulosis with fractionated carbon dioxide laser. *J Cosmet Laser Ther.* 2015 Apr;17(2):90-2. doi: 10.3109/14764172.2014.983933. Epub 2014 Dec 5. PubMed PMID: 25415242.

*Submitted December 4, 2018*