

UC Davis

UC Davis Previously Published Works

Title

Disruption of latent HIV in vivo during the clearance of actinic keratosis by ingenol mebutate

Permalink

<https://escholarship.org/uc/item/21b7d243>

Journal

JCI Insight, 4(7)

ISSN

2379-3708

Authors

Jiang, Guochun

Maverakis, Emanuel

Cheng, Michelle Y

et al.

Publication Date

2019-04-04

DOI

10.1172/jci.insight.126027

Peer reviewed

Disruption of latent HIV in vivo during the clearance of actinic keratosis by ingenol mebutate

Guochun Jiang,¹ Emanuel Maverakis,² Michelle Y. Cheng,² Maher M. Elsheikh,¹ Claire Deleage,³ Gema Méndez-Lagares,¹ Michiko Shimoda,² Steven A. Yukl,⁴ Dennis J. Hartigan-O'Connor,¹ George R. Thompson III,¹ Jacob D. Estes,³ Joseph K. Wong,⁴ and Satya Dandekar¹

¹Department of Medical Microbiology and Immunology and ²Department of Dermatology, UCD, Davis, California, USA.

³AIDS and Cancer Virus Program, Leidos Biomedical Research Inc., Frederick National Laboratory for Cancer Research, Frederick, Maryland, USA. ⁴San Francisco Veterans Affairs (VA) Medical Center and UCSF, San Francisco, California, USA.

Actinic keratosis (AK) is a precancerous skin lesion that is common in HIV-positive patients. Without effective treatment, AKs can progress to squamous cell carcinoma. Ingenol mebutate, a PKC agonist, is a US Food and Drug Administration–approved (FDA-approved) topical treatment for AKs. It can induce reactivation of latent HIV transcription in CD4⁺ T cells both in vitro and ex vivo. Although PKC agonists are known to be potent inducers of HIV expression from latency, their effects in vivo are not known because of the concerns of toxicity. Therefore, we sought to determine the effects of topical ingenol mebutate gel on the HIV transcription profile in HIV-infected individuals with AKs, specifically in the setting of suppressive antiretroviral therapy (ART). We found that AKs cleared following topical application of ingenol mebutate and detected marginal changes in immune activation in the peripheral blood and in skin biopsies. An overall increase in the level of HIV transcription initiation, elongation, and complete transcription was detected only in skin biopsies after the treatment. Our data demonstrate that application of ingenol mebutate to AKs in ART-suppressed HIV-positive patients can effectively cure AKs as well as disrupt HIV latency in the skin tissue microenvironment in vivo without causing massive immune activation.

Introduction

Actinic keratosis (AK), a precancerous skin lesion, commonly develops with age and is usually induced by years of exposure to the sun (1–3). Some of these AK lesions can progress to squamous cell carcinoma (SCC) (4). As antiretroviral therapy–suppressed (ART-suppressed) HIV-positive individuals are getting older, an increased incidence of SCC is being reported among individuals with HIV infection (5). A short course of treatment with ingenol mebutate gel (US Food and Drug Administration–approved [FDA-approved] Picato) leads to effective clearance of AK lesions (1, 2, 6). We and others have previously shown that ingenol mebutate can reactivate latent HIV in the primary CD4⁺ T cells of HIV-infected patients under suppressive ART (7–11). Several families of compounds with PKC agonist activity can induce latent HIV expression by activating the PKC/NF- κ B signaling pathway (12), but many of them have also been associated with systemic toxicities in animal studies (12). Ingenol mebutate is among the highly potent PKC agonists showing enhanced activity for reactivating latent HIV in vitro or ex vivo as compared with other latency reversal agents (LRAs) (8). Importantly, in immune cell studies in vitro and ex vivo, ingenol displays minimal cellular toxicity to immune cells while reactivating latent HIV and does not impair HIV-specific CD8⁺ T cell responses (8, 13). Although ingenol mebutate induces only minimal immune activation, it achieves a high level of reactivation of latent HIV across all memory CD4⁺ T cell subsets from peripheral blood of HIV-infected patients under suppressive ART, singly or in combination with other LRAs (8, 10, 14). However, our knowledge is limited regarding the effects of ingenol mebutate in vivo. In this study, we sought to determine the effects of ingenol mebutate on HIV-infected cells in an accessible skin tissue compartment harboring multiple cell types. We have previously observed reversal of the different blocks to HIV transcription corresponding to different degrees of reactivated latent HIV infection of CD4⁺ T cells during LRA treatment in vitro and ex vivo (15, 16).

Conflict of interest: Ingenol mebutate (PEP005) has been patented for HIV eradication study (SD and G).

Copyright: © 2019 American Society for Clinical Investigation

Submitted: November 6, 2018

Accepted: February 14, 2019

Published: April 4, 2019.

Reference information: *JCI Insight*. 2019;4(7):e126027. <https://doi.org/10.1172/jci.insight.126027>.

It is, however, not known whether ingenol mebutate treatment in vivo could comparably overcome the blocks to initiation, elongation, and full transcription of HIV, especially in tissue compartments.

In the present study, we sought to determine whether topical application of Picato (ingenol mebutate) is able to resolve AK skin lesions and to evaluate the treatment's impact on the immune cells in vivo in HIV-infected patients on suppressive ART. The reason for choosing skin as our target organ was multifold: (a) Skin is a natural reservoir of HIV given that HIV DNA is detected in 87% of skin biopsies obtained from patients with HIV infection (17); (b) when applied topically to the skin, ingenol mebutate gel is not well absorbed into the bloodstream and remains locally effective; and (c) ingenol mebutate is already FDA approved as a topical therapy to treat AKs (1, 2). Thus, we were able to characterize the effects of an LRA in the setting of ART in vivo using this organ-specific approach with minimal risk to the patient. Because relatively low levels of the provirus are localized in skin biopsies of patients with HIV infection, we used an ultrasensitive digital droplet PCR assay to measure HIV transcriptional profile in a single PCR assay that includes detection of the initiation, elongation, and completion and polyadenylation of HIV RNA (8, 18). We applied this approach to skin biopsies of HIV-infected patients with AKs before and following ingenol mebutate treatment. In addition, we used a recently developed, sensitive in situ hybridization approach, RNAscope, to directly detect HIV RNA expression in skin biopsies (19). Histopathologic and cellular analyses were performed on the tissue sections to examine the resolution of the AKs. Our findings showed that topical ingenol mebutate gel application effectively clears AKs. Surprisingly, we found that topical ingenol mebutate, at levels that can reactivate latent HIV in vivo, does so without apparent local or systemic massive immune activation. The observation of these dual effects of ingenol mebutate application to HIV-infected patients with AK identifies such an application as a useful in vivo model for studying the disruption of HIV latency.

Results

AKs are precancerous cutaneous lesions that can progress to SCC. They are common in individuals with HIV infection (5). Topical treatments are provided as part of the routine clinical care to resolve these skin lesions (1, 2). For the present study, patients with HIV infection ($n = 5$) were identified as having AKs and were about to receive a single topical application of ingenol mebutate gel as therapy. These patients were also under suppressive ART for longer than 8 years and had undetectable plasma HIV loads (<20 RNA copies/ml). Their peripheral CD4⁺ T cell numbers were above 594 cells/ μ l (Supplemental Table 1; supplemental material available online with this article; <https://doi.org/10.1172/jci.insight.126027DS1>). Following the topical application of ingenol mebutate on skin lesions on the right forearm, skin biopsies were obtained at day 1 (for patient 5) or day 2 (for patients 1–4). For a paired control sample, a skin biopsy was obtained from an untreated region of the contralateral (left) forearm (day 0 for control). An additional longitudinal biopsy sample was collected, coincident with scheduled skin biopsies, at day 10 (for patients 1–4) or at day 22 (for patient 5) from an area close to the initial day 2 biopsy site from the ingenol mebutate gel-treated arm. Tissue biopsies were divided and placed into RNAlater and into buffered formalin. Peripheral blood samples were collected before ingenol mebutate application, and at day 1 or day 2 and at day 10 or day 22 following ingenol mebutate treatment, and CD4⁺ T cells were isolated. Detection of HIV RNA in skin biopsies and histopathologic evaluations were performed using RNAscope and immunohistochemical analysis.

HIV-infected patients receiving ingenol mebutate gel for treatment of AKs did not report incidence of any adverse reactions besides localized erythema and mild associated pain. Skin biopsies obtained at days 2 and 10 after ingenol mebutate treatment demonstrated lymphocytic exocytosis and mildly increased numbers of dermal and perivascular lymphocytes as compared with untreated skin samples. These changes correlated with superficial erythema at the site of the treatment. However, a gradual resolution of the background erythema was observed at day 10 after the treatment. This was followed by eradication of the scaly AK (Figure 1). We determined the level of generalized immune activation by measuring the expression of CCR5, CD25, CD38, CD69, and HLA-DR in CD4⁺ and CD8⁺ T cell subsets from peripheral blood samples by flow cytometry. The expression of these markers varied among individuals. However, there was no significant change in the level of immune activation in the peripheral T cell subsets following ingenol mebutate application (Supplemental Figure 1, A and B). To further validate these findings, expression of proinflammatory cytokines was determined in plasma samples using the Luminex assay. The expression of TNF- α , IL-6, and IFN γ did not significantly

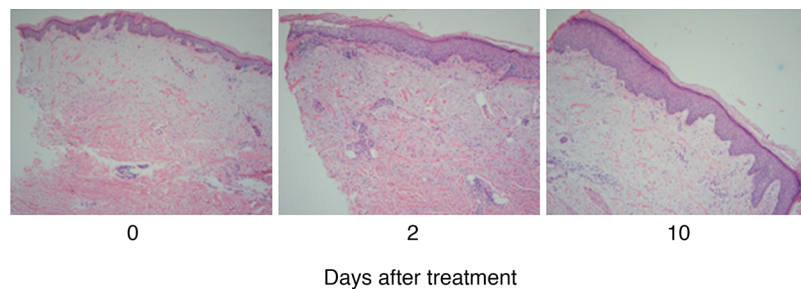


Figure 1. Resolution of the AK lesion following topical ingenol mebutate application. Histopathologic evaluation was performed on the skin biopsies. Lymphocytic exocytosis and slightly increased numbers of dermal and perivascular lymphocytes were observed at 2 and 10 days after ingenol mebutate treatment. The background erythema in the lesions gradually resolved, followed by clearance of the scaly AK thereafter ($n = 5$) (original magnification, $\times 10$).

change following ingenol mebutate application while IL-2 was undetectable in all the plasma samples (Supplemental Figure 2). Collectively, our findings suggest that the topical application of ingenol mebutate to HIV-positive individuals undergoing ART did not induce systemic immune activation in PBMCs, suggesting that it remained local and did not disseminate systemically.

We measured the levels of different HIV transcripts to determine the degree of HIV transcription that was blocked in peripheral CD4⁺ T cells and in skin biopsies during ART. We reasoned that a comparison of HIV transcription profiles following the ingenol mebutate gel application would reveal the degree to which the viral transcription was activated. As expected, in the untreated samples, the level of HIV RNA was significantly lower in the skin biopsies compared with peripheral blood in patients with HIV infection, because the immune cell content in skin is lower than in samples of immune cells from blood (Supplemental Table 2). Compared with the skin biopsies, peripheral blood-derived CD4⁺ T cells had on average 303.6-fold higher total initiated HIV transcripts, 222.6-fold more elongated HIV RNA, and 90.4-fold more full-length HIV RNA. Similarly, HIV DNA levels were also much higher in CD4⁺ T cells in the peripheral blood than in the skin biopsies among untreated samples from these patients (1814.96 ± 1126.38 HIV DNA copies/million cells in CD4⁺ T cells compared with 39.97 ± 33.44 HIV DNA copies/million cells in skin biopsies) (Supplemental Table 3.). Previously we have shown that there may be a block at the level of the full-length HIV transcription during ART (15, 16). Following the topical application of ingenol mebutate, there was no apparent change in the levels of the full-length HIV RNA [poly(A)⁺] or in the initiation and elongation of the HIV transcripts in the CD4⁺ T cells from peripheral blood samples. A decrease in HIV transcript levels was observed in the CD4⁺ T cells from patient 5 at day 22 following the treatment. In contrast, an increase in all 3 types of HIV transcripts (HIV initiation, elongation, and complete transcription) was detected in skin biopsies at day 2 after ingenol mebutate application, except for elongated RNA in patient 5. However, HIV RNA levels decreased at 10 days following the ingenol mebutate treatment, except for patient 1, who had maintained increased levels of HIV initiation transcripts, and for patient 3, who had increased levels of elongated and completed HIV transcripts at day 10 after treatment (Figure 2). To determine the magnitude of HIV reactivation through different stages of HIV transcription following ingenol mebutate treatment, values of elongated HIV transcription or full-length HIV transcription were normalized to the total HIV RNA transcript levels (i.e., initiation of HIV transcription) for each blood and skin biopsy sample. The reactivation of latent HIV expression was detected in samples from all patients with HIV infection, and induction of both elongated HIV transcripts and full-length HIV RNA was detected, except for patient 5, in both the tissue compartments (Figure 3). Interestingly, a somewhat similar pattern was observed in the elongated HIV RNA transcription in peripheral CD4⁺ T cell samples from patients 1 and 3 at day 2 and patients 1, 2, 3, and 4 at day 10 and in the full-length HIV RNA transcription in cell samples from patients 1, 3, and 4 at day 2 and patients 2 and 3 at day 10 (Figure 3). Because proviral HIV DNA levels varied among the skin biopsy samples, we normalized the levels of HIV RNA to the viral DNA levels in each sample to assess the magnitude of HIV reactivation. As shown in Figure 4A, after HIV DNA normalization, initiation of HIV transcription from latent HIV in skin biopsies was upregulated at day 1 or 2 after treatment in all patients except for patients 1 and 4. The elongated HIV RNA was induced in skin biopsies at day 1 or 2 after ingenol mebutate application in all patients except patients 3

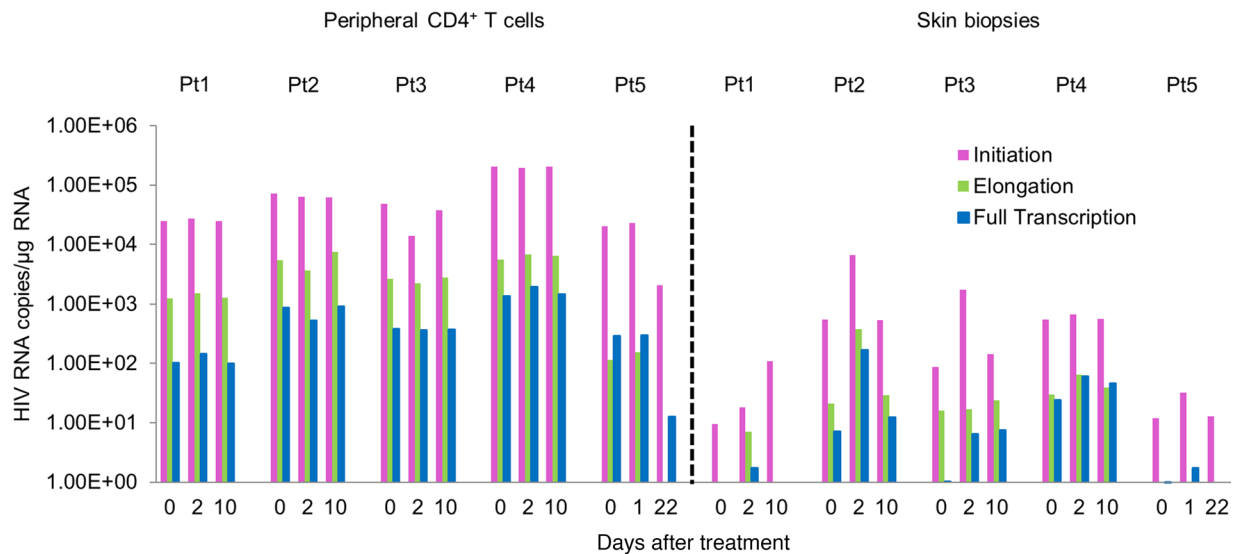


Figure 2. Ingenol mebutate gel reverses blocks to initiation, elongation, and completion of latent HIV transcription in skin biopsies. HIV transcription profile was determined by digital droplet PCR in both primary CD4⁺ T cells and skin biopsy samples. PCR of initiation of HIV, elongation of HIV, and full transcription of HIV was run in the same PCR reaction ($n = 5$). Pt, patient.

and 5 (Figure 4B). Transcription of full-length HIV RNA was induced 1 or 2 days following ingenol mebutate application in skin biopsy samples of all 5 patients, which subsequently decreased at day 10 or day 22 after treatment, except for patient 3, who showed a persistently elevated level of HIV transcription. In the peripheral blood, overall no initiation of RNA was observed after normalization with HIV DNA except in patient 2. Only patients 2 and 3 showed some degree of HIV elongation while transcription of full-length HIV RNA was upregulated in 2 of the 5 patient samples either at 1 or 2 or at 10 days after treatment (Figure 4). Interestingly, the degrees of expression of HIV transcripts (initiation, elongation, and full transcription) all correlated with the sizes of the viral reservoirs in both peripheral CD4⁺ T cells and skin biopsies (Supplemental Figure 3). This is in agreement with a recent report showing that the magnitude of HIV reactivation correlated with HIV reservoirs' size in peripheral blood of patients with HIV infection (14).

To further examine the presence of latent HIV reactivation in vivo following ingenol mebutate application, RNAscope technology was used to directly detect and localize the presence of viral transcripts in skin tissue sections. As shown in Figure 5, cells expressing HIV transcripts were identified in skin biopsies of 3 patients. HIV reactivation was detectable at day 10 (2.66 ± 1.15 HIV RNA⁺ cells/4 sections on day 10 versus 0.33 ± 0.47 HIV RNA⁺ cells/4 sections on day 0, $P = 0.05$ with 2-tailed, nonparametric t test analysis) and at day 2 (0.67 ± 0.58 HIV RNA⁺ cells/4 sections at day 2 versus 0.33 ± 0.47 HIV RNA⁺ cells/4 sections on day 0, $P = 0.50$ with 2-tailed, nonparametric t test analysis) following ingenol mebutate application. To determine the cellular effects of ingenol mebutate, immunohistochemical analysis was performed on the skin biopsies of patients with HIV infection. Although CD4⁺ and CD8⁺ T cells and macrophages (CD68⁺CD163⁺) were detectable in skin biopsies, there was no indication of massive infiltration of cells to the site of ingenol mebutate application in skin biopsies of patients (Supplemental Figure 4).

Discussion

Our study demonstrates that ingenol mebutate, a PKC agonist, is effective in resolving AK lesions on the skin of patients with HIV infection receiving suppressive ART. Topical application of ingenol mebutate was well tolerated, and these study participants reported no adverse reactions. Interestingly, ingenol mebutate induces HIV transcription from the viral reservoirs without triggering detectable upregulation of immune activation or production of proinflammatory cytokines locally or systemically. We previously reported that ingenol compounds IngB and ingenol mebutate were able to reactivate latent HIV in vitro and ex vivo without inducing massive immune activation (7, 8). Although other PKC agonists, including prostratin and bryostatin-1, are also potent in reactivating latent HIV expression, concerns regarding their potential

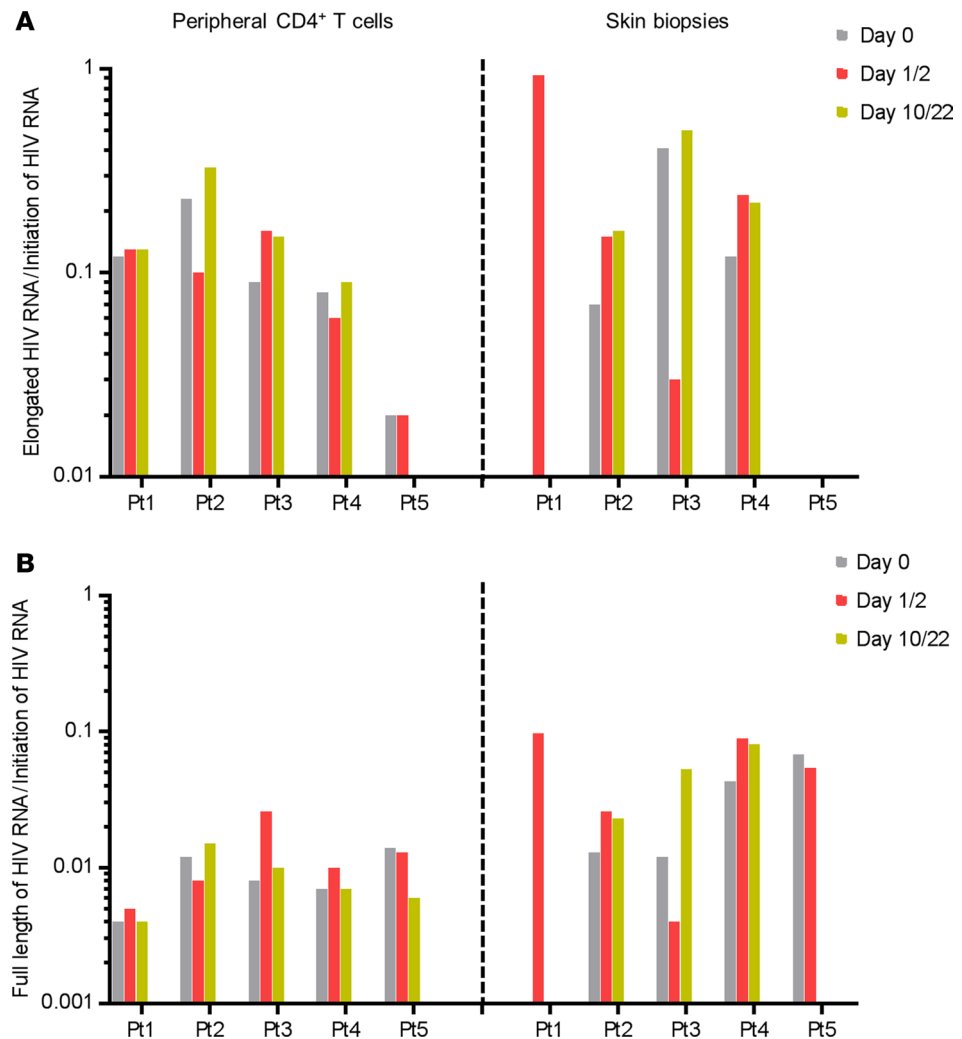


Figure 3. Ingenol mebutate gel reverses blocks to elongation and full transcription of latent HIV among the total transcripts in the skin biopsies from patients. The values of elongated HIV RNA and full-length HIV RNA were normalized with total HIV transcription (transactivation response element [TAR] region of RNA transcription) to determine the reactivation of latent HIV in primary CD4⁺ T cells or skin biopsy samples in each patient ($n = 5$).

cellular toxicity limit their clinical development (12, 20). A recent study reported that prostratin and bryostatin-1 can disrupt the integrity of the blood-brain barrier and trigger inflammatory responses in human cerebral microvascular endothelial cells (21). Due to the concerns of potential cytotoxicity of these PKC agonists, very low levels of bryostatin-1 were administered to patients with HIV infection in a previous clinical trial. Although this dose of bryostatin-1 was safe to administer, it failed to adequately reactivate latent HIV reservoirs in patients in vivo (20). However, data from most recent clinical and preclinical studies are encouraging and support further exploration of PKC agonists as safe and effective LRAs in patients in vivo. First, in the nonhuman primate model of AIDS, administration of IngB demonstrated its ability to reactivate latent SIV without apparent toxicity in vivo (22). Second, in a humanized mouse model of AIDS, a synthetic bryostatin analog not only reactivated latent HIV but also displayed a potential killing effect in vivo (23). Unlike other PKC agonists, ingenol mebutate, or PEP005, can disrupt HIV latency from all the memory CD4⁺ T cell subsets, including central memory, transitional memory, and effector memory CD4⁺ T cells (10). Interestingly, we found that PEP005 was the only LRA that could disrupt all the transcriptional blocks from HIV latency, including initiation, elongation, full transcription, and splicing (15). In addition, ingenol mebutate can reactivate latent HIV in monocytic cells (8). Although our current study shows the ability of ingenol mebutate to reactivate latent HIV in vivo, the magnitude of induction was relatively small in some patients. In addition, our study consisted of a small number of patients.

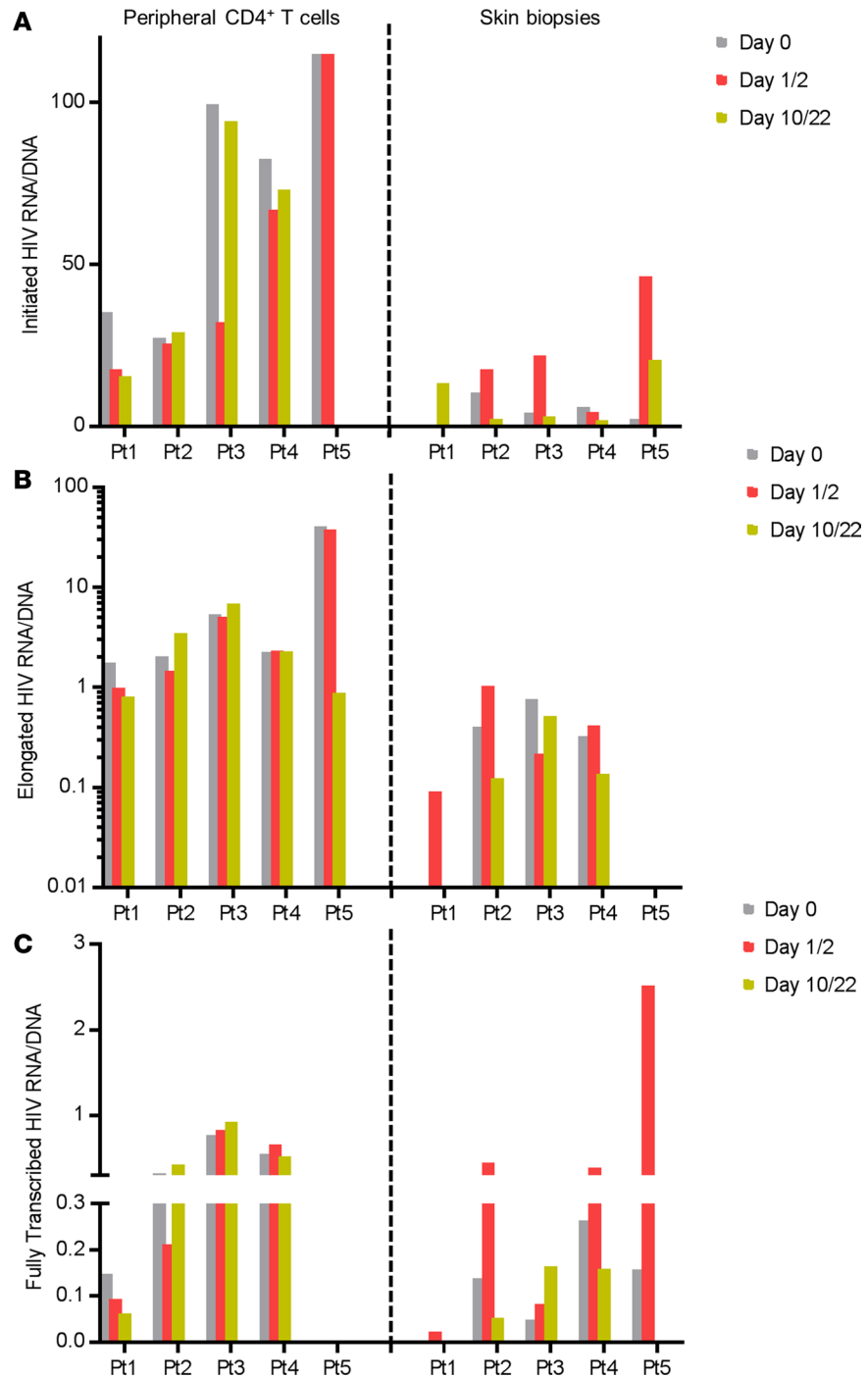


Figure 4. Ingenol mebutate gel induces full-length transcription, initiation, or elongation of latent HIV RNA per each copy of the HIV DNA in primary CD4⁺ T cells and skin biopsies from patients with HIV infection. The value of initiation (A), elongation (B), or full-length transcription (C) of HIV RNA was normalized with its total HIV DNA in the sample of primary CD4⁺ T cells or skin biopsies from patients (*n* = 5).

The copy numbers of HIV RNA and DNA in skin biopsies of patients are smaller than in peripheral blood, possibly because of the increased proportions of immune cells in this compartment. On the other hand, we found that the magnitude of HIV RNA varied across patients, indicating a differential size of HIV reservoirs among patients. Generally, reactivation of latent HIV by ingenol mebutate peaked on days 1 or 2 after the treatment and waned on days 10 or 22, suggesting a transient or short-time effect of its action in vivo. Whether this reflects the effects of its pharmacokinetics in vivo warrants further investigation. Nevertheless,

Methods

Participants. This pilot study was reviewed and approved by the Institutional Review Board at the UCD. All participants provided written informed consent and were recruited from the outpatient UCD dermatology clinic. Specifically, 5 HIV seropositive individuals (54–64 years of age) with AKs distributed over their forearms were enrolled to receive topical ingenol mebutate gel (Picato, LEO Pharma) as standard of care (Supplemental Table 1) at the UCD clinic. Follow-up patient visits were performed for the clinical evaluation of the treated areas. The participants were under suppressive ART for 8 to 20 years (14.6 ± 4.2 years) with plasma HIV viral loads below detection levels (<20 RNA copies/ml) and peripheral blood CD4⁺ T cell numbers of 594 to 1010 cells/ μ l (711.4 ± 117.2 cells/ μ l). They remained on ART while receiving topical ingenol mebutate gel.

Treatment and sample collection. Participants had visible AK lesions on the dorsum of hands and forearm. Cutaneous skin biopsies and peripheral blood samples were obtained from patients with HIV infection before and after ingenol mebutate application. A 5-mm punch tool was used to obtain skin biopsies from the forearms of patients. Resulting wounds were closed with nylon sutures. Skin biopsies were collected from each individual 3 times. The first biopsy was obtained from an area from the right forearm on day 1 ($n = 1$) or day 2 ($n = 4$) after receiving topical 0.05% ingenol mebutate. Control biopsies were obtained from the untreated contralateral left forearm. At day 10 ($n = 4$) or day 22 ($n = 1$), a third biopsy was taken from an area close to the first biopsy on the right forearm, which was treated with topical ingenol mebutate. Each 5-mm biopsy was divided into 2 parts; 1 was immediately placed into RNAlater solution, and the other part was fixed in buffered formalin. Peripheral blood was also collected at day 0, day 1 or 2, and day 10 or 22. PBMCs were isolated and plasma samples collected. Inflammatory cytokine expression in plasma (Luminex bead-based multiplex assay) and markers of immune activation in PBMC (flow cytometry) were measured (Supplemental Methods).

Digital droplet PCR. Total RNA was extracted from PBMC and from skin biopsies by acid guanidinium thiocyanate-phenol-chloroform extraction (Trizol, Molecular Research Center) using Dounce tissue grinder protocol as previously described (15, 16, 25), subsequent isopropanol precipitation, and RNA quantification using a NanoDrop 1000 spectrophotometer. The HIV transcriptional profile was determined to infer the levels of initiation (TAR, short abortive transcripts), elongation (Kumar or Long LTR transcripts), or full transcription/completion of transcripts [poly(A)⁺ transcripts] as previously published (15, 16). The PCR primers/probes for this assay were previously reported to quantify initiation, elongation, or full transcription of HIV (7, 8, 26, 27). Digital droplet PCR was carried out using the QX100 Droplet Digital PCR System (Bio-Rad). Samples were tested in replicate and were amplified in a 7900 Thermal Cycler (Life Technologies) with PCR conditions as follows: 10 minutes at 95°C, 45 cycles of 30 seconds at 95°C and 59°C for 60 seconds, and a final droplet cure step of 10 minutes at 98°C. Absolute quantification of copy numbers was calculated using QuantaSoft software (Bio-Rad).

RNA scope and immunostaining. For the detection of HIV RNA-positive cells in skin biopsies, RNA-scope in situ hybridization was performed as previously reported (28). Immunohistochemical analysis was performed to determine histopathologic changes and the tissue immune cell composition of CD4⁺ and CD8⁺ T cells and CD68⁺CD163⁺ macrophages (Supplemental Methods).

Statistics. Data represent mean \pm SEM, which were calculated using data points from 3–5 patient samples. Statistical significance was determined using the 2-tailed, nonparametric *t* test. When 3 or more than 3 groups were compared, 1-way ANOVA analysis was applied followed by post hoc Tukey's test, where *P* value less than 0.05 was considered significant.

Study approval. This study was carried out under the recommendations of the Public Health Services Policy on Humane Care. Human samples were obtained under informed written consent and a protocol approved by the UCD Institutional Review Board (IRB 219139).

Author contributions

GJ, EM, and SD conceived and designed the experiments. GJ, MYC, MME, GML, CD, and MS performed the experiments. GJ, SAY, GML, MS, DJHO, CD, JDE, JKW, SAY, and SD analyzed the data. MYC, GRT, and EM coordinated patient samples. GJ, EM, and SD contributed to the writing of the manuscript.

Acknowledgments

This work was supported by NIH grants AI123105 and AI43274 and a UC Davis Research Investments in Science and Engineering grant to SD; NIH AI116218 and AI132128 and VA Merit Review to JKW; and NIH DK108349 and NIH AI132128 Foundation for AIDS Research to SAY. This project has been funded in part with federal funds from the National Cancer Institute, NIH, under contract HHSN261200800001E. The content of this publication does not necessarily reflect the views or policies of the Department of Health and Human Services or the Department of Veterans Affairs, nor does mention of trade names, commercial products, or organizations imply endorsement by the US government. We thank the Immune Monitoring Shared Resources in Comprehensive Cancer Center at UCD for cytokine measurements. We thank Peggy L. Kim (San Francisco Veterans Affairs Medical Center, San Francisco, California, USA) for performing HIV RNA assays and for assistance with analysis and Mary Spellman (Menlo Therapeutics, Redwood City, California, USA) for useful advice.

Address correspondence to: Satya Dandekar, 1 Shields Ave., 5511 GBSF, Department of Medical Microbiology and Immunology, UC Davis, Davis, California 95616, USA. Phone: 530.752.3409; Email: sdandekar@ucdavis.edu.

JDE's present address is: Vaccine and Gene Therapy Institute and Division of Pathobiology and Immunology, Oregon National Primate Research Center, Oregon Health & Science University, Beaverton, Oregon, USA.

GJ's present address is: University of North Carolina at Chapel Hill, UNC HIV Cure Center, & Department of Biochemistry and Biophysics, Chapel Hill, North Carolina, USA.

- Lebwohl M, Swanson N, Anderson LL, Melgaard A, Xu Z, Berman B. Ingenol mebutate gel for actinic keratosis. *N Engl J Med.* 2012;366(11):1010–1019.
- Siller G, Gebauer K, Welburn P, Katsamas J, Ogbourne SM. PEP005 (ingenol mebutate) gel, a novel agent for the treatment of actinic keratosis: results of a randomized, double-blind, vehicle-controlled, multicentre, phase IIa study. *Australas J Dermatol.* 2009;50(1):16–22.
- Maverakis E, Miyamura Y, Bowen MP, Correa G, Ono Y, Goodarzi H. Light, including ultraviolet. *J Autoimmun.* 2010;34(3):J247–J257.
- Schmitz L, Oster-Schmidt C, Stockfleth E. Nonmelanoma skin cancer — from actinic keratosis to cutaneous squamous cell carcinoma. *J Dtsch Dermatol Ges.* 2018;16(8):1002–1013.
- Lecuona K, et al. The treatment of carcinoma in situ and squamous cell carcinoma of the conjunctiva with fractionated strontium-90 radiation in a population with a high prevalence of HIV. *Br J Ophthalmol.* 2015;99(9):1158–1161.
- Emmert S, et al. Tumor-preferential induction of immune responses and epidermal cell death in actinic keratoses by ingenol mebutate. *PLoS One.* 2016;11(9):e0160096.
- Jiang G, et al. Reactivation of HIV latency by a newly modified Ingenol derivative via protein kinase C δ -NF- κ B signaling. *AIDS.* 2014;28(11):1555–1566.
- Jiang G, et al. Synergistic reactivation of latent HIV expression by ingenol-3-angelate, PEP005, targeted NF- κ B signaling in combination with JQ1 induced p-TEFb activation. *PLoS Pathog.* 2015;11(7):e1005066.
- Wu G, et al. HDAC inhibition induces HIV-1 protein and enables immune-based clearance following latency reversal. *JCI Insight.* 2017;2:e92901.
- Baxter AE, et al. Single-cell characterization of viral translation-competent reservoirs in HIV-infected individuals. *Cell Host Microbe.* 2016;20(3):368–380.
- Hashemi P, et al. Compounds producing an effective combinatorial regimen for disruption of HIV-1 latency. *EMBO Mol Med.* 2018;10(2):160–174.
- Jiang G, Dandekar S. Targeting NF- κ B signaling with protein kinase C agonists as an emerging strategy for combating HIV latency. *AIDS Res Hum Retroviruses.* 2015;31(1):4–12.
- Kwaa AK, Goldsborough K, Walker-Sperling VE, Pianowski LF, Gama L, Blankson JN. The effect of Ingenol-B on the suppressive capacity of elite suppressor HIV-specific CD8⁺ T cells. *PLoS One.* 2017;12(5):e0174516.
- Darcis G, et al. Reactivation capacity by latency-reversing agents ex vivo correlates with the size of the HIV-1 reservoir. *AIDS.* 2017;31(2):181–189.
- Yukl SA, et al. HIV latency in isolated patient CD4⁺ T cells may be due to blocks in HIV transcriptional elongation, completion, and splicing. *Sci Transl Med.* 2018;10(430):eaap9927.
- Jiang G, et al. HIV latency is reversed by ACSS2-driven histone crotonylation. *J Clin Invest.* 2018;128(3):1190–1198.
- Kanitakis J, Escaich S, Trepo C, Thivolet J. Detection of human immunodeficiency virus-DNA and RNA in the skin of HIV-infected patients using the polymerase chain reaction. *J Invest Dermatol.* 1991;97(1):91–96.
- Kaiser P, et al. Assays for precise quantification of total (including short) and elongated HIV-1 transcripts. *J Virol Methods.* 2017;242:1–8.

19. Deleage C, et al. Defining HIV and SIV reservoirs in lymphoid tissues. *Pathog Immun.* 2016;1(1):68–106.
20. Gutiérrez C, et al. Bryostatin-1 for latent virus reactivation in HIV-infected patients on antiretroviral therapy. *AIDS.* 2016;30(9):1385–1392.
21. Dental C, Proust A, Ouellet M, Barat C, Tremblay MJ. HIV-1 latency-reversing agents prostratin and bryostatin-1 induce blood-brain barrier disruption/inflammation and modulate leukocyte adhesion/transmigration. *J Immunol.* 2017;198(3):1229–1241.
22. Gama L, et al. Reactivation of simian immunodeficiency virus reservoirs in the brain of virally suppressed macaques. *AIDS.* 2017;31(1):5–14.
23. Marsden MD, et al. In vivo activation of latent HIV with a synthetic bryostatin analog effects both latent cell “kick” and “kill” in strategy for virus eradication. *PLoS Pathog.* 2017;13(9):e1006575.
24. Zhou F, et al. Oncolytic reactivation of KSHV as a therapeutic approach for primary effusion lymphoma. *Mol Cancer Ther.* 2017;16(11):2627–2638.
25. Telwatte S, et al. Gut and blood differ in constitutive blocks to HIV transcription, suggesting tissue-specific differences in the mechanisms that govern HIV latency. *PLoS Pathog.* 2018;14(11):e1007357.
26. Kumar AM, Borodowsky I, Fernandez B, Gonzalez L, Kumar M. Human immunodeficiency virus type 1 RNA Levels in different regions of human brain: quantification using real-time reverse transcriptase-polymerase chain reaction. *J Neurovirol.* 2007;13(3):210–224.
27. Yukl SA, Kaiser P, Kim P, Li P, Wong JK. Advantages of using the QIAshredder instead of restriction digestion to prepare DNA for droplet digital PCR. *BioTechniques.* 2014;56(4):194–196.
28. Deleage C, Turbey B, Estes JD. Imaging lymphoid tissues in nonhuman primates to understand SIV pathogenesis and persistence. *Curr Opin Virol.* 2016;19:77–84.