

## **UC Irvine**

### **Western Journal of Emergency Medicine: Integrating Emergency Care with Population Health**

#### **Title**

Shot in the Heart

#### **Permalink**

<https://escholarship.org/uc/item/2197s1v5>

#### **Journal**

Western Journal of Emergency Medicine: Integrating Emergency Care with Population Health, 17(1)

#### **ISSN**

1936-900X

#### **Authors**

Bakhsh, Abdullah  
Morse, Bryan  
Funderburk, Christopher  
[et al.](#)

#### **Publication Date**

2016

#### **DOI**

10.5811/westjem.2015.11.28464

#### **Supplemental Material**

<https://escholarship.org/uc/item/2197s1v5#supplemental>

#### **Copyright Information**

Copyright 2016 by the author(s). This work is made available under the terms of a Creative Commons Attribution License, available at <https://creativecommons.org/licenses/by/4.0/>

Peer reviewed

## Shot in the Heart

Abdullah Bakhsh, MD\*<sup>‡</sup>  
 Bryan Morse, MD<sup>†</sup>  
 Christopher Funderburk, MD<sup>†</sup>  
 Patrick Meloy, MD\*  
 Katie Dean, MD\*  
 Jeffrey Siegelman, MD\*  
 Todd Taylor, MD\*

\*Emory University School of Medicine, Department of Emergency Medicine, Atlanta, Georgia  
<sup>†</sup>Emory University School of Medicine, Department of Surgery, Atlanta, Georgia  
<sup>‡</sup>King Abdulaziz University, Department of Emergency Medicine, Jeddah, Saudi Arabia

Section Editor: Sean O. Henderson, MD

Submission history: Submitted August 17, 2015; Revision received October 4, 2015; Accepted November 1, 2015

Electronically published January 12, 2016

Full text available through open access at [http://escholarship.org/uc/uciem\\_westjem](http://escholarship.org/uc/uciem_westjem)

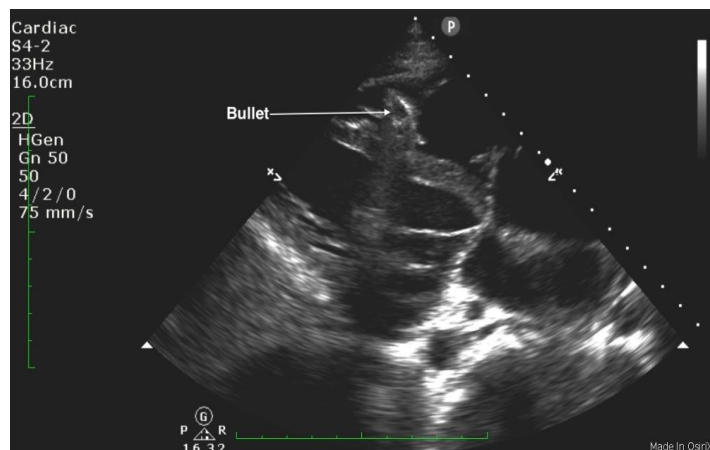
DOI: 10.5811/westjem.2015.11.28464

[West J Emerg Med. 2016;17(1):84–85.]

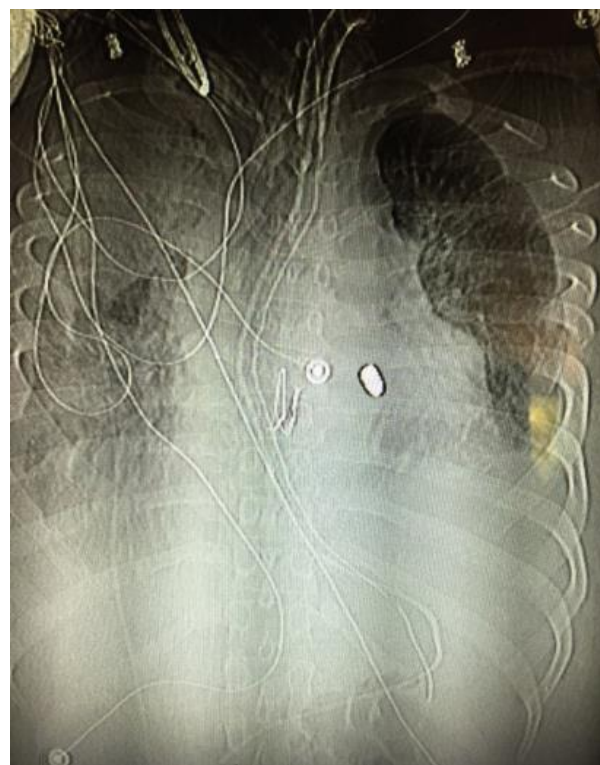
A 25-year-old male was brought in by ambulance to the emergency department (ED) after sustaining a gunshot wound to his chin and left shoulder. Upon arrival to the ED, his airway was intact without evidence of blood in the oropharynx. He was found to have slightly diminished breath sounds on the left side, with respirations at 34 breaths per minute, a blood pressure of 72/50mmHg, and a heart rate of 76 beats per minute with cool extremities and poor peripheral pulses. His focused abdominal sonography in trauma exam showed a foreign body within the right ventricle without a pericardial effusion (Figure 1 and Video). An upright portable chest radiograph performed immediately thereafter showed blunting of the left costophrenic angle with a bullet fragment overlying the cardiac shadow (Figure 2).

#### Diagnosis: Traumatic Ventricular Septal Defect

He was taken emergently to the operating room (OR)



**Figure 1.** Parasternal long axis view demonstrating a bullet fragment within the right ventricle.



**Figure 2.** Anteroposterior chest x-ray demonstrating bullet fragment overlying the cardiac shadow.

in cases of penetrating cardiac injury, with an incidence of only 1% to 5%.<sup>1</sup> In patients who respond to resuscitation, as evidenced by systolic blood pressure >60mmHg to <100mmHg, there is evidence that they would benefit from emergency thoracotomy (ET [immediate thoracotomy performed in the OR]), as opposed to ED thoracotomy (EDT [immediate thoracotomy performed in the ED]). In these patients, survival can reach 75% to hospital discharge. Those patients who do not respond to the initial resuscitative effort have only a 25% survival rate after an EDT.<sup>2</sup> Ultrasonography, performed during the initial survey of a trauma patient, has promise as a diagnostic modality for a variety of foreign bodies with a sensitivity and specificity of 96.7% and 70%, respectively.<sup>3</sup> The chest film in the trauma bay showed a bullet fragment overlaying the cardiac shadow; however, given that only a single anteroposterior view was obtained it was difficult to ascertain the exact location of the bullet fragment. The use of ultrasound has the ability to detect intracardiac foreign bodies.

---

*Address for Correspondence:* Abdullah Bakhsh, MD, Emory University School of Medicine, 68 Armstrong St. SE, Atlanta, GA 30303. Email: [abdullahbakhsh@hotmail.com](mailto:abdullahbakhsh@hotmail.com).

*Conflicts of Interest:* By the *WestJEM* article submission agreement, all authors are required to disclose all affiliations, funding sources and financial or management relationships that could be perceived as potential sources of bias. The authors disclosed none.

*Copyright:* © 2016 Bakhsh et al. This is an open access article distributed in accordance with the terms of the Creative Commons Attribution (CC BY 4.0) License. See: <http://creativecommons.org/licenses/by/4.0/>

---

**Video.** Parasternal long axis clip demonstrating a bullet fragment within the right ventricle.

## REFERENCES

1. Sugiyama G, Lau C, Tak V, et al. Traumatic ventricular septal defect. *Ann Thorac Surg.* 2011;91(3):908-10.
2. Van Waes OJ, Van Riet PA, Van Lieshout EM, et al. Immediate thoracotomy for penetrating injuries: ten years' experience at a Dutch level I trauma center. *Eur J Trauma Emerg Surg.* 2012;32(5):543-51.
3. Nienaber A, Harvey M, Cave G. Accuracy of bedside ultrasound for the detection of soft tissue foreign bodies by emergency doctors. *Emerg Med Australas.* 2010;22:30-4.