

UC Davis

Dermatology Online Journal

Title

Successful treatment of recalcitrant discoid lupus erythematosus with ustekinumab

Permalink

<https://escholarship.org/uc/item/206538zm>

Journal

Dermatology Online Journal, 23(1)

Authors

Romero-Maté, Alberto
García-Donoso, Carmen
Hernández-Núñez, Almudena
et al.

Publication Date

2017

DOI

10.5070/D3231033677

Copyright Information

Copyright 2017 by the author(s). This work is made available under the terms of a Creative Commons Attribution-NonCommercial-NoDerivatives License, available at <https://creativecommons.org/licenses/by-nc-nd/4.0/>

Peer reviewed

Successful treatment of recalcitrant discoid lupus erythematosus with ustekinumab

Alberto Romero-Maté¹ MD, Carmen García-Donoso¹ MD, Almudena Hernández-Núñez¹ MD PhD, Cristina Martínez-Morán¹ MD, Amalia Moreno-Torres² MD, Jesús Borbujo-Martínez¹ MD PhD

Affiliations: ¹ Department of Dermatology, Hospital Universitario de Fuenlabrada, Madrid, Spain; ²Departments of Dermatology and Pathology, Hospital Universitario de Fuenlabrada, Madrid, Spain

Corresponding Author: Alberto Romero, Servicio de Dermatología, Hospital de Fuenlabrada Camino del Molino, 2, 28942 Fuenlabrada, Madrid, Spain Tel. 34916006270; Fax. 34916006364 E-mail: aromerom@salud.madrid.org

Abstract

We report a 52-year old woman with a 28-year history of disfiguring facial discoid lupus erythematosus (DLE), persistent despite both classical therapies and rituximab. Ustekinumab 45 mg was started in combination with methotrexate and intralesional corticosteroids. Methotrexate and intralesional corticosteroids were withdrawn 30 months later and ustekinumab maintained as monotherapy. Forty eight months later stable improvement was achieved without side effects. Only nine patients with cutaneous lupus erythematosus (CLE) treated with ustekinumab have been reported to date. Ustekinumab could be a promising alternative in severe and recalcitrant cases of CLE. Possibly, the Th17-inflammation pathway is playing a role in these patients.

Keywords: ustekinumab, cutaneous lupus erythematosus, discoid lupus erythematosus, IL-12, IL-23

Case Synopsis

A 52-year-old woman had a 28-year history of DLE, which exhibited clinically with disfiguring, erythematous and scaly plaques with atrophic scars of the face, neck, and upper back (**Figure 1**). DLE was histopathologically confirmed (**Figure 2**).

She also had antiphospholipid syndrome and a pulmonary thromboembolism 9 years before, treated with acenocoumarol. Previously, topical and intralesional corticosteroids, topical pimecrolimus, antimalarials, acitretin, azathioprine, and dapsone

had been used but were withdrawn owing to lack of response or side effects. Between 2004 and 2012, she received several additional treatments. Photodynamic therapy was stopped because of side effects after two sessions, without benefit [1]. Methylprednisolone boluses, methotrexate in combination with prednisone, neosidantoiné, and cyclosporine were all ineffective. In January 2009, efalizumab achieved complete control of the inflammation, but was stopped after market withdrawal in April 2009; inflammation of old plaques appeared a few days later. Again methotrexate, in combination with prednisone, acitretin, and thalidomidewereprescribed,withoutremarkableside effects but without complete control of the disease. A combination of mepacrine and methotrexate was also unsuccessful. Weekly rituximab 375mg/m² for a total of 6 weeks was stopped because

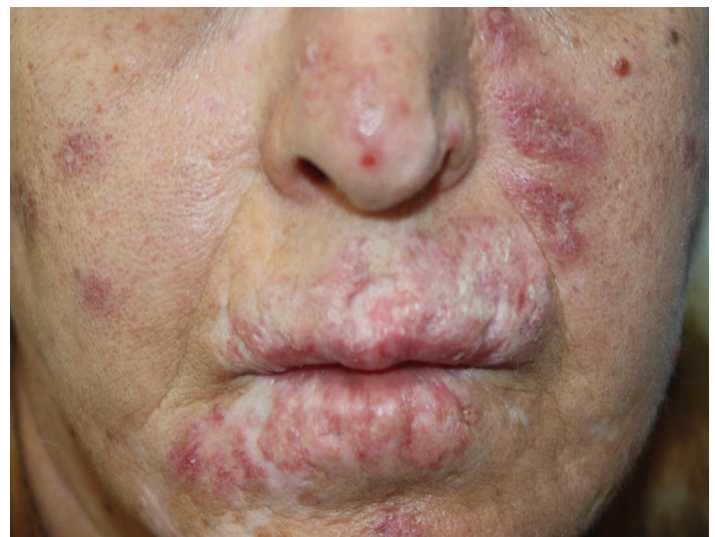

Figure 1. DLE before ustekinumab in March 2012: Erythematous and atrophic disfiguring plaques on the lips, chin, and left cheek.

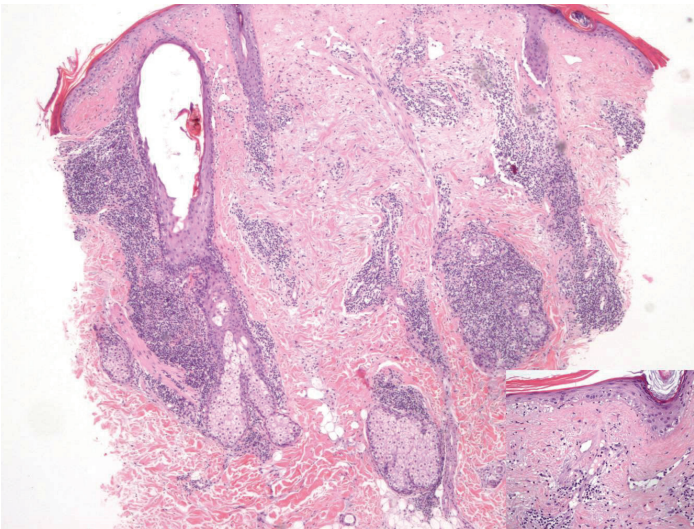


Figure 2. Interface dermatitis involving the follicles and epidermis accompanied by a moderate to heavy superficial and deep perivascular and periapendageal lymphocytic infiltrate (H&E 40x). Inset figure: detail of epidermal interface dermatitis with a keratotic plug and basement membrane zone thickening, note atrophic epidermis (H&E 100x).

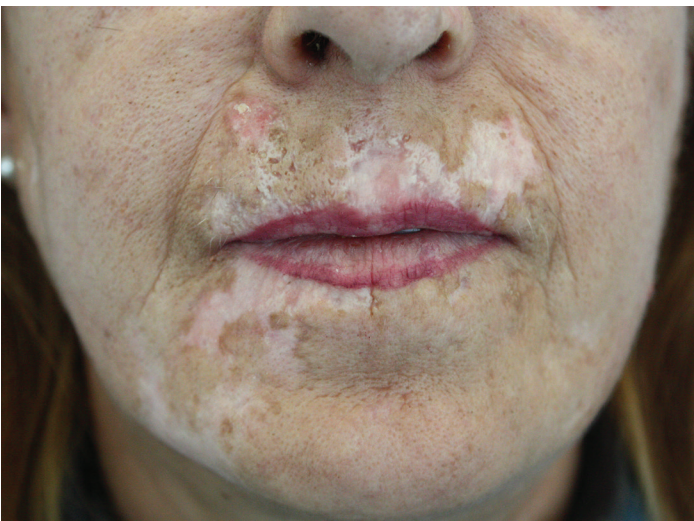

Figure 3. DLE three years after ustekinumab, in May 2015. Cicatricial plaques around the mouth with little active inflammation.

of poor results. Methotrexate associated with mycophenolate mophetil was not effective. In March 2012 ustekinumab was started. It was administered as 45 mg at weeks 0, 4, and then every 12 weeks, while she was still taking methotrexate.

Intralesional corticosteroids were injected in the most active lesions every 4-6 weeks. Since then, slow but continuous improvement was noted and methotrexate was able to be withdrawn in September 2014. She is now receiving monotherapy

with ustekinumab 45 mg every 12 weeks, with only a few lesions remaining slightly active (**Figure 3**). She had no remarkable side effects after 4 years of continuous therapy.

Case Discussion

Cutaneous discoid lupus erythematosus (DLE) is a challenging disease. Antimalarials, corticosteroids, immunosuppressants (azathioprine, methotrexate, mycophenolate mophetil), and thalidomide are well known therapies for this condition. However, if lack of response occurs, there are few alternatives available.

The development of biologics has opened new avenues for the treatment of DLE. Although anti tumour necrosis factor (anti-TNF)-induced CLE and systemic lupus erythematosus (SLE) have been widely reported [2, 3], but are infrequent. In addition, clinical lupus flares in patients with psoriasis and lupus erythematosus (LE) treated with anti-TNF are uncommon and these drugs may be a valid alternative [4]. Rituximab is an anti CD-20 monoclonal antibody that induces B-cell depletion and has been widely used to treat SLE [5], but less frequently in cutaneous disease [6, 7]. Although some studies have showed promising results, this medication did not help our patient.

Ustekinumab is a monoclonal antibody that targets the p40 subunit of IL-12/23, thus inhibiting Th1 and Th17 pathways. The Th17 pathway has been suggested to play a role in subacute cutaneous lupus erythematosus (SCLE). IL-17, which is produced by Th17 lymphocytes and other immune cells, is significantly elevated in the skin of patients with SCLE and DLE [8]. Also, IL-17 expression was detected in skin fibroblasts, owing to IL-17 binding to its receptors on fibroblast surfaces [8]. IL-17 stimulates T cells, increases the production of autoantibodies, inflammatory cytokines (TNF- α , IL-1 β , IL-6, IL-8, IL-17, IL-22, etc.), and chemokines (CCL2, CCL7, CCL20, CXCL1, and CXCL5), and induces neutrophil recruitment through chemokine regulation [9]. The imbalance of pro- and anti-inflammatory cell subsets and cytokines favors inflammation, with the latter failing to maintain homeostasis. Accordingly, preventing the differentiation of T cells to Th17 via IL12/23 inhibition could stop the inflammatory cascade.

To date, only 9 cases of lupus erythematosus treated with ustekinumab have been reported. Varada [4] describes 5 patients, with psoriasis and SLE and one more with psoriasis and DLE, treated with ustekinumab. Two of the patients, both with SLE, had to stop ustekinumab, owing to adverse events (cellulitis and a flare of psoriatic arthritis); the remaining four had good results. Chuyan [10] describes another patient with coexistent SLE and psoriasis, treated with ustekinumab with good results. Winchester [11] reported another case of psoriasis and DLE, successfully treated with ustekinumab. Two of the 9 cases are patients in whom ustekinumab was prescribed for LE, as no associated psoriasis was present. Dhal [12] reported a patient with DLE who achieved substantial improvement after 34 weeks on ustekinumab and De Souza [13] reported a patient with SCLE who had marked improvement of the disease a month after starting ustekinumab.

Our patient did not improve with any of the classical therapies nor rituximab. Only efalizumab achieved regression of the lesions in a few weeks, but it was withdrawn from the market shortly after. Efalizumab is a humanized form of a murine antibody directed against CD11a, the subunit of the lymphocyte function-associated antigen-1 (LFA-1), that inhibits T-cell activation, trafficking, and adhesion. Finally, addition of ustekinumab to immunosuppressants and intralesional corticosteroids in some of the most intractable plaques was the key to achieve near-clearing. Immunosuppressants were withdrawn after 30 months without further flares and intralesional corticosteroids have been no longer needed since June 2015. To date ustekinumab monotherapy has been sufficient to maintain remission. In addition, it played a critical role in conjunction with methotrexate and intralesional corticosteroids in active disease suppression. We believe that ustekinumab could be an effective and safe alternative to treat SCLE or DLE in refractory patients and that the Th17 pathway may play a role in the disease, although more evidence is needed.

References

1. Romero-Maté A, Castaño- Suárez E, García-Donoso C, et al. Unsuccessful treatment of recalcitrant cutaneous discoid lupus erythematosus with photodynamic therapy. *Photodermatol Photoimmunol Photomed*. 2010 Jun;26(3):156-8. [PMID: 20584256]
2. Levine D, Switlyk SA, Gottlieb A. Cutaneous lupus erythematosus

- and anti-TNF-alpha therapy: a case report with review of the literature. *J Drugs Dermatol*. 2010 Oct;9(10):1283-7. [PMID: 20941956]
3. Almoallim H, Al-Ghamdi Y, Almaghrabi H, et al. Anti-Tumor Necrosis Factor- α Induced Systemic Lupus Erythematosus. *Open Rheumatol J*. 2012;6:315-9. [PMID: 23198006]
4. Varada S, Gottlieb AB, Merola JF, et al. Treatment of coexistent psoriasis and lupus erythematosus. *J Am Acad Dermatol*. 2015 Feb;72(2):253-60 [PMID: 25486913]
5. Kamal A, Khamashta M. The efficacy of novel B cell biologics as the future of SLE treatment: a review. *Autoimmun Rev*. 2014 Nov;13(11):1094-101 [PMID: 25149393]
6. Kieu V, O'Brien T, Yap LM, et al. Refractory subacute cutaneous lupus erythematosus successfully treated with rituximab. *Australas J Dermatol*. 2009 Aug;50(3):202-6 [PMID: 19659984]
7. Hofmann SC, Leandro MJ, Morris SD, et al. Effects of rituximab-based B-cell depletion therapy on skin manifestations of lupus erythematosus--report of 17 cases and review of the literature. *Lupus*. 2013 Aug;22(9):932-9 [PMID: 23894047]
8. Tanasescu C, Balanescu E, Balanescu P, et al. IL-17 in cutaneous lupus erythematosus. *Eur J Intern Med*. 2010 Jun;21(3):202-7. [PMID: 20493423]
9. Méndez-Flores S, Hernández-Molina G, Enríquez AB, et al. Cytokines and Effector/Regulatory Cells Characterization in the Physiopathology of Cutaneous Lupus Erythematosus: A Cross-Sectional Study. *Mediators Inflamm*. 2016; 2016:7074829. doi: 10.1155/2016/7074829. Epub 2016 Mar 6
10. Chyuan IT, Tsai TH, Chang TH, et al. Ustekinumab treatment in a patient with psoriasis and systemic lupus erythematosus. *Lupus*. 2015 May;24(6):650-1. [PMID: 25413358]
11. Winchester D, Duffin KC, Hansen C. Response to ustekinumab in a patient with both severe psoriasis and hypertrophic cutaneous lupus. *Lupus*. 2012 Aug;21(9):1007-10 [PMID: 22438028]
12. Dahl C, Johansen C, Kragballe K, et al. Ustekinumab in the treatment of refractory chronic cutaneous lupus erythematosus: a case report. *Acta Derm Venereol*. 2013 May;93(3):368-9. [PMID: 23038045]
13. De Souza A, Ali-Shaw T, Strober BE, et al. Successful treatment of subacute lupus erythematosus with ustekinumab. *Arch Dermatol*. 2011 Aug;147(8):896-8. [PMID: 21844448]