

# UCSF

## UC San Francisco Previously Published Works

### Title

Direct Spread of Primary Testicular Lymphoma along the Gonadal Vessels Detected on F-18 Fluorodeoxyglucose Positron-Emission Tomography/Computed Tomography Imaging

### Permalink

<https://escholarship.org/uc/item/1zh5642k>

### Journal

Indian Journal of Nuclear Medicine, 36(3)

### ISSN

0972-3919

### Authors

Bhargava, Peeyush

Ikwuagwu, Ndy

Villanueva-Meyer, Javier

### Publication Date

2021

### DOI

10.4103/ijnm.ijnm\_34\_21

### Copyright Information

This work is made available under the terms of a Creative Commons Attribution-NonCommercial-ShareAlike License, available at <https://creativecommons.org/licenses/by-nc-sa/4.0/>

Peer reviewed

## Direct Spread of Primary Testicular Lymphoma along the Gonadal Vessels Detected on F-18 Fluorodeoxyglucose Positron-Emission Tomography/Computed Tomography Imaging

### Abstract:

A 63-year-old male presented with left scrotal swelling and the ultrasound showed a large heterogeneous mass consistent with a testicular malignancy. The patient underwent left-sided orchiectomy which showed diffuse large B-cell lymphoma. The patient was then referred for whole-body F-18 fluorodeoxyglucose positron-emission tomography/computed tomography (FDG PET/CT) imaging which showed multiple hypermetabolic foci extending along the left inguinal canal to the retroperitoneum and the left perinephric space, suggesting direct contiguous spread of the tumor along the gonadal vessels, a form of metastasis unique to primary testicular lymphoma, and demonstrated for the first time on FDG PET/CT imaging.

**Keywords:** *Lymphoma, positron-emission tomography/computed tomography, testicular*

The patient underwent left-sided orchiectomy after the ultrasound (US) showed a large heterogeneous mass in the left testis (not shown). Pathology showed diffuse large B-cell lymphoma and the patient was referred for whole-body staging using F-18 fluorodeoxyglucose positron-emission tomography/computed tomography (FDG PET/CT). The MIP image, Figure 1a, acquired after the intravenous administration of 16.0 mCi (592 mBq) of F-18 FDG shows multiple hypermetabolic foci extending from the left groin to the retroperitoneum in a curvilinear pattern (black arrow). Panels b, c, and d show coronal PET, fused PET/CT, and CT images at the level of the left inguinal canal, pelvis, and the perinephric space, respectively, demonstrating abnormal hypermetabolic soft tissue extending from the left inguinal canal to the left perinephric space (arrows). Panels a, b, and c in Figure 2 show the corresponding axial images with direct spread of primary testicular lymphoma (PTL) along the left gonadal vessels (arrows), through the inguinal canal and the retroperitoneum, to the left perinephric space.

PTL is a rare form of extranodal lymphoma arising from the testis. PTL constitutes <5% of testicular tumors and about 1%–2% of

non-Hodgkin's lymphoma.<sup>[1,2]</sup> It is the most frequent testicular neoplasm in men over the age of 60 years who typically present with painless scrotal swelling and there may be bilateral and systemic involvement, especially the central nervous system.<sup>[3-5]</sup> The most common histological subtype is diffuse large B-cell lymphoma.<sup>[6]</sup> Although these patients respond well to chemotherapy, 5-year survival is 35% with a mean survival of 13 months.<sup>[7]</sup>

Several case reports have shown a direct spread of PTL along the spermatic cord and gonadal vessels, and this has been proposed to be unique to PTL and not reported in other more common testicular tumors.<sup>[8-10]</sup> On CT, this is seen as contiguous abnormal soft tissue extending along the spermatic cord and the gonadal vessels, through the inguinal canal, and the retroperitoneum, to the level of insertion of the gonadal veins.<sup>[8-10]</sup> FDG PET/CT although has limited value in initial diagnosis and differentiation of PTL from other primary testicular neoplasms, it is the imaging modality of choice for identifying extratesticular involvement and staging/restaging of PTL.<sup>[11]</sup> Our case shows the utility of FDG PET/CT in identifying the direct

**Peeyush Bhargava,  
Ndy Ikwuagwu,  
Javier  
Villanueva-Meyer**

*Department of Radiology,  
Division of Nuclear Medicine,  
University of Texas Medical  
Branch, Galveston, TX, USA*

### Address for correspondence:

*Dr. Peeyush Bhargava,  
Department of Radiology,  
Division of Nuclear Medicine,  
University of Texas Medical  
Branch, 301 University Blvd.  
UTMB, Galveston,  
TX 77555, USA.  
E-mail: peeyush\_bhargava@  
yahoo.com*

Received: 14-03-2021

Revised: 12-05-2021

Accepted: 29-05-2021

Published: 23-09-2021

### Access this article online

Website: [www.ijnm.in](http://www.ijnm.in)

DOI: 10.4103/ijnm.ijnm\_34\_21

### Quick Response Code:



**How to cite this article:** Bhargava P, Ikwuagwu N, Villanueva-Meyer J. Direct Spread of Primary Testicular Lymphoma along the Gonadal Vessels Detected on F-18 Fluorodeoxyglucose Positron-Emission Tomography/Computed Tomography Imaging. *Indian J Nucl Med* 2021;36:340-2.

This is an open access journal, and articles are distributed under the terms of the Creative Commons Attribution-NonCommercial-ShareAlike 4.0 License, which allows others to remix, tweak, and build upon the work non-commercially, as long as appropriate credit is given and the new creations are licensed under the identical terms.

For reprints contact: [WKHLRPMedknow\\_reprints@wolterskluwer.com](mailto:WKHLRPMedknow_reprints@wolterskluwer.com)

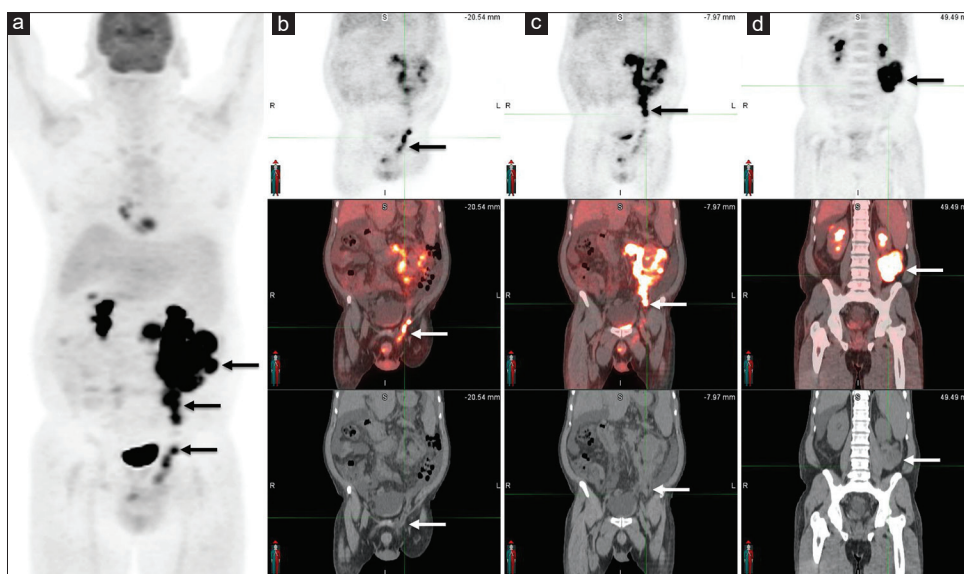


Figure 1: Multiple images from FDG PET/CT study. The whole-body MIP image (a) shows multiple foci of intense uptake seen extending from the left groin to the left kidney (black arrows). Panels (b-d) are coronal PET, fused coronal PET/CT and coronal CT images at multiple levels (from anterior to posterior respectively) showing hypermetabolic tumor foci extending along the left inguinal canal, to the retroperitoneal space, and the left perinephric space

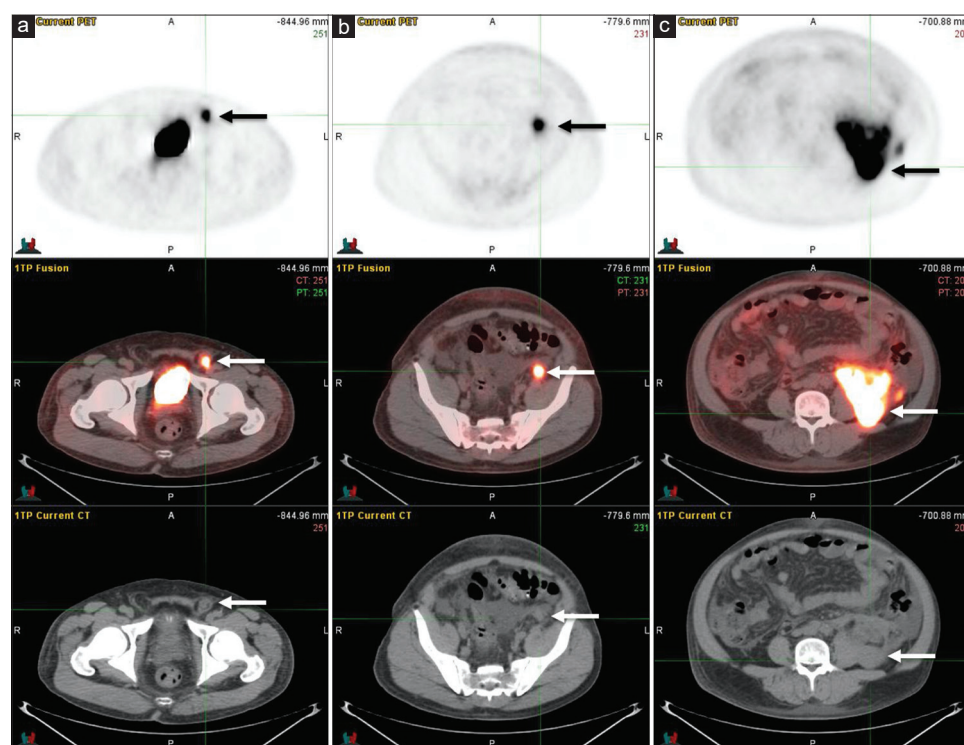


Figure 2: Panels (a-c) are axial PET, fused axial PET/CT and axial CT images at multiple levels (from inferior to superior respectively) showing hypermetabolic tumor foci extending along the left inguinal canal, to the retroperitoneal space, and the left perinephric space

spread of PTL along the gonadal vessels to the retroperitoneum.

#### Declaration of patient consent

The authors certify that they have obtained all appropriate patient consent forms. In the form the patient (s) has/have given his/her/their consent for his/her/their images and

other clinical information to be reported in the journal. The patients understand that their names and initials will not be published and due efforts will be made to conceal their identity, but anonymity cannot be guaranteed.

#### Financial support and sponsorship

Nil.

### Conflicts of interest

There are no conflicts of interest.

### References

1. Shahab N, Doll DC. Testicular lymphoma. *Semin Oncol* 1999;26:259-69.
2. Lantz AG, Power N, Hutton B, Gupta R. Malignant lymphoma of the testis: A study of 12 cases. *Can Urol Assoc J* 2009;3:393-8.
3. Horne MJ, Adeniran AJ. Primary diffuse large B-cell lymphoma of the testis. *Arch Pathol Lab Med* 2011;135:1363-7.
4. Crellin AM, Hudson BV, Bennett MH, Harland S, Hudson GV. Non-Hodgkin's lymphoma of the testis. *Radiother Oncol* 1993;27:99-106.
5. Lokesh KN, Sathyanarayanan V, Kuntegowdanahalli CL, Suresh TM, Dasappa L, Kanakasetty GB. Primary diffuse large B-Cell lymphoma of testis: A single centre experience and review of literature. *Urol Ann* 2014;6:231-4.
6. Cheah CY, Wirth A, Seymour JF. Primary testicular lymphoma. *Blood* 2014;123:486-93.
7. Jia B, Shi Y, Dong M, Feng F, Yang S, Lin H, *et al.* Clinical features, survival and prognostic factors of primary testicular diffuse large B-cell lymphoma. *Chin J Cancer Res* 2014;26:459-65.
8. Sabale A, Prahladan A, Kalidos K, Koshy SM, Ramachandran K. Unusual continuous intra-abdominal spread of primary testicular lymphoma along the spermatic cord and gonadal vessels: Report of 2 cases. *Radiol Case Rep* 2015;10:76-80.
9. Sabarwal KS, Ismail EH. A case of primary testicular lymphoma with continuous spread along the gonadal vein and spermatic cord. *BJR Case Rep* 2019;5:20180063.
10. Ellatif M, Kumar R, Weller A, Katz D, Vrentzou E. Two cases of primary testicular lymphoma presenting with direct spread along the spermatic cord and gonadal vessels. *Case Rep Radiol* 2019;2019:5953618.
11. Okuyucu K, İnce S, Alagöz E, Ataş E, Arslan N. Utility of FDG PET/CT in the management of primary testicular lymphoma. *Mol Imaging Radionucl Ther* 2018;27:61-5.