

UC San Diego

UC San Diego Previously Published Works

Title

Acetabular Bone Marrow Aspiration During Total Hip Arthroplasty

Permalink

<https://escholarship.org/uc/item/1xv6j4nt>

Journal

Journal of the American Academy of Orthopaedic Surgeons, 29(16)

ISSN

1067-151X

Authors

Ruoss, Severin
Ball, Scott T
Dorn, Shanelle N
et al.

Publication Date

2021-08-15

DOI

10.5435/jaaos-d-21-00085

Peer reviewed

Acetabular Bone Marrow Aspiration During Total Hip Arthroplasty

Severin Ruoss, PhD 

Scott T. Ball, MD

Shanelle N. Dorn, BS

Jesal N. Parekh, PhD

Alexander J. Whitehead, BS

Adam J. Engler, PhD 

Samuel R. Ward, PT, PhD 

ABSTRACT

Biologically augmented surgical treatments of orthopaedic conditions are increasingly popular. Bone marrow aspirate concentrate is a key orthobiologic tissue source, and the field is moving from the standard iliac crest marrow aspiration toward local aspirations of marrow depots that are accessible during the standard-of-care procedures in an attempt to reduce morbidity, surgery time, and cost. Here, we present the aspiration of the standard iliac marrow depot, but through a novel acetabular approach during total hip arthroplasty. This procedure markedly simplifies biologic augmentation with bone marrow aspirate concentrate in this large patient cohort.

Bone marrow aspirate (BMA) has seen growing interest as an autologous source for mesenchymal stromal cells (MSCs), previously termed “stem cells.”^{1,2} These cells are either culture-expanded or in the form of minimally manipulated BMA concentrate (BMAC), directly reinjected after harvest to treat patients suffering from osteoarthritis (OA), bone defects, osteonecrosis, chondral defects, tendinopathy, and other orthopaedic diseases.³⁻¹¹ The most commonly used aspiration sites are the anterior and posterior iliac crest,^{12,13} but other sites have been used depending on the patient population, type of surgery, and the clinical use of the aspirate, with the goal to limit morbidity by reducing the number of surgical fields.¹⁴ These options have included aspiration from femur, tibia, malleolus, and calcaneus for lower limb procedures,¹⁵⁻¹⁷ and sternum and humerus for upper body procedures.^{18,19} Typically, aspirations from central and flat bones are preferred over peripheral and long bones because they seem to contain less adipocytes and more progenitor cells.^{16,20} For this reason, the ilium has traditionally served as an autologous bone marrow source, which has been accessed through the iliac crest. In an attempt to maximize procedure efficiency and the therapeutic potency of the marrow preparation, a variety of variables have been investigated, including a different number of aspiration holes along the iliac crest, changing needle depths, angles and rotations, syringe sizes, aspiration speed and volumes, and processing systems. So far, the literature has been conflicting, and the question of whether a certain BMAC preparation is more potent to treat a specific condition remains unresolved.^{15,21-27}

From the Department of Orthopaedic Surgery (Ruoss, Ball, Dorn, Parekh, and Ward), the Department of Bioengineering (Whitehead, Engler, and Ward), and the Department of Radiology, UC, San Diego, La Jolla, CA (Ward).

None of the following authors or any immediate family member has received anything of value from or has stock or stock options held in a commercial company or institution related directly or indirectly to the subject of this article: Ruoss, Ball, Dorn, Parekh, Whitehead, Engler, and Ward.

Conception and design of research: Ward, Ruoss; Subject recruitment: Parekh; Performed surgeries: Ball; Performed BMAC analysis: Ruoss, Dorn, Whitehead; Analyzed data: Ruoss, Ward, Ball, Engler; Funding: Ward; Infrastructure: Ward; Prepared figures: Ruoss, Whitehead; Drafted manuscript: Ruoss, Ball; Edited and revised manuscript: All authors.

J Am Acad Orthop Surg 2021;29:e815-e819

DOI: 10.5435/JAAOS-D-21-00085

Copyright 2021 by the American Academy of Orthopaedic Surgeons.

In patients undergoing total hip arthroplasty (THA), the ilium can be accessed inferiorly through the acetabulum. Thus, we wondered whether an acetabular approach is a viable alternative to crest aspiration to access iliac bone marrow. This would minimize morbidity and surgical time if treatment with a biologic is considered for patients from this cohort. This is particularly interesting because (1) primary and revision THA cases have increased exponentially, and currently, the prevalence of primary arthroplasty is projected to be 635,000 annual cases alone in the United States by 2030.²⁸ (2) Depending on age and sex, 8% to 19% of the population above 60 years present with radiographic hip and knee OA, and 5% to 33% above 50 years present with bilateral hip OA.^{29,30} In such a cohort, the surgeon may choose to do unilateral THA and use BMAC to treat a secondary site, as done previously in bilateral knee OA.³¹ In accordance with the current “Regulatory Considerations for Human Cells, Tissues, and Cellular and Tissue-Based Products” by the United States Food and Drug Administration,³² the aspirated tissue would be used at the time of THA and neither stored for later treatment nor more than minimally manipulated. Currently approved strategies that are considered minimal manipulation include centrifugation, which is a strategy for concentration of BMA to BMAC.

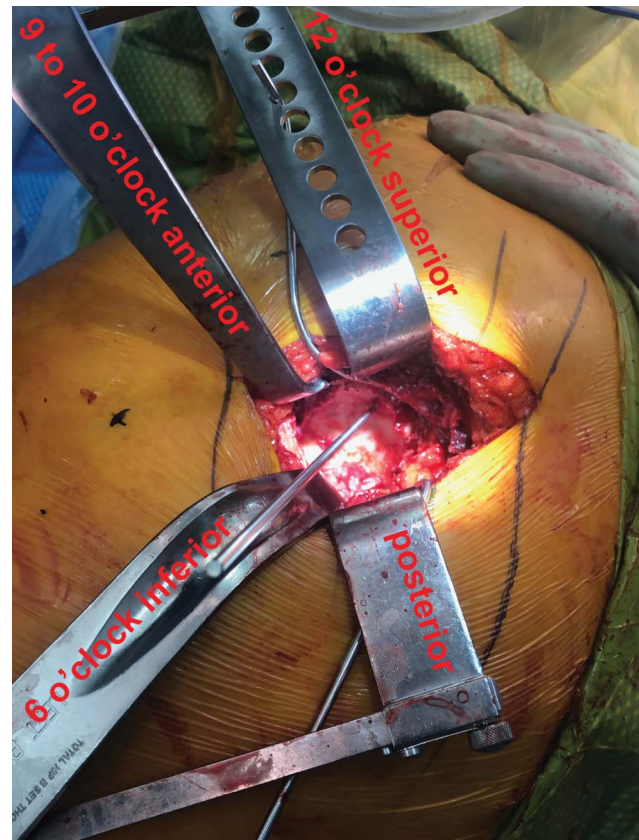
In this brief article, we discuss the acetabulum as a new and convenient access point for bone marrow from the ilium, which may improve treatments of a notable orthopaedic cohort worldwide.

Acetabular Bone Marrow Aspiration

Seventeen patients undergoing THA (nine women: age 64.2 ± 10.4 years [mean \pm SD], body mass 69.6 ± 7.5 kg, height 166.5 ± 6.9 cm, and body mass index 25.2 ± 2.7 kg m⁻²; eight men: age 63.5 ± 12.6 years, body mass 93.6 ± 10.4 kg, height 179.7 ± 5.7 cm, and body mass index 29.0 ± 3.3 kg m⁻²) and free of any hematologic diseases were recruited at the University of California San Diego Department of Orthopaedic Surgery. The study was approved by the University of California San Diego Institutional Review Board, and each patient gave written informed consent.

During THA, the hip joint was exposed through a posterior approach, and after femoral head resection, the acetabulum was visualized. Importantly, the bone marrow aspiration has to be done before reaming the socket. We attempted reaming first to remove the sclerotic bone for easier access to the cancellous bone of the ilium but found that by removing the sclerotic surface, some of the

Figure 1

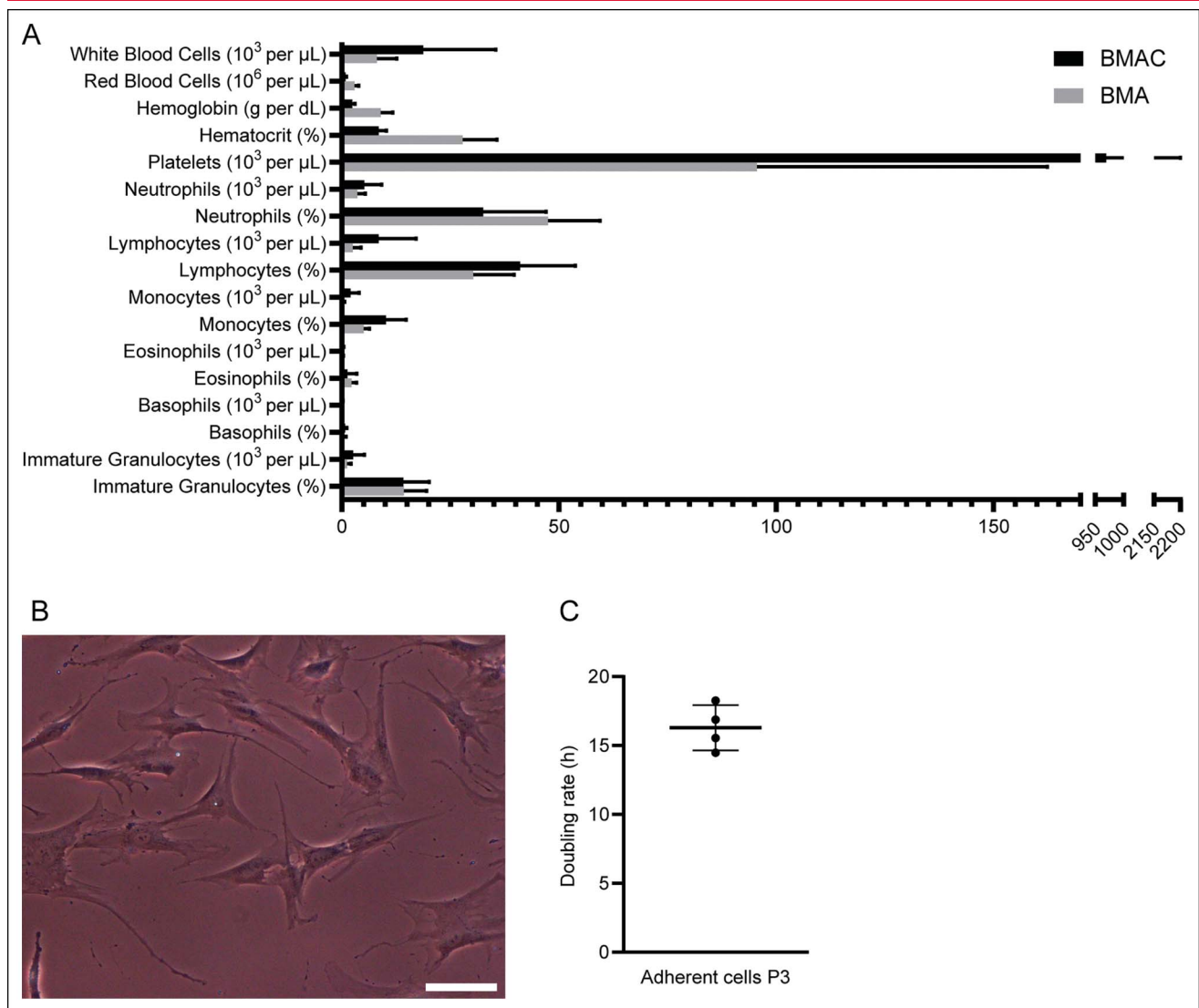


Photograph of Steinmann pin indicating the bone marrow aspiration site in the superior dome of the acetabulum, which corresponds to the typical safe zone for screw fixation.³³ The orientation is indicated by the retractors.

vacuum effect was lost, which made it more difficult to pull adequate volumes of bone marrow. In addition, it has been reported that the first few cc's have a higher concentration of progenitor cells compared with the last cc's because of dilution with blood.²¹ Therefore, we did not want to lose this important fraction by reaming-induced bleeding. The aspiration site is located in the dome of the acetabulum approximately midway between the superior most portion of the acetabular fossa and the superior rim of the acetabulum (Figure 1). This corresponds to the superior “safe zone” commonly used for screw fixation of acetabular implants in THA.³³

We found the sclerotic, articular surface in the dome of the acetabulum to be harder than its iliac-cortex counterpart. Therefore, a pilot hole was created using a 2.0-mm Steinmann pin into the superior dome of the acetabulum in a superomedial direction (Figure 1). Then, the trocar with needle (Arthrex) was inserted into the hole and forwarded using a mallet to a depth of approximately 15 mm. The needle was removed from the trocar, and 2×30 mL syringes were attached to aspirate (50-mL bone

Figure 2



A, Graph showing the results of hematology analysis of BMA and BMAC, N = 13 each. **B**, Representative microscopic image showing plastic-adherent BMAC cells after passage 3. The scale bar denotes 100 μm . **C**, Graph showing cell doubling rates of plastic-adherent BMAC cells of four patients after passage 3. The bars are mean \pm SD. BMA = bone marrow aspirate, BMAC = bone marrow aspirate concentrate

marrow in 10-mL anticoagulant). Finally, the trocar was removed and the THA procedure was continued. After reaming the acetabulum, the pilot hole was unable to be visualized, and the hole was not visualized through the screw holes in the cup. Thus, the cup was placed with no attempt to line up a screw hole with the pilot hole. One screw was placed in all cases, which was the surgeon's typical preference.

This procedure took approximately 2 minutes per case, and no complications were observed in any of these cases. In addition, in all cases, there was no compromise in acetabular implant fixation, and all implants achieved radiographic osseointegration, as determined by 4-month

and 12-month postoperative radiographs. This area of the acetabulum is normally used for screw fixation of the cup, and as such, it is easily accessible from any of the standard approaches to the hip in THA (posterior, anterolateral, and direct anterior approaches).

This technique is relatively contraindicated in patients with notable protrusion where medialization of the acetabulum could increase the risk of the cannula penetrating through the medial wall into the pelvis. Finally, no concerns were observed that the pilot hole may interfere with implant integrity or increase effective joint space. The pilot hole can be thought of as an extremely small acetabular cyst, which are frequently encountered in hip

arthroplasty and are not associated with cup failure or loss of fixation. The effective joint space in hip arthroplasty is generally an extension through the implant to surrounding structures, such as screw holes or dome holes in cups or noncoated channels along previous generation stems. Although it is possible for such a pilot hole to be an extension of the effective joint space, it seems unlikely to be of clinical relevance for a couple of reasons. First, if it is not in line with a screw hole or the dome hole, the remnant of the pilot hole will be covered with a porous surface of the cup, which should ingrow and seal off the effective joint space. Furthermore, with the notable improvements of polyethylene over the past 2 decades, wear and osteolysis have become distinctly uncommon. Finally, for generations, surgeons have been using Steinmann pins in the periarticular space as self-retaining retractors and/or guides to evaluate leg length and offset during the reconstruction, and we are unaware of these holes being implicated in creating channels to increase the effective joint space, and those holes do not get covered by a porous ingrowth surface.

The Cellular Composition of Acetabulum-Aspirated Iliac BMAC and the Proliferative Capacity of its Plasticadherent Cells Are Competitive

BMA was concentrated to BMAC using the Angel System centrifuge (Arthrex) with a 7% hematocrit setting, and a fraction of BMA and BMAC from 13 patients was subjected to complete blood count on a XN-350 hematology analyzer (Sysmex). The range of cell counts and the large between-subject variability for certain populations were in the previously reported range for BMA and BMAC (Figure 2, A).^{3,34,35}

A BMAC fraction of four patients was red blood cell-depleted using ACK buffer (Gibco) at room temperature for 5 minutes and then cultured in low-glucose Dulbecco's Modified Eagle's Medium containing 10% fetal bovine serum and 1% Pen-Strep. Media was changed every other day, by which non-plastic-adherent cells were removed. The adherent cell fraction was passaged at 70% confluence. After passage 3, cell doubling time was assessed as a measurement of cell fitness and lack of senescence.^{36,37} The adherent, fibroblast-shaped BMAC-MSCs (Figure 2, B) doubled every 16.3 ± 1.6 hours (Figure 2, C), which implies a higher proliferative capacity of these cells compared with previously reported doubling rates for human bone marrow-derived MSCs.^{37,38}

Summary

Local aspirations of marrow depots that are accessible during the standard-of-care operating procedure reduce the number of surgical fields, associated morbidity, surgery time, and costs compared with the current benchmark, that is, the iliac crest aspiration. The same iliac marrow depot can be accessed through an acetabular approach in THA patients, which poses a valuable option if biologic augmentation using BMAC is considered in this cohort. It is not uncommon for patients undergoing THA to have less progressed degeneration of other joints (knees or contralateral hip), and with the evolving indications for regenerative and cell-based therapies, there may be future indications described for BMAC to enhance recovery after THA.

Acknowledgments

This work has been generously supported by the Shaffer Family Foundation.

References

References printed in **bold type** are those published within the past 5 years.

- Turner L, Knoepfler P: Selling stem cells in the USA: Assessing the direct-to-consumer industry. *Cell Stem Cell* 2016;19:154-157.
- Sipp D, Robey PG, Turner L: Clear up this stem-cell mess. *Nature* 2018;561:455-457.**
- Shapiro SA, Kazmerchak SE, Heckman MG, Zubair AC, O'Connor MI: A prospective, single-blind, placebo-controlled trial of bone marrow aspirate concentrate for knee osteoarthritis. *Am J Sports Med* 2017;45:82-90.**
- Vega A, Martín-Ferrero MA, Del Canto F, et al: Treatment of knee osteoarthritis with allogeneic bone marrow mesenchymal stem cells: A randomized controlled trial. *Transplantation* 2015;99:1681-1690.
- Chahla J, Piuze NS, Mitchell JJ, et al: Intra-articular cellular therapy for osteoarthritis and focal cartilage defects of the knee: A systematic review of the literature and study quality analysis. *J Bone Joint Surg Am* 2016;98:1511-1521.
- Gessmann J, Köller M, Godry H, Schildhauer TA, Seybold D: Regenerate augmentation with bone marrow concentrate after traumatic bone loss. *Orthop Rev (Pavia)* 2012;4:e14.
- Jäger M, Herten M, Fochtmann U, et al: Bridging the gap: Bone marrow aspiration concentrate reduces autologous bone grafting in osseous defects. *J Orthop Res* 2011;29:173-180.
- Piuze NS, Chahla J, Schrock JB, et al: Evidence for the use of cell-based therapy for the treatment of osteonecrosis of the femoral head: A systematic review of the literature. *J Arthroplasty* 2017;32:1698-1708.**
- Hernigou P, Guerin G, Homma Y, et al: History of concentrated or expanded mesenchymal stem cells for hip osteonecrosis: Is there a target number for osteonecrosis repair?. *Int Orthop* 2018;42:1739-1745.**

10. Imam MA, Holton J, Horriat S, et al: A systematic review of the concept and clinical applications of bone marrow aspirate concentrate in tendon pathology. *SICOT J* 2017;3:58.
11. Pascual-Garrido C, Rolon A, Makino A: Treatment of chronic patellar tendinopathy with autologous bone marrow stem cells: A 5-year-followup. *Stem Cell Int* 2012;2012:953510.
12. Chahla J, Mannava S, Cinque ME, Geeslin AG, Codina D, LaPrade RF: Bone marrow aspirate concentrate harvesting and processing technique. *Arthrosc Tech* 2017;6:e441-e445.
13. Patterson TE, Boehm C, Nakamoto C, et al: The efficiency of bone marrow aspiration for the harvest of connective tissue progenitors from the human iliac crest. *J Bone Joint Surg Am* 2017;99:1673-1682.
14. LaPrade RF, Murray IR: Editorial commentary: Bone marrow aspirate concentrate: Time to harvest locally? *Arthroscopy* 2020;36:2412-2414.
15. Sivasubramaniyan K, Ilas DC, Harichandan A, et al: Bone marrow-harvesting technique influences functional heterogeneity of mesenchymal stem/stromal cells and cartilage regeneration. *Am J Sports Med* 2018;46:3521-3531.
16. Hyer CF, Berlet GC, Bussewitz BW, Hankins T, Ziegler HL, Philbin TM: Quantitative assessment of the yield of osteoblastic connective tissue progenitors in bone marrow aspirate from the iliac crest, tibia, and calcaneus. *J Bone Joint Surg Am* 2013;95:1312-1316.
17. Roukis TS, Hyer CF, Philbin TM, Berlet GC, Lee TH: Complications associated with autogenous bone marrow aspirate harvest from the lower extremity: An observational cohort study. *J Foot Ankle Surg* 2009;48:668-671.
18. Toledo-Pons N, Noell G, Jahn A, et al: Bone marrow characterization in COPD: A multi-level network analysis. *Respir Res* 2018;19:118.
19. Muench LN, Kia C, Otto A, et al: The effect of a single consecutive volume aspiration on concentrated bone marrow from the proximal humerus for clinical application. *BMC Musculoskelet Disord* 2019;20:543.
20. Kricun ME: Red-yellow marrow conversion: Its effect on the location of some solitary bone lesions. *Skeletal Radiol* 1985;14:10-19.
21. Muschler GF, Boehm C, Easley K: Aspiration to obtain osteoblast progenitor cells from human bone marrow: The influence of aspiration volume. *J Bone Joint Surg Am* 1997;79:1699-1709.
22. Hernigou P, Homma Y, Flouzat Lachaniette CH, et al: Benefits of small volume and small syringe for bone marrow aspirations of mesenchymal stem cells. *Int Orthop* 2013;37:2279-2287.
23. Lannert H, Able T, Becker S, et al: Optimizing BM harvesting from normal adult donors. *Bone Marrow Transpl* 2008;42:443-447.
24. Oliver K, Awan T, Bayes M: Single- versus multiple-site harvesting techniques for bone marrow concentrate: Evaluation of aspirate quality and pain. *Orthop J Sports Med* 2017;5:2325967117724398.
25. Hegde V, Shonuga O, Ellis S, et al: A prospective comparison of 3 approved systems for autologous bone marrow concentration demonstrated nonequivalency in progenitor cell number and concentration. *J Orthop Trauma* 2014;28:591-598.
26. Schäfer R, DeBaun MR, Fleck E, et al: Quantitation of progenitor cell populations and growth factors after bone marrow aspirate concentration. *J Transl Med* 2019;17:115.
27. Piuze NS, Hussain ZB, Chahla J, et al: Variability in the preparation, reporting, and use of bone marrow aspirate concentrate in musculoskeletal disorders: A systematic review of the clinical orthopaedic literature. *J Bone Joint Surg Am* 2018;100:517-525.
28. Sloan M, Premkumar A, Sheth NP: Projected volume of primary total joint arthroplasty in the U.S., 2014 to 2030. *J Bone Joint Surg Am* 2018;100:1455-1460.
29. Quintana JM, Arostegui I, Escobar A, Azkarate J, Goenaga JL, Lafuente I: Prevalence of knee and hip osteoarthritis and the appropriateness of joint replacement in an older population. *Arch Intern Med* 2008;168:1576-1584.
30. Kim C, Linsenmeyer KD, Vlad SC, et al: Prevalence of radiographic and symptomatic hip osteoarthritis in an urban United States community: The framingham osteoarthritis study. *Arthritis Rheumatol* 2014;66:3013-3017.
31. Hernigou P, Auregan JC, Dubory A, Flouzat-Lachaniette CH, Chevallier N, Rouard H: Subchondral stem cell therapy versus contralateral total knee arthroplasty for osteoarthritis following secondary osteonecrosis of the knee. *Int Orthop* 2018;42:2563-2571.
32. Food and Drug Administration: Regulatory considerations for human cells, tissues, and cellular and tissue-based products: Minimal manipulation and homologous use, Available at: <https://www.fda.gov/regulatory-information/search-fda-guidance-documents/regulatory-considerations-human-cells-tissues-and-cellular-and-tissue-based-products-minimal>. Accessed April 13, 2021.
33. Wasielewski RC, Cooperstein LA, Kruger MP, Rubash HE: Acetabular anatomy and the transacetabular fixation of screws in total hip arthroplasty. *J Bone Joint Surg Am* 1990;72:501-508.
34. Ziegler CG, Van Sloun R, Gonzalez S, et al: Characterization of growth factors, cytokines, and chemokines in bone marrow concentrate and platelet-rich plasma: A prospective analysis. *Am J Sports Med* 2019;47:2174-2187.
35. Anz AW, Hubbard R, Rendos NK, Everts PA, Andrews JR, Hackel JG: Bone marrow aspirate concentrate is equivalent to platelet-rich plasma for the treatment of knee osteoarthritis at 1 year: A prospective, randomized trial. *Orthop J Sports Med* 2020;8:2325967119900958.
36. Galipeau J, Sensébé L: Mesenchymal stromal cells: Clinical challenges and therapeutic opportunities. *Cell Stem Cell* 2018;22:824-833.
37. Yang YK, Ogando CR, Wang See C, Chang TY, Barabino GA: Changes in phenotype and differentiation potential of human mesenchymal stem cells aging in vitro. *Stem Cell Res Ther* 2018;9:131.
38. Li X, Bai J, Ji X, Li R, Xuan Y, Wang Y: Comprehensive characterization of four different populations of human mesenchymal stem cells as regards their immune properties, proliferation and differentiation. *Int J Mol Med* 2014;34:695-704.