

UC Davis

Dermatology Online Journal

Title

Dupilumab for the treatment of nivolumab-induced bullous pemphigoid: a case report and review of the literature

Permalink

<https://escholarship.org/uc/item/1wr6m73b>

Journal

Dermatology Online Journal, 27(9)

Authors

Klepper, Edward M
Robinson, Howard N

Publication Date

2021

DOI

10.5070/D327955136

Copyright Information

Copyright 2021 by the author(s). This work is made available under the terms of a Creative Commons Attribution-NonCommercial-NoDerivatives License, available at <https://creativecommons.org/licenses/by-nc-nd/4.0/>

Peer reviewed

Dupilumab for the treatment of nivolumab-induced bullous pemphigoid: a case report and review of the literature

Edward M Klepper¹ MS, Howard N Robinson¹ MD

Affiliations: Bernstein & Robinson Dermatology, Bel Air, Maryland, USA

Corresponding Authors: Edward M Klepper MS, Bernstein & Robinson Dermatology PA, 1115 South Main Street, Bel Air, MD 21014, Tel: 410-836-7404, Email: edwardklepper@gmail.com; Howard N Robinson MD, Bernstein & Robinson Dermatology PA, 1115 South Main Street, Bel Air, MD 21014, Tel: 410-836-7404, Email: hnrobinson@yahoo.com

Abstract

Immune checkpoint inhibitors, a relatively new class of drugs, are used to treat a variety of malignancies. These drugs have a known association with cutaneous side effects, such as bullous pemphigoid. Bullous pemphigoid is a pruritic blistering disorder that is caused by autoantibodies forming against the basement membrane of the epidermis. New research has shown that interleukin-4, interleukin-13, and eosinophils play a significant role in the pathogenesis of bullous pemphigoid. Dupilumab, an IL4 alpha receptor antagonist has been shown to reduce IL4 and IL13 in atopic dermatitis. We present a case of nivolumab-induced bullous pemphigoid that was successfully treated with dupilumab.

Keywords: autoantibody, bullae, bullous pemphigoid, dupilumab, eosinophils, immune checkpoint inhibitors, immunotherapy, IL4, IL13, nivolumab, PD1, PDL1, pruritus

Introduction

Immune checkpoint inhibitors are a new class of drugs that have quickly become the first-line treatment for a wide variety of malignancies because of their efficacy and lowered toxicity [1,2]. However, the use of monoclonal antibodies against program cell death protein-1 (PD1) and program cell death ligand-1 (PDL1) does not come without risks. Immune checkpoint inhibitors can cause a vast array of cutaneous side effects, including life threatening bullous pemphigoid (BP), [1-3]. To our knowledge, 22 cases of PD1/PDL1 inhibitor associated BP have been reported thus far in the literature [2].

Bullous pemphigoid (BP) is an autoimmune blistering disease that primarily affects the elderly [4]. This blistering disorder is caused by immunoglobulin G (IgG) autoantibodies forming against the hemidesmosomal antigens, BP180 and BP230, of the basement membrane zone of the epidermis [4,5].

Recently, researchers have learned more about this disease and have discovered other mechanisms that may contribute to the disease process. A study by Teraki, Hotta, and Shiohara showed increased interleukin-4 (IL4) and interleukin-13 (IL13) producing cells in the blood serum and blister fluid in those with BP [6].

In 2017, dupilumab (Dupixent, Regeneron), an IL4 alpha receptor antagonist (IL4ra), was approved for atopic dermatitis in those 6 years of age and older [7]. Because dupilumab blocks both interleukin-4 (IL4) and interleukin-13 (IL13), dupilumab could be a novel treatment for BP.

Herein, we present a 79-year-old woman with nivolumab (Opdivo, Bristol Myers Squibb)-induced BP who was successfully treated with dupilumab. Dupilumab was chosen in this case due to side effects and contraindications to conventional therapies. Along with this case report, we review the literature of all BP cases treated with dupilumab and potential future therapies for BP.

Case Synopsis

A 79-year-old woman with a past medical history of melanoma in situ (in 2016) and desmoplastic malignant melanoma (in 2018) presented with a new onset of pruritic, erythematous lesions. The

desmoplastic melanoma appeared adjacent to her previous melanoma site two years later and both melanomas were excised with wide margins. All were treated by a previous dermatologist. The patient had a sentinel lymph node biopsy which was negative and followed with radiation from her oncologist. Quarterly positron emission tomography (PET) scans and brain magnetic resonance imaging (MRI) were all negative. The patient reported that she will be finishing a 12-month course of nivolumab to prevent melanoma recurrence in one month. Her medication list included: levothyroxine 25mcg oral capsule, hydrochlorothiazide/losartan 12.5mg/100mg oral tablet, and atorvastatin 40mg oral tablet.

The patient initially presented with pruritic, erythematous macules and patches on the trunk and extremities. Owing to her medication history and presentation, she was initially diagnosed with a cutaneous drug eruption and hydrochlorothiazide/losartan was switched to doxazosin and amlodipine by her primary care provider. The eruption persisted after several weeks off the hydrochlorothiazide/losartan and she was recommended to also discontinue her atorvastatin. Since the eruption persisted despite medication changes it was concluded that nivolumab was the offending agent. The patient's eruption progressed into severe pruritus and bullae formation (**Figure 1**).

Therefore, 3mm punch biopsies were obtained for direct immunofluorescence (DIF) and hematoxylin

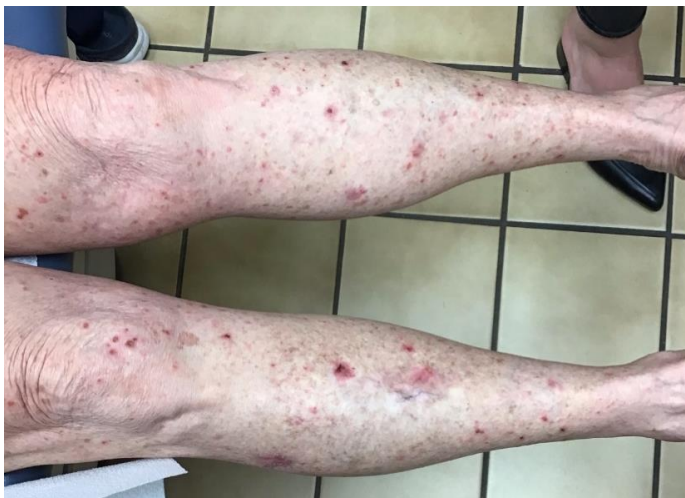

Figure 1. Erythematous vesicles and bullae in various stages of development and healing on the bilateral lower legs.

and eosin. Indirect immunofluorescence (IIF) of blood serum for BP180 IgG and BP230 IgG antibodies were also ordered which showed an elevated BP180 antibody level of 43.4U/mL (negative ≤ 14 U/mL) and a normal BP230 level of 2.2U/mL (negative < 9 U/mL). Direct immunofluorescence of the biopsy from the right upper arm showed intense deposition of IgG, immunoglobulin A (IgA), complement component three (C3), and fibrin along the basement membrane without immunoglobulin M (IgM). There was subepidermal cleft and deposition appearing on both sides. The DIF of the biopsy from the left lower medial leg showed intense deposition of C3 along the basement membrane area of degenerated epidermis, with likely subepidermal vesicles. There was no specific deposition of IgG, IgA, IgM, or fibrin. Hematoxylin and eosin staining of the biopsy from the lower left, more proximal leg showed subepidermal vesicular dermatitis with associated eosinophils in the superficial dermis. The roof of the blister appeared largely necrotic (**Figure 2**). Periodic acid-Schiff-diastase staining appeared negative for fungal hyphae.

Throughout the patient's course of treatment, the eruptions failed to respond to treatment with triamcinolone 0.1% ointment, clobetasol 0.05% ointment, 100mg of doxycycline twice daily, 180mg of fexofenadine daily, oral dapsone, and emollients. Corticosteroid sparing agents such as rituximab (Rituxan, Biogen/Genentech) and mycophenolate mofetil (CellCept, Genentech) were considered; however, her oncologist did not approve of these treatments due to her history of malignancy. The

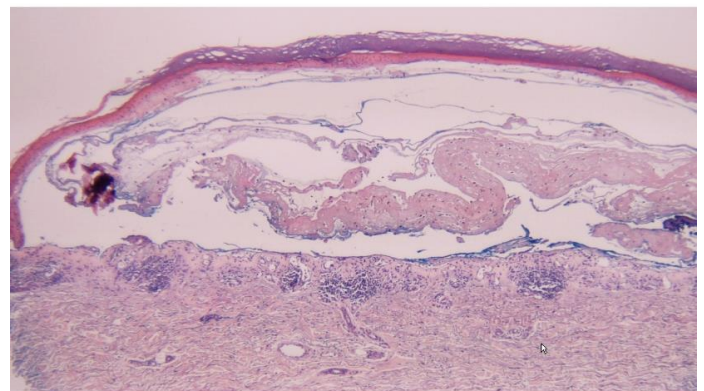


Figure 2. H&E histopathology shows subepidermal vesicular dermatitis with associated eosinophils in the superficial dermis. The roof of the blister appeared largely necrotic, 10x.

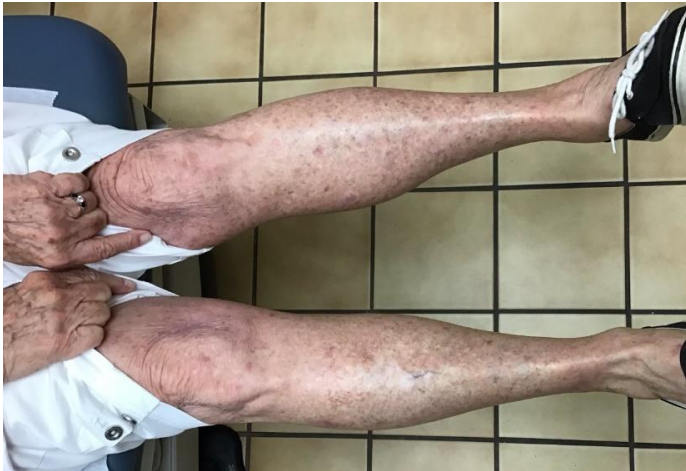

Figure 3. After treatment, the patient presented with no new lesions and the previous lesions were resolved with remaining post-inflammatory hyperpigmentation.

patient was therefore prescribed varying prednisone tapers. Despite improvement of the eruptions on oral prednisone, the patient developed side effects, which included: weight gain, swelling, moon facies, elevated blood pressure, bleeding gums, and blurred vision.

The use of dupilumab was discussed with her oncologist and later approved owing to its early efficacy, low side effect profile, and the lack of malignancy associations in preclinical and clinical trials [7-12]. The patient received a loading dose of 600mg subcutaneously and then 300mg every other week. After four weeks of treatment, she had a 100% reduction in pruritus and new bullae formation with the previous lesions in the process of healing (**Figure 3**). She has received a total of 24 doses thus far and maintains clearance.

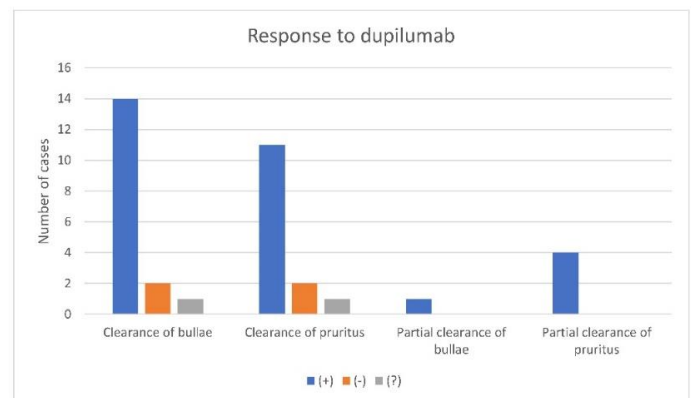
Case Discussion

Dupilumab is a fully human monoclonal IgG4 antibody that targets IL4ra [7]. Binding results in the reduced signaling of T helper type 2 (Th2) cytokines, IL4 and IL13 [7]. It has been approved by the FDA for the treatment of moderate-to-severe atopic dermatitis ages 6 and older, moderate-to-severe asthma ages 12 and older, and inadequately controlled rhinosinusitis with nasal polyposis ages 18 and older [7]. The approved indications are characterized by the type-2 inflammatory response

and immense production of eosinophils [10]. Both cytokines that dupilumab targets drive the chemotaxis of eosinophils, activation of B cells, and class switching of B cells in atopic dermatitis [13,14].

There are several hypotheses regarding the pathophysiology of nivolumab-induced BP. We embrace the hypothesis that since the BP180 antigen is found on tumor cells (malignant melanocytic cells, lung carcinoma cells, and the urothelial epithelial cells), as well as squamous epithelial cells, a cross-reaction most likely occurs when T cells mount a response to tumor cells after a PD1 blocker, in this case nivolumab, unmasks the tumor cells for attack [15,16]. This hypothesis can also explain paraneoplastic BP [17].

Recent research into the underlying cause of BP has suggested that eosinophils contribute significantly to anti-BP180 immunoglobulin E (IgE)-mediated skin blistering [10]. The study by Hashimoto et al. demonstrated a correlation between levels of IL13, eosinophils and the degree of itch [18]. IL4 and IL13 producing cells have also been discovered in the blood serum and blister fluid of patients with BP [6]. A chemokine associated with Th2 cytokines, C-C motif chemokine ligand 18 (CCL18), has also been found at significant levels in the blister fluid of those with BP [19]. CCL18 levels were shown to correlate with the course of disease [19]. Dupilumab has been shown to reduce IL4, IL13, and CCL18 in atopic dermatitis which could translate to a potential mechanism of action in treating BP [13]. Given new



*, negative response; +, positive response; ?, unknown result

Figure 4. Graphical representation of case report and results of all studies using dupilumab to treat bullous pemphigoid [8-11,20].

insights into the pathogenesis of BP, dupilumab could potentially target drivers of autoimmune skin blistering in BP by reducing eosinophils, IL4, IL13, and CCL18.

Given the promising results seen in dupilumab-treated BP patients and dupilumab's low side effect profile, we believed that treating our patient with severe BP with dupilumab was appropriate [7-11]. Potential therapies were limited due to her history of melanoma with local metastasis and side effects of conventional treatments. The review of the literature of seventeen patients showed complete clearance or satisfactory results in fifteen patients and treatment failure in one (**Figure 4, Table 1**), [8-11,20]. Of the thirteen patients studied by Abdat et al., one patient had treatment limitations related to comorbidities and twelve patients had refractory BP [11]. Seven of the thirteen patients had complete clearance and five of the thirteen had satisfactory clearance with a desire to maintain treatment [11]. One study utilized dupilumab for nivolumab induced bullous pemphigoid but did not comment on the response

[20]. Our patient represents the sixteenth patient with a successful outcome; however, she is still undergoing treatment.

When exploring alternative treatments for BP, rituximab has been a new therapy and has been used in one case of nivolumab-induced BP successfully [2]. Rituximab, a chimeric anti-CD20 monoclonal antibody, has demonstrated increased rates of remission with corticosteroid sparing activity. However, it causes the depletion of B cells which may not be ideal in elderly patients as it could make them more susceptible to infection [21].

Since it has been found that Janus kinase (JAK) proteins have been expressed in BP active lesions, these authors have anticipated that targeting JAK proteins could be used in BP treatment [22]. The signal transducer and activator of transcription proteins (JAK/STAT) pathway plays a significant role in cellular proliferation, growth, differentiation, migration, apoptosis, and normal functioning of the immune system [23,24]. In the blister fluid of those with BP, researchers have discovered several

Table 1. Summary of results of studies using dupilumab to treat bullous pemphigoid including this case report [8-11,20].

Patient	Age	Gender	H&E	DIF	IIF	Clearance of bullae	Clearance of pruritus	Partial clearance of bullae	Partial clearance of pruritus	Remission upon discontinuation
1 [8]	80s	M	+	+	-	+	+			?
2 [9]	80	M	+	+	-	+	+			?
3[10]	89	M	+	+	-	+	+			?
4 [11]	83	M	+	+	-	+	+			?
5 [11]	78	F	+	-	+	+	+			?
6 [11]	70	F	+	+	+	+	+			?
7 [11]	77	M	+	+	-	+	+			?
8 [11]	81	M	+	+	+	-			+	?
9 [11]	86	M	+	-	+	+			+	?
10 [11]	83	F	+	+	+	+	+			?
11 [11]	71	F	-	-	-	+	+			?
12 [11]	53	F	+	+	-	-	-			?
13 [11]	86	M	+	-	+	+			+	?
14 [11]	91	M	+	+	-	+	-			?
15 [11]	76	M	+	+	+	+	+			-
16 [11]	64	M	-	+	+			+	+	?
17 [20]	87	M	+	+	-	?	?			?
18**	79	F	+	+	+	+	+			?

DIF, Direct immunofluorescence; F, Female; H&E, hematoxylin and eosin; IIF, Indirect immunofluorescence; M, Male; -, no; +, yes; ?, unknown.

elevations of proinflammatory cytokines that work through the JAK/STAT pathway [25]. In particular, a drug soon to be approved for atopic dermatitis, upadacitinib (Rinvoq, Abbvie), is an oral selective JAK-1 inhibitor that seems to have enhanced activity for treating atopic dermatitis and may possibly be useful in BP [26]. Risks associated with JAK inhibition mainly include increased risk of infection, cytopenias, and mild increases in cholesterol [27]. There is theoretical increased risk of malignancy due to suppression of antitumor immune surveillance [27]. By targeting the Th2 cytokines, IL4 and IL13, dupilumab spares the anti-tumor response of Th1 cell signaling [20]. With this in mind, we believe the side effect profile of dupilumab may be safer. There were no serious side effects observed in dupilumab's clinical trials and the most significant side effect of suppressing IL4 and IL13 was the impaired immune response to helminth infections [7,12].

There are many other drugs being studied for atopic dermatitis that block the JAK-STAT pathway and therefore could be used as potential treatments for BP: upadacitinib (Rinvoq, Abbvie), baricitinib (Olumiant, Lilly), abrocitinib (PF-04965842, Pfizer), ruxolitinib (Jakafi, Incyte/Pfizer), tofacitinib (Xeljanz, Pfizer), cerdulatinib (RVT-502, Dermavant Sciences), gusacitinib (ASN-002, Asana BioSciences), and delgocitinib (JTE-052, Torri), [25].

Conclusion

We report one of the first patients with nivolumab-induced BP to be successfully treated with

dupilumab [20]. Similar to other studies, our patient had a 100% reduction in blisters and pruritus after receiving dupilumab. We speculate that dupilumab's low side effect profile and lack of immune suppression could make it another treatment option for those with limitations or intolerance to standard therapies [7]. The FDA approval of dupilumab for children as young as 6 years of age further substantiates its safety [7]. Because of the expression of IL4 and IL13 in blister fluid, dupilumab may be a preeminent treatment for BP as it directly targets these interleukins, thus surpassing the use of rituximab and other immunomodulators including oral corticosteroids [8].

The limitations of this study include short duration of therapy and concurrent topical corticosteroid use. Because of the high association of BP with age, we cannot rule out the possibility of de novo BP. Further research is needed regarding the safety, efficacy, dosing, and duration of dupilumab treatment for those with a history of malignancy, those with BP induced by immune checkpoint inhibitors (e.g. nivolumab), and those with concurrent use of immune checkpoint inhibitors (e.g. nivolumab).

Potential conflicts of interest

Howard Robinson MD owns shares of Regeneron. No other conflicts to report.

References

1. Kridin K, Ludwig RJ. The growing incidence of bullous pemphigoid: Overview and potential explanations. *Front Med*. 2018;5:1-7. [PMID: 30177969].
2. Lopez AT, Geskin L. A case of nivolumab-induced bullous pemphigoid: Review of dermatologic toxicity associated with programmed cell death protein-1/programmed death ligand-1 inhibitors and recommendations for diagnosis and management. *Oncologist*. 2018;23:1119-1126. [PMID: 30018132].
3. Damsky W, Kole L, Tomayko MM. Development of bullous pemphigoid during nivolumab therapy. *JAAD Case Rep*. 2016;2:442-444. [PMID: 27981213].
4. James WD, Berger TG, Elston DM, Neuhaus IM. *Andrews' disease of the skin: Clinical dermatology*. 12th ed. Elsevier; 2016. p. 458-60.
5. Genovese G, Di Zenzo G, Cozzani E, et al. New insights into the pathogenesis of bullous pemphigoid: 2019 update. *Front Immunol*. 2019;10:1-8. [PMID: 31312206].
6. Teraki Y, Hotta T, Shiohara T. Skin-homing interleukin-4 and -13-producing cells contribute to bullous pemphigoid: Remission of disease is associated with increased frequency of interleukin-10-producing cells. *J Invest Dermatol*. 2001;117:1097-1102. [PMID: 11710918].
7. US FDA. Dupixent® (dupilumab) injection, for subcutaneous use: us prescribing information; 2017. Retrieved from https://www.accessdata.fda.gov/drugsatfda_docs/label/2019/761055s014lbl.pdf. Accessed on December 2, 2020.
8. Kaye A, Gordon SC, Deverapalli SC, Her MJ, Rosmarin D. Dupilumab for the treatment of recalcitrant bullous pemphigoid. *JAMA Dermatol*. 2018;154:1225-1226. [PMID: 30140849].
9. Saleh M, Reedy M, Torok H, Weaver J. Successful treatment of bullous pemphigoid with dupilumab: A case and brief review of the literature. *Dermatol Online J*. 2021;27:1-4. [PMID: 33999579].
10. Seidman JS, Eichenfield DZ, Orme CM. Dupilumab for bullous

- pemphigoid with intractable pruritus. *Dermatol Online J*. 2019;25:1-4. [PMID: 32045153].
11. Abdat R, Waldman RA, Bedout VD, et al. Dupilumab as a novel therapy for bullous pemphigoid: A multicenter case series. *J Am Acad Dermatol*. 2020;83:46–52. [PMID: 32179082].
 12. Braddock M, Hanania NA, Sharafkhaneh A, Colice G, Carlsson M. Potential risks related to modulating interleukin-13 and interleukin-4 signalling: A systematic review. *Drug Saf*. 2018;41:489-509. [PMID: 29411337].
 13. Hamilton JD, Suárez-Fariñas M, Dhingra N, et al. Dupilumab improves the molecular signature in skin of patients with moderate-to-severe atopic dermatitis. *J Allergy Clin Immunol*. 2014;134:1293-1300. [PMID: 25482871].
 14. Russo R, Cozzani E, Gasparini G, Parodi A. Targeting interleukin four receptor α : A new approach to the treatment of cutaneous autoimmune bullous diseases? *Dermatol Ther*. 2020;33:1-5. [PMID: 31863534].
 15. Fairley JA, Heintz PW, Neuburg M, Diaz LA, Giudice GJ. Expression pattern of the bullous pemphigoid-180 antigen in normal and neoplastic epithelia. *Br J Dermatol*. 1995;133:385-392. [PMID: 8546992].
 16. Ong E, Goldacre R, Hoang U, Sinclair R, Goldacre M. Associations between bullous pemphigoid and primary malignant cancers: An English national record linkage study, 1999 - 2011. *Arch Dermatol Res*. 2014;306:75-80. [PMID: 23912480].
 17. Zhao CY, Hwang SJE, Consuegra G, Chou S, Fernandez-Peñas P. Anti-programmed cell death-1 therapy-associated bullous disorders: A systematic review of the literature. *Melanoma Res*. 2018;28:491-501. [PMID: 30169429].
 18. Hashimoto T, Kursewicz CD, Fayne RA, et al. Pathophysiologic mechanisms of itch in bullous pemphigoid. *J Am Acad Dermatol*. 2020;83:53-62. [PMID: 31351883].
 19. Günther C, Carballido-Perrig N, Kopp T, Carballido JM, Pfeiffer C. CCL18 is expressed in patients with bullous pemphigoid and parallels disease course. *Br J Dermatol*. 2009;160:747-755. [PMID: 19120345].
 20. Mihailescu M, Brockstein B, Desai N, et al. Successful reintroduction and continuation of nivolumab in a patient with immune checkpoint inhibitor-induced bullous pemphigoid. *Curr Probl Cancer: Case rep*. 2020; 2:1-4. [DOI: 10.1016/j.cpcr.2020.100031].
 21. Polansky M, Eisenstadt R, Degrazia T, et al. Rituximab therapy in patients with bullous pemphigoid: A retrospective study of 20 patients. *J Am Acad Dermatol*. 2019;81:179–186. [PMID: 30923002].
 22. Juczynska K, Wozniacka A, Waszczykowska E, et al. Expression of the JAK/STAT signaling pathway in bullous pemphigoid and dermatitis herpetiformis. *Mediators Inflamm*. 2017;2017:1-12. [PMID: 29203970].
 23. Anderson CA, Massey DCO, Barret JC, et al. Investigation of Crohn's disease risk loci in ulcerative colitis further defines their molecular relationship. *Gastroenterology*. 2009;136:523–529. [PMID: 19068216].
 24. Walker JG, Ahern MJ, Coleman M., et al. Characterization of a dendritic cell subset in synovial tissue which strongly express Jak/STAT transcription factors from patients with rheumatoid arthritis. *Ann Rheum Dis*. 2007;66:992–999. [PMID: 17223651].
 25. Szilveszter KP, Németh T, Mócsai A. Tyrosine kinases in autoimmune and inflammatory skin diseases. *Front Immunol*. 2019;10:1-21. [PMID: 31447854].
 26. Guttman-Yassky E, Thaçi D, Pangan AL, et al. Upadacitinib in adults with moderate to severe atopic dermatitis: 16-week results from a randomized, placebo-controlled trial. *J Allergy Clin Immunol*. 2020;145:877–884. [PMID: 31786154].
 27. Damsky W, King BA. JAK inhibitors in dermatology: The promise of a new drug class. *J Am Acad Dermatol*. 2017;76:736–744. [PMID: 28139263].
 28. Szalus K, Trzeciak M, Nowicki RJ. JAK-STAT Inhibitors in atopic dermatitis from pathogenesis to clinical trials results. *Microorganisms*. 2020;8:1:14. [PMID: 33172122]