

UC Irvine

Western Journal of Emergency Medicine: Integrating Emergency Care with Population Health

Title

Case of Urethral Foreign Body: IUD Perforation of the Bladder with Calculus Formation

Permalink

<https://escholarship.org/uc/item/1wd8424m>

Journal

Western Journal of Emergency Medicine: Integrating Emergency Care with Population Health, 7(3)

ISSN

1936-900X

Authors

Gillis, Erin
Chhiv, Nak
Kang, Sacha
[et al.](#)

Publication Date

2006

Copyright Information

Copyright 2006 by the author(s). All rights reserved unless otherwise indicated. Contact the author(s) for any necessary permissions. Learn more at <https://escholarship.org/terms>

Peer reviewed

Case Report

Case of Urethral Foreign Body: IUD Perforation of the Bladder with Calculus Formation

E Gillis, MD[^], N Chhiv, MD^{^^}, S Kang, MD^{*}, R Sayegh^{**}, S Lotfipour, MD, MPH^{^^}

[^]Division of Emergency Medicine, Stanford School of Medicine

^{^^}Department of Emergency Medicine, University of California Irvine Medical Center (UCIMC)

^{*}Department of Obstetrics and Gynecology, UCIMC

^{**}University of California-Irvine

Correspondence: Shahram Lotfipour, MD, MPH, FAAEM, FACEP, Assistant Clinical Professor,
University of California Irvine Medical Center, Department of Emergency Medicine
101 The City Drive, Route 128-01
Orange, CA 92868

ABSTRACT—A 28-year-old female presented to the Emergency Department (ED) with a chief complaint of strings protruding from her vagina. The patient also complained of recurrent symptoms of cystitis and occasional hematuria over the past five months without resolution after treatment. The patient underwent ED evaluation and was noted to have strings coated in calculus protruding from her urethral meatus. On AP abdominal film a T-shaped intrauterine device (IUD) with calculus was noted in the pelvis. By computed tomography (CT) scan the object was shown to be extruding from the vagina into the bladder. Of note the patient had a history of IUD use with supposed removal five years prior to presentation. The diagnosis of IUD perforation of the bladder with calculus formation was confirmed by cystoscopy, and the IUD and calculi were successfully removed without complication.

INTRODUCTION

Intrauterine devices (IUDs) have been a viable birth control method since the introduction of the Dalkon Shield in 1970. In 1995 the International Planned Parenthood Federation bulletin quoted nearly 100 million women worldwide as active IUD users.²² Since the advent of intrauterine contraception, a myriad of rare complications have been reported. These

complications include an increased incidence of pelvic infections, septic abortion, endometrial adenocarcinoma, uterine perforation, infertility, and overwhelming sepsis leading to death.^{1, 2, 4-7, 9-18, 21, 23-30} In this paper we will discuss a rare complication of IUD use: uterine perforation with migration into the bladder and subsequent calculus formation. This complication has been reported approximately 50 times in the last 35 years since the inception of intrauterine contraception. Notable in this case is the presentation of the IUD string at the urethral meatus five years after its supposed removal.

CASE REPORT

A 28-year-old Hispanic female presented to the Emergency Department (ED) at UC Irvine Medical Center with a history of vaginal pain and discharge for two days followed by the appearance of strings protruding from her genital area. The patient had been pregnant twice and had delivered two infants (G2P2) at the time of her ED visit. The patient reported a six-month history of dysuria, urinary urgency and increased frequency, suprapubic pain, and intermittent vaginal bleeding followed by a two-day history of vaginal discharge. A few hours prior to presentation, the patient noted strings with “pearls” extruding from her genital area. Of note, the patient reported numerous visits to the hospital for recurrent urinary symptoms without resolution. She had also

undergone colposcopy one month prior to presentation, which was reportedly normal. The patient had a history of IUD placement five years prior to presentation. One month after IUD insertion the patient developed abdominal pain and returned to clinic. According to the patient, the IUD was removed and her pain resolved. The patient was without complaints until one year prior to presentation when she developed suprapubic pain, voiding symptoms, and occasional hematuria for five months.

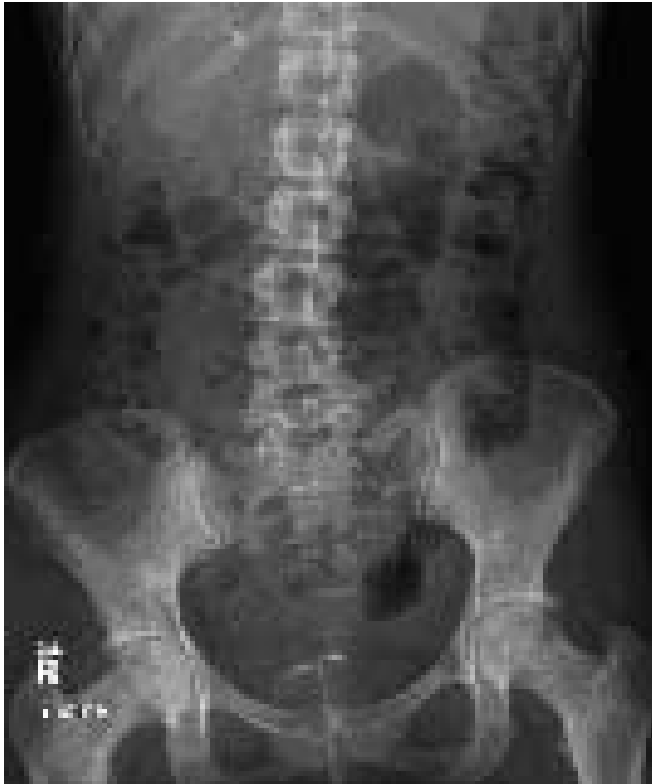

Figure 1. AP View of the Abdomen with a T-shaped IUD in the suprabubic region.

In the emergency department, physical exam showed a string encased in calculus protruding from her urethral meatus. Urinalysis revealed moderate bacteria, large leukocyte esterase, negative nitrites, 17 red blood cells and 59 white blood cells. An antero-posterior (AP) view of the abdomen showed a T-shaped IUD in the suprapubic region, in the correct anatomical location for an intrauterine device (Figure 1). However, bedside ultrasound demonstrated an IUD in the bladder, adherent to the mucosal wall causing exquisite pain with traction. A computed tomography (CT) of the pelvis showed the IUD extruding from the vagina into the bladder (Figure 2).

The patient was then admitted to the Gynecology service at the UC Irvine Medical Center

and a Urology consult was obtained. The patient underwent cystoscopy, holmium laser lithotripsy of bladder calculi, and endoscopic removal of both the Copper-T IUD and the calculus fragments (Figure 3, 4, and 5). No bladder wall defects or fistulas were noted by cystoscopy. Also, no vaginal-wall fistulas or defects were noted on exam under anesthesia. The patient, able to void freely, was discharged to home on hospital day number two.

DISCUSSION

Most reports of IUD perforation of the bladder have occurred with the Lippes Loop or the Copper T devices.⁵

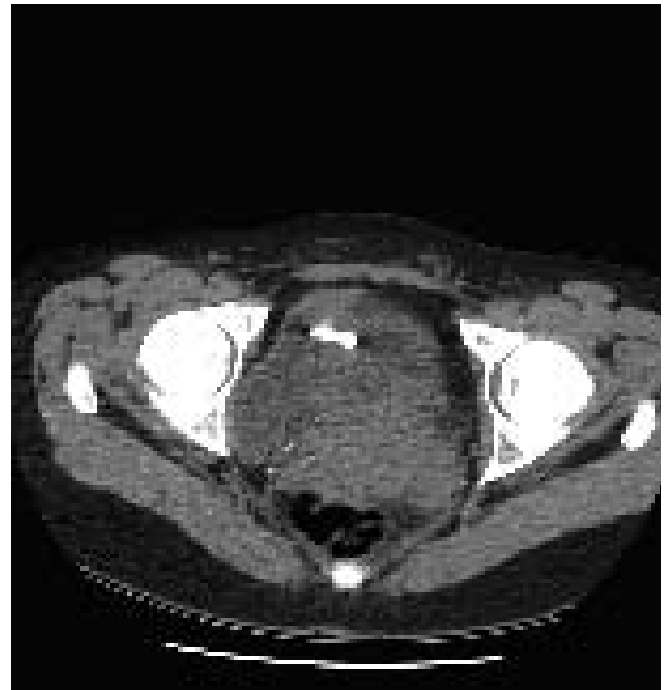

Figure 2. CT of an IUD extruding from the vagina into the bladder.

Today in the U.S. only the Copper T380A and Progestasert, a progesterone-secreting device, are available. However, worldwide a variety of IUDs have been in use since the introduction of the Dalkon Shield in the seventies. In this case, the likely IUD used was a Copper T380A, or ParaGard. This IUD is a T-shaped device with a polyethylene frame wrapped in copper wiring at the stem and collars of copper at each transverse arm.³⁴ The copper acts as both a spermicidal agent as well as a deterrent to implantation.³⁴

The intrauterine contraceptive device has generally been recommended for multiparous women who do not have a history of pelvic inflammatory disease (PID) and who are not at high risk for sexually transmitted diseases.³⁷ Since the newer Copper-T devices are so effective in preventing pregnancy, a history of ectopic pregnancy is no longer considered a contraindication to insertion. In

fact, the Copper T380A may be a viable alternative to sterilization. A multi-center study performed by the World Health Organization (WHO) in 1999 quoted a cumulative pregnancy rate of 2.2 per 100 women over a twelve-year period with the Copper T380A.^{36,37} This rate is similar to that quoted for women in the U.S. who have undergone sterilization.^{37,36} In China, the WHO estimated that if all inserted IUDs from 1993 onwards were the newer copper-containing devices rather than the stainless steel rings, the net effect over ten years would be to avert 41 million pregnancies.³⁶ According to these studies, the new copper IUDs are an excellent means of reversible long-term contraception.

The Copper T380A can be used for up to ten years without removal. The most common reasons for early removal include heavy bleeding, dysmenorrhea, or expulsion.³⁷ A multi-center study performed by the WHO followed 100 women over six years to compare the safety, effectiveness, and acceptability of the Copper T380A compared to new frameless IUD devices. Of the Copper T IUD users, 7.5% discontinued use after two years. The most common complaints were partial expulsion (4.4%) and bleeding (6.7%).³⁴ Overall, the WHO and International Planned Parenthood Federation (IPPF) have deemed the intrauterine device a safe, effective, and acceptable means of fertility regulation.^{34,36,19}

Despite the relative safety and excellent efficacy of the IUD, in the U.S. only 1% of sexually active women of reproductive age currently use an IUD.³⁷ This is in

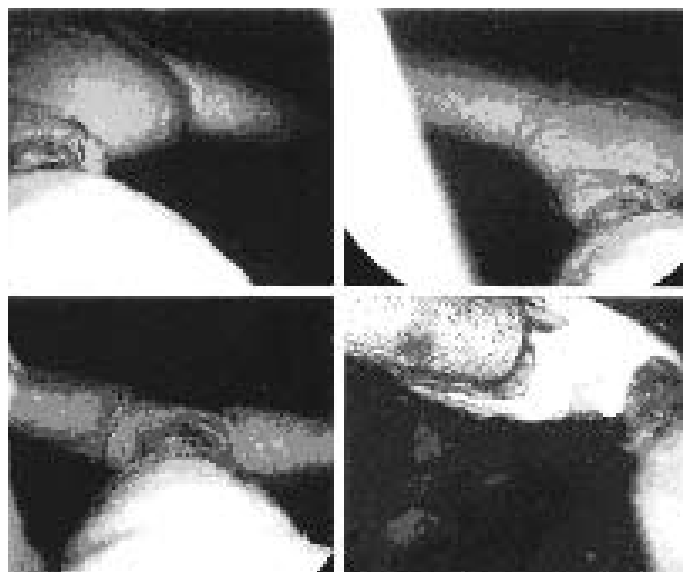


Figure 3. Upper pictures show IUD encrusted with calculi; lower left IUD partial removal of calculi with holmium laser; lower right is destruction of IUD with holmium laser.

contrast to many industrialized nations where nearly 25% of women of reproductive age currently use an IUD.³⁷ The early history of IUD use was marred by reports of complicated pregnancies, septic abortion and PID associated with the Dalkon Shield.²⁵ At that time it was thought that the Dalkon Shield's multifilament tail acted as a wick, bringing bacteria from the vagina into the endometrial cavity.

Today IUD complications remain rare. These complications include spontaneous abortion, PID, uterine perforation, dysmenorrhea, heavy bleeding, and unplanned pregnancy.^{14,34-37} The rate of spontaneous

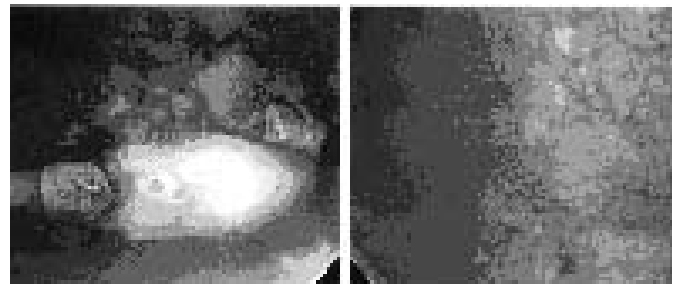


Figure 4: Upper left shows IUD post laser removal of calculi (seen in background); upper right hyperemic bladder mucosa, intact.

abortion is doubled and the risk of PID is increased 10-13% with an IUD in situ.³⁶ The rate of uterine perforation has been estimated to be between 0-1.6 per 1000 insertions.^{22,33} Risk factors for uterine perforation have been extensively studied and include the timing of insertion in relation to last delivery, abortion, lactation, the clinical experience of the inserter, congenital uterine and cervical anomalies, extreme position anomalies, and former uterine operations.^{1,8,18,22} Recent Cochrane reviews by Grimes suggest that immediate post-partum (and post-termination) IUD insertions are not associated with increased incidence of perforation.³² The key to safe and effective use of an IUD is regular self-exam and follow up to verify placement. The IPPF suggested in 1987 that all IUD wearers should have a follow-up exam within three months of insertion with annual check ups to monitor IUD placement. It may be prudent to consider all IUD users who lack regular follow up as high risk for perforation.

The pathogenesis of uterine perforation by an IUD may occur by one of two mechanisms. The first is perforation at the time of IUD insertion, especially when associated with severe abdominal pain.² The second proposed mechanism of perforation is by a gradual pressure necrosis of the uterine wall by the IUD (likely at its lead point) with eventual migration out of the uterus.² Migration and perforation may or may not

be facilitated by uterine contractions.

Two types of uterine perforation have been characterized. Partial perforation is described as perforation that may advance through all the layers of the uterus, but some part of the IUD is retained within the uterine cavity or wall. An IUD may also be described as “embedded” to varying degrees within the uterine wall.² Complete perforation occurs when all the layers of the uterine wall have been crossed, including the endometrium, myometrium, and serosa.² With complete perforation the IUD may be free in the peritoneal cavity or embedded in nearby structures or

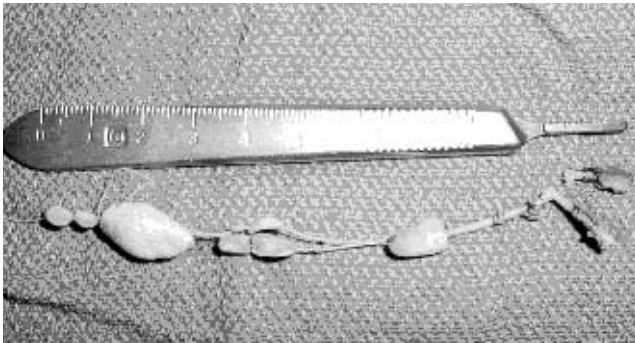

Figure 5: IUD post removal from bladder.

organs. Approximately 80% of uterine perforations are free in the peritoneal cavity.²³ However, migration into adjacent organs with subsequent severe complications has been reported. IUD migration into adjacent organs has led to bowel obstruction and perforation, peritonitis, appendicitis, vesical calculus formation, obstructive nephropathy, fistula formation, menouria, and intraperitoneal adhesions leading to infertility.^{5, 28, 29} Zakin in 1982 reported the complications of uterine perforation, including five cases of death related to uterine perforation by an IUD, generally due to overwhelming sepsis or pulmonary embolism.²

Uterine perforation is often a silent phenomenon. It may present soon after insertion or remain undiagnosed until incidentally discovered, unexpected pregnancy develops, or severe complications occur. In 2003 Harrison reported that out of 17,469 insertions of the Multiload Copper 375, there were 28 reports of uterine perforation. Eighty-six percent of the perforations were not diagnosed at the time of insertion, with some remaining undiagnosed for several years.³³ In 1992 Dietrick reported eight cases of intravesical IUD migration, with the development of urinary symptoms as early as three months to as late as five years after insertion.²⁵

The most common presentation of uterine perforation is the finding of “missing strings” on cervical exam.² It is important to evaluate all cases of missing

strings thoroughly, as the IUD may have been expelled, may still be in the uterus with the strings retracted, or may have perforated the uterus.¹⁴ Of note, strings felt on blind self-exam or even those seen at the cervical os may give a false sense of reassurance. Caspi reported a case of IUD perforation into the bladder with strings felt on cervical exam and no associated urinary complaint.²³ This may suggest that in any IUD wearer with vague abdominal pain, hematuria or recurrent cystitis, the suspicion for IUD displacement should be raised regardless of cervical exam. A quick evaluation with imaging may prevent dangerous attempts at the removal of partially embedded or perforated devices that have strings present on exam.³ Another common presentation of IUD displacement is unexpected pregnancy. It is important to note that the patient is no longer protected from pregnancy once the IUD has perforated through the uterus.

Most reported cases of IUD perforation of the bladder have included a history of pelvic pain, hematuria, and recurrent cystitis that may persist or only temporarily resolve with treatment.¹ Cases of silent urological involvement in IUD perforation have also been reported.²¹ In this case, the patient was asymptomatic in the first month after insertion, suggesting a migratory uterine perforation. The patient’s initial episode of abdominal pain quickly resolved, possibly after the IUD had perforated and migrated out of the uterus. However, given that uterine perforation is often silent, it is difficult to say when the perforation occurred. The development of urinary symptoms four years after IUD insertion may be secondary to either the entrance of the IUD into the bladder or the development of a large calculus around the IUD in the bladder, subsequently causing irritative symptoms and hematuria from contact with the bladder mucosa.

Bladder stones are relatively unusual in young women. They are more commonly associated with stasis secondary to prostatic obstruction in older men.^{18, 25} Calculus formation around a bladder IUD usually occurs. However, the degree and amount of stone formation appears to be independent of the duration of IUD exposure in the bladder.⁵ Reports of calculus formation have been noted as early as six months after bladder perforation.¹ Killholma reported a case of partial IUD perforation of the bladder discovered three years post insertion with no significant calculus noted after extraction.²⁷ Our case is consistent with previous case reports suggesting that any woman with recurrent cystitis, pelvic pain, and hematuria be evaluated for a bladder foreign body acting as a nidus for stone formation.^{18, 25} Furthermore, in any woman presenting to the ED with the above symptoms and a history of IUD use, uterine perforation of the IUD and involvement of the bladder should be suspected until proven otherwise.^{5, 18, 25}

In the event of missing strings, abdominal pain, urinary symptoms, or other signs suspicious of IUD displacement, initial evaluation begins with verifying IUD presence.² Initial management may include AP and lateral abdominal plain films to verify IUD placement in the pelvis. Detecting an IUD on an AP abdominal film depends on the radiopacity of the IUD. Some IUDs contain elemental metal in their matrix while others may have trace amounts of barium sulfate added to their plastic frame.¹ Of note, the Dalkon Shield is typically not well seen on radiography. Formation of a calculus around an IUD in the bladder may aid in both visualization and position of the IUD.¹ However, if a calculus has not sufficiently formed on the IUD, an AP view of the abdomen with an IUD noted in the pelvis may be falsely reassuring. On a lateral film the IUD may then be shown to be sufficiently anterior to suggest bladder involvement.¹ It is important to remember that an anteriorly displaced IUD may be located in the anterior cul de sac, beneath the vesico-uterine reflection, in the space of Retzius, or in the bladder. Zakin reported two of eight bladder perforations erroneously called intrauterine because of reliance on the AP film alone, even with a history of urinary symptoms and missing strings on exam.¹ A simple uterine round placed when obtaining the AP and lateral radiographs may also help determine the relative position of the IUD.¹

The next step in assessing a displaced IUD is often the bedside ultrasound exam. An IUD can be distinguished from the endometrium by higher amplitude echoes, acoustic shadowing, and entrance-exit reflections.³ Rosenblatt suggested that it is difficult to differentiate the IUD from the endometrial cavity, and therefore one may not be able to accurately depict the relationship of the IUD to the endometrial wall. This may make deep embedding and partial perforation difficult to rule out by ultrasound. In the case of complete perforation, ultrasound may be limited in detection unless the device is still near the uterus, as bowel gas may obscure the view.³ Rosenblatt and Zakin suggested that hystero-graphy was the most accurate method of evaluation, especially in regards to detecting deep embedment and partial perforation. Compared to ultrasound, hystero-graphy was more likely to prevent hazardous attempts at vaginal removal of partially intramural IUDs.³ Nonetheless, ultrasound is a widely accessible, quick, and noninvasive means of evaluating IUD placement.⁷ Ultrasound can evaluate IUD position and adherence to local anatomic structures. Some suggest that regular pelvic ultrasound exams may be appropriate management for all IUD wearers, regardless of symptoms or cervical exam.²⁰ Regular evaluations may prevent unexpected pregnancy and the serious complications of perforation.^{14, 20}

If the IUD is not well visualized in the bladder

by ultrasound, Zakin suggests opacification of the bladder with intravenous (IV) pyelography or retrograde cystography. IV pyelography may also help determine the extent of urinary tract involvement in the IUD perforation, including ureteral damage.¹ Other imaging methods include computed tomography, pneumography and laparoscopy.² Richardson suggested that CT evaluation of IUD location involved less radiation and was easier, faster, and just as definitive in comparison to hystosalpingography.³⁸ Once bladder involvement in IUD perforation is suspected, cystoscopy may help in planning the removal of the IUD and assessing mucosal wall damage.¹ In this case the CT showed the IUD protruding from the uterus into the bladder. However, on cystoscopic and manual exam no bladder or vaginal wall defects were noted.

The International Planned Parenthood Federation has recommended that all perforated IUDs be immediately removed given the rare but potentially catastrophic consequences.¹⁹ This topic has been debated; however, it is generally agreed that any IUD causing urinary symptoms should be removed promptly.²⁷ An IUD perforating the bladder may be removed by suprapubic cystotomy, vaginal cystotomy, or cystoscopy. In this case the IUD and vesical calculi were successfully removed by cystoscopy with lithotripsy.

CONCLUSION

Uterine perforation of an IUD may occur soon after insertion or gradually with late development of symptoms.¹ In some cases uterine perforation may be completely silent and not present until years after insertion or with the advent of an unexpected pregnancy. Rarely, catastrophic complications can occur with IUD use. In all known IUD wearers a history of missing strings on exam or pelvic pain should be considered IUD perforation until proven otherwise. Intravesical migration of an IUD should be considered when a patient presents with persistent or recurrent cystitis with a history of IUD placement.^{2, 4, 5, 18} Furthermore, with a questionable or no known history of IUD use, recurrent cystitis, hematuria and pelvic pain in a female patient may suggest the presence of a bladder foreign body.^{2, 4, 5, 18} In this case, the detection of a foreign body on exam with a history of previous IUD use was highly suggestive of IUD perforation. The history of recurrent cystitis, hematuria and a foreign body extruding from the urethral meatus suggested complete or partial intravesical migration of the IUD. The initial evaluation of a suspected perforated or expelled IUD should include abdominal AP and lateral views.^{1, 2} Plain films are a quick and effective means of discerning if the IUD is still present, and may suggest migration when both AP and lateral views are obtained.² Given that it is readily

accessible and noninvasive, abdominal or transvaginal ultrasound is useful in localizing a perforated IUD noted on plain film.^{2, 3, 7, 23, 26} Following the detection of a bladder foreign body, cystoscopy may help in further evaluating the means of extraction as well as assessing bladder wall damage.^{1, 2, 5} This case is an unusual presentation of recurrent cystitis secondary to IUD perforation and bladder calculus formation.

References

- Zakin, David. Perforation of the Bladder by the Intrauterine Device. *Obstetrical Gynecology Surv* 1984;39(2):59-66.
- Zakin, D. Stern, W.Z. and Rosenblatt, R: Complete and partial uterine perforation and embedding following insertion of intrauterine devices. II Diagnostic methods, prevention and management. *Obstetrical Gynecology Surv* 1981;36(8):401-17.
- Rosenblatt, R. Zakin, D., Stern, W.Z., Kutcher, R.,: Uterine perforation and embedding by intrauterine device: Evaluation by *US and Hystero-graphy. Radiology* 1985;157:765-770.
- Tuncay, Y.A. Tuncay E., Guzin, K. Ozurk D., Omurcan C., Yucel, N. Transuterine migration as a complication of intrauterine contraceptive devices: six case reports. *The Euro J of Contraception and Reprod Health Care* 2004;9:194-200.
- Rafique, M. Rauf, N. Khan, A., Haque, T.U. An unusual cause of vesical stone: a migrant intrauterine device. *The Eur J of Contraception and Reprod. Health Care* 2003; 8:170-172.
- Thomalla JV. Perforation of urinary bladder by intrauterine device. *Urology* 1986;27(3):260-4.
- McNamara M, Kennan N, Buckley AR. Copper-7 perforation of the uterus and urinary bladder with calculus formation-sonographic demonstration. *Br J Radiology* 1985; 58(690):558-9.
- Chi IC, Kelly E. Is lactation a risk factor of IUD and sterilization related uterine perforation? A hypothesis. *Int J Gynaecol Obstet* 1984;22(4): 315-7.
- Neutz E. Silber A, Merendino VJ Dalkon shield perforation of the uterus and urinary bladder with calculus formation: case report. *Am J Obstet Gynecol* 1978;130(7):848-9.
- Avello EJ, Torga LG, Villanueva JL, Gonzalea Bernaldo De Quiros A Perforation of the uterus and migration to the bladder by a intrauterine device. A case report. *Acta Ginecol* 1977;30(2):79-86.
- Iglesias J, Corbalan G. Galan G, Gayan P. Perforation of the uterus and the urinary bladder with the Lippes loop. *Rev Chil Obstet Ginecol* 1977;42(3):149-50.
- Saronwala KC, Singh, Dass H. Lippes Loop perforation of the uterus and urinary bladder with stone formation. *Obstet. Gynecol* 1974;44(3):424-7.
- Demirci D, Ekmekcioglu O, Demirtas a, Gulmez I. Big Bladder stones around an intravesical migrated intrauterine device. *Int Urol Nephrol* 2003;35(4):495-6.
- Eskandar OS, Eckford SD. Intravesical migration of a GyneFlx intrauterine device. *J Fam Plann Reprod Health Care* 2003;29(4):237-8.
- Nwofor AM, Ikechebelu JO Uterovesical fistula and bladder stones following bladder penetration by a perforating intrauterine contraceptive device. *J Obstet Gynaecol* 2003;23(6):683-4.
- Honarbaksh A, Rastegar M, Hervai I, Khoury E, Unrecognized perforation of the uterus into bladder by an IUD. *J Obstet Gynaecol* 2003;(23):444-5.
- Dabbas, M, Maaita M. Ureteric Claculus around an intrauterine contraceptive device. *J Obstet Gynaecol* 2002;22(1):101-2.
- Atakan H. Kaplan M, Ertrk E. Intravesical migration of intrauterine device resulting in stone formation. *Urology* 2002; 60(5):911.
- Singh MM. IUDs and transmigration—putting an old concern to rest. *International Planned Parenthood Federation Med Bull* 1995;29(1):2-3.
- Coronel Sanchez B. Sanchez Sanchis MJ, Carrasvosa Lloret V, Beltran Armada JR, Rodrigo Guanter V, Tarin Planes M, San Juan de Laorden C. Migration of an intrauterine contraceptive device into the urinary bladder: report of one case. *Arch Esp Urol* 2004;57(1):75-8.
- Sirikci A, Sarica K, Bayram M. Ureteral displacement due to a migrated intrauterine contraceptive device. *Urol Int* 2000;65(3):179-80.
- Andersson K, Ryde-Blomqvist E, Lindell K, Odind V, Misom I. Perforations with intrauterine devices. *Report from a Swedish Survey. Contraception.* 1998; 57(4):251-5.
- Caspi B, Rabinerson D, Appelman Z, Kaplan B. Penetration of the bladder by a perforating intrauterine contraceptive device: a sonographic diagnosis. *Ultrasound Obstet Gynecol* 1996;7(6):458-60.
- Broso PR, Buffetti G. The IUD and uterine perforation. *Minerva Ginecol* 1994;46(9):505-9.
- Dietrick DD, Issa MM, Kabalin JN, Basset JB. Intravesical migration of intrauterine device. *J Urol* 1992;147(1):132-4.
- Sepulveda WH, Ciuffardi I, Olivari A, Gallegos O. Sonographic diagnosis of bladder perforation by an intrauterine device. A case report. *J Reprod Med* 1993;38(11):911-3.
- Kiillholma P, Makinene J, Vuori J. Bladder perforation: uncommon complications with a misplaced IUD. *Contraception* 1989; 5(1):47-49.
- Timonen H, Kurpa K. IUD perforation leading to obstructive nephropathy necessitating nephrectomy: a rare complication. *Adv Contracept.* 1987;3(1):71-5.
- Schwartzwald D. Mooppan UM, Tancer ML, Gomez-Leon G, Kim H. Vesicouterine fistula with menouria: a complication from an intrauterine contraceptive device. *J Urol* 1986;136(5):1066-7.
- Boaji II, Saridogan E, Lammers G, Fieldman N, Djahanbakhch O. Perforation of the uterus and colon by copper-T intrauterine contraceptive device. *Int J of Gynecol and Obstet* 1995;48:231-232.
- Grimes D, Schulz K, van Vliet H, Stanwood N. Immediate post partum insertion of intrauterine devices. *The Cochrane Database of Systematic Reviews* 2003, issue I. Art. No:CD003036. DOI: 10.1002/14651858.CD003036.
- Grimes D, Schulz K, Stanwood N. Immediate postabortal insertion of intrauterine devices. *The Cochrane Database of Systematic Reviews* 2004, Issue 4. Art. No.:CD001777. DOI: 10.1002/14651858.CD001777.pub2.
- Harrison-Woolrych M, Ashton J, Coulter D. Uterine perforation on intrauterine device insertion: is the incidence higher than previously reported? *Contraception* 2003;67(1): 53-6.

34. Li HQ, Feng ZC, Wang YB, Han YL, Van Kets H, Wildemeersch D. Performance of the frameless IUD (Flexigard prototype inserter) and the T Cu380A after six years as part of a WHO multicenter randomized comparative clinical trial in parous women. *Adv in Contraception* 1999;15:201-209.
35. Curtis KM, Chrisman CE, Peterson HB. Contraception for Women in Selected Circumstances. *Obstet Gynecol* 2002;99:1100-12.
36. Skegg D. Safety and efficacy of fertility-regulating methods: a decade of research. *Bulletin of the World Health Organization*. 1999;77(9):713.
37. Sulak P. Intrauterine Device Practice Guidelines: patient Types. *Contraception* 1998;58:55-58.
38. Richardson ML, Kinard RE, Watters DH. Location of intrauterine devices: evaluation by computed tomography. *Radiology* 1982;142(3):690.