

UCSF

UC San Francisco Previously Published Works

Title

Advances in multidisciplinary therapy for meningiomas.

Permalink

<https://escholarship.org/uc/item/1tv2k1wg>

Journal

Neuro-oncology, 21(Suppl 1)

ISSN

1522-8517

Authors

Brastianos, Priscilla K
Galani, Evanthia
Butowski, Nicholas
et al.

Publication Date

2019

DOI

10.1093/neuonc/noy136

Peer reviewed

Advances in multidisciplinary therapy for meningiomas

Priscilla K. Brastianos,* Evanthia Galanis,* Nicholas Butowski, Jason W. Chan, Ian F. Dunn, Roland Goldbrunner, Christel Herold-Mende, Franziska M. Ippen, Christian Mawrin, Michael W. McDermott, Andrew Sloan, James Snyder, Ghazaleh Tabatabai, Marcos Tatagiba, Joerg C. Tonn, Patrick Y. Wen, Kenneth Aldape, Farshad Nassiri, Gelareh Zadeh, Michael D. Jenkinson,* David R. Raleigh,* and the International Consortium on Meningiomas*

Divisions of Hematology/Oncology & Neuro-Oncology, Departments of Medicine & Neurology, Massachusetts General Hospital, Boston, Massachusetts, USA (P.K.B., F.M.I.); Division of Medical Oncology, Mayo Clinic, Rochester, Minnesota, USA (E.G.); Department of Neurological Surgery, University of California, San Francisco, California, USA (N.B.); Department of Radiation Oncology, University of California, San Francisco, California, USA (J.W.C., D.R.R.); Center for Skull Base and Pituitary Surgery, Department of Neurosurgery, Brigham and Women's Hospital, Harvard Medical School, Boston, Massachusetts, USA (I.F.D.); Department of General Neurosurgery, University Hospital Cologne, Cologne, Germany (R.G.); Division of Experimental Neurosurgery, Heidelberg University Hospital, Germany (C.H.M.); Institute of Neuropathology, Otto-von-Guericke University, Magdeburg, Germany (C.M.); Department of Neurological Surgery, University of California, San Francisco, California, USA (M.W.M., D.R.R.); Department of Neurological Surgery, University Hospital–Case Medical Center, Cleveland, Ohio, USA (A.S.); Department of Neurosurgery, Henry Ford Health System, Detroit, Michigan, USA (J.S.); Interdisciplinary Division of Neuro-Oncology, Hertie Institute for Clinical Brain Research & Centre for CNS Tumors, Comprehensive Cancer Center Tübingen–Stuttgart, University Hospital Tübingen, Eberhard Karls University, Tübingen, Germany (G.T.); Department of Neurosurgery, University Hospital Tübingen, Tübingen, Germany (M.T.); Department of Neurosurgery, Ludwig-Maximilians-University, Munich, Germany (J.C.T.); Center for Neuro-Oncology, Dana-Farber Cancer Institute, Boston, Massachusetts, USA (P.Y.W.); Laboratory of Pathology, Center for Cancer Research, National Cancer Institute, Bethesda, Maryland, USA (K.A.); Division of Neurosurgery, University Health Network, University of Toronto, Ontario, Canada (F.N., G.Z.); MacFeeters-Hamilton Center for Neuro-Oncology, Princess Margaret Cancer Center, Toronto, Ontario, Canada (F.N., K.A., G.Z.); Department of Neurosurgery & Institute of Translational Medicine, The Walton Centre NHS Foundation Trust & University of Liverpool, Lower Lane, Liverpool, Merseyside, UK (M.D.J.)

Corresponding Authors: Priscilla K Brastianos, Divisions of Hematology/Oncology & Neuro-Oncology, Departments of Medicine & Neurology, Massachusetts General Hospital, Boston, MA, USA, pbrastianos@mgh.harvard.edu, Evanthia Galanis, Division of Medical Oncology, Mayo Clinic, Rochester, MN, USA, Galanis.evanthia@mayo.edu, Michael D Jenkinson, Department of Neurosurgery, The Walton Centre NHS Foundation Trust, Lower Lane, Liverpool, Merseyside, UK, Michael.jenkinson@liverpool.ac.uk, David R Raleigh, Department of Radiation Oncology, University of California, San Francisco, CA, USA, David.raleigh@ucsf.edu

*Denotes equal contribution.

*See ICOM authorship statement at end of article.

Abstract

Surgery has long been established as the first-line treatment for the majority of symptomatic and enlarging meningiomas, and evidence for its success is derived from retrospective case series. Despite surgical resection, a subset of meningiomas display aggressive behavior with early recurrences that are difficult to treat. The decision to radically resect meningiomas and involved structures is balanced against the risk for neurological injury in patients. Radiation therapy has largely been used as a complementary and safe therapeutic strategy in meningiomas with evidence primarily stemming from retrospective, single-institution reports. Two of the first cooperative group studies (RTOG 0539 and EORTC 22042) evaluating the outcomes of adjuvant radiation therapy in higher-risk meningiomas have shown promising preliminary results. Historically, systemic therapy has resulted in disappointing results in meningiomas. However, several clinical trials are under way evaluating the efficacy of chemotherapies, such as trabectedin, and novel molecular agents targeting Smoothed, AKT1, and focal adhesion kinase in patients with recurrent meningiomas.

Keywords

clinical trial | meningioma | radiation | surgery | targeted therapy

Meningiomas are primarily a neurosurgical disease and while the majority of tumors are histologically classified as “benign,” the clinical course and impact on patients and caregivers can be far from benign. First-line treatments include surgery, followed by (in selected cases) fractionated radiation therapy (RT) or stereotactic radiosurgery (SRS). The indications for treatment should be individualized and take into consideration factors such as age, comorbidity, life expectancy, patient preference, histologic grade, molecular factors, tumor location, and extent of resection.

We increasingly recognize that like other recognized neoplastic entities, meningioma comprises a spectrum of disease with marked variation in tumor biology and clinical outcomes. A patient with a small, heavily calcified, asymptomatic incidental meningioma is unlikely to require any treatment and indeed may not need long-term monitoring.^{1,2} In contrast, a patient with a large symptomatic meningioma causing epilepsy or neurological deficit requires surgery and, depending on the histopathology grade or extent of resection, may also need adjuvant RT or SRS. While there are no approved medical therapies for meningioma, systemic therapy is largely used in higher-grade tumors as a last resort once all surgery and RT options have been exhausted, but typically results in only modest efficacy.^{3,4}

While the majority of meningiomas have excellent long-term control rates, due to their slow growth, clinical series with follow-up in the range of 5–10 years carry the risk of underreporting late meningioma recurrences that can occur decades after primary treatment.⁵ For patients with clinically aggressive meningiomas with early and multiple recurrences, multimodality treatment is required, combining surgery and radiation therapy, and in select cases chemotherapy or experimental clinical trials for treatment-refractory tumors. Although support for these approaches is rooted in historical series of cases, several advancements that deserve attention have been made in each therapeutic modality. This review will address advances in each of these modalities as well as the evidence supporting their use, and will provide general recommendations for advancing the treatment of patients with meningiomas.

Surgery for the Treatment of Intracranial Meningioma

Surgery is the primary treatment for the majority of patients with symptomatic and enlarging meningiomas.² Surgery not only removes the tumor to relieve mass effect, but also can rapidly improve neurological function and control seizures.^{6,7} The surgical gold standard for meningioma is complete resection of tumor and any involved dura or bone, while minimizing neurological morbidity in order to achieve long-term local control or cure. Moreover, surgery also provides tissue for histological diagnosis of meningioma type and grade⁸ and for translational research.^{9–14} While there is no standardized method for surgical sampling of meningioma, it is incumbent on surgeons to ensure that adequate tissue is provided and any evidence of macroscopic brain invasion is reported to the pathologist to ensure accurate grading, especially in the light of the revised version of the World Health Organization (WHO) grading system, where

brain invasion alone is sufficient for diagnosis of WHO grade II.^{8,15} Moreover, adequate tissue will allow for the possibility of future molecular analysis, if needed.

Evolution of Surgery for Meningioma

Evidence for the effectiveness of surgery as monotherapy for meningioma is largely derived from single institutional case series. Reports of neurosurgical outcomes were historically limited to tumor recurrence, complication, and mortality rates. Recognizing that so called benign meningiomas regrew despite apparently satisfactory surgery, in 1957 Simpson described a classification system to define the risk of recurrence following surgery alone based on the surgeon’s intraoperative assessment of the extent of resection (Table 1).¹⁶ Recognizing that extent of resection was important to reduce the risk of recurrence, the neurosurgery community strove for new approaches to achieve complete resection. These included new technologies such as the operating microscope,¹⁷ micro-instruments, and cavitation ultrasonic aspirators, and new surgical techniques such as approaches to the skull base,¹⁸ venous sinus reconstruction,¹⁹ and in situ cranioplasty for skull vault meningiomas.²⁰ These advances heralded an era of radical surgical resection, sometimes at the expense of neurological function. However, with subsequent improvements in neurosurgical care and recognition that quality of life is an important patient outcome, neurosurgeons currently aim for maximum safe resection with low morbidity and preservation of neurological function.^{21,22}

Technical Considerations in Meningioma Surgery

Meningioma surgery can be technically challenging, and meticulous presurgical planning with careful attention to neurovascular anatomy is essential to maximize success and minimize morbidity. Attention to venous anatomy will avoid inadvertent injury to cortical veins and intradiploic venous drainage that can lead to postoperative venous infarction with devastating consequences for the patient. Reconstruction of major venous sinuses remains a controversial topic, with up to 93% gross total resection (GTR) rate, a 3% risk of death,²³ and a 21% risk of major morbidity.²⁴ An alternative strategy is to leave meningioma invading the sinus that can be monitored or treated with adjuvant RT or SRS,²⁵ but it is preferable to attempt to remove the tumor completely.

Image guidance is used routinely in cranial neurosurgery to position the craniotomy and allows image fusion of multiple datasets that provide information about critical neurovascular structures or transosseous growth. Intraoperative MRI (iMRI) and CT (iCT) can be used to update neuronavigation and identify residual tumor,^{26–28} particularly for hyperostotic skull base meningiomas. DOTATATE PET can discriminate between meningioma and normal tissues with greater sensitivity than MRI,²⁹ and may be particularly useful for meningioma with intraosseous involvement.³⁰ DOTATATE PET imaging may also be used as a predictor of tumor growth rate (discussed further in the companion imaging article).³¹

Intraoperative imaging can also be used for emerging approaches such as adaptive hybrid surgery, whereby

Table 1 Simpson grades of resection and corresponding EORTC/RTOG definitions of extent of resection^{16,39}

WHO Grade	Definition	Extent of Resection
I	Gross total resection of tumor, dural attachment, and abnormal bone	GTR
II	Gross total resection of tumor, coagulation of dural attachment	GTR
III	Gross total resection of tumor without resection or coagulation of dural attachments, or extradural extensions (eg, invaded or hyperostotic bone)	GTR
IV	Partial resection of tumor	STR
V	Biopsy of tumor	STR

the surgeon plans to leave a small (deemed unresectable) residual that can be treated with postoperative SRS.³² In addition, intraoperative neurophysiological monitoring (eg, facial nerve and brainstem evoked potentials) may help minimize postoperative neurological deficit in critically located lesions. In the pursuit of complete resection, studies of surgical adjuncts such as 5-aminolevulinic acid (5-ALA) fluorescence have shown heterogeneous fluorescence within the meningioma as well as nonspecific fluorescence in adjacent brain,³³ which suggests a limited role, although a recent systematic review found that 5-ALA may be more useful in higher-grade meningioma.³¹ Fluorescence-guided surgery remains a nonstandard adjunct that needs further prospective evaluation. Minimally invasive and endoscopic endonasal techniques are being used for resection of anterior skull base meningiomas despite the lack of a direct comparison to established open transcranial approaches in a prospective trial. A recent systematic review and meta-analysis reported that endoscopic techniques were not superior to open craniotomy and achieved lower rates of GTR and higher rates of cerebrospinal fluid leak and vascular injury,³⁴ highlighting the fact that new surgical techniques should be subject to rigorous testing before routine adoption into clinical practice.³⁵

In patients with recurrent meningiomas, the surgical challenges are compounded by scar tissue, and the underlying brain is often more friable and susceptible to injury. Moreover, practical issues also include the ability of the scalp to withstand repetitive surgery to heal appropriately. The indications for further surgery include symptomatic meningioma growth and reduction of the tumor volume to leave a smaller target for postoperative radiation. Minimally invasive surgical options such as laser interstitial thermal therapy—where an image-guided fiberoptic laser is used to produce irreversible thermal damage to a defined focus that can be monitored in real time due to advancements of MRI thermometry—have been trialed in one small case series of recurrent meningiomas.³⁶ However, the small number of patients treated with this modality precludes large conclusions regarding its efficacy.³⁶

Extent of Resection and Risk of Recurrence

The Simpson classification¹⁶ predates CT and MRI as modalities to assess extent of resection. Despite this, the Simpson grade remains the only validated surgical method for

estimating risk of recurrence and is still relevant in modern neurosurgery.^{37,38} A recent systematic review and meta-analysis reported that Simpson grade still predicts risk of recurrence even when stratified by WHO grade.³⁸ However, the lack of standardized reporting of recurrence by Simpson grade and by tumor location has resulted in grouping of resection categories for the purpose of clinical trials (Table 1).³⁹

Neurosurgical Meningioma Trials

There are no randomized controlled trials comparing surgery with other therapies for meningiomas. Historically, this problem has been compounded by the potential lack of equipoise in head-to-head comparisons with other local treatments. Small meningiomas that could be treated with resection or SRS may be an exception to the aforementioned problem with equipoise, but such a trial would be difficult to conduct for several reasons. First, patients with incidental, asymptomatic meningioma do not need active treatment and can be safely monitored. Secondly, both symptomatic patients and their physicians may have strong preferences for one technique and would not want to risk randomization to the alternative. Indeed, concern for lack of clinical equipoise and surgeon bias against RT were contributory factors in the early closure of the European Organisation for Research and Treatment of Cancer (EORTC) 26021-22021 phase III trial, which randomized patients following biopsy or subtotal resection (STR) to observation versus fractionated RT or SRS.

Radiation for the Treatment of Meningiomas

Radiation therapy is the only nonsurgical standard of care treatment option for meningiomas.² However, until recently the evidence supporting RT for meningioma was largely limited to single-institution, retrospective data. Indeed, radiotherapeutic options for meningioma are diverse, and there are no randomized trials comparing different RT modalities. As a result, RT technique is individualized and depends on meningioma size, proximity to critical structures, and any prior radiation to the same site. Despite these caveats, excellent local control has been observed following various forms of RT for meningioma, including fractionated external beam radiation therapy (EBRT), SRS, and brachytherapy.

Evolution of the Role of Radiation Therapy for Meningioma

In the 1950s, Simpson initially proposed that EBRT could be considered after an STR.¹⁶ However, by the 1960s, several investigators reported infrequent tumor shrinkage following RT, and in conjunction with concerns for radiation-induced meningioma and late toxicity, it was unclear if RT had any role for patients with meningioma.⁴⁰ Then in the 1970s and 1980s, retrospective series with long-term follow-up emerged and concluded that EBRT improved local control for incompletely resected and recurrent meningiomas.^{41–43} Furthermore, in the 1990s and early 2000s, several reports found similarly efficacious tumor control with primary EBRT for upfront treatment.^{44–47}

Evolution of Radiation Therapy Technologies

Three-dimensional conformal radiation therapy

In the early 1990s, 3-dimensional conformal radiation therapy (3D-CRT) became widely adopted as a result of important technical advancements in CT and multileaf collimators. In 3D-CRT, the radiation field of each incident beam is shaped to the projection of the target volume in the eye view of the beam. The fluence distribution in the plane perpendicular to each incident beam is homogeneous so it is generally not possible to “dose-paint” hot or cold spots into the target. Three-dimensional CRT remains a standard treatment option for meningiomas, although newer approaches may be better suited for irregular targets and/or those that are adjacent to critical structures. These newer, highly precise methods to deliver conventionally fractionated radiation are also aptly referred to as stereotactic radiation therapy in the literature.

Intensity-modulated radiation therapy and volumetric modulated arc therapy

Similar to 3D-CRT, intensity-modulated radiation therapy (IMRT) refers to EBRT from discrete beam directions. The treatment beam is off as the gantry moves from one angle to the next, which is commonly referred to as “step-and-shoot.” Multileaf collimators allow each beam to be discretized into beamlets and for the fluence distribution in the plane perpendicular to each incident beam to be modulated. The goal during optimization is to find the fluence maps of all incidence beams that provide the desired dose distribution in the patient.

Volumetric modulated arc therapy (VMAT) is an extension of IMRT where the beam is continuously on while the gantry rotates around the patient. By treating over more gantry angles in an arc sector rather than being limited to a few discrete beam angles, VMAT in principle can provide more conformal dose distributions than IMRT and treatment times can be shortened.

Particle therapy

There has been comparatively less experience with particle therapies than photon-based therapies, such as

3D-CRT, IMRT, and VMAT, due to widespread availability of the latter. However, the number of treatment centers offering proton or carbon ion therapies worldwide has increased significantly in recent years. In principle, irradiating meningiomas with heavy particles rather than photons can potentially reduce late toxicities in long-term survivors by lowering scatter doses to adjacent normal tissues.⁴⁸ In practice, particle therapy remains investigational and is the subject of several ongoing prospective trials. For instance, UPCC 24309 (NCT01117844) is a feasibility/phase II study of proton radiation for WHO grades I–III meningiomas and hemangiopericytomas. Furthermore, a combined phase I/II study at Massachusetts General Hospital and MD Anderson Cancer Center (NCT02693990) is studying dose escalation with proton therapy for atypical meningiomas following STR and anaplastic meningiomas following any extent of resection. With recent advancements in proton therapy intensity modulation, it is possible that heavy particles may improve outcomes, such as for meningiomas near the pituitary gland.

Radiation Target Delineation and Dose Prescriptions

Meningiomas are generally homogeneously enhancing, extra-axial tumors with hypervascular trailing enhancements from the margins called dural tails. Dural tails are typically composed of benign, hypervascular tissue and unless they contain suspicious nodular enhancement, they do not need to be included in the radiation target. WHO grade I and radiographically defined (presumed grade I) meningiomas are commonly treated to a total dose of 50–54 Gy with a 0–5 mm clinical target volume (CTV) margin. Grade I meningiomas are not thought to be infiltrative, and surrounding hyperintensity is more likely to represent edema, which should not be included in the gross tumor volume (GTV). In contrast, WHO grade II (atypical) and grade III (anaplastic) meningiomas are commonly treated to 59.4–60 Gy with 10–20 mm GTV to CTV anisotropic expansion that respects anatomic barriers to tumor growth, such as the skull. However, hyperostosis or direct bone invasion should be included in the GTV. An additional margin of 3–5 mm is generally used to create a planning target volume from the CTV for all meningiomas, depending on image-guidance method and reproducibility of the treatment setup.

Radiation Therapy Outcomes

Several retrospective studies have reported excellent outcomes of EBRT as adjuvant therapy after STR of WHO grade I or radiographically defined meningiomas. Furthermore, favorable outcomes of EBRT as definitive therapy have been reported for patients with meningiomas that are not amenable to surgery or are diagnosed in patients who are medically inoperable or elect radiation over surgery. Reported outcomes can vary depending on the treatment era, tumor characteristics, and clinical scenario but overall are supportive of current treatment paradigms with EBRT. In an excellent review, these studies are summarized by Rogers et al.⁴

Radiation therapy following subtotal resection

The rate of meningioma recurrence following STR is higher than with a GTR. Following a GTR, defined as Simpson grades I–III, 5-, 10-, and 15-year recurrence rates are 7%, 20%, and 32%, respectively.⁴³ In contrast, the rate of local recurrence with STR at 5 years is 47%.⁴¹ Several retrospective studies have found high rates of local control in patients treated with EBRT following STR. In that regard, 5- and 10-year rates of progression of less than 10% have been observed and local control rates have trended upward since the 1980s, suggesting that improvements in patient stratification, and perhaps EBRT techniques, have improved outcomes.^{49–51}

Primary external beam radiation therapy

Retrospective studies of primary EBRT for meningioma consist of patients and tumors that are inherently different than those selected for surgical monotherapy or observation. For instance, primary EBRT is useful for certain tumor locations where GTR is not possible without causing significant morbidity to the patient, such as optic nerve sheath meningioma. For example, in a series of 64 patients with optic nerve sheath meningiomas, 14 (22%) were treated with EBRT alone (40–55 Gy) with no failures and 86% of these patients had improved or stable vision at a median follow-up of 8.3 years.⁵² In another series, of 101 patients with presumed WHO grade I skull base meningiomas treated with EBRT alone (65%) or after STR (35%), 5-year local control was 95% for all patients at a median follow-up of 5 years.⁵³

External beam radiation therapy following resection of atypical or anaplastic meningioma

High-grade tumors constitute less than one quarter of meningiomas, and thus their natural histories and optimal treatment paradigms are less clear. Some studies found similar outcomes between atypical and anaplastic meningiomas,^{54,55} while others have found significantly higher rates of failure in the latter.^{56,57} The efficacy of adjuvant EBRT following the resection of high-grade meningiomas is the subject of 2 prospective studies that have closed to accrual: Radiation Therapy Oncology Group (RTOG) 0539 (NCT00895622) and EORTC 22042 (NCT00626730). The initial clinical outcomes for the intermediate-risk group from RTOG 0539 were recently reported, consisting of 48 evaluable patients with newly diagnosed, completely resected WHO grade II tumors or recurrent WHO grade I tumors irrespective of extent of resection. With a median follow-up time of 3.7 years, 3-year progression-free survival (PFS) was 94% following 3D-CRT or IMRT, 54 Gy in 30 fractions.⁵⁸ Two additional phase III randomized controlled trials remain open for accrual: Neuro-Oncology Research Group (NRG) BN-003 (<http://clinicaltrials.gov/ct2/show/NCT03180268>) and the Radiation versus Observation following surgical resection of Atypical Meningioma (ROAM)/EORTC 1308 trial (<http://roam-trial.org.uk>; ISRCTN71502099), both of which compare surgery plus adjuvant RT with surgery alone in grade II meningioma status post GTR.⁵⁹ As discussed below, molecular features

have largely yet to be incorporated into clinical trials of surgery or radiation for meningiomas. Thus, secondary subset analyses may be required to identify subgroups of patients who derive the most benefit for adjuvant interventions. With respect to the inclusion criteria of NRG BN-003 and ROAM/EORTC 1308, an MIB-1 labeling index >7% identifies a subpopulation of grade II meningiomas at high risk for local recurrence after GTR, and therefore may benefit most from adjuvant radiation.^{60,61}

Stereotactic Radiosurgery

SRS refers to higher dose per fraction RT that is delivered with extremely precise 3D localization systems, typically within a single session. Although variable among centers, single fraction SRS is generally considered feasible for tumors less than 3–4 cm in diameter with at least 2 mm separation from critical normal structures such as the optic nerves and chiasm to allow for sharp dose gradients (Fig. 2). Similar to studies with primary EBRT, retrospective series with Gamma Knife, robotic, and linear accelerator-based SRS have generally been found to prevent the growth of grade I meningiomas.^{62–66} Even though most meningiomas do not shrink significantly after treatment, symptomatic improvement can occur after both EBRT and SRS.

Fractionated Stereotactic Radiosurgery

Meningiomas can be challenging targets for radiosurgery because some tumors, particularly those involving the skull base, have irregular contours and indistinct margins. Even with sufficient distance from critical normal structures, it may not be feasible to complete a single-session treatment in a reasonable amount of time. Ablative doses of RT in 2 to 5 treatments have several synonyms in the literature: fractionated SRS, stereotactic body RT, and stereotactic ablative RT.

Stereotactic Radiosurgery and Fractionated Stereotactic Radiosurgery Outcomes

The largest published series of grade I and radiographically defined meningiomas treated with Gamma Knife radiosurgery reported outcomes of 5300 lesions with median tumor volume of 4.8 cm³ in 4656 patients who were treated at 15 participating centers to a median marginal dose of 14 Gy.⁶⁷ With a median imaging follow-up of 5.3 years, the 5- and 10-year PFS rates were 95% and 89%, respectively. Similarly, in a single institution series with median tumor volume of 2.5 cm³ and median prescription dose of 15 Gy, 5-year PFS rates of presumed benign (97%) and pathologically confirmed WHO grade I (87%) meningiomas were excellent following Gamma Knife SRS but were suboptimal for WHO grades II (56%) and III (47%) tumors.⁶⁸ Furthermore, larger tumor volume (≥ 10 cm³) was associated with significantly worse PFS. There have been fewer reports describing the outcomes for fractionated SRS for tumors that are not amenable to SRS. In a series of 199 patients with benign or presumed benign meningiomas, 63

(32%) were not deemed to be candidates for single-session SRS due to the presence of lesions larger than 13.5 cm³ and/or location within 3 mm of the optic pathways.⁶⁹ The median tumor volume was 7.5 cm³ and prescription doses ranging 11–25 Gy were delivered between 2 and 5 daily fractions. With a median follow-up of 2.5 years, 5-year PFS was 94%, with 7 patients (3.5%) experiencing neurologic deterioration. Irrespective of the number of fractions, SRS for meningioma is typically well tolerated, with minimal toxicity that is often limited to transient fatigue.

Brachytherapy

There are limited options for patients with recurrent atypical or anaplastic meningiomas after prior radiation therapy to the same site. Repeat surgery alone provides poor local control, the operative bed is often too large for SRS, and the benefit of systemic therapy is still being investigated. Re-resection followed by permanent-seed low-dose-rate brachytherapy is a viable salvage treatment option in this patient population with very limited options, but relatively high complication rates have been observed in these heavily treated patients. The largest experience with I-125 permanent seed implant at the time of re-resection of atypical or malignant meningiomas is a series consisting of 42 patients, 85% of whom had a history of prior radiation therapy, where the median time to progression was 11.4 months.⁷⁰ Overall complication rates were high and observed in 17 patients (40%), consisting of radiation necrosis (19%), wound breakdown (14%), wound infection (7%), and pseudomeningocele (5%).

Radionuclide Therapy

Like brachytherapy, peptide receptor radionuclide therapy (PRRT) may be beneficial for pretreated, progressive meningiomas. Somatostatin receptor type IIA (SSTR) is a highly specific marker for meningioma cells that is not otherwise expressed in the central nervous system,⁷¹ with the exception of the pituitary gland. Thus, positron emission tomography with SSTR ligands like DOTATATE and DOTATOC conjugated to the positron-emitter gallium-68 is being investigated for diagnostic purposes.⁷² In analogy to neuroendocrine tumors,⁷³ DOTA-conjugated SSTR ligands linked with the β -emitters lutetium-177 or yttrium-90 are suitable for PRRT,^{74–76} and consistently, meningiomas with higher SSTR expression are associated with tracer uptake and clinical response.^{77,78}

Systemic Treatments for Meningiomas

Patients with meningiomas in surgically challenging areas, such as the skull base, or patients with progressive or recurrent meningiomas after having undergone all potential surgical and radiotherapeutic treatment options, may benefit from systemic treatment options. However, to date, the efficacy of systemic agents has been disappointing. A variety of systemic treatment agents such as temozolomide, bevacizumab, somatostatin analogues, hydroxyurea, irinotecan, everolimus, vatalanib (PTK787/

ZK-222584), sunitinib, mifepristone, interferon- α , imatinib, erlotinib, gefitinib, and the combination of cyclophosphamide, doxorubicin, and vincristine have been investigated, and response rates have been, for the most part, small (Supplementary Table 1). Unfortunately, the interpretation of most meningioma trials can be challenging, as many studies are small and underpowered and lack control arms.^{3,79,80} A recent review summarized a total of 47 publications in regard to the outcomes of meningioma patients treated with systemic therapies. The weighted average PFS rates at 6 months were 29% (95% CI: 20.3%–37.7%) for WHO grade I meningiomas and 26% (95% CI: 19.3%–32.7%) for WHO grades II/III meningiomas, highlighting the need for improved systemic therapies for these patients.⁷⁹

Chemotherapy

Trabectedin is a chemotherapeutic agent which is routinely used for advanced sarcoma as well as for ovarian cancer.^{81,82} Trabectedin has shown activity in in vitro studies of meningioma, yet other than transcriptional interference, the mechanism of action of trabectedin is complex and not completely understood.⁸³ Based on these results, trabectedin is currently the only chemotherapeutic agent being investigated in a randomized, multicenter phase II trial for patients with recurrent WHO grades II/III meningiomas (EORTC-1320-BTG). This trial has recently completed accrual and results are expected in the near future.

Molecular Therapy

In recent years, the identification of specific genetic alterations in meningiomas has improved our understanding of this brain tumor and has opened up potential targeted treatment options for affected patients (Fig. 1 and 2).

In the 1990s, inactivation of the tumor suppressor gene neurofibromatosis 2 (*NF2*), which encodes for the protein merlin on chromosome 22 by either mutations or monosomy 22, was established as a driver in about 50% of sporadic meningiomas.^{84–87} Merlin plays a role in the activation of the mammalian target of rapamycin (mTOR) pathway during the pathogenesis of meningioma by negatively regulating the mTOR complex 1 (mTORC1)⁸⁸ and by positively regulating the kinase activity of mTORC2.⁸⁹ Consistently, overexpression of mTORC1 pathway components has been reported in meningiomas, and mTORC1 inhibitors, temsirolimus and everolimus, suppress meningioma growth in preclinical mouse models.⁹⁰ A phase II study of everolimus in combination with bevacizumab revealed stable disease for more than 6 months in 35% of patients (Supplementary Table 1).⁹¹ Moreover, the dual mTORC1 and mTORC2 inhibitor vistusertib (AZD2014) revealed promising results in preclinical studies in blocking proliferation of meningioma cells.⁹² AZD2014 is currently under evaluation in 2 phase II trials investigating efficacy in patients with recurrent WHO grades II and III meningiomas (NCT03071874), and in *NF2* patients with progressive or symptomatic meningiomas (NCT02831257).

Focal adhesion kinase (FAK) inhibition may be another promising avenue in *NF2*-altered tumors. In other

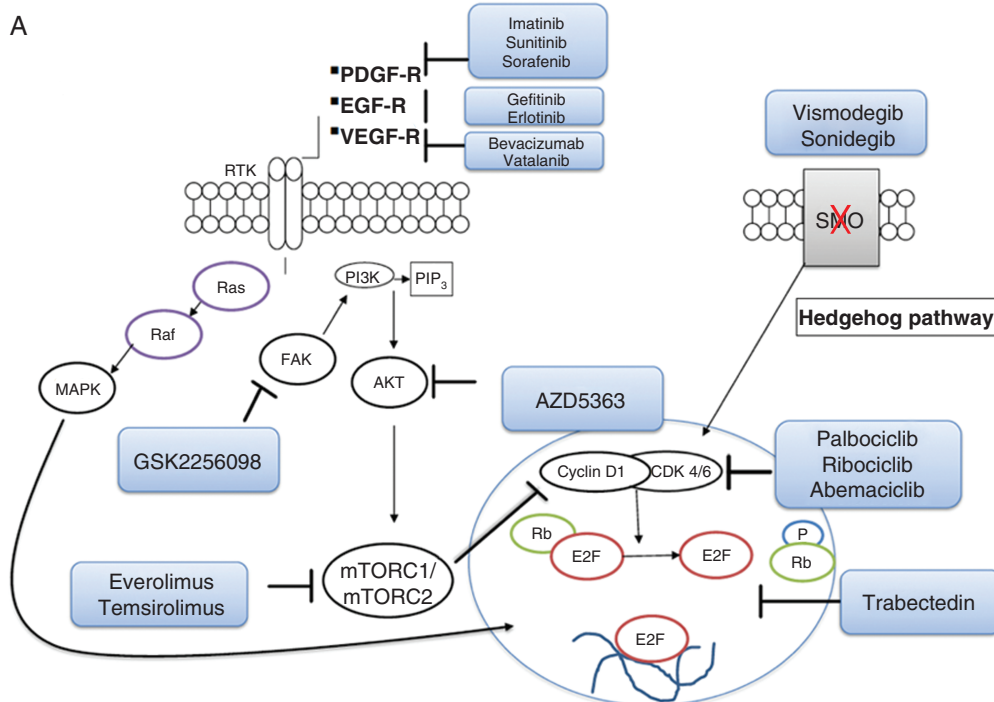


Figure modified from *Nature Reviews Neurology* 14, 106–115 (2018) with permission

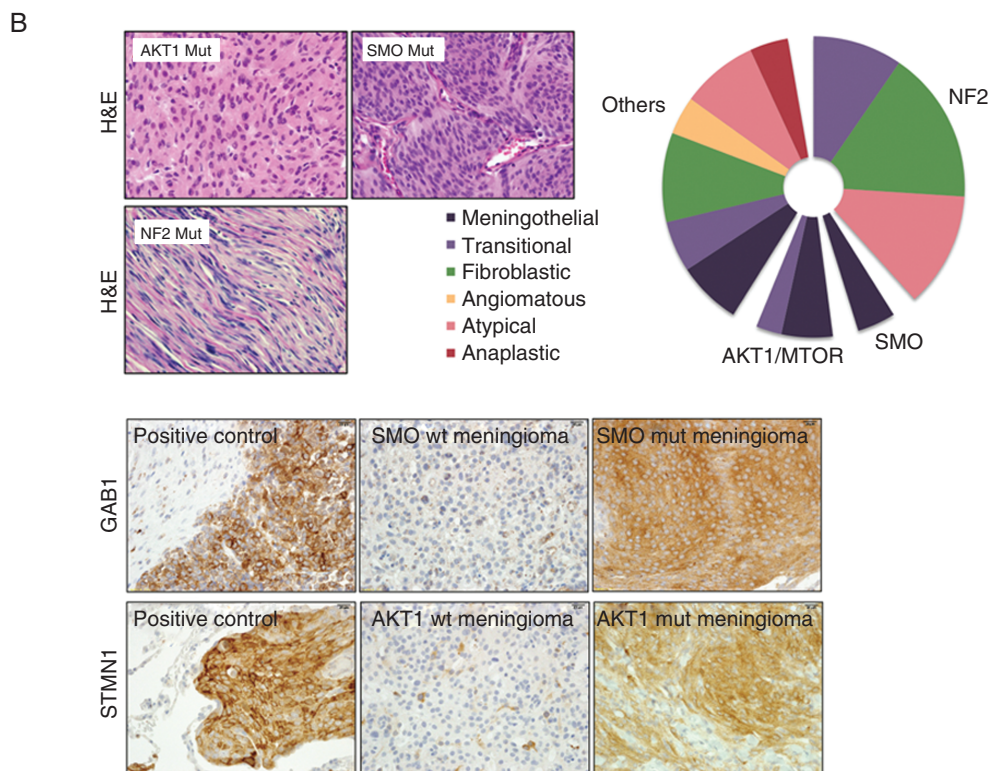


Figure modified from *Nature Genetics* 45(3), 285–289 (2013) with permission

Fig. 1 Potential signaling pathways that can be targeted in meningiomas (A, figure modified with permission from Preusser, Brastianos et al *Nature Reviews Neurology* 2018¹²⁶). (B) Human tumor samples with mutations in SMO and AKT1 are predominantly meningothelial, whereas NF2 mutated tumors are fibroblastic and/or transitional. Immunohistochemistry demonstrates activation of the Hedgehog signaling pathway with GAB1 positivity and the Akt/PI3K pathway with STMN1 positivity (figure modified with permission from Brastianos et al. *Nature Genetics* 2013¹²⁷).

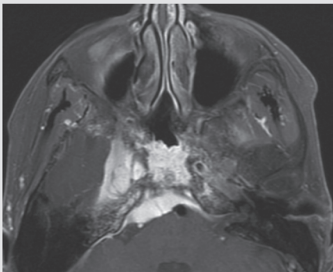
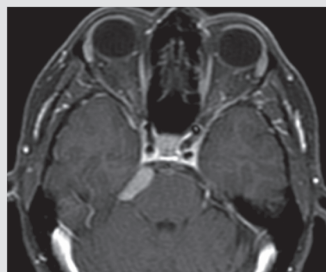
	External beam radiation therapy	Stereotactic radiosurgery
Example		
Tumor features	<ul style="list-style-type: none"> • Large (> 3–4 cm) • Contacting optic apparatus 	<ul style="list-style-type: none"> • Small • ≥ 2–3 mm from optic apparatus
Example prescription for WHO grade I	<ul style="list-style-type: none"> • 54 Gy at 1.8 Gy per fraction 	<ul style="list-style-type: none"> • 15 Gy in a single fraction
Additional technical considerations	<ul style="list-style-type: none"> • Increase conformality with IMRT or VMAT • Prescribe to high isodose line to minimize hot spots to adjacent critical structures 	<ul style="list-style-type: none"> • No margin added to GTV • Gamma knife SRS commonly prescribes to 50% isodose line for steep dose gradients; linear accelerator SRS typically treats at the 80% isodose line
Follow-up expectations	<ul style="list-style-type: none"> • EBRT and SRS generally prevent the growth of benign meningiomas on long-term follow-up; transient swelling after RT has been observed • Little to no tumor reduction • Symptomatic improvement is common despite minimal tumor reduction 	

Fig. 2 Comparisons of external beam radiation therapy (EBRT) and stereotactic radiosurgery (SRS) for the treatment of presumed benign meningiomas.

NF2-mutant tumors such as malignant pleural mesothelioma and serous ovarian carcinoma, cells which lack expression of merlin have been shown to be sensitive to FAK inhibition in vitro and in vivo studies.^{93,94} The role of FAK inhibitors in *NF2*-altered meningiomas is currently being investigated in a national Alliance-sponsored phase II trial (NCT02523014/A071401).

Anti-angiogenic inhibitors have also been investigated in meningiomas, with limited demonstrable efficacy. In retrospective studies of recurrent or progressive meningiomas, bevacizumab has some antineoplastic activity; however, these results need to be further validated in randomized controlled trials.^{95,96} In prospective studies, other anti-angiogenic agents, vatalanib and sunitinib, have shown limited efficacy, with response rates of 0% and 6%, respectively (Supplementary Table 1).^{97,98}

With the advent of massively parallel sequencing technologies, strides have been made that increase our understanding of the genomic landscape of meningiomas. Whole exome and whole genome sequencing have revealed that grade I meningiomas display relatively simple genomes compared with other brain tumors in adult

patients.⁹ In addition to *NF2* inactivation, alterations in epigenetic modifiers which have been associated with cancer such as *KDM5C*, *KDM6A*, and *SMARCB1* were found in 8% of meningiomas.¹⁴ Compounds targeting epigenetic changes such as inhibitors of histone deacetylase, DNA methyltransferase, enhancer of zeste homolog 2 (*EZH2*), and lysine (K)-specific demethylase 1 (*KDM1A*) are currently under evaluation in various clinical trials in other cancer types.⁹⁹ Other inhibitors—for example, the selective *KDM5*-inhibitor *KDOAM-25*¹⁰⁰—are being evaluated in preclinical trials and may warrant further investigation in preclinical studies in meningiomas before these compounds are explored in clinical trials. These agents are of particular interest for meningioma given the recently discovered prognostic significance of DNA methylation profile, whereby higher levels of DNA methylation in a set of stereotypic cytosine-phosphate-guanine sites delineate tumors that are more likely to recur.^{13,101,102}

Using next-generation sequencing techniques, recurrent oncogenic mutations have been identified in a subset of *NF2*-wildtype grade I meningiomas, such as mutations of *AKT1* (8–13%), a member of the phosphatidylinositol-3

kinase (PI3K)/Akt/mTOR pathway, and of Smoothed (SMO) (3–5%), a member of the Hedgehog (Hh) pathway.^{9,10,103} These mutations tend to be mutually exclusive with NF2 mutation, suggesting that they represent independent biological drivers of the tumor. These mutations can have location specificity as well, as the majority of meningiomas harboring *AKT1* and *SMO* mutations are present in the skull base.¹⁰⁴ In particular, *SMO* mutations are enriched in the olfactory groove location.¹⁰⁴ Akt inhibitors are showing promising activity in other *AKT*-mutated tumors.¹⁰⁵ Inhibitors of the Hh pathway have not been tested in meningioma patients to date, but 2 Hh inhibitors (vismodegib and sonidegib) are FDA approved for the treatment of patients with basal cell carcinoma, another Hh-associated cancer.¹⁰⁶ *PIK3CA* mutations are approximately as common as *AKT1* and *SMO* mutations in NF2-wildtype meningiomas, and the majority of these cases are similarly enriched in the skull base.¹⁰⁷

Because the skull base is a challenging location for surgery and radiotherapy, molecular agents targeting the PI3K/Akt/mTOR and Hh pathways may in the future represent promising approaches for some meningioma patients with tumors in this location. Indeed, a recent case report demonstrated a promising response to an Akt inhibitor in a patient with multiple recurrent intracranial meningiomas despite repeated surgical resections, RT, and other systemic agents.¹⁰⁸ Molecular therapy was well tolerated and resulted in a radiographic tumor reduction of up to 12.5%. After one year of treatment with AZD5363, the patient had a sustained clinical and radiographic response.¹⁰⁸ A national Alliance-sponsored cooperative group phase II trial in the US is currently evaluating the efficacy of SMO, AKT1, and FAK inhibitors in patients with residual, recurrent, or progressive meningiomas with targetable alterations in *SMO*, *AKT1*, and *NF2*, respectively (NCT02523014/A071401). This umbrella trial, the first precision medicine trial to be conducted in meningiomas, has co-primary endpoints of PFS and response rate at 6 months.

Other potential genetic driver alterations in NF2-wildtype meningiomas include alterations of the tumor suppressor genes cyclin-dependent kinase inhibitor 2A (*CDKN2A*) and *CDKN2B*, especially in atypical and anaplastic meningiomas.¹⁰⁹ In addition, malignant progression to WHO grade III is frequently characterized by recurrent genomic alterations such as *CDKN2A/CDKN2B* locus loss on the p-arm of chromosome 9.¹¹⁰ Thus, cyclin-dependent kinase pathway inhibition might be a potential target to treat higher-grade meningiomas in the near future and needs to be explored in preclinical and clinical studies.

Potential Molecular Targets

A recent genomic screen of meningioma samples that lacked previously identified driver genes discovered recurrent mutations in *POLR2A*, a gene encoding for the DNA-directed RNA polymerase II subunit RPB1 in 6% of all cases. *POLR2A* mutations were exclusively detected in WHO grade I meningiomas and were mainly associated with meningeothelial histology and a tendency to arise from the tuberculum sellae.¹⁴ The ubiquitin ligase tumor necrosis factor receptor-associated factor 7 (*TRAF7*) is mutated in approximately 20% of WHO grades I and II meningiomas.^{10,111} Mutations in the Krüppel-like factor 4 (*KLF4*) gene, a transcription factor,

are exclusively seen in secretory meningiomas, which also harbor *TRAF7* mutations.¹¹² Unfortunately, there are no existing targeted agents that inhibit the underlying pathways of these alterations. Likewise, there are no tractable targeted agents that inhibit the activity of forkhead box M1 (FOXO1), a pro-mitotic transcription factor that may underlie the growth of some clinically aggressive meningiomas.¹⁰² As is the case with *POLR2A*, *TRAF7*, *KLF4*, *FOXO1*, and the molecular targets described below, additional pre-clinical laboratory investigation is required before clinical trials targeting these molecules can be initiated.

Telomerase reverse transcriptase (*TERT*)-promoter mutations are associated with aggressive meningiomas¹¹³ and a significantly shorter time to recurrence¹² and were frequently observed in meningiomas with malignant histological progression.¹¹⁴ This mutation is associated with a significantly shorter overall survival compared with *TERT*-promoter wildtype grade III meningiomas (2.7 y vs 10.8 y).¹¹⁵ Further validation of *TERT* mutations on overall survival in larger studies is needed in order to determine its diagnostic and prognostic role.

In rhabdoid meningiomas, a histological subtype of WHO grade III meningiomas, inactivation of the tumor suppressor gene breast cancer 1 associated protein 1 (*BAP1*) was associated with an early tumor recurrence.¹¹⁶ Loss of immunohistochemical BAP1 expression is a surrogate for gene inactivation, and staining for BAP1 in this particular meningioma subtype might be a promising marker for risk assessment in these patients, as well as resolve true rhabdoid meningiomas from those which show histologic features of rhabdoid meningiomas but lack the mutation. Loss of *BAP1* may confer sensitivity to EZH2 inhibition. Furthermore, *SMARCE1* mutations were identified as a predisposing factor for intracranial clear cell meningiomas as well as for spinal cord meningiomas.^{117,118} Taken together, these findings might contribute to a better stratification of meningioma patients in future clinical trials. After validating their prognostic role, molecular alterations such as *TERT* promoter and *BAP1* mutations should be included in improved classification schemes to assign those patients to the most suitable treatment options. Moreover, taking molecular alterations into account might also facilitate the interpretation of results of clinical trials in the long term.

Fewer somatic targetable mutations have been identified in higher-grade meningiomas compared with grade I meningiomas. Higher-grade meningiomas do appear to harbor mutations that are predicted to be neoantigens, and therefore immunotherapy may play a larger role in higher-grade tumors.¹¹⁹

Immunotherapy

Immunotherapy is also being investigated in meningioma patients. A recent study examined immune infiltrates and found that expression of programmed death ligand 1 (PD-L1) was increased in WHO grade III meningiomas.^{120,121} Furthermore, higher numbers of PD-L1 expressing cells have been associated with a worse overall survival,¹²⁰ and there is evidence that meningiomas contain antigen-experienced effector T cells of an exhausted phenotype.¹²² Given these data, an immunosuppressive microenvironment might contribute to the malignant phenotype of meningiomas.¹²¹

Consequently, phase II trials are currently investigating the efficacy of checkpoint inhibitors (nivolumab and pembrolizumab) in recurrent or residual high-grade meningiomas (NCT03279692, NCT02648997), and the combination of RT and checkpoint blockade may offer benefit to meningioma patients, as has been shown for other cancer types.¹²³

Conclusions

For the majority of patients, surgery remains the first-line treatment for symptomatic and enlarging meningiomas. However, the lack of standardized outcomes for meningioma patients in neurosurgical series makes comparisons and pooling of data challenging.⁴ EBRT and SRS techniques have largely been used as a complementary therapeutic strategy in meningiomas, with excellent long-term local control. Brachytherapy is a salvage treatment option but is associated with high complication rates. Evidence supporting the current practices of RT in meningiomas is primarily from retrospective, single-institution reports, and studies of this nature have well-known weaknesses. RTOG 0539 and EORTC 22042 are two of the first cooperative group studies evaluating the outcomes of adjuvant RT in higher-risk meningiomas, and the final results will be highly anticipated. Several systemic therapies for meningiomas remain under investigation. The use of trabectedin, a chemotherapeutic agent commonly used in sarcomas, is under evaluation in a randomized, multicenter phase II trial for patients with recurrent WHO grade II/III meningiomas (EORTC-1320-BTG). The use of AZD2014 (dual mTOR inhibitor) is also currently under evaluation in 2 phase II trials in patients with recurrent WHO grades II and III meningiomas (NCT03071874) and in NF2 patients with progressive or symptomatic meningiomas (NCT02831257). A national Alliance-sponsored cooperative group phase II trial in the US is currently evaluating the efficacy of SMO, AKT1, and FAK inhibitors in patients with residual, recurrent, or progressive meningiomas with targetable alterations in *SMO*, *AKT1*, and *NF2*, respectively (NCT02523014/A071401). The results of these trials are highly anticipated, and the community awaits the results to establish the role of systemic therapies in treating patients with recurrent meningiomas.

Recommendations

Regarding treatment of patients with meningiomas and advancement of therapeutic research, the International Consortium on Meningiomas recommends:

- Patients should be made aware of all possible treatment options for primary and recurrent disease, including surgical resection, radiation therapy, and clinical trials.
- Challenging cases and multiply recurrent cases should be reviewed with a multidisciplinary team to allow for consensus of optimal treatment approach.
- Development of a core outcome set that includes intervention complication rates, epilepsy, cognitive function, and health-related quality of life will ensure that

meningioma trials report outcomes that are relevant and important to both patients and clinicians.^{124,125}

- Clinical trials should continue to stratify patients according to relevant biological subtypes of meningiomas defined by mutational and epigenetic alterations.
- Rapid cycle translation from discovery and preclinical testing to clinical trials is needed to promote research on therapeutic advances in meningiomas.

Funding

The collaborative effort of the International Consortium on Meningiomas (ICOM) is supported by the Brain Tumour Charity Quest for Cures: Collaborative Team Award and the Canadian Institute of Health Research.

Conflict of interest statement. J.C.T. was on the speaker's bureau and received honoraria from BrainLab company. P.K.B is a Consultant for Anglochem and Lilly and has received Speaker's Honoraria from Merck and Genentech-Roche and Institutional funding from Pfizer and Merck

Authorship statement. The generation of all manuscripts has been supported by the membership of the consortium, which at the time of supplement generation includes: Kenneth Aldape, Karolyn Au, Jill Barnhart-Sloan, Wenya Linda Bi, Priscilla K. Brastianos, Nicholas Butowski, Carlos Carlotti, Michael D. Cusimano, Francesco DiMeco, Katharine Drummond, Ian F. Dunn, Evanthia Galanis, Caterina Giannini, Roland Goldbrunner, Brent Griffith, Rintaro Hashizume, C. Oliver Hanemann, Christel Herold-Mende, Craig Horbinski, Raymond Y. Huang, David James, Michael D. Jenkinson, Christine Jungk, Timothy J. Kaufman, Boris Krischek, Daniel Lachance, Christian Lafougère, Ian Lee, Jeff C. Liu, Yasin Mamatjan, Alireza Mansouri, Christian Mawrin, Michael McDermott, David Munoz, Farshad Nassiri, Houtan Noushmehr, Ho-Keung Ng, Arie Perry, Farhad Pirouzmand, Laila M Poisson, Bianca Pollo, David Raleigh, Felix Sahn, Andrea Saladino, Thomas Santarius, Christian Schichor, David Schultz, Nils O. Schmidt, Warren Selman, Andrew Sloan, Julian Spears, James Snyder, Suganth Suppiah, Ghazaleh Tabatabai, Marcos Tatagiba, Daniela Tirapelli, Joerg C. Tonn, Derek Tsang, Michael A. Vogelbaum, Andreas von Deimling, Patrick Y. Wen, Tobias Walbert, Manfred Westphal, Adriana M. Workewych, Gelareh Zadeh.

Sponsorship statement. This supplement was supported by an unrestricted grant from the MacFeeters Hamilton Neuro-Oncology Program at the Princess Margaret Cancer Center and by the Dr. Mary Hunter Brain Tumor Research Funds from the Toronto General & Western Hospital Foundation.

References

1. Jadid KD, Feychting M, Höjjer J, Hylin S, Kihlström L, Mathiesen T. Long-term follow-up of incidentally discovered meningiomas. *Acta Neurochir (Wien)*. 2015;157(2):225–30; discussion 230.

2. Goldbrunner R, Minniti G, Preusser M, et al. EANO guidelines for the diagnosis and treatment of meningiomas. *Lancet Oncol*. 2016;17(9):e383–e391.
3. Wen PY, Quant E, Drappatz J, Beroukhi R, Norden AD. Medical therapies for meningiomas. *J Neurooncol*. 2010;99(3):365–378.
4. Rogers L, Barani I, Chamberlain M, et al. Meningiomas: knowledge base, treatment outcomes, and uncertainties. A RANO review. *J Neurosurg*. 2015;122(1):4–23.
5. Nakasu S, Fukami T, Jito J, Matsuda M. Microscopic anatomy of the brain-meningioma interface. *Brain Tumor Pathol*. 2005;22(2):53–57.
6. Chen WC, Magill ST, Englot DJ, et al. Factors associated with pre- and postoperative seizures in 1033 patients undergoing supratentorial meningioma resection. *Neurosurgery*. 2017;81(2):297–306.
7. Englot DJ, Magill ST, Han SJ, Chang EF, Berger MS, McDermott MW. Seizures in supratentorial meningioma: a systematic review and meta-analysis. *J Neurosurg*. 2016;124(6):1552–1561.
8. Louis DN, Perry A, Reifenberger G, et al. The 2016 World Health Organization Classification of Tumors of the Central Nervous System: a summary. *Acta Neuropathol*. 2016;131(6):803–820.
9. Brastianos PK, Horowitz PM, Santagata S, et al. Genomic sequencing of meningiomas identifies oncogenic SMO and AKT1 mutations. *Nat Genet*. 2013;45(3):285–289.
10. Clark VE, Erson-Omay EZ, Serin A, et al. Genomic analysis of non-NF2 meningiomas reveals mutations in TRAF7, KLF4, AKT1, and SMO. *Science*. 2013;339(6123):1077–1080.
11. Schmidt M, Mock A, Jungk C, et al. Transcriptomic analysis of aggressive meningiomas identifies PTTG1 and LEPR as prognostic biomarkers independent of WHO grade. *Oncotarget*. 2016;7(12):14551–14568.
12. Sahm F, Schrimpf D, Olar A, et al. TERT promoter mutations and risk of recurrence in meningioma. *J Natl Cancer Inst*. 2016;108(5):d37377.
13. Sahm F, Schrimpf D, Stichel D, et al. DNA methylation-based classification and grading system for meningioma: a multicentre, retrospective analysis. *Lancet Oncol*. 2017;18(5):682–694.
14. Clark VE, Harmanci AS, Bai H, et al. Recurrent somatic mutations in POLR2A define a distinct subset of meningiomas. *Nat Genet*. 2016;48(10):1253–1259.
15. Jenkinson MD, Santarius T, Zadeh G, Aldape KD. Atypical meningioma—is it time to standardize surgical sampling techniques? *Neuro Oncol*. 2017;19(3):453–454.
16. Simpson D. The recurrence of intracranial meningiomas after surgical treatment. *J Neurol Neurosurg Psychiatry*. 1957;20(1):22–39.
17. Kriss TC, Kriss VM. History of the operating microscope: from magnifying glass to microneurosurgery. *Neurosurgery*. 1998;42(4):899–907; discussion 907–908.
18. Rachinger W, Grau S, Tonn JC. Different microsurgical approaches to meningiomas of the anterior cranial base. *Acta Neurochir (Wien)*. 2010;152(6):931–939.
19. Sindou M, Hallacq P. Venous reconstruction in surgery of meningiomas invading the sagittal and transverse sinuses. *Skull Base Surg*. 1998;8(2):57–64.
20. Bloch O, McDermott MW. In situ cranioplasty for hyperostosing meningiomas of the cranial vault. *Can J Neurol Sci*. 2011;38(1):59–64.
21. Di Maio S, Ramanathan D, Garcia-Lopez R, et al. Evolution and future of skull base surgery: the paradigm of skull base meningiomas. *World Neurosurg*. 2012;78(3-4):260–275.
22. Misra BK. The paradigm of skull base meningiomas: what is optimal? *World Neurosurg*. 2012;78(3-4):220–221.
23. Sindou MP, Alvernia JE. Results of attempted radical tumor removal and venous repair in 100 consecutive meningiomas involving the major dural sinuses. *J Neurosurg*. 2006;105(4):514–525.
24. Han MS, Kim YJ, Moon KS, et al. Lessons from surgical outcome for intracranial meningioma involving major venous sinus. *Medicine (Baltimore)*. 2016;95(35):e4705.
25. Combs SE, Ganswindt U, Foote RL, Kondziolka D, Tonn JC. State-of-the-art treatment alternatives for base of skull meningiomas: complementing and controversial indications for neurosurgery, stereotactic and robotic based radiosurgery or modern fractionated radiation techniques. *Radiat Oncol*. 2012;7:226.
26. Yamashita S, Fujisawa M, Kodama K, Ishikawa M, Katagi R. Use of preoperative 3D CT/MR fusion images and intraoperative CT to detect lesions that spread onto the brain surface. *Acta Neurochir Suppl*. 2013;118:239–244.
27. Schichor C, Terpolilli N, Thorsteinsdottir J, Tonn J-C. Intraoperative computed tomography in cranial neurosurgery. *Neurosurg Clin N Am*. 2017;28(4):595–602.
28. Terpolilli NA, Rachinger W, Kunz M, et al. Orbit-associated tumors: navigation and control of resection using intraoperative computed tomography. *J Neurosurg*. 2016;124(5):1319–1327.
29. Rachinger W, Stoecklein VM, Terpolilli NA, et al. Increased 68Ga-DOTATATE uptake in PET imaging discriminates meningioma and tumor-free tissue. *J Nucl Med*. 2015;56(3):347–353.
30. Kunz WG, Jungblut LM, Kazmierczak PM, et al. Improved detection of transosseous meningiomas using 68Ga-DOTATATE PET/CT compared with contrast-enhanced MRI. *J Nucl Med*. 2017;58(10):1580–1587.
31. Cocks K, King MT, Velikova G, Fayers PM, Brown JM. Quality, interpretation and presentation of European Organisation for Research and Treatment of Cancer quality of life questionnaire core 30 data in randomised controlled trials. *Eur J Cancer*. 2008;44(13):1793–1798.
32. Barani I, Parsa A. Adaptive hybrid surgery: feasibility of planned subtotal resection of benign skull base tumors followed by radiosurgery to minimize morbidity without compromising tumor control. *IJROBP*. 2012;84(3, Supplement):S278-S279.
33. Motekalleli A, Jeltama H-R, Metzemaekers JDM, van Dam GM, Crane LMA, Groen RJM. The current status of 5-ALA fluorescence-guided resection of intracranial meningiomas—a critical review. *Neurosurg Rev*. 2015;38(4):619–628.
34. Muskens IS, Briceno V, Ouweland TL, et al. The endoscopic endonasal approach is not superior to the microscopic transcranial approach for anterior skull base meningiomas—a meta-analysis. *Acta Neurochir (Wien)*. 2018;160(1):59–75.
35. McCulloch P, Altman DG, Campbell WB, et al; Balliol Collaboration. No surgical innovation without evaluation: the IDEAL recommendations. *Lancet*. 2009;374(9695):1105–1112.
36. Ivan ME, Diaz RJ, Berger MH, et al. Magnetic resonance-guided laser ablation for the treatment of recurrent dural-based lesions: a series of five cases. *World Neurosurg*. 2017;98:162–170.
37. Gallagher MJ, Jenkinson MD, Brodbelt AR, Mills SJ, Chavredakis E. WHO grade 1 meningioma recurrence: are location and Simpson grade still relevant? *Clin Neurol Neurosurg*. 2016;141:117–121.
38. Lam Shin Cheung V, Kim A, Sahgal A, Das S. Meningioma recurrence rates following treatment: a systematic analysis. *J Neurooncol*. 2018;136(2):351–361.
39. Vogelbaum MA, Leland Rogers C, Linskey MA, Mehta MP. Opportunities for clinical research in meningioma. *J Neurooncol*. 2010;99(3):417–422.
40. King DL, Chang CH, Pool JL. Radiotherapy in the management of meningiomas. *Acta Radiol Ther Phys Biol*. 1966;5:26–33.
41. Wara WM, Shelton GE, Newman H, Townsend JJ, Boldrey EB. Radiation therapy of meningiomas. *Am J Roentgenol Radium Ther Nucl Med*. 1975;123(3):453–458.
42. Goldsmith BJ, Wara WM, Wilson CB, Larson DA. Postoperative irradiation for subtotally resected meningiomas. A retrospective analysis of 140 patients treated from 1967 to 1990. *J Neurosurg*. 1994;80(2):195–201.

43. Mirimanoff RO, Dosoretz DE, Linggood RM, Ojemann RG, Martuza RL. Meningioma: analysis of recurrence and progression following neurosurgical resection. *J Neurosurg.* 1985;62(1):18–24.
44. Henzel M, Gross MW, Hamm K, et al. Stereotactic radiotherapy of meningiomas: symptomatology, acute and late toxicity. *Strahlenther Onkol.* 2006;182(7):382–388.
45. Milker-Zabel S, Zabel A, Schulz-Ertner D, Schlegel W, Wannenmacher M, Debus J. Fractionated stereotactic radiotherapy in patients with benign or atypical intracranial meningioma: long-term experience and prognostic factors. *Int J Radiat Oncol Biol Phys.* 2005;61(3):809–816.
46. Henzel M, Gross MW, Hamm K, et al. Significant tumor volume reduction of meningiomas after stereotactic radiotherapy: results of a prospective multicenter study. *Neurosurgery.* 2006;59(6):1188–1194; discussion 1194.
47. Debus J, Wuendrich M, Pirzkall A, et al. High efficacy of fractionated stereotactic radiotherapy of large base-of-skull meningiomas: long-term results. *J Clin Oncol.* 2001;19(15):3547–3553.
48. Adebeg S, Harrabi SB, Verma V, et al. Treatment of meningioma and glioma with protons and carbon ions. *Radiat Oncol.* 2017;12(1):193.
49. Vendrely V, Maire JP, Darrouzet V, et al. Fractionated radiotherapy of intracranial meningiomas: 15 years' experience at the Bordeaux University Hospital Center. *Cancer Radiother.* 1999;3(4):311–317.
50. Wenkel E, Thornton AF, Finkelstein D, et al. Benign meningioma: partially resected, biopsied, and recurrent intracranial tumors treated with combined proton and photon radiotherapy. *Int J Radiat Oncol Biol Phys.* 2000;48(5):1363–1370.
51. Metellus P, Regis J, Muracciole X, et al. Evaluation of fractionated radiotherapy and gamma knife radiosurgery in cavernous sinus meningiomas: treatment strategy. *Neurosurgery.* 2005;57(5):873–886; discussion 873–886.
52. Turbin RE, Thompson CR, Kennerdell JS, Cockerham KP, Kupersmith MJ. A long-term visual outcome comparison in patients with optic nerve sheath meningioma managed with observation, surgery, radiotherapy, or surgery and radiotherapy. *Ophthalmology.* 2002;109(5):890–9; discussion 899–900.
53. Mendenhall WM, Morris CG, Amdur RJ, Foote KD, Friedman WA. Radiotherapy alone or after subtotal resection for benign skull base meningiomas. *Cancer.* 2003;98(7):1473–1482.
54. Hug EB, Devries A, Thornton AF, et al. Management of atypical and malignant meningiomas: role of high-dose, 3D-conformal radiation therapy. *J Neurooncol.* 2000;48(2):151–160.
55. Coke CC, Corn BW, Werner-Wasik M, Xie Y, Curran WJ. Atypical and malignant meningiomas: an outcome report of seventeen cases. *J Neurooncol.* 1998;39(1):65–70.
56. Perry A, Stafford SL, Scheithauer BW, Suman VJ, Lohse CM. Meningioma grading: an analysis of histologic parameters. *Am J Surg Pathol.* 1997;21(12):1455–1465.
57. Perry A, Scheithauer BW, Stafford SL, Lohse CM, Wollan PC. Malignancy in meningiomas: a clinicopathologic study of 116 patients, with grading implications. *Cancer.* 1999;85(9):2046–2056.
58. Rogers L, Zhang P, Vogelbaum MA, et al. Intermediate-risk meningioma: initial outcomes from NRG Oncology RTOG 0539. *J Neurosurg.* 2017;129:1–13.
59. Jenkinson MD, Javadpour M, Haylock BJ, et al. The ROAM/EORTC-1308 trial: radiation versus observation following surgical resection of atypical meningioma: study protocol for a randomised controlled trial. *Trials.* 2015;16:519.
60. Chen WC, Magill ST, Wu A, et al. Histopathological features predictive of local control of atypical meningioma after surgery and adjuvant radiotherapy. *J Neurosurg.* 2018;6:1–8.
61. Chen WC, Hara J, Magill ST, et al. Salvage therapy outcomes for atypical meningioma. *J Neurooncol.* 2018;138(2):425–433.
62. Stafford SL, Pollock BE, Foote RL, et al. Meningioma radiosurgery: tumor control, outcomes, and complications among 190 consecutive patients. *Neurosurgery.* 2001;49(5):1029–37; discussion 1037–8.
63. Nicolato A, Giorgetti P, Foroni R, et al. Gamma knife radiosurgery in skull base meningiomas: a possible relationship between somatostatin receptor decrease and early neurological improvement without tumour shrinkage at short-term imaging follow-up. *Acta Neurochir (Wien).* 2005;147(4):367–74; discussion 374.
64. Kreil W, Luggin J, Fuchs I, Weigl V, Eustacchio S, Papaefthymiou G. Long term experience of gamma knife radiosurgery for benign skull base meningiomas. *J Neurol Neurosurg Psychiatry.* 2005;76(10):1425–1430.
65. Di Franco R, Borzillo V, Ravo V, et al. Radiosurgery and stereotactic radiotherapy with cyberknife system for meningioma treatment. *Neuroradiol J.* 2018;31(1):18–26.
66. Hasegawa T, Kida Y, Yoshimoto M, Koike J, Iizuka H, Ishii D. Long-term outcomes of Gamma Knife surgery for cavernous sinus meningioma. *J Neurosurg.* 2007;107(4):745–751.
67. Santacrose A, Walier M, Régis J, et al. Long-term tumor control of benign intracranial meningiomas after radiosurgery in a series of 4565 patients. *Neurosurgery.* 2012;70(1):32–9; discussion 39.
68. Kaprelian T, Raleigh DR, Sneed PK, Nabavizadeh N, Nakamura JL, McDermott MW. Parameters influencing local control of meningiomas treated with radiosurgery. *J Neurooncol.* 2016;128(2):357–364.
69. Colombo F, Casentini L, Cavedon C, Scalchi P, Cora S, Francescon P. Cyberknife radiosurgery for benign meningiomas: short-term results in 199 patients. *Neurosurgery.* 2009;64(2 Suppl):A7–13.
70. Magill ST, Lau D, Raleigh DR, Sneed PK, Fogh SE, McDermott MW. Surgical Resection and interstitial iodine-125 brachytherapy for high-grade meningiomas: a 25-year series. *Neurosurgery.* 2017;80(3):409–416.
71. Menke JR, Raleigh DR, Gown AM, Thomas S, Perry A, Tihan T. Somatostatin receptor 2a is a more sensitive diagnostic marker of meningioma than epithelial membrane antigen. *Acta Neuropathol.* 2015;130(3):441–443.
72. Galldiks N, Albert NL, Sommerauer M, et al. PET imaging in patients with meningioma-report of the RANO/PET Group. *Neuro Oncol.* 2017;19(12):1576–1587.
73. Imhof A, Brunner P, Marincek N, et al. Response, survival, and long-term toxicity after therapy with the radiolabeled somatostatin analogue [90Y-DOTA]-TOC in metastasized neuroendocrine cancers. *J Clin Oncol.* 2011;29(17):2416–2423.
74. Kwekkeboom DJ, de Herder WW, Kam BL, et al. Treatment with the radiolabeled somatostatin analog [177 Lu-DOTA 0,Tyr3]octreotate: toxicity, efficacy, and survival. *J Clin Oncol.* 2008;26(13):2124–2130.
75. Bartolomei M, Bodei L, De Cicco C, et al. Peptide receptor radionuclide therapy with (90)Y-DOTATOC in recurrent meningioma. *Eur J Nucl Med Mol Imaging.* 2009;36(9):1407–1416.
76. Marincek N, Radojewski P, Dumont RA, et al. Somatostatin receptor-targeted radiopeptide therapy with 90Y-DOTATOC and 177Lu-DOTATOC in progressive meningioma: long-term results of a phase II clinical trial. *J Nucl Med.* 2015;56(2):171–176.
77. Hänscheid H, Sweeney RA, Flentje M, et al. PET SUV correlates with radionuclide uptake in peptide receptor therapy in meningioma. *Eur J Nucl Med Mol Imaging.* 2012;39(8):1284–1288.
78. Seystahl K, Stoeklein V, Schüller U, et al. Somatostatin receptor-targeted radionuclide therapy for progressive meningioma: benefit linked to 68Ga-DOTATATE/-TOC uptake. *Neuro Oncol.* 2016;18(11):1538–1547.
79. Kaley T, Barani I, Chamberlain M, et al. Historical benchmarks for medical therapy trials in surgery- and radiation-refractory meningioma: a RANO review. *Neuro Oncol.* 2014;16(6):829–840.
80. Nordren AD, Ligon KL, Hammond SN, et al. Phase II study of monthly pasireotide LAR (SOM230C) for recurrent or progressive meningioma. *Neurology.* 2015;84(3):280–286.

81. Demetri GD, Chawla SP, von Mehren M, et al. Efficacy and safety of trabectedin in patients with advanced or metastatic liposarcoma or leiomyosarcoma after failure of prior anthracyclines and ifosfamide: results of a randomized phase II study of two different schedules. *J Clin Oncol*. 2009;27(25):4188–4196.
82. Kaye SB, Colombo N, Monk BJ, et al. Trabectedin plus pegylated liposomal doxorubicin in relapsed ovarian cancer delays third-line chemotherapy and prolongs the platinum-free interval. *Ann Oncol Off J Eur Soc Med Oncol*. 2011;22(1):49–58.
83. Preusser M, Spiegl-Kreinecker S, Lötsch D, et al. Trabectedin has promising antineoplastic activity in high-grade meningioma. *Cancer*. 2012;118(20):5038–5049.
84. Choy W, Kim W, Nagasawa D, et al. The molecular genetics and tumor pathogenesis of meningiomas and the future directions of meningioma treatments. *Neurosurg Focus*. 2011;30(5):E6.
85. Lekan Deprez RH, Bianchi AB, Groen NA, et al. Frequent NF2 gene transcript mutations in sporadic meningiomas and vestibular schwannomas. *Am J Hum Genet*. 1994;54(6):1022–1029.
86. Rutledge MH, Sarrazin J, Rangaratnam S, et al. Evidence for the complete inactivation of the NF2 gene in the majority of sporadic meningiomas. *Nat Genet*. 1994;6(2):180–184.
87. Wellenreuther R, Kraus JA, Lenartz D, et al. Analysis of the neurofibromatosis 2 gene reveals molecular variants of meningioma. *Am J Pathol*. 1995;146(4):827–832.
88. James MF, Han S, Polizzano C, et al. NF2/merlin is a novel negative regulator of mTOR complex 1, and activation of mTORC1 is associated with meningioma and schwannoma growth. *Mol Cell Biol*. 2009;29(15):4250–4261.
89. James MF, Stivison E, Beauchamp R, et al. Regulation of mTOR complex 2 signaling in neurofibromatosis 2-deficient target cell types. *Mol Cancer Res*. 2012;10(5):649–659.
90. Pachow D, Andrae N, Kliese N, et al. mTORC1 inhibitors suppress meningioma growth in mouse models. *Clin Cancer Res*. 2013;19(5):1180–1189.
91. Shih KC, Chowdhary S, Rosenblatt P, et al. A phase II trial of bevacizumab and everolimus as treatment for patients with refractory, progressive intracranial meningioma. *J Neurooncol*. 2016;129(2):281–288.
92. Beauchamp RL, James MF, DeSouza PA, et al. A high-throughput kinome screen reveals serum/glucocorticoid-regulated kinase 1 as a therapeutic target for NF2-deficient meningiomas. *Oncotarget*. 2015;6(19):16981–16997.
93. Shah NR, Tancioni I, Ward KK, et al. Analyses of merlin/NF2 connection to FAK inhibitor responsiveness in serous ovarian cancer. *Gynecol Oncol*. 2014;134(1):104–111.
94. Shapiro IM, Kolev VN, Vidal CM, et al. Merlin deficiency predicts FAK inhibitor sensitivity: a synthetic lethal relationship. *Sci Transl Med*. 2014;6(237):237ra68.
95. Nunes FP, Merker VL, Jennings D, et al. Bevacizumab treatment for meningiomas in NF2: a retrospective analysis of 15 patients. *PLoS One*. 2013;8(3):e59941.
96. Lou E, Sumrall AL, Turner S, et al. Bevacizumab therapy for adults with recurrent/progressive meningioma: a retrospective series. *J Neurooncol*. 2012;109(1):63–70.
97. Raizer JJ, Grimm SA, Rademaker A, et al. A phase II trial of PTK787/ZK 222584 in recurrent or progressive radiation and surgery refractory meningiomas. *J Neurooncol*. 2014;117(1):93–101.
98. Kaley TJ, Wen P, Schiff D, et al. Phase II trial of sunitinib for recurrent and progressive atypical and anaplastic meningioma. *Neuro Oncol*. 2015;17(1):116–121.
99. Pfister SX, Ashworth A. Marked for death: targeting epigenetic changes in cancer. *Nat Rev Drug Discov*. 2017;16(4):241–263.
100. Tumber A, Nuzzi A, Hookway ES, et al. Potent and selective KDM5 inhibitor stops cellular demethylation of H3K4me3 at transcription start sites and proliferation of MM1S myeloma cells. *Cell Chem Biol*. 2017;24(3):371–380.
101. Olar A, Wani KM, Wilson CD, et al. Global epigenetic profiling identifies methylation subgroups associated with recurrence-free survival in meningioma. *Acta Neuropathol*. 2017;133(3):431–444.
102. Vasudevan HN, Braunstein SE, Phillips JJ, et al. Comprehensive molecular profiling identifies FOXM1 as a key transcription factor for meningioma proliferation. *Cell Rep*. 2018;22(13):3672–3683.
103. Sahm F, Bissel J, Koelsche C, et al. AKT1E17K mutations cluster with meningothelial and transitional meningiomas and can be detected by SFRP1 immunohistochemistry. *Acta Neuropathol*. 2013;126(5):757–762.
104. Strickland MR, Gill CM, Nayyar N, et al. Targeted sequencing of SMO and AKT1 in anterior skull base meningiomas. *J Neurosurg*. 2017;127(2):438–444.
105. Hyman DM, Smyth LM, Donoghue MTA, et al. AKT inhibition in solid tumors with AKT1 mutations. *J Clin Oncol*. 2017;35(20):2251–2259.
106. Silapunt S, Chen L, Migden MR. Hedgehog pathway inhibition in advanced basal cell carcinoma: latest evidence and clinical usefulness. *Ther Adv Med Oncol*. 2016;8(5):375–382.
107. Abedalthagafi M, Bi WL, Aizer AA, et al. Oncogenic PI3K mutations are as common as AKT1 and SMO mutations in meningioma. *Neuro Oncol*. 2016;18(5):649–655.
108. Weller M, Roth P, Sahm F, et al. Durable control of metastatic AKT1-mutant WHO grade 1 meningothelial meningioma by the AKT inhibitor, AZD5363. *J Natl Cancer Inst*. 2017;109(3):1–4.
109. Boström J, Meyer-Puttitz B, Wolter M, et al. Alterations of the tumor suppressor genes CDKN2A (p16(INK4a)), p14(ARF), CDKN2B (p15(INK4b)), and CDKN2C (p18(INK4c)) in atypical and anaplastic meningiomas. *Am J Pathol*. 2001;159(2):661–669.
110. Goutagny S, Yang HW, Zucman-Rossi J, et al. Genomic profiling reveals alternative genetic pathways of meningioma malignant progression dependent on the underlying NF2 status. *Clin Cancer Res*. 2010;16(16):4155–4164.
111. Yuzawa S, Nishihara H, Yamaguchi S, et al. Clinical impact of targeted amplicon sequencing for meningioma as a practical clinical-sequencing system. *Mod Pathol*. 2016;29(7):708–716.
112. Reuss DE, Piro RM, Jones DTW, et al. Secretory meningiomas are defined by combined KLF4 K409Q and TRAF7 mutations. *Acta Neuropathol*. 2013;125(3):351–358.
113. Kalala JPO, Maes L, Vandenbroecke C, de Ridder L. The hTERT protein as a marker for malignancy in meningiomas. *Oncol Rep*. 2005;13(2):273–277.
114. Goutagny S, Nault JC, Mallet M, Henin D, Rossi JZ, Kalamirides M. High incidence of activating TERT promoter mutations in meningiomas undergoing malignant progression. *Brain Pathol*. 2014;24(2):184–189.
115. Juratli TA, Thiede C, Koerner MVA, et al. Intratumoral heterogeneity and TERT promoter mutations in progressive/higher-grade meningiomas. *Oncotarget*. 2017;8(65):109228–109237.
116. Shankar GM, Santagata S. BAP1 mutations in high-grade meningioma: implications for patient care. *Neuro Oncol*. 2017;19(11):1447–1456.
117. Smith MJ, O'Sullivan J, Bhaskar SS, et al. Loss-of-function mutations in SMARCE1 cause an inherited disorder of multiple spinal meningiomas. *Nat Genet*. 2013;45(3):295–298.
118. Smith MJ, Wallace AJ, Bennett C, et al. Germline SMARCE1 mutations predispose to both spinal and cranial clear cell meningiomas. *J Pathol*. 2014;234(4):436–440.
119. Bi WL, Greenwald NF, Abedalthagafi M, et al. Erratum: genomic landscape of high-grade meningiomas. *NPJ Genom Med*. 2017;2:26.

120. Han SJ, Reis G, Kohanbash G, et al. Expression and prognostic impact of immune modulatory molecule PD-L1 in meningioma. *J Neurooncol.* 2016;130(3):543–552.
121. Du Z, Abedalthagafi M, Aizer AA, et al. Increased expression of the immune modulatory molecule PD-L1 (CD274) in anaplastic meningioma. *Oncotarget.* 2015;6(7):4704–4716.
122. Fang L, Lowther DE, Meizlish ML, et al. The immune cell infiltrate populating meningiomas is composed of mature, antigen-experienced T and B cells. *Neuro Oncol.* 2013;15(11):1479–1490.
123. Sharabi AB, Lim M, DeWeese TL, Drake CG. Radiation and checkpoint blockade immunotherapy: radiosensitisation and potential mechanisms of synergy. *Lancet Oncol.* 2015;16(13):e498–e509.
124. Williamson PR, Altman DG, Blazeby JM, et al. Developing core outcome sets for clinical trials: issues to consider. *Trials.* 2012;13(1):132.
125. Williamson P, Altman D, Blazeby J, Clarke M, Gargon E. Driving up the quality and relevance of research through the use of agreed core outcomes. *J Health Serv Res Policy.* 2012;17(1):1–2.
126. Preusser M, Brastianos PK, Mawrin C. Advances in meningioma genetics: novel therapeutic opportunities. *Nat Rev Neurol.* 2018;14(2):106–115.
127. Brastianos PK, Horowitz PM, Santagata S, et al. Genomic sequencing of meningiomas identifies oncogenic SMO and AKT1 mutations. *Nat Genet.* 2013;45(3):285–289.