

UC Davis

Dermatology Online Journal

Title

Angiolymphoid hyperplasia with eosinophilia treated with Mohs micrographic surgery

Permalink

<https://escholarship.org/uc/item/1t75v80t>

Journal

Dermatology Online Journal, 25(12)

Authors

Trivedi, Apoorva
Norris, Ivy
DeWitt, Corey M
et al.

Publication Date

2019

DOI

10.5070/D32512046725

Copyright Information

Copyright 2019 by the author(s). This work is made available under the terms of a Creative Commons Attribution-NonCommercial-NoDerivatives License, available at <https://creativecommons.org/licenses/by-nc-nd/4.0/>

Peer reviewed

Angiolymphoid hyperplasia with eosinophilia treated with Mohs micrographic surgery

Apoorva Trivedi MD, Ivy Norris MD, Corey M DeWitt MD, and Glenn D Goldman MD

Affiliations: The Robert Larner, M.D. College of Medicine at the University of Vermont, Burlington, Vermont, USA

Corresponding Author: Apoorva Trivedi MD, Saint Vincent's Medical Center, 2800 Main Street, Bridgeport, CT 06606, Tel: 203-576-6000, pager extension 910, Email: Apoorva.Trivedi@ascension.org

Abstract

A 60-year-old healthy man presented with several enlarging, tender, spontaneously bleeding, and episodically pruritic nodules on his ear. Five agminated pink-red papulonodules of the superior postauricular sulcus were noted on examination. Pathological examination revealed a lobular dermal vascular proliferation with plump endothelial cells protruding into the lumen in a hobnail pattern, along with a dense perivascular inflammatory infiltrate composed of plasma cells, lymphocytes, and numerous eosinophils. The diagnosis of angiolymphoid hyperplasia with eosinophilia was confirmed. After discussing treatment modalities, the patient opted for Mohs micrographic surgery (MMS). Three stages of MMS were able to remove all large vessel involvement and clear the peripheral margins, but the tumor had a complex branching pattern of growth in the deep bed of the wound with numerous tiny foci remaining. Owing to risk of disfigurement, no further excision was undertaken. The area was reconstructed with a temporalis fascia flap and a full-thickness skin graft. Despite remaining microscopic disease, the patient remained without recurrence or symptoms at one year of follow up.

Keywords: angiolymphoid hyperplasia with eosinophilia, epithelioid hemangioma, Mohs micrographic surgery

Introduction

Angiolymphoid hyperplasia with eosinophilia (ALHE) is a rare vascular tumor with a tendency to occur in the head and neck of middle-aged adults. Although benign, the tumor may cause pain, bleeding, or pruritus. Surgical excision is considered the most effective treatment from amongst many options, but

treatment failure still exceeds 40% with surgery. We present a case of ALHE treated with Mohs micrographic surgery.

Case Synopsis

A 60-year-old healthy man presented to the dermatology clinic with a 6-month history of several enlarging nodules of the ear. The lesions were enlarging, tender, spontaneously bleeding, and episodically pruritic. The only attempted treatment was with oral cephalosporins, which was ineffective.

Physical examination revealed five agminated pink-red papulonodules of the superior postauricular sulcus, the largest of which was over one centimeter in diameter. Several of the lesions were eroded (**Figure 1**). The clinical differential diagnosis was broad but most suggestive of cutaneous lymphoma or angiolymphoid hyperplasia.

A skin biopsy was performed and revealed a lobular dermal vascular proliferation (**Figure 2**). The vessels were lined by plump endothelial cells exhibiting protrusion into the lumen. A dense perivascular

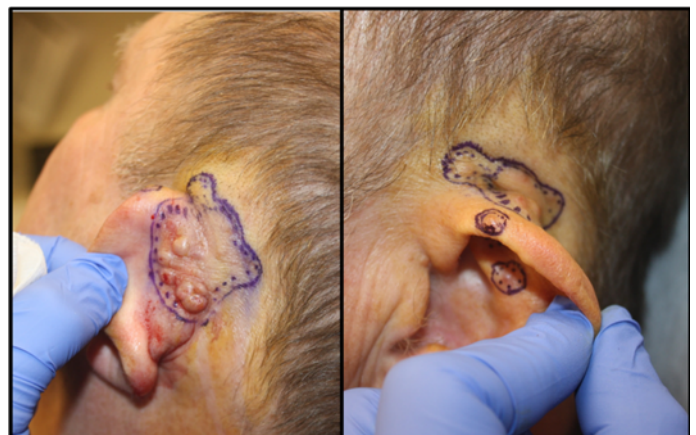


Figure 1. Pink-red papulonodules noted in the left ear and postauricular sulcus on initial presentation of the patient.

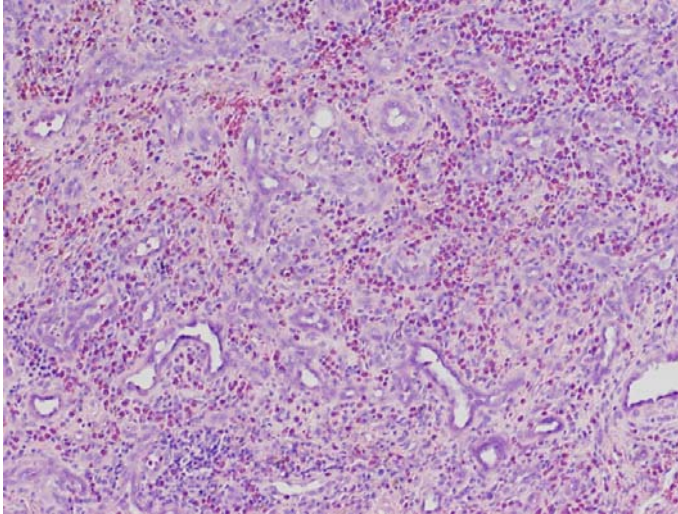


Figure 2. Hematoxylin and eosin stain consistent with angiolymphoid hyperplasia with eosinophilia.

inflammatory infiltrate of plasma cells, lymphocytes, and numerous eosinophils was noted. The pathologic diagnosis was angiolymphoid hyperplasia with eosinophilia (ALHE).

Owing to enlargement and symptoms the patient opted for treatment. After discussing options, the patient elected to proceed with surgical resection. Mohs micrographic surgery (MMS) was suggested as potential way to avoid recurrence. At surgery the patient presented with a deeply seated, multi-lobulated mass behind the left ear. In two foci, papules had penetrated through the triangular fossa to the anterior ear.

A first stage of MMS was carried out to the fascia. The lesion was grossly transected and visualized as a semi-encapsulated worm-like mass. Histology of the

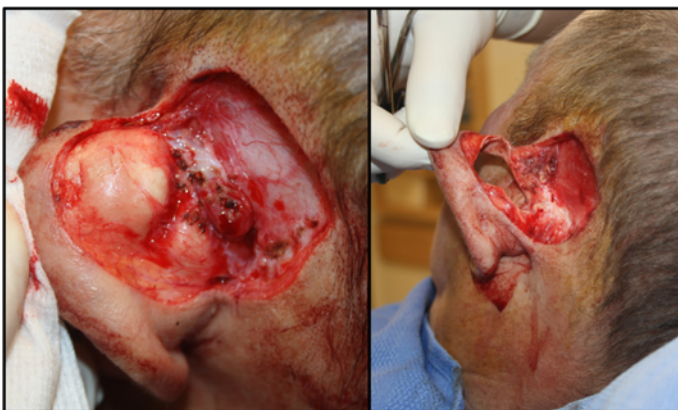


Figure 3. Intra-operative photo showing residual foci of angiolymphoid hyperplasia with eosinophilia deeply seated into the postauricular sulcus.

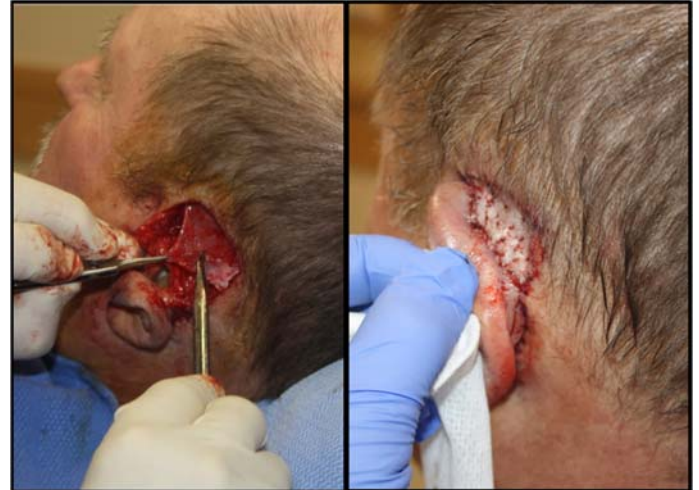

Figure 4. Reconstruction completed with a temporalis fascia flap and a full-thickness skin graft.

first stage revealed nodular aggregates of vessels with dense inflammation characterized by numerous eosinophils. A second stage of MMS was carried out deeply into the postauricular sulcus. The lesion was seen visibly tracking down a posterior superior auricular artery and through two small foramina in the cartilage of the triangular fossa (**Figure 3**). A third stage of MMS removed all large vessel involvement and created a transmural wound of the ear. Although all peripheral margins and larger vessels had been cleared, the deep bed of the wound still contained widely-scattered tiny foci of inflammation. Given that ALHE is benign and that further resection would have been highly-disfiguring, MMS was halted. The ear was reconstructed with a temporalis fascia flap and a full-thickness skin graft (**Figure 4**). At one year the patient healed well and was symptom and recurrence free (**Figure 5**).

Case Discussion

Angiolymphoid hyperplasia with eosinophilia has an unclear etiology hypothesized to be related to trauma, elevated estrogen levels, or arteriovenous shunting given presence of mural damage of large vessels in some patients [1, 2]. Angiolymphoid hyperplasia with eosinophilia occurs primarily in middle-aged adults with an Asian racial predilection [3]. Approximately 82% of cases occur on the head and neck [3]. Angiolymphoid hyperplasia with eosinophilia may present with itching (36%),

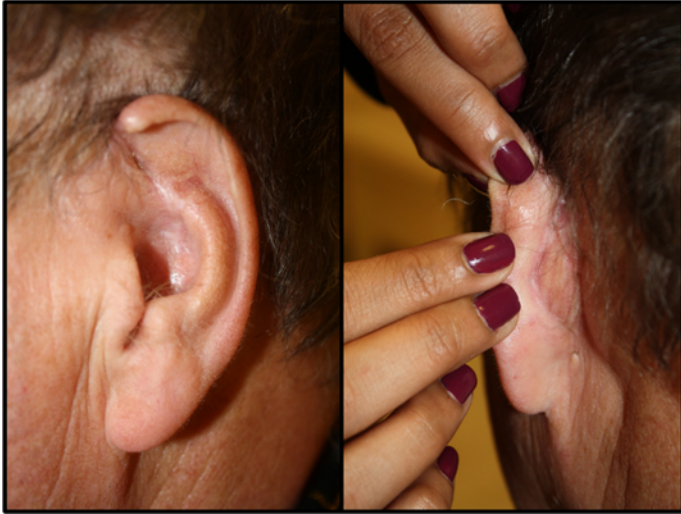

Figure 5. The patient remains symptom and disease free at one year follow up.

bleeding (25%), and pain (20%), [3]. The differential diagnosis of ALHE includes lymphoma cutis, sarcoidosis, basal cell carcinoma, Merkel cell carcinoma, angiosarcoma, or metastasis [3, 4].

Angiolymphoid hyperplasia with eosinophilia is characterized histologically by well-circumscribed lobular proliferations in the dermis and subcutaneous tissue [2, 4]. The proliferations include capillary-sized vessels surrounding larger central blood vessels [2]. The vessels in ALHE are typified by a “hobnail” or cobblestone appearance formed by the protrusion of large endothelial cells into the lumen of the vessel [2]. Between and among these vessels is a dense mixed inflammatory infiltrate with lymphocytes and predominant eosinophils, and may include mast cells and plasma cells [2].

A myriad of treatment modalities have been reviewed in the literature for ALHE. A review including 908 cases of ALHE found that treatment failure, defined by the authors as incomplete resolution or recurrence after treatment, was 40.8%

with excision, 50.0% with pulsed dye laser, 54.6% with carbon dioxide laser, and 66.7% with argon laser [3]. The treatment modalities with the highest failure rates were intralesional corticosteroids (79.1%), cryotherapy (80.5%), systemic corticosteroids (87.8%), and topical corticosteroids (98.2%), [3]. Clearly, the most common and effective treatment remains standard surgical excision, which was used in 44.2% of these cases with a failure rate of 40.8% [3]. There is a single case report of MMS being used successfully to treat a patient with ALHE with no recurrence at eight months [5].

The high rate of failure in the cases treated with surgical excision can be explained by difficulty in identifying margins in what is a complex branching vascular proliferation. These findings suggest MMS could be a more definitive treatment for ALHE. The extensive growth pattern found in our case of ALHE suggests why simple excision may not be curative. Interestingly, although we left scattered, multifocal microscopic disease, our patient has not experienced recurrence. Since the natural history of ALHE is poorly understood we will follow him clinically for at least five years.

Conclusion

This case is presented to demonstrate that MMS may be used to map out and resect ALHE and that the extent of disease may be striking. Our case also suggests that complete microscopic cure may not be essential but long term follow up of our patient will be necessary.

Potential conflicts of interest

The authors declare no conflicts of interests

References

1. Fontana SC, Borgstadt A, Fraga GR, Reeves AR, Andrews BT. Angiolymphoid Hyperplasia With Eosinophilia Within a Vascular Malformation: Case Report and Review of the Literature. *Ann Otol Rhinol Laryngol.* 2016;125:775-8. [PMID: 27141028].
2. Guo R, Gavino AC. Angiolymphoid hyperplasia with eosinophilia. *Arch Pathol Lab Med.* 2015;139:683-6. [PMID: 25927152].
3. Adler B, Krausz A, Minuti A, Silverberg J, Lev-Tov H. Epidemiology and treatment of angiolymphoid hyperplasia with eosinophilia (ALHE): A systematic review. *J Am Acad Dermatol.* 2016;74:506-512.e11. [PMID: 26685720].
4. North P, Kincannon J. Vascular Neoplasm and Neoplastic-like Proliferations. In: Bologna J, Jorizzo J, Schaffer J, ed. *Dermatology.* 3rd ed. Elsevier; 2012. p. 1920-1921.
5. Miller C, Ioffreda M, Ammirati C. Mohs Micrographic Surgery for Angiolymphoid Hyperplasia with Eosinophilia. *Dermatol Surg.* 2004;30:1169-1173. [PMID: 15274714].