

UC Davis

Dermatology Online Journal

Title

Hidradenitis suppurativa associated with sorafenib initiation

Permalink

<https://escholarship.org/uc/item/1s2016td>

Journal

Dermatology Online Journal, 25(6)

Authors

Morse, Daniel C
Chockalingam, Ramya
Pye, Allison
et al.

Publication Date

2019

DOI

10.5070/D3256044496

Copyright Information

Copyright 2019 by the author(s). This work is made available under the terms of a Creative Commons Attribution-NonCommercial-NoDerivatives License, available at <https://creativecommons.org/licenses/by-nc-nd/4.0/>

Peer reviewed

Hidradenitis suppurativa associated with sorafenib initiation

Daniel C Morse¹ MD, Ramya Chockalingam¹ MD, Allison Pye¹ MD, Auris Huen² MD

Affiliations: ¹Department of Dermatology, McGovern School of Medicine at the University of Texas Health Sciences Center at Houston, Houston, Texas, USA, ²Department of Dermatology, The University of Texas MD Anderson Cancer Center, Houston, Texas, USA

Corresponding Author: Auris Huen MD, Department of Dermatology, The University of Texas MD Anderson Cancer Center, 1515 Holcombe Boulevard, Houston, Texas 77030, Tel: 713-798-0190, Email: aohuen@mdanderson.org

Abstract

Sorafenib is a multi-kinase inhibitor approved for the treatment of renal cell and hepatocellular carcinoma. Adverse cutaneous reactions are a very common side effect of the medication. We report the development of hidradenitis suppurativa (HS) in a patient after initiation of treatment with sorafenib. HS is marked by recurrent deep painful nodules, fluctuant abscesses, and draining sinus tracts most frequently occurring in the groin and axilla. To our knowledge, sorafenib-induced HS in the axillary and inguinal skin folds has not been previously reported.

Keywords: hidradenitis suppurativa, sorafenib, drug induced hidradenitis suppurativa

Introduction

Sorafenib inhibits a variety of tyrosine kinase receptors responsible for tumor cell proliferation and angiogenesis. The medication has been approved for the treatment of advanced hepatocellular carcinoma and renal cell carcinoma but has also been shown to be effective in treating various other cancers including thyroid cancer [1]. Adverse cutaneous reactions occur in nearly 90% of sorafenib treated patients [2]. As both the antitumor efficacy and incidence of skin toxicity of sorafenib are dose dependent, the development of skin toxicity parallels the antitumor effectiveness of the medication [3].

The most frequent adverse cutaneous reaction is a hand-foot-skin reaction, which has been reported in

different series to occur in 21%-93% of patients on sorafenib [2, 4]. Other cutaneous reactions include the development of an erythematous rash on the scalp and face occurring in 63% of patients, subungual splinter hemorrhages (70%), scalp dysesthesia (49%), alopecia (4%-57%), pruritus (4%-32%), xerosis (6%-27%), and skin follicular hyperkeratosis (21%), [2, 4]. Reports of less common cutaneous reactions have included skin neoplasms, areolar hyperkeratosis, eruptive nevi, and psoriasiform rashes [4]. Herein, we present a patient that developed hidradenitis suppurativa (HS) after initiation of sorafenib.

Case Synopsis

A 33-year-old man on sorafenib for papillary thyroid cancer presented for evaluation of "boils" that began when he initiated chemotherapy 5 years prior and had continued to progress. The patient denied a history of similar lesions prior to the onset of sorafenib. Examination revealed multiple erythematous, violaceous papules and pustules, as well as draining sinus tracts in the bilateral axillae and inguinal region, consistent with HS (**Figure 1**). He was treated with doxycycline and hydrocortisone 2.5% cream and treatment with sorafenib was held. After the sorafenib was discontinued, the patient noted marked improvement in his lesions and after a month stopped treatment with doxycycline and hydrocortisone. The patient's HS continued to improve on the chemotherapy drug holiday despite no ongoing topical treatment. Six months after discontinuing sorafenib, no axillary sinus tracts remained and only mild scarring was noted.

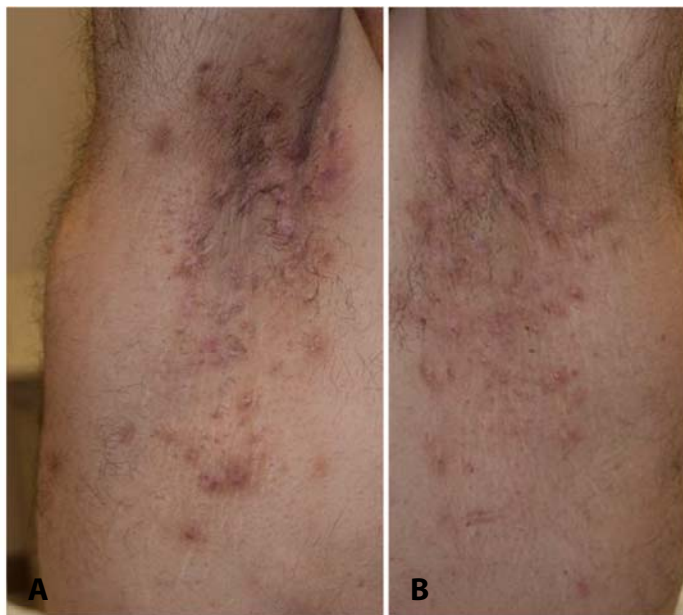


Figure 1. A) Right axillary nodules, abscesses, and sinus tract. **B)** Left axillary nodules, abscesses, and sinus tract formation.

Case Discussion

The clear temporal association between the development of HS lesions upon sorafenib initiation and the improvement upon cessation of the drug, suggests that our patient's HS was triggered by sorafenib. Classic HS within the skin folds of the axilla and groin has not been previously associated with sorafenib. Pichler et al., reported a case of an acne inversa-like lesion on the leg after initiation of sorafenib, which improved with lowering the dose of sorafenib in combination with topical antibiotics [5]. Although the lesion reported by Pichler et al. was considered to be acne inversa-like, we describe a presentation that matches the characteristic description of HS with abscesses and draining sinus tracts in the axilla and groin.

The mechanisms behind sorafenib-induced cutaneous toxicities remain unclear but have been associated with blockade of PDGF and KIT in the

eccrine gland epithelium and antagonism of VEGFRs in subcutaneous vessels, which may lead to impaired cutaneous regeneration and healing [2]. Hyperkeratinization of the follicle infundibulum is believed to play a central role [6]. A study by Frank et al. found that out of 43 patients on sorafenib, 9 (21%) developed spiny 1mm papules on the face, scalp, and trunk, which they termed as "spiny follicular hyperkeratosis" [7]. Histologic examination of these lesions revealed an infundibulum filled with an orthoparakeratotic column, which extended above the epidermal surface [7].

Sorafenib has been shown to cause alterations in the keratinocyte differentiation and proliferation pathways and has been associated with cyst formation [8]. Cases of follicular hyperplasia [9], perforating folliculitis [10-12], a keratosis pilaris-like reaction [13], and a nodular cystic eruption [14] have also been reported. Interestingly, sorafenib induced keratinocyte proliferation and follicular cyst formation have been linked to paradoxical activation of the MAP kinase pathway [8]. It is likely that the keratinocyte proliferating effects of sorafenib contributed to the development of the follicular cystic lesions in our patient.

Conclusion

To our knowledge this is first description of sorafenib associated HS in the axillary and inguinal skin folds. We encourage clinicians to be aware of the potential correlation between sorafenib and HS and recommend further studies to explore this association. Awareness of this association between sorafenib and HS will expediate future diagnosis and management.

Potential conflicts of interest

The authors declare no conflicts of interests.

References

1. White PT, Cohen MS. The discovery and development of sorafenib for the treatment of thyroid cancer. *Expert Opin Drug Discov.* 2015;10:427-439. [PMID: 25662396].
2. Zhang L, Zhou Q, Ma L, Wu Z, Wang Y. Meta-analysis of dermatological toxicities associated with sorafenib. *Clin Exp Dermatol.* 2011;36:344-350. [PMID: 21507035].

3. Vincenzi B, Santini D, Russo A, et al. Early skin toxicity as a predictive factor for tumor control in hepatocellular carcinoma patients treated with sorafenib. *Oncologist*. 2010;15:85-92. [PMID: 20051477].
4. Ara M, Pastushenko E. Antiangiogenic agents and the skin: Cutaneous adverse effects of sorafenib, sunitinib, and bevacizumab. *Actas Dermosifiliogr*. 2014;105:900-912. [PMID: 24766821].
5. Pichler M, Carriere C, Mazzoleni G, Kluge R, Eisendle K. Acne inversa-like lesions associated with the multi-kinase inhibitor sorafenib. *Clin Exp Dermatol*. 2014;39:232-233. [PMID: 24330088].
6. Smith MK, Nicholson CL, Parks-Miller A, Hamzavi IH. Hidradenitis suppurativa: An update on connecting the tracts. *F1000Res*. 2017;6:1272. [PMID: 28794864].
7. Franck N, Barete S, Moguelet P, et al. Spiny follicular hyperkeratosis eruption: A new cutaneous adverse effect of sorafenib. *J Clin Oncol*. 2010;28:e640-2. [PMID: 20855839].
8. Arnault JP, Mateus C, Escudier B, et al. Skin tumors induced by sorafenib; paradoxical RAS-RAF pathway activation and oncogenic mutations of HRAS, TP53, and TGFBR1. *Clin Cancer Res*. 2012;18:263-272. [PMID: 22096025].
9. Lopez V, Pinazo I, Marti N, Monteagudo C, Jorda E. Follicular hyperplasia on the face subsequent to therapy with sorafenib. A new skin side effect. *J Eur Acad Dermatol Venereol*. 2009;23:959-960. [PMID: 18785888].
10. Wolber C, Udvardi A, Tatzreiter G, Schneeberger A, Volc-Platzer B. Perforating folliculitis, angioedema, hand-foot syndrome--multiple cutaneous side effects in a patient treated with sorafenib. *J Dtsch Dermatol Ges*. 2009;7:449-452. [PMID: 19178612].
11. Batalla A, Menendez L, Blay P, Curto JR. Delayed onset perforating folliculitis associated with sorafenib. *Australas J Dermatol*. 2014;55:233-235. [PMID: 25117168].
12. Minami-Hori M, Ishida-Yamamoto A, Komatsu S, Iiduka H. Transient perforating folliculitis induced by sorafenib. *J Dermatol*. 2010;37:833-834. [PMID: 20883372].
13. Kong HH, Turner ML. Array of cutaneous adverse effects associated with sorafenib. *J Am Acad Dermatol*. 2009;61:360-361. [PMID: 19615549].
14. Borgia F, Saitta C, Vaccaro M, Franze MS, Lentini M, Cannavo SP. Nodular-cystic eruption in course of sorafenib administration for hepatocarcinoma: An unconventional skin reaction requiring unconventional treatment. *Int J Immunopathol Pharmacol*. 2017;30:327-331. [PMID: 28825507].