

# UC Irvine

## UC Irvine Previously Published Works

### Title

Infected thyroglossal duct cyst.

### Permalink

<https://escholarship.org/uc/item/1qp7b988>

### Journal

Western Journal of Emergency Medicine, 10(3)

### ISSN

1936-900X

### Authors

Deaver, Mark J  
Silman, Eric F  
Lotfipour, Shahram

### Publication Date

2009-08-01

### Copyright Information

This work is made available under the terms of a Creative Commons Attribution License, available at <https://creativecommons.org/licenses/by/4.0/>

Peer reviewed

# Infected Thyroglossal Duct Cyst

Mark J. Deaver, MD, MBA\*

Eric F. Silman, MD†

Shahram Lotfipour, MD, MPH‡

\* Harbor-University of California, Los Angeles, Department of Emergency Medicine

† University of California, San Francisco, Department of Emergency Medicine

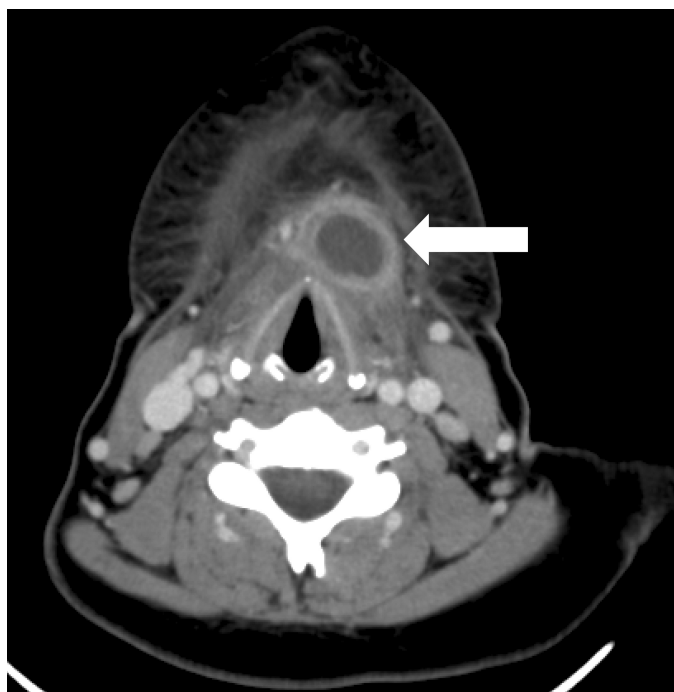
‡ University of California, Irvine School of Medicine, Department of Emergency Medicine, Orange, CA

Supervising Section Editor: Rick A McPheeters, DO

Submission history: Submitted June 26, 2008; Revision Received July 29, 2008; Accepted August 01, 2008

Reprints available through open access at [www.westjem.org](http://www.westjem.org)

[WestJEM. 2009;10:205.]



**Figure.** CT of the neck with contrast showing an enhancing, well-circumscribed lesion located in the anterior neck at the level of the thyroid cartilage.

A 23-year-old female presented to the emergency department (ED) with a five-day history of sore throat, body aches and 24 hours of throat swelling accompanied by globus sensation and hoarseness. The patient was afebrile with normal vital signs. Physical exam was significant for a firm, non-erythematous anterior neck mass that was exquisitely tender to palpation. The mass was noted to move slightly with swallowing. A CT scan with contrast revealed a 2 x 2.5 x 3 cm cystic lesion with a thick, enhancing rim located inferior to the hyoid bone with overlying soft tissue swelling. Given the history and radiographic appearance of the lesion, a diagnosis of infected thyroglossal duct cyst was made. The patient was started on Clindamycin in the ED and admitted to ENT for needle aspiration and 23-hour observation.

Thyroglossal duct cysts (TGDC) are the most common cause of midline neck masses.<sup>1</sup> TGDC are typically located inferior to the hyoid bone (65%) in the region adjacent to the thyrohyoid membrane.<sup>2</sup> However, these remnants can occur anywhere along the path followed by the primordial thyroid gland during descent from the base of the tongue. Frequently presenting as an asymptomatic neck mass in the pediatric population, the most common presentation in adults is underlying infection of the cyst.<sup>1</sup> Other common causes of midline neck masses include lymphadenopathy, dermoid cysts, and various odontogenic anomalies. Classic physical exam findings include a mobile neck mass that moves with swallowing or protrusion of the tongue. Accompanying symptoms include sore throat, pain, dysphagia, hoarseness, and globus. Serious complications involve airway obstruction precipitated by rapid enlargement of the cyst. Findings on CT include a well-circumscribed lesion with significant rim enhancement.<sup>3</sup>

Definitive treatment of infected TGDC involves both antibiotics and needle aspiration. Examination of the aspirate allows for identification of the involved organisms as well as cytologic analysis to rule out underlying TGDC carcinoma. The most common organisms involved include *Staphylococcus epidermidis*, *Haemophilus influenza*, and *Staphylococcus aureus*.<sup>3</sup> Following control of the underlying infection, the patient may elect to surgically remove the cyst to prevent further recurrence.

*Address for Correspondence:* Shahram Lotfipour, MD, MPH, Associate Clinical Professor, 101 The City Drive, Rte 128-01, Orange, CA 92868. Email: [SHL@uci.edu](mailto:SHL@uci.edu)

## REFERENCES

1. Acierno S, Waldhausen J. Congenital Cervical Cysts, Sinuses and Fistulae. *Otolaryngol Clin N Am*. 2007; 40:161-176.
2. Batsakis JG. Tumors of the head and neck: clinical and pathological considerations. 2nd ed. Baltimore: Williams & Wilkins; 1979:233-239.
3. Reede D, Bergeron R, Som P. CT of Thyroglossal Duct Cysts. *Radiology*. 1985; 157:121-125.