

UC Irvine

UC Irvine Previously Published Works

Title

The Rabbit Costal Cartilage Reconstructive Surgical Model

Permalink

<https://escholarship.org/uc/item/1q46d1kj>

Journal

Facial Plastic Surgery, 30(01)

ISSN

0736-6825

Authors

Badran, Karam W

Waki, Curt

Hamamoto, Ashley

et al.

Publication Date

2014-02-01

DOI

10.1055/s-0033-1363754

Copyright Information

This work is made available under the terms of a Creative Commons Attribution License, available at <https://creativecommons.org/licenses/by/4.0/>

Peer reviewed

Published in final edited form as:

Facial Plast Surg. 2014 February ; 30(1): 76–80. doi:10.1055/s-0033-1363754.

The Rabbit Costal Cartilage Reconstructive Surgical Model

Karam W. Badran, BSc¹, Curt Waki, BSc¹, Ashley Hamamoto, BSc¹, Ryan Manz, MD², and Brian J. F. Wong, MD, PhD^{1,2}

¹ Beckman Laser Institute and Medical Clinic, University of California-Irvine, Irvine, California

² Division of Facial Plastic Surgery, Department of Otolaryngology -Head and Neck Surgery, University of California-Irvine, Orange, California

Abstract

Rib grafts in facial plastic surgery are becoming more frequently used. Small animal models, although not ideal may be used to emulate costal cartilage-based procedures. A surgical characterization of this tissue will assist future research in the selection of appropriate costal segments, based on quantitative and qualitative properties. The objective of this study is to assess the surgical anatomy of the rabbit costal margin and evaluate costal cartilage for use in either in vivo or ex vivo studies and to examine reconstructive procedures. Detailed thoracic dissections of 21 New Zealand white rabbits were performed post-mortem. Costal cartilage of true, false, and floating ribs were harvested. The length, thickness, and width at proximal, medial, and distal locations of the cartilage, with perichondrium intact were measured. Further qualitative observation and digital images of curvature, flexibility, and segmental cross-sectional shape were recorded. The main outcome measure(s) is to characterize, describe, and assess the consistency of dimensions, location, and shape of costal cartilage. In this study, 12 to 13 ribs encase the thoracic cavity. Cartilage from true ribs has an average length, width, and depth of 23.75 ± 0.662 , 3.02 ± 0.025 , and 2.18 ± 0.018 mm, respectively. The cartilage from false ribs has an average length, width, and depth of 41.97 ± 1.48 , 2.00 ± 0.07 , 1.19 ± 0.03 mm, and that of floating ribs are 7.66 ± 0.29 , 1.98 ± 0.04 , and 0.96 ± 0.03 mm. Rib 8 is found to be the longest costal cartilage (49.10 ± 0.64 mm), with the widest and thickest at ribs 1 (3.91 ± 0.08 mm) and 6 (2.41 ± 0.11 mm), respectively. Cross-sectional segments reveal the distal cartilage to maintain an hourglass shape that broadens to become circular and eventually ovoid at the costochondral junction. The New Zealand white rabbit is a practical source of costal cartilage that is of sufficient size and reproducibility to use in surgical research where the long-term effects of operations, therapies, devices, and pharmacologic on cartilage can be studied in vivo.

Keywords

costal cartilage; rabbit costal cartilage; cartilage graft; cartilage length; cartilage volume; animal model for facial surgery

Cartilage grafts obtained from the costal margin are frequently used in facial reconstruction providing durable bulk with minimal resorption as this source provides a large reservoir of accessible cartilage.¹⁻⁴ To evaluate new technologies, pharmacologic, and biomedical devices aimed at treating or modifying costal cartilage, studies often require long-term, metabolically active in vivo tissue investigations. Animal trials therefore are necessary for the assessment of long-term tissue behavior, analysis of injury, and in vivo clinical validity of an emerging technology. Although a variety of animal models exist for facial surgery, one must make selections based on characteristics that are similar to the object of previous experimentation and that at least grossly approximates what can be expected in humans.⁵

Although cartilage may be found in many locations, the most abundant source of utilizable cartilage is the rib cage. Although all mammals have costal cartilage, as ex vivo surgical models, porcine and bovine costal cartilage most closely mimic their human counterparts in terms of their ability to be carved, sutured, and reshaped with form factor grossly approximating that of humans, and are ideal for training surgeons how to cut and shape grafts. In vivo studies utilizing large mammals, however, are not always practical due to the substantial costs, and survival studies are a logistic and economic challenge. Medium-sized animals, in contrast, are more practical alternative to mimic costal cartilage-based procedures, particularly to evaluate new instrumentation, pharmaceuticals, or tissue engineered technologies, however, they are accompanied with increasing ethical concerns.⁶ As dogs and cats are domestic, companion animals, biomedical ethics and negative public perception have limited their use in medical research, hence attention has been focused on the rabbit as an appropriate medium-sized animal.^{7,8}

The New Zealand white rabbit (*Oryctolagus cuniculus*) is well established as a viable model for the development and validation of novel reconstructive surgical techniques in a variety of surgical fields including craniomaxillofacial surgery and rhinoplasty with the use of rabbit septum.⁹⁻¹¹ Despite the prevalence of in vivo and ex vivo studies, the surgical anatomy of the rabbit costal cartilage for reconstructive studies has yet to be characterized.

Rabbit Anatomy

Similar to humans, the rabbit rib cage is a bony cartilaginous structure that encases the thoracic cavity. Supporting the pectoral girdle, the thoracic cage also provides attachments to the muscles of the head, neck, thorax, and abdomen. New Zealand white rabbits have been found to have 12 or 13 ribs based on the individual's genetic makeup.¹² On the basis of their anterior attachment, as described in humans, ribs are classified into three types: true, false, and floating.¹³ Ribs 1 to 7 comprise the true ribs, articulating with the sternum at synovial sternocostal joints. The false ribs, numbers 8 to 10, articulate anteriorly with the costal cartilages of the adjacent superior rib pair. The 11th, 12th, and, if available, 13th rib pairs are floating ribs and do not articulate anteriorly.

Methods

Detailed thoracic dissections of 21 freshly euthanized New Zealand white rabbits from the Institutional Animal Care and Use Committee approved protocols were performed, weighing

3.9 to 4.1 kg and aged 14 to 16 weeks. Reflecting skin, pectoralis muscles, and rectus abdominis, careful exposure of the anterior rib cage and costal margin from the xiphoid process to the posterolateral aspect of the thorax was performed.

Anatomic Measurements

Costal cartilage, bounded by sternum and costochondral junction, was harvested and classified as true, false, or floating ribs. The length (measured medial to lateral), width (measured superior to inferior), and depth (measured anterior to posterior) of costal cartilage were recorded at proximal, medial, and distal locations, with perichondrium intact (Fig. 1). Calculating the product of the three dimensions recorded approximated the volume of each costal cartilage segment.

Qualitative Observations

Each costal cartilage level was divided at 2-mm intervals to assess the curvature and cross-sectional geometry of the tissue (Fig. 2). Subjective assessment of resistance to dorsal-ventral flexion was noted following excision of costal cartilage tissue.

Results

Anatomic Findings

Cartilage from the true ribs has an average length, width, and depth of 23.75 ± 0.66 , 3.02 ± 0.03 , and 2.18 ± 0.018 mm, respectively. The cartilage from false ribs has an average length, width, and depth of 41.97 ± 1.48 , 2.00 ± 0.07 , and 1.19 ± 0.03 mm, and that of floating ribs are 7.66 ± 0.29 , 1.98 ± 0.04 , and 0.96 ± 0.03 mm. Rib 8 is found to be the longest costal cartilage (49.10 ± 0.64 mm), with the widest and thickest at ribs 1 (3.91 ± 0.08 mm) and 6 (2.41 ± 0.11 mm), respectively. Rib 7 contains the greatest amount of cartilage by volume at 327.81 mm^3 . All quantitative data, including volumetric estimation, are compiled and presented in Tables 1 and 2 and Fig. 3.

Qualitative Observation

Cross-sectional cartilage segments beginning medially reveal an hourglass shape that broadens to become circular and eventually ovoid at the costochondral junction. Contributing to this geometry is the increasingly linear portions of costal cartilage when beginning with the medial border that increasingly delay a point of inflection when progressing inferiorly. Progressing in a similar fashion, costal cartilage is more amenable to flexure as one advances caudally.

Discussion

Used as a large source of rigid, yet easily contoured tissue, costal cartilage has long been used for grafting in the hands of surgeons.¹ Although resorption rates have been shown to be low,^{9,14} its tendency to warp can complicate ideal results. Various techniques have shown that the selection of appropriate costal cartilage segments will minimize these adverse effects; namely, the selection of segments that contains large cross sections of centrally located tissue.^{15,16} Used widely in secondary rhinoplasty operations, merging technologies

and therapeutics along with innovative surgical procedures are being developed to expand the use of this tissue, and better prepare it for use in the head and neck.¹⁷⁻¹⁹ Clinical studies on the use of costal cartilage have grown exponentially.^{17,20,21} Accordingly, research on costal cartilage dynamics increased as well.²¹⁻²⁴

With the related costs of care, feeding, and management for larger animals and a relatively large amount of tissue as specimen, in vivo studies on costal cartilage have largely used the medium-sized, New Zealand white rabbit for research. To better guide investigators in the selection and utilization of the appropriate costal cartilage segment, a characterization of this tissue in the rabbit model is necessary.

This study demonstrates that the New Zealand white rabbit has ample costal cartilage for in vivo and ex vivo reconstructive experimentation. In assessing the rib cage, the costal cartilage progressively grows in length until reaching a maximum length of 49.10 ± 0.644 mm. The false ribs then decrease in size, Fig. 3. The calculated volume in each cartilaginous segment mimics the trend seen with length, while depth and width measurements remain consistent for each of the true, false, and floating ribs.

The consistency of measurements, as calculated by the standard error of the mean can be largely attributed to the similarity in age and weights of the rabbits used. Remaining variance, as Masoud et al investigated, can be contributed to skeletal development that is more accurately assessed by body length than weight.²⁵ Variance in subjectivity of flexion may also be present as rib cartilage has a tendency to calcify with age.²⁶ Despite minor variation in previously studied subjective qualities,^{25,26} the results described demonstrate reproducible tissue characteristics, with the potential for broad application to the New Zealand white rabbit population.

Although our results aid future animal model reconstructive studies, further longitudinal growth data on body weight and length in relation to costal cartilage dimensions would allow for more precisely timed interventions. Furthermore, a quantitative approach in the assessment of tissue resistance to flexure would better characterize this property. A technique used by Oliaei et al has demonstrated that an integrated elastic modulus can be calculated through the measurement of displacement and reactive force produced following specimen mechanical deformation.²⁷ These recommendations would more accurately characterize costal cartilage properties in future experimental investigations.

Conclusion

The New Zealand white rabbit proves to be an excellent, inexpensive source of costal cartilage appropriate for reshaping in in vivo studies. Although this animal model has been extensively used as a surgical model in facial plastic surgery, little has been done to characterize or describe its costal rib cartilage. The consistency of measurements across a large sample size demonstrates the reproducible anatomy found in this animal model. Characterization of the dimensions, location, shape, and relative flexibility of costal cartilage will aid future studies aimed at better understanding the biology and physiology of costal cartilage graft behavior.

References

1. Horton CE, Matthews MS. Nasal reconstruction with autologous rib cartilage: a 43-year follow-up. *Plast Reconstr Surg.* 1992; 89(1):131–135. [PubMed: 1727245]
2. Kridel RW, Ashoori F, Liu ES, Hart CG. Long-term use and follow-up of irradiated homologous costal cartilage grafts in the nose. *Arch Facial Plast Surg.* 2009; 11(6):378–394. [PubMed: 19917899]
3. Sivayoham E, Woolford TJ. Current opinion on auricular reconstruction. *Curr Opin Otolaryngol Head Neck Surg.* 2012; 20(4):287–290. [PubMed: 22695626]
4. von Mangoldt H. Correction of saddlenose by cartilage transplant. *Gesell Chir.* 1900; 29:460–463.
5. Health N.I.o. [December 25, 2012] Medical Research with Animals. Apr 4. 2011 Available at: <http://science.education.nih.gov/animals>.
6. Calasans-Maia MD, Monteiro ML, Ascoli FO, Granjeiro JM. The rabbit as an animal model for experimental surgery. *Acta Cir Bras.* 2009; 24(4):325–328. [PubMed: 19705034]
7. Hasiwa N, Bailey J, Clausing P, et al. Critical evaluation of the use of dogs in biomedical research and testing in Europe. *ALTEX.* 2011; 28(4):326–340. [PubMed: 22130483]
8. Pearce AI, Richards RG, Milz S, Schneider E, Pearce SG. Animal models for implant biomaterial research in bone: a review. *Eur Cell Mater.* 2007; 13:1–10. [PubMed: 17334975]
9. Lattyak BV, Maas CS, Sykes JM. Dorsal onlay cartilage autografts: comparing resorption in a rabbit model. *Arch Facial Plast Surg.* 2003; 5(3):240–243. [PubMed: 12756118]
10. Hizal E, Buyuklu F, Ozer O, Cakmak O. Effects of different levels of crushing on the viability of rabbit costal and nasal septal cartilages. *Plast Reconstr Surg.* 2011; 128(5):1045–1051. [PubMed: 22030487]
11. Griffioen FM, Smit-Vis JH, Urbanus NA. Facial growth in the rabbit after autologous grafting in unilateral clefts. *Cleft Palate J.* 1988; 25(3):226–234. [PubMed: 3048791]
12. Green EL. The inheritance of a rib variation in the rabbit. *Anat Rec.* 1939; 74(1):47–60.
13. Leonard, RJ. *Human Gross Anatomy: An Outline Text.* Oxford University Press; Riverside: 1995. p. 452
14. Tjelmeland K, Stal S. Cartilage graft resorption: an animal model. *Aesthet Surg J.* 2000; 20(6): 471–476.
15. Lopez MA, Shah AR, Westine JG, O'Grady K, Toriumi DM. Analysis of the physical properties of costal cartilage in a porcine model. *Arch Facial Plast Surg.* 2007; 9(1):35–39. [PubMed: 17224486]
16. Spencer MG. Chondroplastic graft augmentation rhinoplasty. *J Laryngol Otol.* 1990; 104(7):539–543. [PubMed: 2384709]
17. Kim WS, Kim CH, Yoon JH. Premaxillary augmentation using autologous costal cartilage as an adjunct to rhinoplasty. *J Plast Reconstr Aesthet Surg.* 2010; 63(9):e686–e690. [PubMed: 20627762]
18. Manuel CT, Foulad A, Protsenko DE, Hamamoto A, Wong BJ. Electromechanical reshaping of costal cartilage grafts: a new surgical treatment modality. *Laryngoscope.* 2011; 121(9):1839–1842. [PubMed: 22024834]
19. Ching WC, Hsiao YC. Transumbilical Endoscopic Costal Cartilage Harvesting: A New Technique. *Ann Plast Surg.* 2012
20. Hassani E, Karimi H, Hassani A. Inferior encephalocele: transpalatal repair using paired costal bone grafts with a 14-year follow-up. *J Pediatr Surg.* 2011; 46(10):E9–E13. [PubMed: 22008362]
21. Piao Z, Takahara M, Harada M, et al. The response of costal cartilage to mechanical injury in mice. *Plast Reconstr Surg.* 2007; 119(3):830–836. [PubMed: 17312484]
22. Forman JL, de Dios EdIP, Kent RW. A pseudo-elastic effective material property representation of the costal cartilage for use in finite element models of the whole human body. *Traffic Inj Prev.* 2010; 11(6):613–622. [PubMed: 21128192]
23. Forman JL, Kent RW. Modeling costal cartilage using local material properties with consideration for gross heterogeneities. *J Biomech.* 2011; 44(5):910–916. [PubMed: 21168845]

24. Alkan Z, Yigit O, Acioglu E, et al. Tensile characteristics of costal and septal cartilages used as graft materials. *Arch Facial Plast Surg*. 2011; 13(5):322–326. [PubMed: 21931086]
25. Masoud I, Shapiro F, Kent R, Moses A. A longitudinal study of the growth of the New Zealand white rabbit: cumulative and biweekly incremental growth rates for body length, body weight, femoral length, and tibial length. *J Orthop Res*. 1986; 4(2):221–231. [PubMed: 3712130]
26. Allcroft RA, Friedman CD, Quatela VC. Cartilage grafts for head and neck augmentation and reconstruction. Autografts and homografts. *Otolaryngol Clin North Am*. 1994; 27(1):69–80. [PubMed: 8159428]
27. Oliaei S, Manuel C, Karam B, et al. In vivo electromechanical reshaping of ear cartilage in a rabbit model: a minimally invasive approach for otoplasty. *JAMA Facial Plast Surg*. 2013; 15(1):34–38. [PubMed: 23117484]

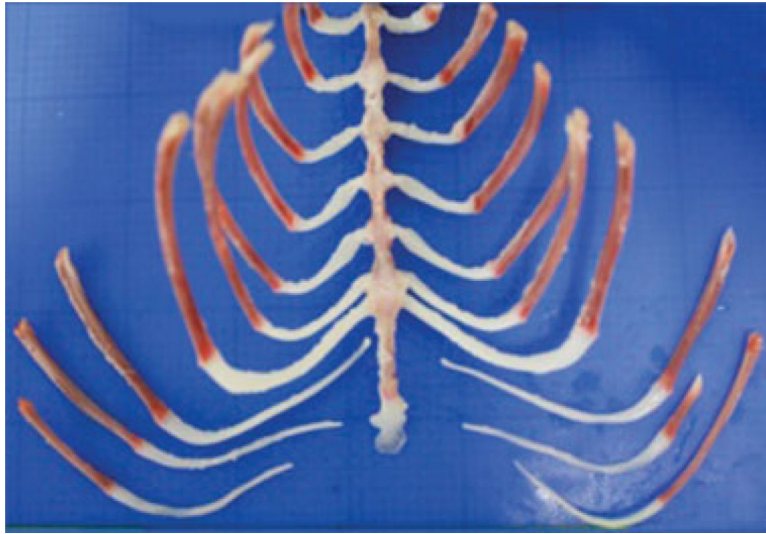


Fig. 1. Posterior view of the rabbit rib cage. Those attached to the sternum are true ribs. The remaining are false ribs.

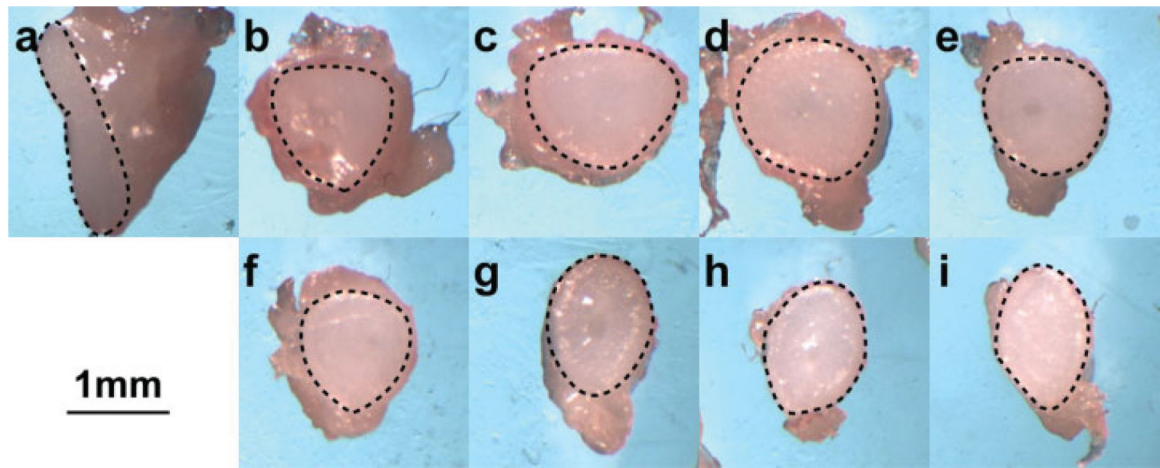


Fig. 2.
The medial surface of 2-mm interval cross sections of rib 6 is outlined with a dashed line.
Segment “a” begins at the costosternal junction and “f” terminates at the costochondral joint.

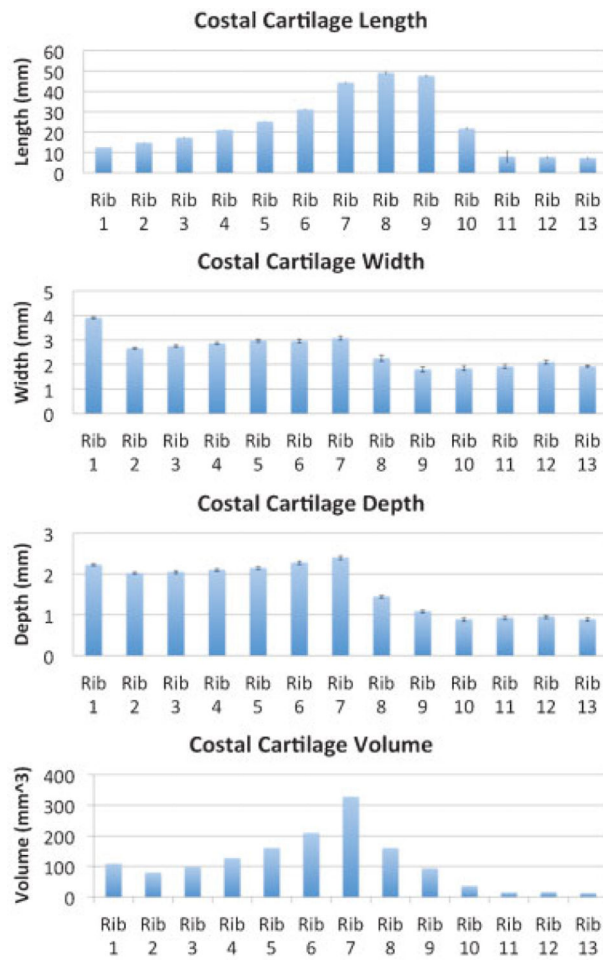


Fig. 3. Graphical representation of length, width, depth, and volume. Standard error of the mean is depicted by error bars atop each rib segment.

Table 1

Dimensions and volume for each costal cartilage segment

Rib segment	Length \pm standard error (mm)		Depth \pm standard error (mm)		Width \pm standard error (mm)		Volume (mm ³)
Rib 1	12.47	0.22	2.23	0.03	3.91	0.05	108.57
Rib 2	14.78	0.25	2.02	0.03	2.66	0.04	79.59
Rib 3	17.31	0.21	2.05	0.05	2.75	0.04	97.6
Rib 4	21.05	0.24	2.11	0.04	2.86	0.05	126.81
Rib 5	25.13	0.31	2.15	0.05	2.97	0.06	160.56
Rib 6	31.05	0.43	2.28	0.05	2.95	0.07	209.11
Rib 7	44.25	0.74	2.41	0.06	3.08	0.08	327.81
Rib 8	49.1	0.64	1.45	0.04	2.25	0.12	160.08
Rib 9	47.60	0.73	1.09	0.05	1.8	0.11	93.53
Rib 10	21.69	3.1	0.89	0.05	1.84	0.09	35.67
Rib 11	7.96	0.55	0.93	0.05	1.92	0.08	14.28
Rib 12	7.72	0.58	0.96	0.05	2.1	0.08	15.51
Rib 13	7.27	0.39	0.89	0.05	1.93	0.05	12.5

Table 2

Dimensions categorized by surgical anatomy

Rib segment	Length \pm standard error (mm)		Depth \pm standard error (mm)		Width \pm standard error (mm)	
True ribs (ribs 1–7)	23.72	0.66	2.18	0.02	3.02	0.03
False ribs (ribs 8–10)	41.89	1.47	1.19	0.03	2.0	0.07
Floating ribs (ribs 11–13)	7.65	0.29	0.93	0.03	1.98	0.04