

UCLA

UCLA Electronic Theses and Dissertations

Title

Differential assessment of skeletal, alveolar and dental components induced by microimplant-supported Midfacial Skeletal Expander (MSE), utilizing novel angular measurements from the fulcrum

Permalink

<https://escholarship.org/uc/item/1px2q3hz>

Author

Paredes Sampen, Ney Alberto

Publication Date

2020

Peer reviewed|Thesis/dissertation

UNIVERSITY OF CALIFORNIA

Los Angeles

Differential assessment of skeletal, alveolar and dental components induced by microimplant-supported Midfacial Skeletal Expander (MSE), utilizing novel angular measurements from the fulcrum

A thesis submitted in partial satisfaction of the requirements for the degree Master of Science
in Oral Biology

by

Ney Alberto Paredes Sampen

2020

© Copyright by

Ney Alberto Paredes Sampen

2020

ABSTRACT OF THE THESIS

Differential assessment of skeletal, alveolar and dental components induced by microimplant-supported Midfacial Skeletal Expander (MSE), utilizing novel angular measurements from the fulcrum

by

Ney Alberto Paredes Sampen

Master of Science in Oral Biology

University of California, Los Angeles, 2020

Professor Benjamin Wu, Chair

In order to assess skeletal expansion, alveolar bone bending and dental tipping after maxillary expansion, linear and angular measurements have been performed utilizing different craniofacial references. Since the expansion with Midfacial Skeletal Expander (MSE) is archial in nature, the aim of this paper is to quantify the differential components of MSE expansion by calculating the fulcrum locations and applying a novel angular measurement system.

Methods: Thirty-nine subjects with a mean age of 18.2 ± 4.2 years were treated with MSE. Pre- and post-expansion CBCT records were superimposed and compared. The rotational fulcrum of the zygomaticomaxillary complex was identified by localizing the interfrontal distance and modified interfrontal distance. Based on the fulcrum, a novel angular measurement method is presented and compared with a conventional linear method to assess changes of the zygomaticomaxillary complex, dentoalveolar bone, and maxillary first molars.

Results: From 39 patients, 20 subjects have the rotational fulcrum of the zygomaticomaxillary complex at the most distant points of the interfrontal distance (101.6 ± 4.7 mm) and 19 subjects at the most distant points of the modified interfrontal distance (98.9 ± 5.7 mm). Linear measurements accounted for 60.16% and 56.83% of skeletal expansion, 16.15% and 16.55% of alveolar bone bending, and 23.69% and 26.62% of dental tipping for right and left side. Angular measurements showed 96.58% and 95.44% of skeletal expansion, 0.34% and 0.33% alveolar bone bending and 3.08% and 4.23% of dental tipping for the right and left sides. The frontozygomatic, frontoalveolar and frontodental angles were not significantly different ($P > 0.05$).

Conclusions: In the coronal plane, the center of rotation for the zygomaticomaxillary complex was located at the most external and inferior point of the zygomatic process of the frontal bone or slightly above and parallel to the interfrontal distance. Due to the rotational displacement of the zygomaticomaxillary complex, angular measurements should be a preferred method for assessing the expansion effects, instead of the traditional linear measurement method.

The thesis of Ney Alberto Paredes Sampen is approved.

Renate Lux

Mallya Sanjay

Benjamin Wu, Committee Chair

University of California, Los Angeles

2020

TABLE OF CONTENT

1. ACKNOWLEDGEMENTS	Pg. IX
2. INTRODUCTION	Pg. 1
3. OBJECTIVE AND SPECIFIC AIMS	Pg. 3
4. DESIGN AND METHODOLOGY	Pg. 4
5. RESULTS	Pg.16
6. DISCUSSION	Pg.22
7. CONCLUSIONS	Pg. 31
8. FUTURE DIRECTIONS	Pg.32
9. REFERENCES	Pg. 34

LIST OF FIGURES AND TABLES

Fig. 1. Method use on CBCT to obtain the maxillomandibular bone width discrepancy.

Fig. 2 Method used in dental casts to project the extent of maxillary skeletal expansion required.

Fig. 3 Midfacial skeletal expander device and x-ray showing bicortical engagement of the four micro-implants.

Fig. 4. 3D Reconstruction of the maxillary sagittal plane (MSP) on the pre-expansion CBCT.

Fig. 5. A, 3D reconstruction of the Coronal zygomatic section on the pre-expansion CBCT; **B,** Pre-treatment and post-treatment superimposed image of an MSE patient in the coronal zygomatic section.

Fig 6. A. Interfrontal distance (IFD) and modified interfrontal distance (MIFD) as reference lines to determine rotational fulcrum; **B.** Pre-expansion measurements. **C.** Post-expansion measurements.

Fig 7. Measurement systems in the coronal zygomatic section. **A,** Angular measurement system; **B,** Linear measurement system

Fig 8. Diagram displaying the inaccuracy of using linear measurements in order to assess rotational pattern movement.

Fig 9. Superimposed 3D model of an MSE patient displaying the rotational pattern of the zygomaticomaxillary complex.

Table 1. Skeletal, alveolar bone and dental linear measurements

Table 2. Skeletal, alveolar bone and dental angular measurements

Table 3. Linear and angular treatment change measurements for each component

Table 4. Mean values of the total frontozygomatic, frontoalveolar and frontodental angles

ACKNOWLEDGEMENTS

I would like to start thanking all the people who collaborated in this research, offering their help and contributing to my professional growth. Particularly I want to thank Dr. Moon for his mentorship, guidance, advice and encouragement throughout the last three years. His innovative ideas and expertise in multiple disciplines has cultivated my personal and intellectual growth. I will forever be grateful and honored to have been mentored by him and had the opportunity to belong to the UCLA Orthodontic family. I would also like to thank Dr. Benjamin Wu for his unconditional support and direction during the last months and for accepting to be my PI. Finally, I want to thank Dr. Renate Lux and Dr. Mallya Sanjay, who I am honored to have had as committee members.

Additionally, I want to acknowledge all the members of Dr. Moon's lab, specially to Dr. Ozge Colak, Dr. Carolina Torres, Dr. Tam Duong, Dr. Luca Sfogliano, Dr. Islam El-Kenawy, Dr. Andrew Fraser, Dr. Boshi Zhang and Dr. Ausama Gargoum for their constant help and dedication with the past and ongoing researches. Finally, a big thank goes to the dental students Joseph Bui, Kody Kuo and Sara Jahangiri for their availability in helping with the tedious part of this project. Thanks to Mr. Matthew Dingman for handling the administrative work. Finally, I would like to acknowledge my family for their

financial support and unconditional love during my studies. I would not have made it this far without you.

INTRODUCTION

Maxillary transverse deficiency is probably one of the most common skeletal problems in the craniofacial region. Fortunately, the transverse dimension of maxilla may be the most malleable of the craniofacial complex.(1) Rapid palatal expansion (RPE) has been the preferred standard treatment when transverse deficit is present, especially in young patients. While the main goal of RPE is to split the midpalatal suture, the circum-maxillary sutures are also affected,(2) and bone bending and dental tipping are common.(3-6) The desire is to produce a greater skeletal effect than dentoalveolar side-effects; however, the latter are commonly expressed in substantive magnitude.

When RPE treatment is performed before the pubertal growth spurt, the skeletal expansion predominates over the dentoalveolar changes.(7) However, a significant alveolar bone bending and dental tipping cannot be ignored, even in these young population. Dentoalveolar changes are associated with decrease in alveolar bone height, fenestration, and bone dehiscence.(8) These negative effects escalate in mature patients because of the difficulty in splitting the heavily interlocked midpalatal suture with tooth-borne appliance. In order to overcome the undesired dentoalveolar effects of RPE, a variety of bone-borne or hybrid microimplant assisted rapid palatal expanders (MARPE) have been designed by many investigators.(9-19) In recent years, MARPE became popular in attempts to minimize the negative side-effects discussed above. These new breeds of expanders offered more bone anchor than the traditional tooth-borne RPE; however, the results varied significantly from one appliance to another because of the difference in appliance design and expansion protocols. Even with the bone anchor,

significant dentoalveolar changes have been reported in many MARPE studies.(11, 14-20) While a paper reported a negligible molar tipping,(21) others claimed that dental tipping and alveolar bone bending are not preventable but presented different percentage of dentoalveolar changes between RPE and MARPE.(9, 10)

Midfacial skeletal expander (MSE) is a particular type of MARPE which has been described in the literature since 2014.(12, 20-29) The impacts of appliance has been thoroughly studied and described in the recent years, and it has been successfully applied in mature patients.(12, 21, 28) Cantarella illustrated that the zygomaticomaxillary complex, along with its inferior structures, move in a downward and outward direction in the coronal plane with a fulcrum localized slightly above the frontozygomatic suture.(21)

In assessing percentages of skeletal, alveolar and dental components after maxillary expansion with RPE and MARPE, various linear measurements and angular measurements from arbitrary points were predominantly used.(8-19, 30) However, it has been demonstrated that the expansion is often archial in nature.(21) In that sense, linear distance measurements could produce false differential assessments when the expansion is rotational. Moreover, angular measurements would be more accurate if a true fulcrum can be located. The purpose of this study was to quantify the differential components of MSE expansion by calculating the fulcrum locations and applying a novel angular measurement system.

OBJECTIVE AND SPECIFIC AIMS

Objective:

The long-term goal of this study is to differentially assess the skeletal, alveolar and dental components induced by microimplant-supported Midfacial Skeletal Expander (MSE), utilizing novel angular measurements from the fulcrum.

Specific Aims:

The first aim of this paper is to present a novel angular measurement system that can properly represent the morphological changes occurring with the MSE expansion having as a reference the precise localization of the rotational fulcrum of the zygomaticomaxillary complex in the coronal plane.

The second aim of this study is to assess the skeletal, alveolar and dental components induced by microimplant-supported Midfacial Skeletal Expander, utilizing a novel angular measurement system from the fulcrum.

The third aim of this study is to compare the Midfacial Skeletal Expander outcomes by using the novel angular measurement system versus the traditional linear system.

DESIGN AND METHODOLOGY

This retrospective study was performed at the University of California at Los Angeles (UCLA) with approval by the ethics committee (IRB number 17-000567).

The pre- and post-expansion CBCT images from 39 patients (13 males, 26 females), successively treated with MSE (Biomaterials Korea, Seoul, Korea), with mean age of 18.2 ± 4.2 years (13.3 - 27.3), were obtained. All patients were diagnosed with maxillary transverse deficit: thirty-two patients with posterior crossbite (15 bilaterally and 17 unilaterally) and the other seven patients without crossbite. All patients were treated at the orthodontic clinic, UCLA School of Dentistry, under the supervision of one clinician. The orthodontic treatments with bonding of brackets and other appliances were carried out after the completion of MSE expansion and acquisition of post-expansion CBCT. The selection criteria included: (1) diagnosis of a transverse maxillary deficiency; (2) cases requiring MSE expansion as part of the overall treatment plan, (3) patient records with CBCT images obtained at 2 times: pretreatment and within 3 weeks after active expansion; (4) absence of any craniofacial irregularity, and (5) no orthodontic treatment precedent.

The transverse deficiency was diagnosed by relating the maxillary and mandibular bone width lines in coronal cuts from the initial CBCTs. The maxillary bone width was determined by the distance between the right and left bony points at the level of the mesiobuccal root tips of the upper first molars. Mandibular bone width was defined as the

distance between the right and left bony buccal surface at the level of lower first molar furcation. The maxillomandibular bone width discrepancy was obtained by subtracting mandibular bone width from the maxillary bone width. Ideally the maxillary width must be equal or greater than the mandibular width in order to obtain adequate transverse skeletal relationship and allow dental decompensation.

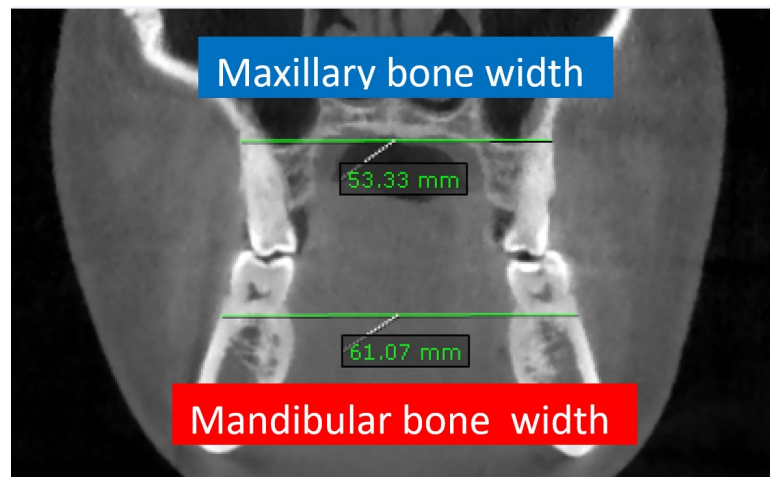


Fig 1. The maxillary bone width is determined by the distance between the right and left bony points at the level of the mesiobuccal root tips of the first molars. Mandibular bone width was defined as the distance between the right and left bony buccal surface at the level of the furcation of first molars. The maxillomandibular bone width discrepancy is obtained by subtracting mandibular bone width (61.07 mm.) from the maxillary bone width (53.33) = -7.74 mm.

Furthermore, in clinic and with dental casts, the maxillary width is determined by the distance between the right and left most concave points, lying on the maxillary vestibule above the mesiobuccal cusps of the first molars.(31) Mandibular width is defined as the distance between the right and left buccal surface over the furcation of first molars. The amount of difference among these values projects the extent of maxillary skeletal expansion required.

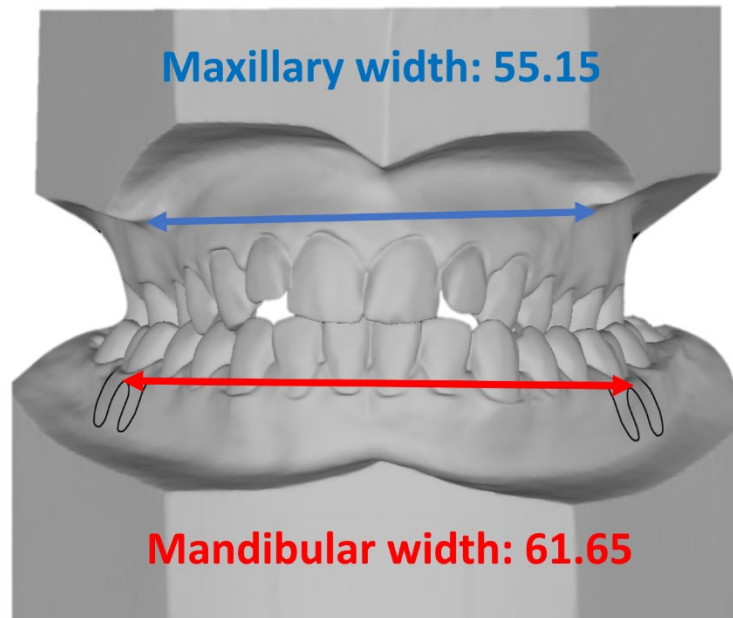


Fig 2. Method used in dental casts to project the extent of maxillary skeletal expansion required. Blue line, maxillary width and red line, mandibular width measured with a digital caliper; Mandibular width is defined as the distance between the right and left gingiva tissue projected at the level of first mandibular molar's furcation. In this case the transverse deficiency in models accounts for 6.5 mm.

Taking measurements on study models can be done before and during the expansion in order to assess the bone relationship. With these measurements, the expansion was stopped when an adequate expansion had been achieved. The maxillary width must be wider than the mandibular width in order to produce an optimal occlusion after dental decompensation. The furcation is most likely the center of rotation for mandibular molars during the decompensation. The width between the buccal points over furcation was a projected mandibular width after lower dental uprighting. The maxillary molars are generally flared buccally and the decompensation will involve a constriction of the dental arch. The most concave area of the maxilla is often at the apex of the maxillary molar, and controlled tipping with fulcrum at the apex is required during the decompensation unlike the mandibular molars. Some patients with slight transverse deficiency, but not

requiring expansion for normal function (due to well compensated dentition), were not included in this study.

The MSE device has a jackscrew unit (16.15 mm in length, 4.5 mm in width and 14.15 mm in depth) with four parallel holes (1.8 mm in diameter) for micro-implant insertion and two soft supporting arms on each side which are soldered to the molar bands for stabilizing MSE during the expansion. The body of MSE is positioned between the zygomatic buttress bones, usually located lateral to the first molars. Four micro-implants (1.8 mm in diameter, 11 mm or 13 mm in length) were inserted through the palatal bone, bi-cortically. The posterior placement and bicortical engagements promote posterior and superior expansion of the maxillary process, which in turn produce the archial expansion described in previous study.(21) The rate of expansion was 2 activations per day (0.20 mm per turn) until a diastema appeared; then the expansion rate changed to 1 activation per day. The activation was continued until the maxillary skeletal width, was equal or greater than the mandibular width. The MSE was kept in place with no further activation for 6 months to retain the expansion during the bone formation.



Fig 3. Midfacial skeletal expander device and x-ray showing bicortical engagement of the four micro-implants.

In addition to the pre-expansion CBCT scan taken before the expansion, a second CBCT scan was obtained within 3 weeks after completing the expansion. The time interval between the scans was 5 ± 2 months, and this included the time lapsed for administrative procedures, appliance fabrication, delivery and treatment. In order to assess skeletal outcomes induced purely by MSE, post-expansion scans were obtained before patients received any other orthodontic appliances. The same scanner (5G; NewTom, Verona, Italy) was used for all patients, with an 18 X 16 cm field of view, 14-bit gray scale, and a standard voxel size of 0.3 mm. Configuration of the CBCT included scan time of 18 seconds (3.6 seconds emission time), with 110 kV. In order to properly adjust the milliamperes, an automated exposure control system was used to detect the patient's anatomic density. OnDemand3D (Cybermed, Daejeon, Korea) software was used to superimpose the pre- and post-expansion CBCT images, using the anatomical structures

of the entire anterior cranial base(32) by automated processing in matching the voxel gray-scale patterns.

Following the superimposition of pre- and post-expansion CBCT images, the exact fulcrum location of each patient was identified utilizing the following method. The maxillary sagittal plane was identified, passing through the anterior nasal spine, posterior nasal spine, and nasion on the pre-expansion CBCT image.

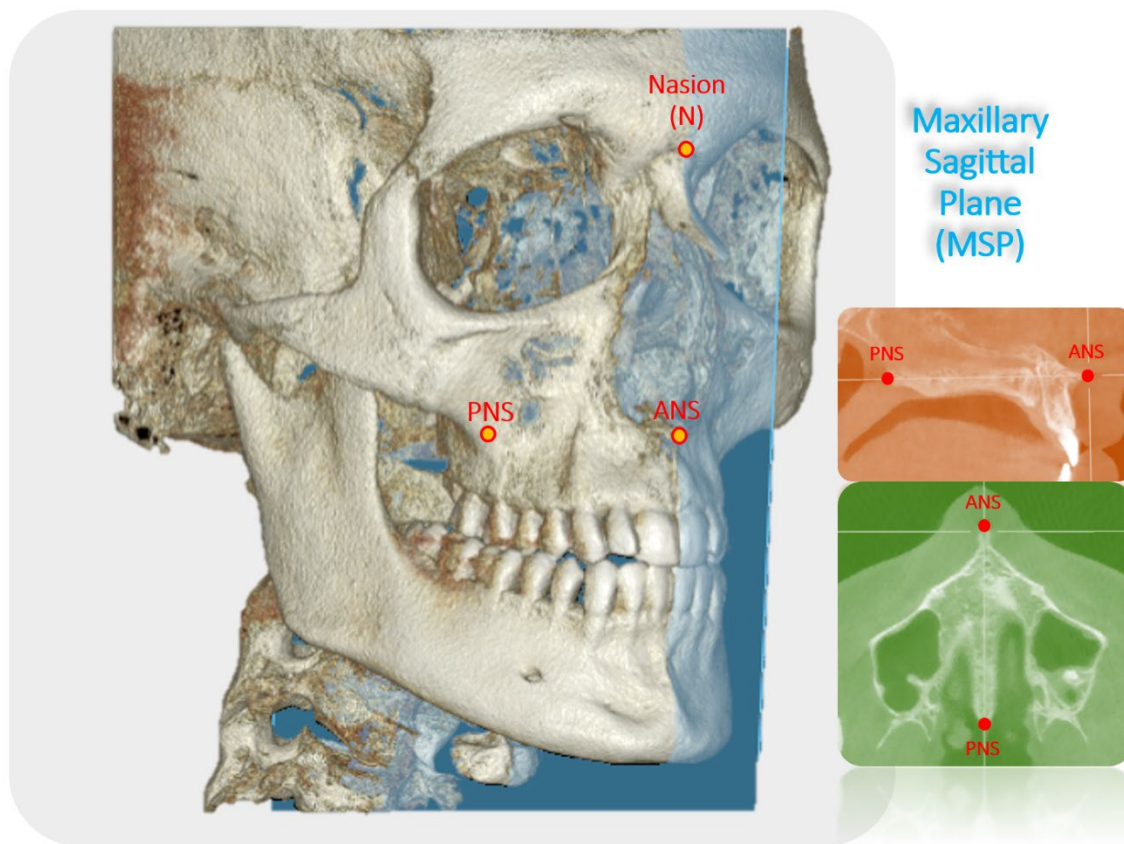


Fig 4. 3D Reconstruction with the maxillary sagittal plane (MSP) passing through anterior nasal spine (ANS), posterior nasal spine (PNS) and nasion (N) on the pre-expansion CBCT.

Then the coronal zygomatic plane was selected. This section passes through the uppermost point of the frontozygomatic sutures and the lowermost point of the zygomaticomaxillary sutures.

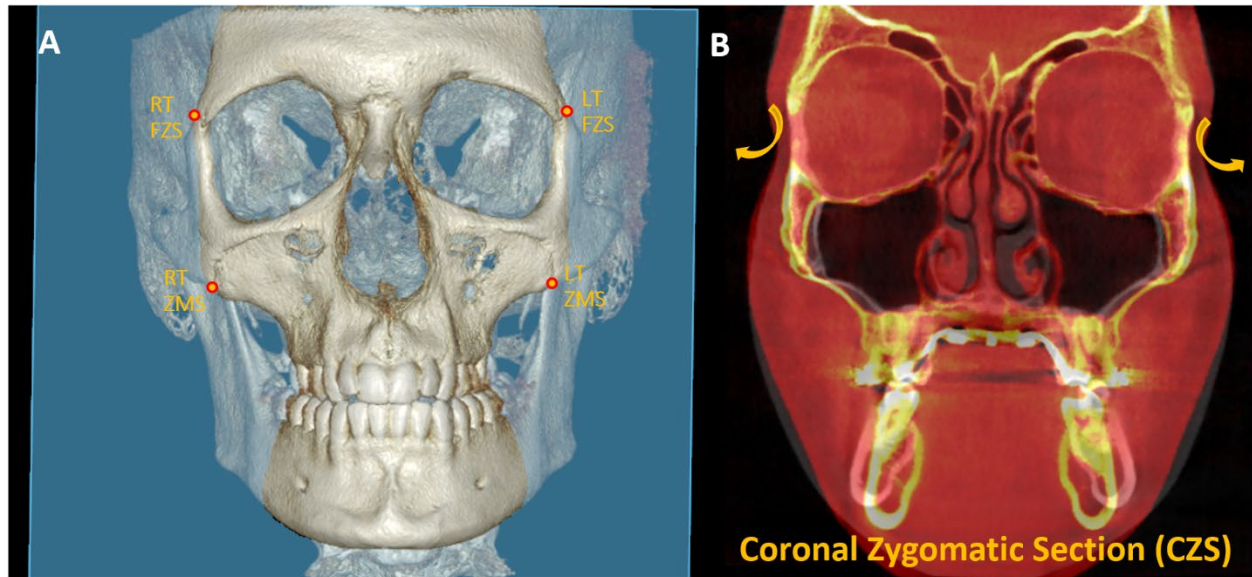


Fig 5. **A**, 3D reconstruction with the Coronal zygomatic section in blue passing through the right and left frontozygomatic sutures (FZS) and zygomaticomaxillary sutures (ZMS); **B**, Pre-treatment and post-treatment superimposed image of an MSE patient in the coronal zygomatic section. The rotational arrows on yellow show the archial movement of the zygomaticomaxillary complex in the coronal plane.

The fulcrum localization was indicated to be near and slightly above the external surface of the frontozygomatic suture because sutures are the weakest points of the midfacial structure during its archial movement after expansion.(21) For this reason, the most external and inferior points of the zygomatic processes of the frontal bones were picked as primary reference landmarks. These two reference points were connected and measured through the interfrontal distance (IFD) on both pre- and post-expansion CBCT images. If post-expansion measurements were greater than pre-expansion measurements, the exact fulcrum points were located more superiorly. To identify the true fulcrums, a parallel line, slightly above the initial interfrontal line, was moved superiorly

upwards until pre and post expansion distances were equal. After this was achieved, these newly established lines with no width changes were designated as the modified interfrontal distance (MIFD). The most external points of this MIFD were referred to as the right and left rotational fulcrum respectively. If the initial interfrontal distances (pre- and post-expansion) were the same size, the most external points of this line can be denoted as right and left rotational fulcrum points. In addition, a parallel line slightly below the initial interfrontal line was used to verify that the post-expansion distances were greater than the pre-expansion. In this situation, the modified interfrontal line is the same as initial interfrontal line. To further validate the true center of rotation, two different landmarks were picked in the zygomatic bone and the angular displacement was measured around this proposed fulcrum point. The angles formed between the modified interfrontal line and the line connecting the proposed fulcrum to two chosen landmarks were measured. The first landmark was the zygomaticomaxillary suture and the second landmark was the junction of the inner zygomatic cortical bone with the floor of the orbit and maxillary sinus in both pre and post expansion CBCT. According to the Reuleaux technique,(33) at least two corresponding landmarks must show uniform displacement around a single point, to be able to pinpoint a center of rotation. If the changes in pre- and post-expansion degrees were the same for the two angles within each zygoma in all cases, the accuracy of the fulcrum locations was confirmed.

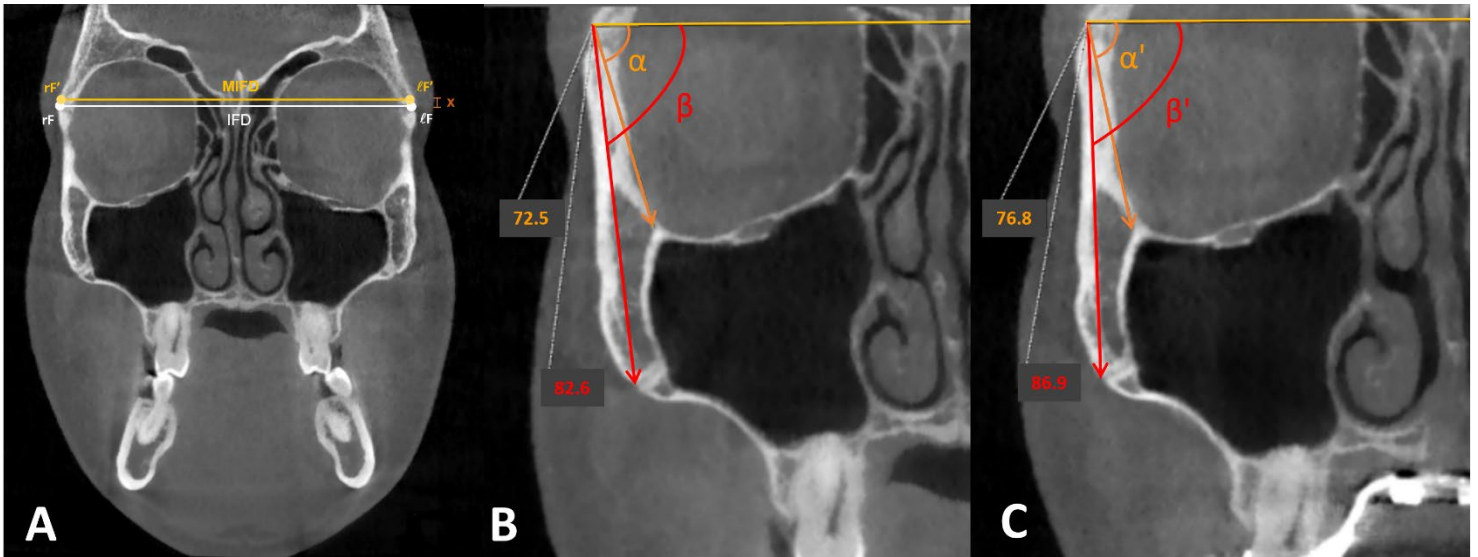


Fig 6. A. Reference lines to determine rotational fulcrum. Interfrontal distance (IFD) and modified interfrontal distance (MIFD); x: distance between IFD and MIFD. According to the Reuleaux technique, at least two corresponding landmarks must show uniform displacement around a single point, to be able to pinpoint a center of rotation. B. Pre-expansion measurements. C. Post-expansion measurements. By subtracting the pre-expansion values from the post expansion values ($\alpha' - \alpha = \beta' - \beta$), equals 4.30 of difference.

After locating the fulcrums and using the same coronal section, two different measurement systems were applied to assess the skeletal, alveolar and dental components of MSE expansion: traditional linear measurements and a novel angular measurement system.

From the rotational fulcrum, the following angular measurements were performed: the Frontozygomatic Angle (FZA) connects the interfrontal line and the line extending from fulcrum to the most external point of the zygomaticomaxillary suture, the Frontoalveolar Angle (FAA) connects the interfrontal line and the line extending from fulcrum to the alveolar bone surface at the level of distobuccal root tip of the upper first molars, and the Frontodental Angle (FDA) connects the interfrontal line and the line extending from fulcrum to the occlusal point located at the central groove of the upper first molar.

In order to determine the alveolar point for the FAA, a line parallel to the interfrontal line was moved down until it contacted the tip of the root. The alveolar point that intersected the line was selected. These three particular angles were measured on right and left sides, and the pretreatment value was subtracted from the post-expansion value in order to determine the treatment change for each section. The FZA changes correspond to the zygomaticomaxillary expansion, a true skeletal expansion (FZA changes); the FAA changes correspond to the sum of the skeletal expansion (FZA change) and the alveolar bone bending (FAA changes-FZA changes); and the FDA changes correspond to the sum of the skeletal expansion (FZA changes), alveolar bone bending (FAA changes-FZA changes) and the dental tipping (FDA changes-FAA changes).

In order to contrast with the angular values obtained, a set of traditional linear distance measurements were performed on the same coronal section (Fig 7B). The zygomaticomaxillary line (ZML), the alveolar bone line (ABL), and the dental line (DL) are perpendicular lines connecting the three landmarks used for the above angular measurements to the intersecting points on the maxillary sagittal plane. Similarly, the changes in the three sections of linear measurements, before and after the MSE treatment, were calculated for right and left sides in order to determine the treatment change. The ZML changes corresponds to the zygomaticomaxillary skeletal changes (ZML changes); the ABL changes involves the sum of the skeletal change (ZML change) and the alveolar bone bending (ZML changes-ABL changes); and the DL changes includes the sum of the skeletal change (ZML change), alveolar bone bending (ZML changes-ABL changes) and the dental tipping (DL changes-ABL changes).

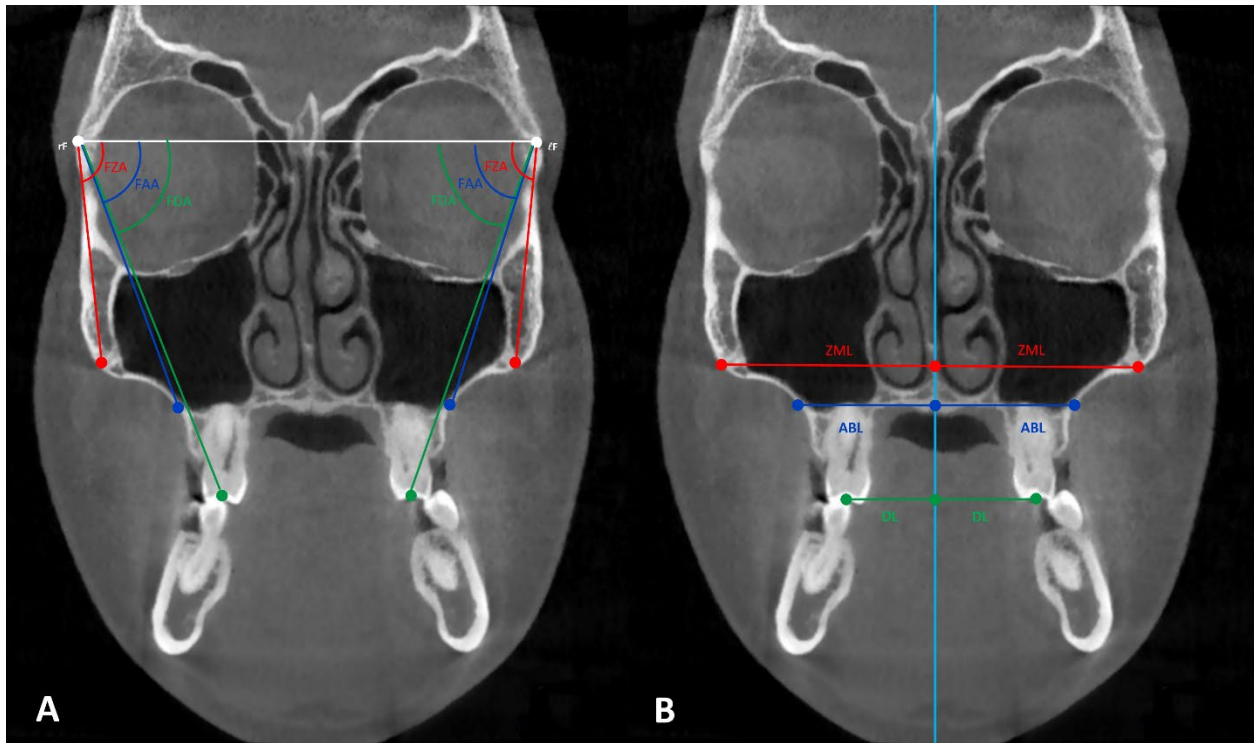


Fig. 7. Measurement systems in the coronal zygomatic section. **A**, Angular measurement system: frontozygomatic angle (FZA), frontoalveolar angle (FAA), and frontodental angle (FDA), rF, right fulcrum, lF, left fulcrum. **B**, Linear measurement system: zygomaticomaxillary line (ZML), alveolar bone line (ABL), and dental line (DL). Light blue line represents the maxillary sagittal plane.

After determining the fulcrum in all the 39 cases, the three components of the expansion (skeletal expansion, alveolar bone bending and dental tipping) were assessed by the two measurement systems described above. These results were compared.

Statistical analysis

Measurements were obtained for the 12 variables (6 pretreatment and 6 post expansion) on 10 randomly selected patients, by 2 raters, to assess method reliability. Measurements were then repeated after 2 weeks by the same operators, after reorienting the skull according to the reference planes to compute reliability parameters that are the combination of error in identification of reference planes (maxillary sagittal plane, coronal zygomatic section) and error in landmark localization. The calculated parameters were rater standard deviation, rater coefficient of variation, error standard deviation, error coefficient of variation, and intraclass correlation coefficient (ICC).

For each variable, the pre-expansion value was subtracted from the post-expansion value. The percentages of skeletal expansion (a: the frontozygomatic angle changes), alveolar bone bending (b: the frontoalveolar angle change - the frontozygomatic angle change) and dental tipping (c: the frontodental angle change – the frontoalveolar angle change). A similar calculation was performed for the linear measurements. The mean of the treatment change per each variable was compared with zero, and the P value was computed using the Wilcoxon signed rank test for paired data.

Mean values of the total frontozygomatic, frontoalveolar and frontodental angle changes were compared using Kruskal Wallis test.

RESULTS

The mean maxillomandibular bone width discrepancy, assessed in CBCT, accounted for 5.2 (± 3.4) mm. The average amount of activation of the MSE expansion jackscrew was 8.7 ± 1.2 mm. The duration of maxillary expansion ranged from 15 to 36 days. From the 39 patients, 20 subjects have the rotational fulcrum of the zygomaticomaxillary complex at the most distant points of the interfrontal distance (101.6 ± 4.7 mm) and 19 subjects at the most distant points of the modified interfrontal distance' (98.9 ± 5.7 mm). The modified interfrontal distance was found to be at 0.6 ± 0.29 mm above the interfrontal distance (range 0.19 – 1.01 mm). Pre-expansion and post-expansion linear and angular measurements are presented on tables 1 and 2.

The treatment change for the 39 cases with linear measurements at the zygomaticomaxillary level was 2.31 (± 1.02) and 2.37 (± 1.18) mm (right and left sides), at the alveolar bone level was 0.62 (± 0.44) and 0.69 (± 0.46) mm. (right and left sides), and at the dental level was 0.91 (± 0.73) and 1.11 (± 0.6) mm. (right and left sides). These values suggest 60.16% and 56.83% (right and left sides) skeletal expansion, 16.15% and 16.55% (right and left sides) alveolar bone bending, and 23.69% and 26.62% (right and left sides) dental tipping. In contrast, the treatment change with angular measurements at the zygomaticomaxillary level was 2.82° (± 1.26) and 2.93° (± 1.49) (right and left sides), at the alveolar bone level was 0.01° (± 0.03) (both right and left sides), and at the dental level was 0.09° (± 0.17) and 0.13° (± 0.12) (right and left sides). These values represent 96.58% and 95.44% of skeletal expansion for the right and left sides, 0.34% and 0.33% alveolar bone bending for right and left sides and dental tipping of 3.08% and 4.23% for the right and left sides respectively (Table 3).

There was no significant difference between the mean values of the total frontozygomatic, frontoalveolar and frontodental treatment change angles ($P=0.748$). (Table 4)

For the considered parameters, the rater coefficient of variation was 1.36% or less, and the error coefficient of variation was 1.75% or less, showing that measurements were highly reliable.

Table 1. Skeletal, alveolar bone and dental linear measurements

Linear Measurements	Unit	<u>Before expansion</u>		<u>After expansion</u>		<u>Treatment change</u>		P value
		Mean	SD	Mean	SD	Mean	SD	
Skeletal linear measurements								
Right Zygomaticomaxillary line	mm	44.46	2.54	46.77	2.65	2.31	1.02	<0.0001*
Left Zygomaticomaxillary line	mm	44.30	2.49	46.67	2.62	2.37	1.18	<0.0001*
Alveolar bone linear measurements								
Right Alveolar bone line	mm	29.07	2.32	32.01	2.53	2.93	1.16	<0.0001*
Left Alveolar bone line	mm	29.38	2.23	32.45	2.33	3.06	1.47	<0.0001*
Dental linear measurements								
Right Dental line	mm	22.44	2.69	26.28	2.66	3.84	1.65	<0.0001*
Left Dental line	mm	23.12	2.42	27.30	2.32	4.17	1.86	<0.0001*

*P <0.01.

SD: Standard deviation

Table 2. Skeletal, alveolar bone and dental angular measurements

Angular Measurements	Unit	<u>Before expansion</u>		<u>After expansion</u>		<u>Treatment change</u>		P value
		Mean	SD	Mean	SD	Mean	SD	
Skeletal angular measurements								
Right Frontozygomatic angle	°	83.47	3.60	86.29	3.47	2.82	1.26	<0.0001*
Left Frontozygomatic angle	°	83.25	3.49	86.19	3.88	2.93	1.49	<0.0001*
Alveolar bone angular measurements								
Right Frontoalveolar angle	°	70.20	2.51	73.03	2.38	2.83	1.27	<0.0001*
Left Frontoalveolar angle	°	70.44	2.85	73.39	3.27	2.94	1.48	<0.0001*
Dental angular measurements								
Right Frontodental angle	°	69.37	2.32	72.29	2.09	2.92	1.29	<0.0001*
Left Frontodental angle	°	69.92	2.19	72.99	2.54	3.07	1.48	<0.0001*

*P <0.01.

SD: Standard deviation

Table 3. Linear and angular treatment change measurements for each component.

				Skeletal expansion	Alveolar bone bending	Dental tipping
Right linear measurements						
Unit	Δa	Δb	Δc	Δa	$\Delta b - \Delta a$	$\Delta c - \Delta b$
mm.	2.31	2.93	3.84	2.31	0.62	0.91
%				60.16%	16.15%	23.69%
Right angular measurements						
	Δa	Δb	Δc	Δa	$\Delta b - \Delta a$	$\Delta c - \Delta b$
°	2.82	2.83	2.92	2.82	0.01	0.09
%				96.58%	0.34%	3.08%
Left linear measurements						
	Δa	Δb	Δc	Δa	$\Delta b - \Delta a$	$\Delta c - \Delta b$
mm.	2.37	3.06	4.17	2.37	0.69	1.11
%				56.83%	16.55%	26.62%
Left angular measurements						
	Δa	Δb	Δc	Δa	$\Delta b - \Delta a$	$\Delta c - \Delta b$
°	2.93	2.94	3.07	2.93	0.01	0.13
%				95.44%	0.33%	4.23%

Δa = Skeletal expansion Δb = Skeletal expansion + Alveolar bone bending Δc = Skeletal expansion + Alveolar bone bending + Dental tipping

Table 4. Mean values of the total frontozygomatic, frontoalveolar and frontodental angles

	Treatment change at ZM point		Treatment change at AB point		Treatment change at D point		
Unit	Mean	SD	Mean	SD	Mean	SD	P value
°	2.87	1.37	2.88	1.37	2.99	1.38	0.748

ZM, zygomaticomaxillary; AB, alveolar bone; D, dental.

SD: Standard deviation

DISCUSSION

It is desirable to design an appliance that produces skeletal maxillary expansion with minimal dentoalveolar consequences. In designing an expansion device, the main considerations should be maximizing the orthopedic expansion of the midcranial structure without significant dentoalveolar changes, by applying the force directly against the resisting structures. Maintenance of surrounding tissue integrity and stability, while achieving desired dimensional changes in an efficient and consistent manner, is desired. The MSE is specifically designed to achieve a skeletal midfacial expansion by applying the expansion force directly against midpalatal suture and zygomatic buttress bones in order to minimize the negative dentoalveolar side-effects. This resulted in archial rotations of mid-cranial structures with the fulcrums located near the frontozygomatic sutures.(21) With this information, a method of determining the precise fulcrum locations and a novel measurements system utilizing the angular changes from these fulcrums were developed. In order to apply this measurement system, it is vitally important to first determine the correct fulcrum location for each individual patient. Furthermore, the fulcrum location used in the current study can only be applied to MSE patients because the fulcrum location most likely will differ with each appliance design and activation protocol.

The treatment timing is another factor to consider when maxillary expansion is performed. The resistance against skeletal separation increases beyond the pubertal growth period, and a significant sutural separation cannot be anticipated with tooth-borne expanders, causing more dentoalveolar changes. It has been believed that, by young adulthood, fusion of the sutures virtually eliminates the potential for sutural separation without

surgical assistance.(34) Even in growing patients, heavy forces of RME produce an increased buccal inclination of anchored teeth at the end of active phase, regardless of the type of expanders (3, 4, 10, 35-38) or of the rate of activation.(8) Also in pre-pubertal patients, it has been demonstrated that alveolar structures splayed buccally and carried the teeth with them,(3, 37) and that a 6-month period is necessary to allow recovery of the alveolar plate.(39) This adverse effect was observed in both adolescents and adult subjects when tooth-borne devices were used. However, the undesirable consequences such as dentoalveolar tipping, fenestration, dehiscence, and gingival recession(5) were more common and critical with post-pubertal patients. Furthermore, the dental tipping gradually relapsed after the active expansion phase even in growing patients,(6, 8) indicating the importance of avoiding the dentoalveolar changes during the expansion.

With the introduction of microimplants to the RPE appliances, a new non-surgical alternative treatment for maxillary deficiency patient has been established. Since many of these appliances are bone-borne in nature, the MARPE should not affect dentoalveolar structures. Nonetheless, expression of a pure skeletal expansion has been negated in several articles,(9-19, 40) and they present various amount/percentage of alveolar bone bending and dental tipping. There are two problems associated with these studies. These studies employed linear measurements to differentiate three components of the expansion. This approach has an inherent error.

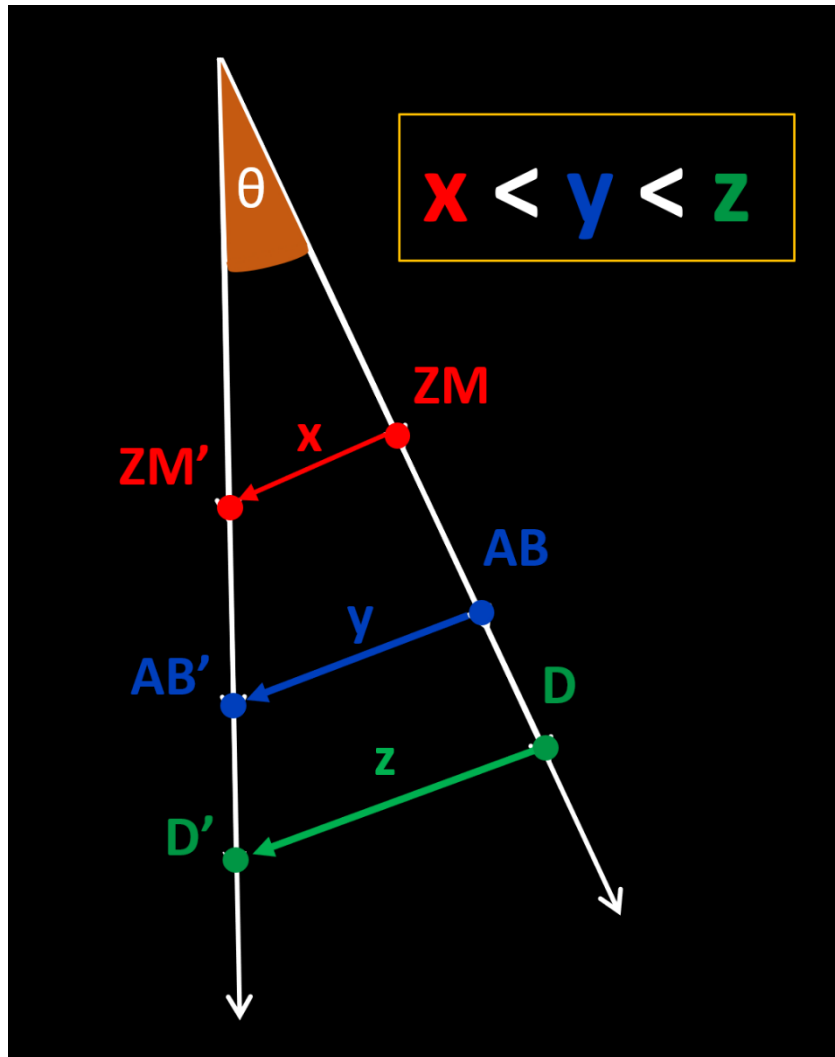


Fig 8. Diagram displaying the inaccuracy of using linear measurements in order to assess rotational pattern movement. For the same angle θ , points closer to the fulcrum experience a shorter linear displacement than points farther from the fulcrum. ZM, pre-expansion zygomaticomaxillary point; ZM' post-expansion zygomaticomaxillary point; AB pre-expansion alveolar bone point; AB' post-expansion alveolar bone point; D pre-expansion dental point; D' post-expansion dental point; x, linear skeletal distance; y, linear alveolar bone distance; z, linear dental distance.

When the expansion is archial in nature, the movement of a structure further away from the fulcrum point will be displaced further when linear measurements are used. Although linear measurements are not accurate, in our daily orthodontic diagnosis and practice, transverse dimensions are still practically measured on the horizontal plane. But this can lead to an error in assessing the differentiation of the three components (skeletal, alveolar

and dental) of expansion since the dental and alveolar components are further away from the fulcrum point. In the current study, the angular measurements were employed in order to overcome the above problems. The proposed angular measurements reflect true differential movements of the three components (skeletal, alveolar, and dental movements). This approach is possible only if the true fulcrums have been defined. The conventional linear measurements were also applied to all patients, in order to assess the differences between the two measurement systems.

To assess the MSE outcomes, the fulcrum position of the zygomaticomaxillary complex on the coronal plane was determined based on Cantarella study.(21) When the angular measurements were used from these fulcrum points, the MSE produced almost pure skeletal expansion ($2.82^\circ = 96.58\%$ R; $2.93^\circ = 95.44\%$ L) negligible alveolar bone bending ($0.01^\circ = 0.34\%$ R; $0.01^\circ = 0.33\%$ L) and with a slight dental tipping ($0.09^\circ = 3.08\%$ R; $0.13^\circ = 4.23\%$ L), in contrast to other MARPE studies. There was no significant difference between the total mean values of the frontozygomatic, frontoalveolar and frontodental treatment change angles ($P=0.748$). The angular changes (counting both right and left values together) indicating the alveolar bone bending and dental tipping were not statistically different than the angular change indicating the skeletal changes (table 4), which illustrates that the MSE expansion was mostly skeletal with entire midcranial structures rotating from the fulcrum points.

The results were obtained by MSE treatment for late adolescents and adults. The principal features related to the above results were the bicortical engagement(20) of the

four micro-implants (11 to 13 mm. length) placed immediately next to the midpalatal suture and the MSE location in-between the zygomatic buttress bones. The bicortical engagements of the micro-implants promotes the expansion force to reach the superior aspect of the maxillary complex.(20) The anatomical location of MSE produced a force vector in line with the zygomatic bone(28) and produced the midcranial movement. These two factors together produced the rotation of midcranial structure at a high fulcrum position. Clearly, the MSE produced a pure rotation of midfacial structures with negligible alveolar bone bending or dental tipping.

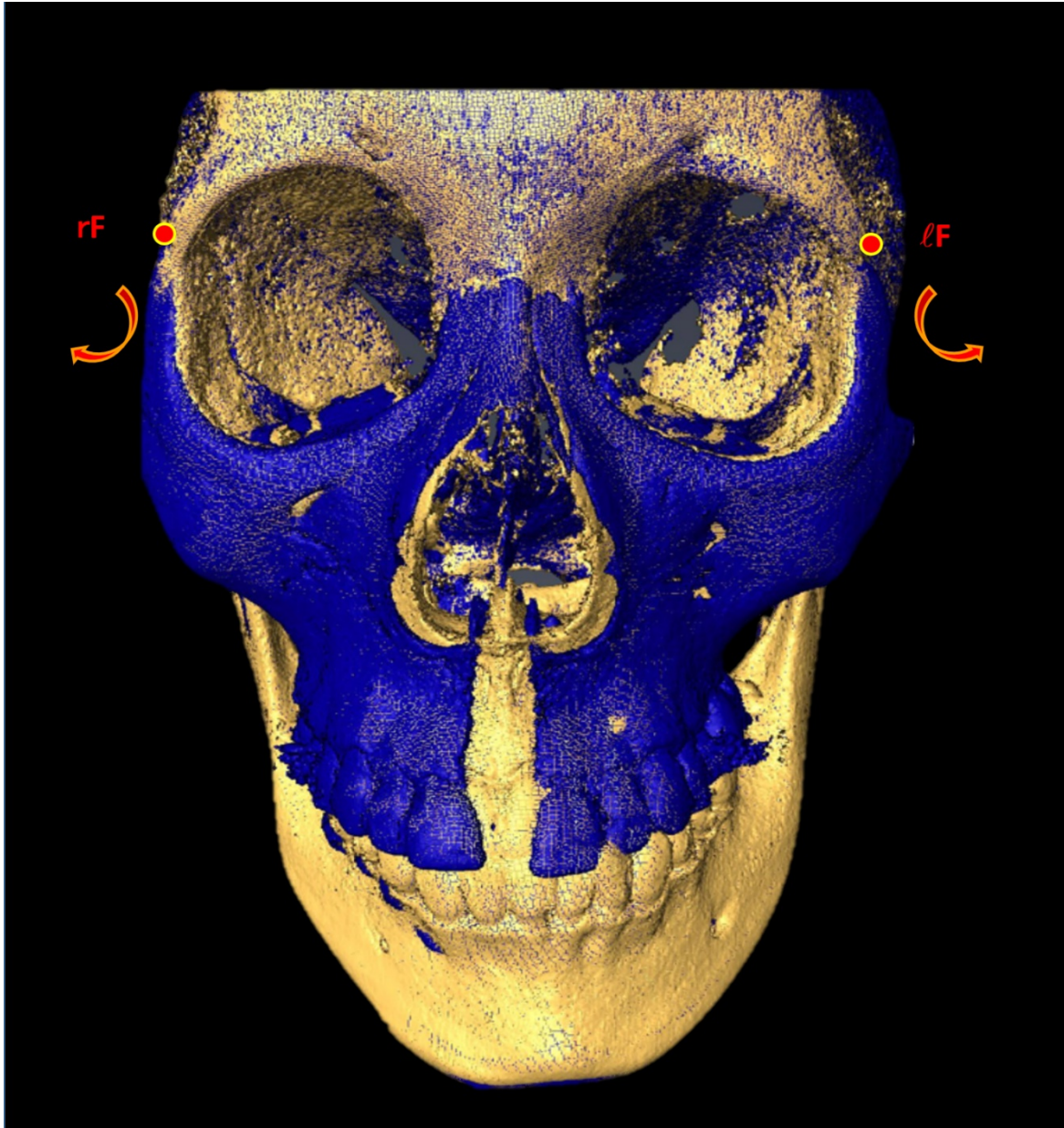


Fig 9. Superimposed 3D model of an MSE patient displaying the rotational pattern of the zygomaticomaxillary complex. Yellow, pre-expansion; blue, post-expansion; rF, right fulcrum; lF, left fulcrum. Structures medial and above the fulcrum are stable. Red arrows show the outward and downward direction of the expansion on the coronal view.

The linear measurement system was used on the same data set, in order to assess the inherent error built into this system. The results from the linear measurement were quite different than those from the angular measurements: the skeletal expansion (2.31mm = 60.16% R; 2.37 mm = 56.83% L) negligible alveolar bone bending (0.62 mm = 16.15% R; 0.69 mm = 16.55% L) and with a slight dental tipping (0.91mm = 23.69% R; 1.11 mm =

26.62% L). When dealing with a rotational movement, this type of measurement system has severe shortcomings because it does not account for the differences in radius of each variable. The structure further away from the fulcrum has a longer radius, and the linear length of the movement is longer, producing a false differential movement. Other studies related to archial movement of the structures could have suffered the same consequences if this type of linear measurements was employed. However, the angular measurements from arbitrary points cannot produce accurate readings either. Without an accurate fulcrum location, even the angular measurements can produce false assessments.

Lin et al.(9) had a comparison study between tooth-borne and bone-borne MARPE on late adolescents. The MARPE used in this study included 4 micro-implants embedded in two acrylic shelves supporting the jackscrew. All implants were positioned close to the dentition, inferiorly from the midpalatal suture, but the appliance did not contact the dentition. Angular measurements were employed to assess alveolar bone bending and dental tipping using an arbitrary palatal plane. They found a significant alveolar bone bending and dental tipping even with this bone-borne expander treatment. Because of the force applied to the dentoalveolar region by this appliance, the dentoalveolar changes may have been possible; however, it is difficult to accept that dental movement can occur when the expander did not have any physical contact with the dentition. This implies that angular measurements from arbitrary points cannot accurately assess the true impact of an appliance. Similarly, many have used arbitrary reference lines and points to assess the results of expansion, without considering the fulcrum position.

The actual dental tipping and alveolar bone bending may be much less than the reported values in many instances when the movement was rotational in nature. The challenge is locating the true fulcrum for each appliance in question. Further study will be necessary in order to determine the best way to identify the fulcrum for various appliance design. Once the fulcrum is located, the angular measurements similar to the system proposed in this study can be useful in accurately determining the effect of expanders. Comparative studies with conventional tooth-borne appliances, other bone-borne expanders and surgically assisted rapid palatal expansion (SARPE), using the novel method presented here will be useful in understanding the real differences between these groups of expansion modalities.

The tooth-borne, pure bone-borne, tooth-and-bone-borne, bone-and-tissue-borne all behave differently. Furthermore, each appliance within the same type can exhibit completely different expansion pattern. Moreover, the position of the expander can alter the fulcrum position and expansion pattern. It is not possible to understand the expansion configuration for each appliance without identifying the exact fulcrum locations. Once the fulcrum has been established, the angular measurements can be taken. We could expect more dental components from tooth-borne, and tooth-and-bone-borne appliances. However, the alveolar bone bending probably is more related to the expansion force delivery relative to the resisting structures, which is defined by the position of bone and tooth anchors. More inferior they are, generally will cause more alveolar bone bending.

Limitations of this study are related to its retrospective nature, and the lack of a control group due to ethical issues. Although the values obtained from the current study are

applied to the MSE, the system presented in this article could not be used for another types of expanders. Every expander has a different design an activation protocol. These factors may vary the position of the fulcrum.

CONCLUSIONS

1. MSE produced almost pure skeletal rotational movement of midcranial structures.
2. Alveolar bone bending and dental tipping were not statistically significant with MSE.
3. The angular measurement system from fulcrums provided much different results than the linear measurement system. The conventional linear measurements can falsely exaggerate the alveolar and dental components of MSE treatment.
4. To correctly differentiate the expansion pattern of the rotating zygomaticomaxillary complex, a localization of the fulcrum should be the first step, then the angular measurements should be performed.
5. Fulcrum position may vary depending on the design of the expander and the activation protocol, and a true fulcrum for each appliance should be identified for the proposed angular measurement system.

FUTURE DIRECTIONS

In the present study, post expansion changes with MSE, have been studied at the skeletal, alveolar bone and dental level. We compared T0 (initial) vs T1 (post-expansion) time. It would be interesting to assess if the orthopedic changes are still stable by the end of treatment. We could expect to find no changes at the alveolar level and some changes (lingual decompensation) at the dental level. At the moment, the 39 patients included in the present study are still not finished but 60% of them could be enough sample to prove whether there is stability or not in terms of the maxillary transverse correction for patients that underwent treatment with the Maxillary Skeletal Expander.

Although this is a study performed in CBCT, the values were obtained from 2D cuts. As we know, the skull is a 3D structure. In the same sense, the fulcrum should be considered as an area and not a solely point. A 3D superimposition and a vector map could provide us a better idea how every single point from the skull displace after expansion with MSE utilizing the 3 dimensions. Automation by machine-learning and/or artificial intelligence (AI) may be able to detect true point-to-point correspondence in the future. A simplified vector map could be developed as well, reducing the 1 million vectors by averaging their displacement and direction according to specific areas of interest to obtain trends/patterns of movements.

To have a control group is always desired for any study. However, the control would be represented by a series of two consecutive CBCTs from the same subject without any intervention. Obviously, this involves ethical issues due to patient's double exposure to radiation. Another interesting control group could be patients that underwent conventional rapid palatal expansion with Hyrax. Again, an initial CBCT could be justified pre-treatment, but an immediate post-expansion CBCT could be hardly acceptable in an IRB.

Some of the patients used in this investigation have also been subjects to study the asymmetric expansion changes in another study. We could correlate their findings with our study's amounts of skeletal expansion, alveolar bone bending and dental tipping.

The data could potentially be divided into subcategories such as the amount of expansion, age and sex of the patient and compared among them to see if these factors are intervening factors of the MSE effect.

REFERENCES

1. McNamara JA. Maxillary transverse deficiency. *Am J Orthod Dentofacial Orthop.* 2000;117(5):567-70.
2. Ghoneima A, Abdel-Fattah E, Hartsfield J, El-Bedwehi A, Kamel A, Kula K. Effects of rapid maxillary expansion on the cranial and circummaxillary sutures. *Am J Orthod Dentofacial Orthop.* 2011;140(4):510-9.
3. Kilic N, Kiki A, Oktay H. A comparison of dentoalveolar inclination treated by two palatal expanders. *Eur J Orthod.* 2008;30(1):67-72.
4. Olmez H, Akin E, Karacay S. Multitomographic evaluation of the dental effects of two different rapid palatal expansion appliances. *Eur J Orthod.* 2007;29(4):379-85.
5. Baysal A, Uysal T, Veli I, Ozer T, Karadede I, Hekimoglu S. Evaluation of alveolar bone loss following rapid maxillary expansion using cone-beam computed tomography. *Korean J Orthod.* 2013;43(2):83-95.
6. Kartalian A, Gohl E, Adamian M, Enciso R. Cone-beam computerized tomography evaluation of the maxillary dentoskeletal complex after rapid palatal expansion. *Am J Orthod Dentofacial Orthop.* 2010;138(4):486-92.
7. Baccetti T, Franchi L, Cameron CG, McNamara JA, Jr. Treatment timing for rapid maxillary expansion. *Angle Orthod.* 2001;71(5):343-50.
8. LaBlonde B, Vich ML, Edwards P, Kula K, Ghoneima A. Three dimensional evaluation of alveolar bone changes in response to different rapid palatal expansion activation rates. *Dental Press J Orthod.* 2017;22(1):89-97.
9. Lin L, Ahn HW, Kim SJ, Moon SC, Kim SH, Nelson G. Tooth-borne vs bone-borne rapid maxillary expanders in late adolescence. *Angle Orthod.* 2015;85(2):253-62.

10. Lagravere MO, Carey J, Heo G, Toogood RW, Major PW. Transverse, vertical, and anteroposterior changes from bone-anchored maxillary expansion vs traditional rapid maxillary expansion: a randomized clinical trial. *Am J Orthod Dentofacial Orthop.* 2010;137(3):304 e1-12; discussion -5.
11. Park JJ, Park YC, Lee KJ, Cha JY, Tahk JH, Choi YJ. Skeletal and dentoalveolar changes after miniscrew-assisted rapid palatal expansion in young adults: A cone-beam computed tomography study. *Korean J Orthod.* 2017;47(2):77-86.
12. Carlson C, Sung J, McComb RW, Machado AW, Moon W. Microimplant-assisted rapid palatal expansion appliance to orthopedically correct transverse maxillary deficiency in an adult. *Am J Orthod Dentofacial Orthop.* 2016;149(5):716-28.
13. Lee KJ, Park YC, Park JY, Hwang WS. Miniscrew-assisted nonsurgical palatal expansion before orthognathic surgery for a patient with severe mandibular prognathism. *Am J Orthod Dentofacial Orthop.* 2010;137(6):830-9.
14. Mosleh MI, Kaddah MA, Abd EISayed FA, EISayed HS. Comparison of transverse changes during maxillary expansion with 4-point bone-borne and tooth-borne maxillary expanders. *Am J Orthod Dentofacial Orthop.* 2015;148(4):599-607.
15. Lombardo L, Carlucci A, Maino BG, Colonna A, Paoletto E, Siciliani G. Class III malocclusion and bilateral cross-bite in an adult patient treated with miniscrew-assisted rapid palatal expander and aligners. *Angle Orthod.* 2018;88(5):649-64.
16. Seo YJ, Chung KR, Kim SH, Nelson G. Camouflage treatment of skeletal class III malocclusion with asymmetry using a bone-borne rapid maxillary expander. *Angle Orthod.* 2015;85(2):322-34.

17. Vassar JW, Karydis A, Trojan T, Fisher J. Dentoskeletal effects of a temporary skeletal anchorage device-supported rapid maxillary expansion appliance (TSADRME): A pilot study. *Angle Orthod.* 2016;86(2):241-9.
18. Wilmes B, Nienkemper M, Drescher D. Application and effectiveness of a mini-implant- and tooth-borne rapid palatal expansion device: the hybrid hyrax. *World J Orthod.* 2010;11(4):323-30.
19. Yilmaz A, Arman-Ozcirpici A, Erken S, Polat-Ozsoy O. Comparison of short-term effects of mini-implant-supported maxillary expansion appliance with two conventional expansion protocols. *Eur J Orthod.* 2015;37(5):556-64.
20. Lee RJ, Moon W, Hong C. Effects of monocortical and bicortical mini-implant anchorage on bone-borne palatal expansion using finite element analysis. *Am J Orthod Dentofacial Orthop.* 2017;151(5):887-97.
21. Cantarella D, Dominguez-Mompell R, Moschik C, Mallya SM, Pan HC, Alkahtani MR, et al. Midfacial changes in the coronal plane induced by microimplant-supported skeletal expander, studied with cone-beam computed tomography images. *Am J Orthod Dentofacial Orthop.* 2018;154(3):337-45.
22. MacGinnis M, Chu H, Youssef G, Wu KW, Machado AW, Moon W. The effects of micro-implant assisted rapid palatal expansion (MARPE) on the nasomaxillary complex- a finite element method (FEM) analysis. *Prog Orthod.* 2014;15:52.
23. Brunetto DP, Sant'Anna EF, Machado AW, Moon W. Non-surgical treatment of transverse deficiency in adults using Microimplant-assisted Rapid Palatal Expansion (MARPE). *Dental Press J Orthod.* 2017;22(1):110-25.

24. Suzuki SS, Braga LFS, Fujii DN, Moon W, Suzuki H. Corticopuncture Facilitated Microimplant-Assisted Rapid Palatal Expansion. *Case Rep Dent.* 2018;2018:1392895.
25. Abedini S, Elkenawy I, Kim E, Moon W. Three-dimensional soft tissue analysis of the face following micro-implant-supported maxillary skeletal expansion. *Prog Orthod.* 2018;19(1):46.
26. Garcez AS, Suzuki SS, Storto CJ, Cusmanich KG, Elkenawy I, Moon W. Effects of maxillary skeletal expansion on respiratory function and sport performance in a para-athlete - A case report. *Phys Ther Sport.* 2019;36:70-7.
27. Storto CJ, Garcez AS, Suzuki H, Cusmanich KG, Elkenawy I, Moon W, et al. Assessment of respiratory muscle strength and airflow before and after microimplant-assisted rapid palatal expansion. *Angle Orthod.* 2019;89(5):713-20.
28. Cantarella D, Dominguez-Mompell R, Mallya SM, Moschik C, Pan HC, Miller J, et al. Changes in the midpalatal and pterygopalatine sutures induced by micro-implant-supported skeletal expander, analyzed with a novel 3D method based on CBCT imaging. *Prog Orthod.* 2017;18(1):34.
29. Cantarella D, Dominguez-Mompell R, Moschik C, Sfogliano L, Elkenawy I, Pan HC, et al. Zygomaticomaxillary modifications in the horizontal plane induced by micro-implant-supported skeletal expander, analyzed with CBCT images. *Prog Orthod.* 2018;19(1):41.
30. Luebbert J, Ghoneima A, Lagravere MO. Skeletal and dental effects of rapid maxillary expansion assessed through three-dimensional imaging: A multicenter study. *Int Orthod.* 2016;14(1):15-31.

31. Andrews LF AW. The six elements of orofacial harmony. . Andrews J Orthod Orofac Harmony. 2000(1):13-22.
32. Cevidanes LH, Bailey LJ, Tucker GR, Jr., Styner MA, Mol A, Phillips CL, et al. Superimposition of 3D cone-beam CT models of orthognathic surgery patients. Dentomaxillofac Radiol. 2005;34(6):369-75.
33. Reuleaux F. Theoretische Kinematik: Grundzüge einer Theorie des Maschinenwesens; the English translation is: Kinematics of Machinery. Outlines of a Theory of Machines. London: MacMillan; 1875.
34. Bell RA KT. Posterior crossbites in children: Developmental-based diagnosis and implications to normative growth patterns. Semin Orthod 2014(20):77–113.
35. Christie KF, Boucher N, Chung CH. Effects of bonded rapid palatal expansion on the transverse dimensions of the maxilla: a cone-beam computed tomography study. Am J Orthod Dentofacial Orthop. 2010;137(4 Suppl):S79-85.
36. Weissheimer A, de Menezes LM, Mezomo M, Dias DM, de Lima EM, Rizzatto SM. Immediate effects of rapid maxillary expansion with Haas-type and hyrax-type expanders: a randomized clinical trial. Am J Orthod Dentofacial Orthop. 2011;140(3):366-76.
37. Ciambotti C, Ngan P, Durkee M, Kohli K, Kim H. A comparison of dental and dentoalveolar changes between rapid palatal expansion and nickel-titanium palatal expansion appliances. Am J Orthod Dentofacial Orthop. 2001;119(1):11-20.
38. Asanza S, Cisneros GJ, Nieberg LG. Comparison of Hyrax and bonded expansion appliances. Angle Orthod. 1997;67(1):15-22.

39. Ballanti F, Lione R, Fanucci E, Franchi L, Baccetti T, Cozza P. Immediate and post-retention effects of rapid maxillary expansion investigated by computed tomography in growing patients. *Angle Orthod.* 2009;79(1):24-9.
40. Gunyuz Toklu M, Germec-Cakan D, Tozlu M. Periodontal, dentoalveolar, and skeletal effects of tooth-borne and tooth-bone-borne expansion appliances. *Am J Orthod Dentofacial Orthop.* 2015;148(1):97-109.