

# UC San Diego

## UC San Diego Previously Published Works

### Title

Eplerenone as a novel treatment for persistent subretinal fluid following retinal detachment surgery

### Permalink

<https://escholarship.org/uc/item/1pr408pj>

### Authors

Haghighi, Arezu

Do, Jiun

Ameri, Hossein

### Publication Date

2018-06-01

### DOI

10.1016/j.ajoc.2018.03.012

Peer reviewed



## Case report

## Eplerenone as a novel treatment for persistent subretinal fluid following retinal detachment surgery

Arezu Haghighi<sup>a</sup>, Jiun Do<sup>a,b</sup>, Hossein Ameri<sup>a,\*</sup><sup>a</sup> USC Roski Eye Institute, University of Southern California, 1450 San Pablo Street, Los Angeles, CA, USA<sup>b</sup> University of San Diego Shiley Eye Institute, 9415 Campus Point Dr, La Jolla, CA, 92093, USA

## ARTICLE INFO

## Keywords:

Subretinal fluid  
Retinal detachment  
Central serous retinopathy  
Eplerenone  
Retinal pigment epithelium  
Scleral buckling

## ABSTRACT

**Purpose:** To describe the clinical course of a patient with persistent subretinal fluid (SRF) after primary scleral buckle surgery for a rhegmatogenous retinal detachment (RRD) repair who was subsequently treated with oral eplerenone for resolution of SRF.

**Observations:** A 34 year-old-male presented with a large bullous macula-involving RRD of unknown duration and underwent primary scleral buckle and retinotomy for drainage of subretinal fluid (SRF). His post-operative course was characterized by persistent macular SRF for 1.5 years with poor vision largely unchanged from his pre-operative presentation. Patient declined additional surgical treatment and opted for conservative management. Given such persistent SRF, the patient was trialed on a course of oral eplerenone 50 mg po bid. After only one month on this therapy, a marked decline in SRF was noted with near complete resolution after two months.

**Conclusions and Importance:** To our knowledge, this is the first report of its kind to show the effectivity of oral eplerenone treatment in the reduction of SRF following retinal detachment surgery.

## 1. Introduction

The incidence of subretinal fluid (SRF) following rhegmatogenous retinal detachment (RRD) repair varies widely and has an unclear effect on final visual acuity.<sup>1</sup> In many cases of persistent SRF following RRD repair, an approach of watchful waiting for spontaneous SRF resorption is employed. Studies have shown that 62.5–94% of patients with macula-involving RRDs who undergo surgical repair have persistent SRF on OCT after one month. The average time for spontaneous SRF resorption is on the order of  $7.8 \pm 4.4$  months.<sup>1,2</sup> Younger age, aphakia, absence of a PVD, and longer standing inferior RRDs with viscous SRF have been speculated as risk factors for prolonged persistence of SRF.<sup>1,5</sup>

A number of retinal pigment epithelium (RPE) morphological changes occur with long-standing SRF. In RD animal models, RPE metabolic and phagocytic capabilities are affected, in particular, when it comes to resorbing large proteins, glycosaminoglycans, and cellular debris found in longstanding SRF.<sup>3–6</sup> Changes in non-polarized RPE cell proliferation as well as Muller cell proliferation in the subretinal space have also been noted.<sup>3,7</sup> In so far as persistent SRF may contribute to a pigment epitheliopathy, medical treatment may be analogous to that used in another disease of RPE function — central serous retinopathy (CSCR). The anti-mineralocorticoid effect of eplerenone has garnered much attention over recent years in the treatment of SRF in CSCR.<sup>8</sup>

Herein we describe a case of a young male patient with persistent SRF following retinal detachment surgery who was subsequently treated with a short course of oral eplerenone.

## 1.1. Case report

A 34-year-old male presented to the Emergency Department at Los Angeles County/University of Southern California (LAC + USC) Medical Center for an ophthalmological evaluation after failing the visual assessment portion of his driver's license examination secondary to poor vision in the left eye. The patient had a remote history of trauma to the left eye 14 years prior and recalled experiencing symptoms of flashes and floaters one year prior to presentation. He denied any recent changes in vision. On examination, the visual acuity in the left eye was 20/150 and dilated examination demonstrated a large, macula-involving, bullous inferior retinal detachment (RD) with a demarcation line extending through the fovea and an inferior horseshoe tear at 6 o'clock anterior to the equator near the ora. Optical coherence tomography (OCT) of the macula showed foveal involvement of the RD (Fig. 1A).

The patient underwent a primary scleral buckle with external drainage of subretinal fluid (SRF) and cryotherapy of the inferior retinal tear. Postoperative month 1, the patient's visual acuity was 20/400, pin

\* Corresponding author. USC Roski Eye Institute, 1450 San Pablo Street, Los Angeles, CA, 90033, USA.

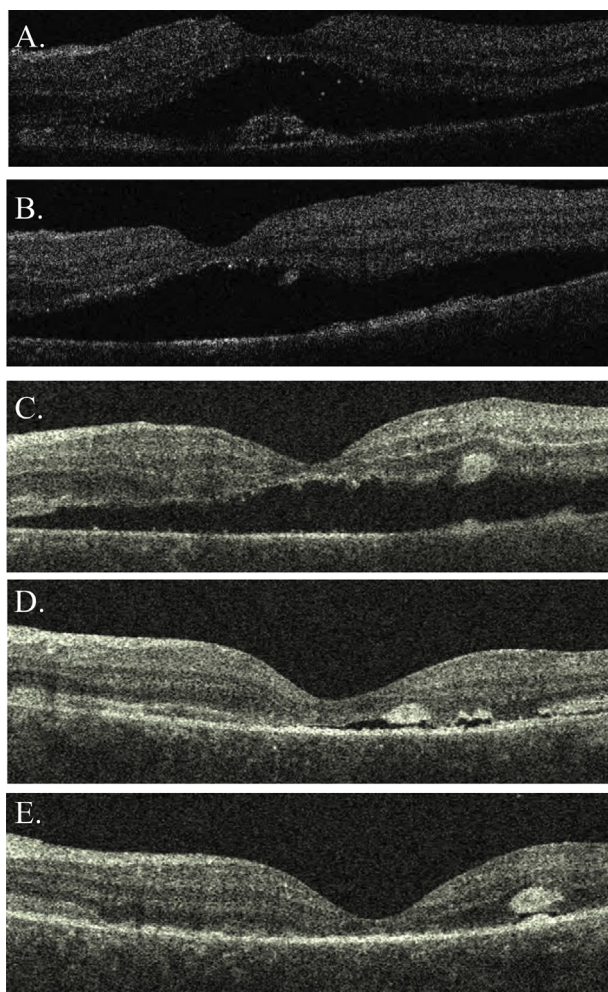
E-mail address: [ameri@med.usc.edu](mailto:ameri@med.usc.edu) (H. Ameri).

<https://doi.org/10.1016/j.ajoc.2018.03.012>

Received 6 November 2017; Received in revised form 3 March 2018; Accepted 8 March 2018

Available online 09 March 2018

2451-9936/ © 2018 Published by Elsevier Inc. This is an open access article under the CC BY-NC-ND license (<http://creativecommons.org/licenses/by-nc-nd/4.0/>).



**Fig. 1.** Optical coherence tomography (OCT) macula of the left eye showing the extent of subretinal fluid at various time points including A. on initial presentation, B. 1 month postoperatively following retinal detachment repair surgery, C. 1.5 years after initial presentation, D. 1 month following oral eplerenone treatment, and E. 2 months following oral eplerenone treatment.

holing to 20/200. Persistent subfoveal SRF was noted in the inferior macula (Fig. 1B). Patient was subsequently lost to follow-up.

Upon return to the clinic 1.5 years later, there was no improvement of the SRF (Fig. 1C) and the vision had decreased to hand motion. Partial success of the off-label use of eplerenone in resolving SRF in CSCR was explained to the patient who expressed interest in a trial of this medication. One month following 50 mg po daily eplerenone, there was significant improvement in the SRF (Fig. 1D) but the patient's vision remained poor at hand motion. After two months of treatment, the extent of SRF continued to improve and subfoveal fluid resolved completely (Fig. 1E) but visual acuity remained unchanged. At this point, however, the patient developed symptoms of breast pain and polyuria; thus, the dose of eplerenone was decreased to 25 mg daily. Unfortunately, patient was lost to follow-up thereafter.

## 2. Discussion

In this case presentation, a short course of eplerenone therapy led to a remarkably rapid resolution of SRF which had been persistent for at least 1.5 years following primary scleral buckle for an RRD that transpired perhaps a year prior to initial presentation.

Understanding the mechanism by which the anti-mineralocorticoid effect of eplerenone may promote resolution of persistent SRF following RRD repair may best be understood in the context of SRF secondary to

CSCR. The pathophysiology behind CSCR is incompletely understood; however, choroidal vasculopathy, disruption in RPE pump function, as well as alterations in paracellular permeability through tight junctions are all thought to contribute.<sup>8</sup> Mineralocorticoid receptors have been shown to be expressed in several cell types in the neuroretina, including Müller glial cells where they control potassium and water homeostasis through regulation of ion and water channels.<sup>8,9</sup> Mineralocorticoid activity has been shown to enhance choroidal vessel and choriocapillary vasodilation and leakage which further propagate the disease process in CSCR.<sup>8</sup> Thus, inhibition of mineralocorticoid activity in CSCR has the therapeutic benefit of limiting choriocapillary vasodilation and permeability, regulating fluid permeability and effusion in the neurosensory retina. The pattern of subretinal RPE cell proliferation and morphological changes in persistent SRF following an RRD suggests a target by which a mineralocorticoid antagonist may similarly modify cellular pump function and vascular permeability in this disease process.

A case report by Kapoor and Wagner demonstrated improvement in the extent of SRF in a patient diagnosed with polypoidal choroidal vasculopathy treated with both intravitreal Avastin and oral eplerenone.<sup>10</sup> In a separate case report, Kapoor and Wagner also documented the possible adjunctive benefit of including oral eplerenone alongside anti-VEGF agents in the setting of chronic SRF associated with neovascular age-related macular degeneration (AMD).<sup>11</sup> To our knowledge, however, our case report is the first to document a beneficial role of eplerenone in the resolution of persistent SRF following surgical repair of an RRD.

The etiology and composition of SRF after RRD repair is distinct from that of both CSCR and neovascular AMD. However, we postulate that similar tol leakage may play a role in the delayed or lack of resorption of SRF in cases similar to ours. This hypothesis is supported by the aforementioned disease processes, decreased RPE pump function or increased choroidal qualitative increased choroidal thickness measured on OCT images taken from both the affected and unaffected eyes of the patient. While we cannot definitely rule out a concomitant pathology such as CSCR in this case, the absence of features such as PEDs, pigmentary or autofluorescence changes, and absence of associated risk factors make this possibility less likely.

Since the patient was lost to follow up, we were unable to determine possible recurrence of SRF following discontinuation of eplerenone. While there was almost complete resolution of the SRF following 2 months of eplerenone use, the final visual acuity did not improve and outer retinal structural abnormalities persisted. The poor visual acuity and morphological changes observed in the neuroretina may be more difficult to normalize in cases such as ours in which fluid persisted for over a year and retinal degeneration has occurred. Thus, it is worth investigating further the role and timing of eplerenone treatment in cases of persistent SRF following RRD surgery to optimize visual and structural outcomes. A number of studies have shown eplerenone and spironolactone—an alternative mineralocorticoid antagonist—to be effective in both the resolution of SRF in CSCR and improvement in final visual acuity.<sup>12</sup> Thus one can speculate that early intervention prior to RPE and photoreceptor atrophy in cases of persistent SRF following retinal detachment surgery may result in similarly improved visual outcomes.

## 3. Conclusions

In Summary, our case demonstrates that 50 mg oral daily dose of eplerenone may be effective in speedy resolution of persistent SRF following RRD repair. Further studies are needed to determine the timing and effectiveness of this treatment in restoring retinal structure and visual function.

## Acknowledgments and Disclosures

### Patient consent

Written consent to publish this case has not been obtained. The report does not contain any personal identifying information.

### Funding

Unrestricted Departmental Grant from Research to Prevent Blindness. No other financial disclosures.

### Conflict of interest

The following authors have no financial disclosures: AH, JD, HA.

### Authorship

All authors attest that they meet the current ICMJE criteria for Authorship.

## Acknowledgments

None.

## Appendix A. Supplementary data

Supplementary data related to this article can be found at <http://dx>.

[doi.org/10.1016/j.ajoc.2018.03.012](https://doi.org/10.1016/j.ajoc.2018.03.012).

## References

- [1]. Gharbiya M, Malagola R, Mariotti C, et al. Spectral-domain optical coherence tomography analysis of persistent subretinal fluid after scleral buckling surgery for macula-off retinal detachment. *Eye*. 2015;29:1186–1193.
- [2]. Ricker LJ, Noordzij LJ, Goezinne F, et al. Persistent subfoveal fluid and increased preoperative foveal thickness impair visual outcome after macula-off retinal detachment repair. *Retina*. 2011;31:1505–1512.
- [3]. Anderson DH, Stern WH, Fisher SK, et al. Retinal detachment in the cat: the pigment epithelial-photoreceptor interface. *Invest Ophthalmol Vis Sci*. 1983;24:906–926.
- [4]. Immel J, Negi A, Marmor MF. Acute changes in RPE apical morphology after retinal detachment in rabbit. A SEM study. *Invest Ophthalmol Vis Sci*. 1986;27:1770–1776.
- [5]. Veckeneer M, Derycke L, Lindstedt EW, et al. Persistent subretinal fluid after surgery for rhegmatogenous retinal detachment: hypothesis and review. *Graefes Arch Clin Exp Ophthalmol*. 2012;250:795–802.
- [6]. Quintyn JC, Brasseur G. Subretinal fluid in primary rhegmatogenous retinal detachment: physiopathology and composition. *Surv Ophthalmol*. 2004;49:96–108.
- [7]. Sethi C, Lewis GP, Fisher SK, et al. Glial remodeling and neural plasticity in human retinal detachment with proliferative vitreoretinopathy. *Invest Ophthalmol Vis Sci*. 2005;46:329–342.
- [8]. Zhao M, Celerier I, Bousquet E, et al. Mineralocorticoid receptor is involved in rat and human ocular choreoretinopathy. *J Clin Invest*. 2012;122(7):2672–2679.
- [9]. Zhao M, Valamanesh F, Celerier I, et al. The neuroretina is a novel mineralocorticoid target: aldosterone up-regulates ion and water channels in Muller glial cells. *Faseb J*. 2010;24(9):3405–3415.
- [10]. Kapoor K, Wagner A. Eplerone in the treatment of polypoidal choroidal vasculopathy. *Case Rep Ophthalmol*. 2015;6:477–481.
- [11]. Kapoor K, Todi N, Wagner A. Mineralocorticoid antagonists as adjuncts in neovascular age-related macular degeneration. *Ophthalmol Ther*. 2017;6:141–146.
- [12]. Yang D, Elliott D. Systemic mineralocorticoid antagonists in the treatment of central serous chorioretinopathy. *Semin Ophthalmol*. 2017;32(1):36–42.