

# UCSF

## UC San Francisco Previously Published Works

### Title

NCCN Guidelines Insights: Hepatobiliary Cancers, Version 1.2017.

### Permalink

<https://escholarship.org/uc/item/1nz179nk>

### Journal

Journal of the National Comprehensive Cancer Network, 15(5)

### ISSN

1540-1405

### Authors

Benson, Al B  
D'Angelica, Michael I  
Abbott, Daniel E  
et al.

### Publication Date

2017-05-01

### DOI

10.6004/jnccn.2017.0059

Peer reviewed



Published in final edited form as:

*J Natl Compr Canc Netw*. 2017 May ; 15(5): 563–573.

## Hepatobiliary Cancers, Version 1.2017:

### Featured Updates to the NCCN Guidelines

Al B. Benson III, MD<sup>1,\*</sup>, Michael I. D’Angelica, MD<sup>2,\*</sup>, Daniel E. Abbott, MD<sup>3,\*</sup>, Thomas A. Abrams, MD<sup>4</sup>, Steven R. Alberts, MD, MPH<sup>5</sup>, Daniel Anaya Saenz, MD<sup>6</sup>, Chandrakanth Are, MD<sup>7</sup>, Daniel B. Brown, MD<sup>8,\*</sup>, Daniel T. Chang, MD<sup>9,\*</sup>, Anne M. Covey, MD<sup>2,\*</sup>, William Hawkins, MD<sup>10</sup>, Renuka Iyer, MD<sup>11</sup>, Rojymon Jacob, MD<sup>12</sup>, Andrea Karachristos, MD<sup>13</sup>, R. Kate Kelley, MD<sup>14,\*</sup>, Robin Kim, MD<sup>15</sup>, Manisha Palta, MD<sup>16,\*</sup>, James O. Park, MD<sup>17</sup>, Vaibhav Sahai, MD, MS<sup>18,\*</sup>, Tracey Schefter, MD<sup>19</sup>, Carl Schmidt, MD<sup>20</sup>, Jason K. Sicklick, MD<sup>21</sup>, Gagandeep Singh, MD<sup>22</sup>, Davendra Sohal, MD, MPH<sup>23</sup>, Stacey Stein, MD<sup>24</sup>, G. Gary Tian, MD, PhD<sup>25</sup>, Jean-Nicolas Vauthey, MD<sup>26,\*</sup>, Alan P. Venook, MD<sup>14</sup>, Andrew X. Zhu, MD, PhD<sup>27</sup>, Karin G. Hoffmann, RN, CCM<sup>28,\*</sup>, and Susan Darlow, PhD<sup>28,\*</sup>

<sup>1</sup>Robert H. Lurie Comprehensive Cancer Center of Northwestern University

<sup>2</sup>Memorial Sloan Kettering Cancer Center

<sup>3</sup>University of Wisconsin Carbone Cancer Center

<sup>4</sup>Dana-Farber/Brigham and Women’s Cancer Center

<sup>5</sup>Mayo Clinic Cancer Center

<sup>6</sup>Moffitt Cancer Center

<sup>7</sup>Fred & Pamela Buffett Cancer Center

<sup>8</sup>Vanderbilt-Ingram Cancer Center

<sup>9</sup>Stanford Cancer Institute

<sup>10</sup>Siteman Cancer Center at Barnes-Jewish Hospital and Washington University School of Medicine

<sup>11</sup>Roswell Park Cancer Institute

<sup>12</sup>University of Alabama at Birmingham Comprehensive Cancer Center

<sup>13</sup>Fox Chase Cancer Center

<sup>14</sup>UCSF Helen Diller Family Comprehensive Cancer Center

<sup>15</sup>Huntsman Cancer Institute at the University of Utah

<sup>16</sup>Duke Cancer Institute

<sup>17</sup>Fred Hutchinson Cancer Research Center/Seattle Cancer Care Alliance

<sup>18</sup>University of Michigan Comprehensive Cancer Center

\*Provided content development and/or authorship assistance.

<sup>19</sup>University of Colorado Cancer Center

<sup>20</sup>The Ohio State University Comprehensive Cancer Center - James Cancer Hospital and Solove Research Institute

<sup>21</sup>UC San Diego Moores Cancer Center

<sup>22</sup>City of Hope Comprehensive Cancer Center

<sup>23</sup>Case Comprehensive Cancer Center/University Hospitals Seidman Cancer Center and Cleveland Clinic Taussig Cancer Institute

<sup>24</sup>Yale Cancer Center/Smilow Cancer Hospital

<sup>25</sup>St. Jude Children's Research Hospital/The University of Tennessee Health Science Center

<sup>26</sup>The University of Texas MD Anderson Cancer Center

<sup>27</sup>Massachusetts General Hospital Cancer Center

<sup>28</sup>National Comprehensive Cancer Network

## Abstract

The NCCN Guidelines for Hepatobiliary Cancers provide treatment recommendations for cancers of the liver, gallbladder, and bile ducts. The NCCN Hepatobiliary Cancers Panel meets at least annually to review comments from reviewers within their institutions, examine relevant new data from publications and abstracts, and reevaluate and update their recommendations. These NCCN Guidelines Insights summarize the panel's discussion and most recent recommendations regarding locoregional therapy for treatment of patients with hepatocellular carcinoma.

---

## Overview

Incidence and mortality rates for cancer overall are declining, but rates for hepatocellular carcinoma (HCC) are increasing.<sup>1</sup> Risk factors for the development of HCC include viral infections such as those caused by hepatitis B virus and/or hepatitis C virus, and cirrhosis from any cause (eg, alcohol cirrhosis).<sup>2</sup> Some nonviral causes include inherited errors of metabolism (relatively rare), such as hereditary hemochromatosis, porphyria cutanea tarda, and alpha-1 antitrypsin deficiency; Wilson disease; and stage IV primary biliary cirrhosis.<sup>3</sup> There is growing evidence for an association between the sequelae of nonalcoholic fatty liver disease, such as nonalcoholic steatohepatitis (a spectrum of conditions characterized by histologic findings of hepatic steatosis with inflammation in individuals who consume little or no alcohol) in the setting of metabolic syndrome or diabetes mellitus and the development of HCC.<sup>4,5</sup>

## HCC Treatment

The management of patients with HCC is complicated by the presence of underlying liver disease. Furthermore, it is possible that the different etiologies of HCC and their effects on the host liver may impact treatment response and outcome. The treatment of patients with HCC often necessitates multidisciplinary care with the involvement of hepatologists,

diagnostic and interventional radiologists, transplant surgeons, pathologists, and medical and surgical oncologists, thereby requiring careful coordination of care.<sup>6</sup>

The NCCN panel considers locoregional therapy to be the preferred approach for treating patients with unresectable disease confined to the liver (category 2A; see HCC-5; page 565). Locoregional therapies are directed toward inducing selective tumor necrosis and are broadly classified into ablation and arterially directed therapies (both category 2A options). External-beam radiation therapy (EBRT) is recommended as a category 2B option. A number of factors are involved in measuring the effectiveness of locoregional therapies, and the criteria for evaluating tumor response are evolving.<sup>7-11</sup> Patients with extensive intrahepatic disease burden and/or significant vascular involvement (eg, extensive main portal vein involvement) may not be appropriate for locoregional therapies and should be evaluated for systemic therapy.

### Ablation

Radiofrequency ablation (RFA) and percutaneous alcohol injection (PEI) are 2 commonly used ablation therapies for HCC. The safety and efficacy of RFA and PEI in the treatment of Child-Pugh class A patients with early-stage HCC tumors (either a single tumor  $\leq 5$  cm or multiple tumors [up to 3 tumors] each  $\leq 3$  cm) has been compared in a number of randomized controlled trials (RCTs).<sup>12-19</sup> Independent meta-analyses of randomized trials that have compared RFA and PEI have concluded that RFA is superior to PEI with respect to overall survival (OS) and tumor response in patients with early-stage HCC, particularly for tumors  $>2$  cm.<sup>20-22</sup> Results of some long-term studies show survival rates of  $>50\%$  at 5 years for patients with early-stage HCC treated with RFA.<sup>23-26</sup> However, the reported OS and recurrence rates vary widely across studies for patients treated with RFA, which is most likely due to differences in the size and number of tumors and, perhaps more importantly, tumor biology and the extent of underlying liver function. In multivariate analysis, Child-Pugh class, tumor size, and tumor number were independent predictors of survival.<sup>24-26</sup>

Some investigators consider RFA as the first-line treatment in highly selected patients with HCC tumors  $\leq 2$  cm in diameter, in an accessible location, and away from major biliary structures.<sup>27,28</sup> In one study, RFA as the initial treatment in 218 patients with a single HCC lesion  $\leq 2$  cm induced complete necrosis in 98% of patients.<sup>27</sup> After a median followup of 31 months, the sustained complete response (CR) rate was 97%. More recently, in a retrospective comparative study, Peng et al<sup>28</sup> reported that percutaneous RFA was better than resection in terms of OS and recurrence-free survival (RFS), especially for patients with central HCC tumors  $<2$  cm. The 5-year OS rates in patients with central HCC tumors were 80% for RFA compared with 62% for resection ( $P=.02$ ); corresponding RFS rates were 67% and 40%, respectively ( $P=.033$ ). Cryoablation may be safe and effective for small lesions, but studies are inconsistent regarding how outcomes compare with those for RFA.<sup>29</sup>

Microwave ablation (MWA) is emerging as an alternative to RFA for the treatment of patients with small or unresectable HCC.<sup>30-34</sup> So far, only 2 randomized trials have compared MWA with resection and RFA.<sup>30,34</sup> In the RCT that compared RFA with percutaneous microwave coagulation, no significant differences were observed between these 2 procedures in terms of therapeutic effects, complication rates, and rates of residual

foci of untreated disease.<sup>30</sup> In a recent randomized study that evaluated the efficacy of MWA and resection in the treatment of HCC conforming to Milan criteria, MWA was associated with lower disease-free survival (DFS) rates than resection with no differences in OS rates.<sup>34</sup>

Panel consensus is that evidence (although inconclusive) suggests that the choice of ablative therapy for patients with early-stage HCC should be based on tumor size and location, as well as underlying liver function, and overall management should be considered in the context of a multidisciplinary review and institutional expertise.<sup>35,36</sup> Ablative therapies are most effective for tumors <3 cm (preferably <2 cm) that are in an appropriate location away from other organs and major vessels/bile ducts. All tumors should be amenable to ablation such that the tumor and, in the case of thermal ablation, a margin of normal tissue is treated. Tumors should be in a location accessible for laparoscopic, percutaneous, or open approaches. Lesions in certain portions of the liver may not be accessible for ablation. Similarly, ablative treatment of tumors located on the liver capsule may cause tumor rupture with track seeding. Tumor seeding along the needle track has been reported in <1% of patients with HCC treated with RFA.<sup>37-39</sup> Lesions with subcapsular location and poor differentiation seem to be at higher risk for this complication.<sup>37</sup> During an ablation procedure, major vessels in proximity to the tumor can absorb large amounts of heat (ie, the “heat sink effect”), which can decrease the effectiveness and significantly increase local recurrence rates.<sup>40,41</sup> The panel emphasizes that caution should be exercised when ablating lesions near major bile ducts and other intra-abdominal organs, such as the colon, stomach, diaphragm, heart, and gallbladder, to decrease complications.

### Arterially Directed Therapies

Arterially directed therapy involves the selective catheter-based infusion of particles targeted to the arterial branch of the hepatic artery feeding the portion of the liver in which the tumor is located.<sup>42</sup> Arterially directed therapy is made possible by the dual blood supply to the liver. Furthermore, HCC tumors are hypervascular resulting from increased blood flow to tumor relative to normal liver tissue. Arterially directed therapies currently in use include transarterial bland embolization (TAE), transarterial chemoembolization (TACE), TACE with drug-eluting beads (DEB-TACE), and transarterial radioembolization (TARE) with yttrium-90 microspheres.

The principle of TAE is to reduce or eliminate blood flow to the tumor, resulting in tumor ischemia followed by tumor necrosis. TAE has been shown to be an effective treatment option for patients with unresectable HCC.<sup>43-46</sup> TACE is distinguished from TAE in that the goal of TACE is to deliver a highly concentrated dose of chemotherapy to tumor cells, prolong the contact time between the chemotherapeutic agents and the cancer cells, and minimize systemic toxicity of chemotherapy.<sup>47</sup> Results of 2 randomized clinical trials have shown a survival benefit for TACE compared with supportive care in patients with unresectable HCC.<sup>48,49</sup> Many of the clinical studies evaluating the effectiveness of TAE and/or TACE in the treatment of patients with HCC are confounded by the use of a wide range of treatment strategies, including types of embolic particles, chemotherapy, and emulsifying agents (for studies involving TACE), and number of treatment sessions. The relative effectiveness of TACE over TAE has not been established in randomized trials.

TACE causes increased hypoxia leading to an upregulation of vascular endothelial growth factor receptor (VEGFR) and insulin-like growth factor receptor 2 (IGFR-2).<sup>50</sup> Increased plasma levels of VEGFR and IGFR-2 have been associated with the development of metastasis after TACE.<sup>51,52</sup> These findings have led to the evaluation of TACE in combination with sorafenib in patients with residual or recurrent tumor not amenable to additional locoregional therapies.<sup>53–60</sup> Results from nonrandomized phase II studies and a retrospective analysis suggest that concurrent administration of sorafenib with TACE or DEB-TACE may be a treatment option for patients with unresectable HCC.<sup>54–61</sup> However, in a phase III randomized trial, when given after treatment with TACE, sorafenib did not significantly prolong time to progression or OS in patients with unresectable HCC that responded to TACE.<sup>60</sup>

DEB-TACE has also been evaluated in patients with unresectable HCC.<sup>62–69</sup> In a randomized study (PRECISION V) of 212 patients with localized unresectable HCC with Child-Pugh class A or B cirrhosis and without nodal involvement, TACE with doxorubicin-eluting embolic beads induced statistically nonsignificant higher rates of CR, objective response, and disease control compared with conventional TACE with doxorubicin (27% vs 22%; 52% vs 44%; and 63% vs 52%, respectively).<sup>64</sup> Overall, DEB-TACE was not superior to conventional TACE with doxorubicin in this study. However, DEB-TACE was associated with a significant increase in objective response ( $P=.038$ ) compared with conventional TACE in patients with Child-Pugh class B, ECOG performance status (PS) 1, bilobar disease, and recurrent disease. DEB-TACE was also associated with improved tolerability with a significant reduction in serious liver toxicity and a significantly lower rate of doxorubicin-related side effects compared with conventional TACE.<sup>64</sup> A recent randomized study compared DEB-TACE versus conventional TACE in 177 patients with intermediate-stage unresectable, persistent, or recurrent HCC. The study revealed no significant efficacy or safety differences between the approaches; however, DEB-TACE was associated with less postprocedural abdominal pain.<sup>69</sup> Conversely, Dhanasekaran et al<sup>66</sup> reported a survival advantage for DEB-TACE over conventional TACE in a prospective randomized study of 71 patients with unresectable HCC. However, these results are from underpowered studies and need to be confirmed in large prospective studies. A recent randomized trial comparing the effectiveness of TAE with that of doxorubicin-based TACE in 101 patients with HCC<sup>70</sup> found no statistically significant differences in response, progression-free survival (PFS), and OS between the groups.

TARE is a method that involves internal delivery of high-dose beta radiation to the tumor-associated capillary bed, thereby sparing the normal liver tissue.<sup>42,71</sup> TARE is accomplished through the catheter-based administration of microspheres (glass or resin microspheres) embedded with yttrium-90, an emitter of beta radiation. A growing body of literature suggests that radioembolization might be an effective treatment option for patients with liver-limited, unresectable disease,<sup>72–77</sup> but additional randomized clinical trials are needed to determine the harms and benefits of TARE with yttrium-90 micro-spheres in patients with unresectable HCC.<sup>78</sup> Although radioembolization with yttrium-90 microspheres, such as TAE and TACE, involves some level of particle-induced vascular occlusion, it has been proposed that such occlusion is more likely to be microvascular than macrovascular, and that the resulting tumor necrosis is more likely to be induced by radiation rather than ischemia.<sup>72</sup>

Reported complications of TARE include cholecystitis/bilirubin toxicity, gastrointestinal ulceration, and abscess formation.<sup>72,74,79</sup> TARE with yttrium-90 microspheres has an increased risk of radiation-induced liver disease in patients with bilirubin >2 mg/dL.<sup>74</sup>

All HCC tumors, irrespective of location in the liver, may be amenable to arterially directed therapies, provided that the arterial blood supply to the tumor can be isolated.<sup>45,49,72,80</sup> Complications common to TAE and TACE include nontarget embolization (including cholecystitis); complications after TACE include acute portal vein thrombosis (PVT), bone marrow suppression, and pancreatitis (very rare), although the reported frequencies of serious adverse events vary across studies.<sup>81,82</sup> A postembolization syndrome involving fever, abdominal pain, and intestinal ileus is relatively common in patients undergoing these procedures.<sup>81,82</sup> TAE or TACE can increase the risk of liver failure, hepatic necrosis, and liver abscess formation in patients with biliary obstruction; therefore, the panel recommends that a total bilirubin level >3 mg/mL be considered a relative contraindication for TACE and TAE unless segmental injections can be performed. Minimal extrahepatic disease is considered a “relative” contraindication for arterially directed therapies. Arterially directed therapies are relatively contraindicated in patients with main PVT and are contraindicated in patients with Child-Pugh class C cirrhosis.<sup>83</sup>

Tumors between 3 and 5 cm may be treated with a combination of ablation and arterially directed therapies to prolong survival, as long as the tumor location is favorable to ablation.<sup>84–86</sup> The panel recommends that patients with unresectable or inoperable lesions >5 cm be considered for treatment using arterially directed therapies or systemic therapy. An evaluation of the arterial anatomy of the liver, patient PS, and liver function is necessary before the arterially directed therapy. In addition, more individualized patient selection that is specific to the particular arterially directed therapy being considered is necessary to avoid significant treatment-related toxicity.

Locoregional therapy may be used as part of downstaging therapy, which is used to reduce the tumor burden in selected patients with more advanced HCC (without distant metastasis) who are beyond the accepted liver transplant criteria.<sup>87,88</sup> Prospective studies have demonstrated that downstaging (before transplant) with PEI,<sup>89</sup> RFA,<sup>89,90</sup> TACE,<sup>89–92</sup> TARE with yttrium-90 microspheres,<sup>92</sup> and transarterial chemoinfusion<sup>93</sup> improves DFS after transplant. However, such studies have used different selection criteria for the downstaging therapy and different transplant criteria after successful downstaging. Further validation is needed to define the end points for successful downstaging before transplant.

### External-Beam Radiation Therapy

EBRT allows focal administration of high-dose radiation to liver tumors while sparing surrounding liver tissue, thereby limiting the risk of radiation-induced liver damage in patients with unresectable or inoperable HCC.<sup>94,95</sup> Advances in EBRT, such as intensity-modulated radiation therapy (IMRT), have allowed for enhanced delivery of higher radiation doses to the tumor while sparing surrounding critical tissue. Stereotactic body radiation therapy (SBRT) is an advanced technique of EBRT that delivers large ablative doses of radiation. There is growing evidence (primarily from non-RCTs) supporting the usefulness of SBRT for patients with unresectable, locally advanced, or recurrent HCC.<sup>96–100</sup>

In a phase II trial of 50 patients with inoperable HCC treated with SBRT after incomplete TACE, SBRT induced CRs and partial responses in 38.3% of patients within 6 months of completing SBRT.<sup>99</sup> The 2-year local control rate, OS, and PFS rates were 94.6%, 68.7%, and 33.8%, respectively. In another study that evaluated the long-term efficacy of SBRT for patients with primarily small HCC ineligible for local therapy or surgery (42 patients), SBRT induced an overall CR rate of 33%, with 1- and 3-year OS rates of 92.9% and 58.6%, respectively.<sup>96</sup> In patients with recurrent HCC treated with SBRT, tumor size, recurrent stage, and Child-Pugh classification were identified as independent prognostic factors for OS in multivariate analysis.<sup>98</sup> A retrospective analysis comparing RFA and SBRT in 224 patients with inoperable, nonmetastatic HCC showed that SBRT may be a preferred option for tumors  $\leq 2$  cm.<sup>101</sup> SBRT has also been shown to be an effective bridging therapy for patients with HCC and cirrhosis awaiting liver transplant.<sup>102–104</sup>

Most safety and efficacy data on the use of SBRT are available for patients with HCC and Child-Pugh class A liver function; limited safety data are available for the use of SBRT in patients with Child-Pugh class B or poorer liver function.<sup>97,100,105–107</sup> Those with Child-Pugh class B cirrhosis can safely be treated but may require dose modifications and strict dose constraint adherence. The safety of SBRT for patients with Child-Pugh class C cirrhosis has not been established, because clinical trials are not likely to be available for this group of patients with a very poor prognosis.

In 2014, American Society for Radiation Oncology (ASTRO) released a model policy supporting the use of proton beam therapy (PBT) in some oncology populations.<sup>108</sup> In a recent phase II study, 94.8% of patients with unresectable HCC who received high-dose hypofractionated PBT demonstrated  $>80\%$  local control after 2 years, as defined by RECIST criteria.<sup>109</sup> In a recent meta-analysis including 70 studies, charged particle therapy (mostly including PBT) was compared with SBRT and conventional radiotherapy.<sup>110</sup> OS (relative risk [RR], 25.9; 95% CI, 1.64–408.5;  $P=.02$ ), PFS (RR, 1.86; 95% CI, 1.08–3.22;  $P=.013$ ), and locoregional control (RR, 4.30; 95% CI, 2.09–8.84;  $P<.001$ ) through 5 years were greater for charged particle therapy than for conventional radiotherapy. No significant differences in these outcomes were seen between charged particle therapy and SBRT. Analyses from a prospective RCT including 69 patients with HCC showed that PBT tended to be associated with improved 2-year local control ( $P=.06$ ), better PFS ( $P=.06$ ), and fewer hospitalization days after treatment ( $P<.001$ ) compared with TACE.<sup>111</sup> The panel advises that PBT may be considered and appropriate in select settings for treating HCC. During the 2017 panel meeting, the panel discussed the role of PBT in HCC treatment and decided to add a statement in the “Principles of Locoregional Therapy” emphasizing the importance of centers with experience (see HCC-E 2 of 3; page 566). Several ongoing studies are continuing to investigate the impact of hypofractionated PBT on HCC outcomes (eg, ClinicalTrials.gov identifiers: NCT02395523 and NCT02632864), including randomized trials comparing PBT versus RFA (NCT02640924) and PBT versus TACE (NCT00857805).

All tumors, irrespective of their location, may be amenable to SBRT, IMRT, or 3-dimensional conformal RT. The panel recommends EBRT as a category 2B recommendation for patients with unresectable disease or those who are medically inoperable due to comorbidity. The panel recommends that SBRT can be considered as an alternative to



ablation and/ or embolization techniques or when these therapies have failed or are contraindicated (in patients with unresectable disease characterized as extensive or otherwise not suitable for liver transplantation, and those with local disease but who are not considered candidates for surgery due to PS or comorbidity). SBRT (1–5 fractions) is often used for patients with 1 to 3 tumors with minimal or no extrahepatic disease. There is no strict size limit, so SBRT may be used for larger lesions if there is sufficient uninvolved liver and liver radiation dose constraints can be respected. The panel encourages prospective clinical trials evaluating the role of SBRT in patients with unresectable, locally advanced, or recurrent HCC. Palliative EBRT is appropriate for symptom control and/or prevention of complications from metastatic HCC lesions in bone or brain.<sup>112</sup>

## Summary

For patients not amenable to surgery or liver transplantation, locoregional therapy (eg, ablation, arterially directed therapies, and EBRT) is the preferred treatment approach. Ablation alone may be curative in select patients with small tumors, whereas embolization is generally not considered curative. Tumors between 3 and 5 cm may be treated with a combination of ablation and arterially directed therapies to prolong survival, as long as the tumor location is favorable to ablation, and patients with unresectable or inoperable lesions >5 cm should be considered for treatment using arterially directed therapies or systemic therapy. Advances in EBRT, such as IMRT, have allowed for enhanced delivery of higher radiation doses to the tumor while reducing damage to surrounding critical tissue. Evidence supports the usefulness of SBRT and PBT for treatment of patients with unresectable HCC.

## Acknowledgments

This activity is supported by educational grants from Astellas, AstraZeneca, Celldex Therapeutics, Clovis Oncology, Genomic Health, Inc., Kyowa Hakkō Kirin, Jazz Pharmaceuticals, Novartis Pharmaceuticals Corporation, and NOVOCURE. This activity is supported by an independent educational grant from Merck Co., Inc.

## Please Note

The NCCN Clinical Practice Guidelines in Oncology (NCCN Guidelines<sup>®</sup>) are a statement of consensus of the authors regarding their views of currently accepted approaches to treatment. The NCCN Guidelines<sup>®</sup> Insights highlight important changes to the NCCN Guidelines<sup>®</sup> recommendations from previous versions. Colored markings in the algorithm show changes and the discussion aims to further the understanding of these changes by summarizing salient portions of the NCCN Guideline Panel discussion, including the literature reviewed.

These NCCN Guidelines Insights do not represent the full NCCN Guidelines; further, the National Comprehensive Cancer Network<sup>®</sup> (NCCN<sup>®</sup>) makes no representation or warranties of any kind regarding the content, use, or application of the NCCN Guidelines and NCCN Guidelines Insights and disclaims any responsibility for their applications or use in any way.

**The full and most current version of these NCCN Guidelines are available at [NCCN.org](http://NCCN.org).**

## Disclosure of Relevant Financial Relationships

### Editor

**Kerrin M. Green, MA**, Assistant Managing Editor, *JNCCN—Journal of the National Comprehensive Cancer Network*, has disclosed that she has no relevant financial relationships.

### JNCCN

**Kimberly Callan, MS**, Senior Director, Professional and Patient Publications, NCCN, has disclosed that she has no relevant financial relationships.

**Genevieve Emberger Hartzman, MA**, Journal Production Specialist, NCCN, has disclosed that she has no relevant financial relationships.

### CE Authors

**Deborah J. Moonan, RN, BSN**, Director, Continuing Education, NCCN, has disclosed that she has no relevant financial relationships. (Employed by NCCN until 2/17/17.)

**Karen Kanefield**, Manager, Continuing Education Accreditation and Program Operations, NCCN, has disclosed that she has no relevant financial relationships.

**Kathy Smith**, Manager, CE Grant Writing & Project Management, NCCN, has disclosed that she has no relevant financial relationships.

**Kristina M. Gregory, RN, MSN, OCN**, Vice President, Clinical Information Operations, NCCN, has disclosed that she has no relevant financial relationships.

**Rashmi Kumar, PhD**, Director, Clinical Information Operations, NCCN, has disclosed that she has no relevant financial relationships.

## Individuals Who Provided Content Development and/or Authorship

### Assistance

**Al B. Benson III, MD**, Panel Chair, has disclosed that he receives grant/research support from Advanced Accelerator Applications SA, Alchemia, Amgen Inc., Gilead, and Novartis Pharmaceuticals Corporation; receives consulting fees/honoraria from Astellas and Aveo; and is a scientific advisor for Bayer HealthCare, Bristol-Myers Squibb Company, Celgene Corporation, Genentech, Inc., Genomic Health, Inc., Lilly/Imclone, Merck & Co., Inc., NCI, Precision Therapeutics, Inc., sanofi-aventis U.S., Spectrum, and Vicus.

**Michael I. D'Angelica, MD**, Panel Vice Chair, has disclosed that he has no relevant financial relationships.

**Daniel E. Abbott, MD**, Panel Member, has disclosed that he has no relevant financial relationships.

**Daniel B. Brown, MD**, Panel Member, has disclosed that he is on the product/speakers' bureau for Boston Scientific; receives consulting fees/honoraria from Cook Medical; and receives grant/research support from Sirtex Medical.

**Daniel T. Chang, MD**, Panel Member, has disclosed that he receives consulting fees/honoraria, grant/research support, and salary from Varian Medical Systems, Inc.; and receives equity interest/stock options from ViewRay, Inc.

**Anne M. Covey, MD**, Panel Member, has disclosed that she is a scientific advisor for Accurate Medical.

**R. Kate Kelley, MD**, Panel Member, has disclosed that she has no relevant financial relationships.

**Manisha Palta, MD**, Panel Member, has disclosed that she receives other financial benefit from Oakstone CME.

**Vaibhav Sahai, MD, MS**, Panel Member, has disclosed that he receives consulting fees/honoraria from Celgene Corporation and NewLink Genetics; receives grant/research support from Celgene Corporation; and is a scientific advisor for Celgene Corporation and Merrimack.

**Jean-Nicolas Vauthey, MD**, Panel Member, has disclosed that he has no relevant financial relationships.

**Karin G. Hoffmann, RN, CCM**, Guidelines Coordinator, NCCN, has disclosed that she has no relevant financial relationships.

**Susan Darlow, PhD**, Oncology Scientist/Medical Writer, NCCN, has disclosed that she has no relevant financial relationships.

## References

1. Ryerson AB, Ehemann CR, Altekruse SF, et al. Annual Report to the Nation on the Status of Cancer, 1975–2012 featuring the increasing incidence of liver cancer. *Cancer*. 2016; 122:1312–1337. [PubMed: 26959385]
2. Fattovich G, Stroffolini T, Zagni I, Donato F. Hepatocellular carcinoma in cirrhosis: incidence and risk factors. *Gastroenterology*. 2004; 127:S35–50. [PubMed: 15508101]
3. Blonski W, Kotlyar DS, Forde KA. Non-viral causes of hepatocellular carcinoma. *World J Gastroenterol*. 2010; 16:3603–3615. [PubMed: 20677332]
4. Marchesini G, Bugianesi E, Forlani G, et al. Nonalcoholic fatty liver, steatohepatitis, and the metabolic syndrome. *Hepatology*. 2003; 37:917–923. [PubMed: 12668987]
5. Takamatsu S, Noguchi N, Kudoh A, et al. Influence of risk factors for metabolic syndrome and non-alcoholic fatty liver disease on the progression and prognosis of hepatocellular carcinoma. *Hepatogastroenterology*. 2008; 55:609–614. [PubMed: 18613418]
6. Volk ML, Marrero JA. Early detection of liver cancer: diagnosis and management. *Curr Gastroenterol Rep*. 2008; 10:60–66. [PubMed: 18417044]
7. Bruix J, Sherman M, Llovet JM, et al. Clinical management of hepatocellular carcinoma. Conclusions of the Barcelona-2000 EASL conference. European Association for the Study of the Liver. *J Hepatol*. 2001; 35:421–430. [PubMed: 11592607]

8. Eisenhauer EA, Therasse P, Bogaerts J, et al. New response evaluation criteria in solid tumours: revised RECIST guideline (version 1.1). *Eur J Cancer*. 2009; 45:228–247. [PubMed: 19097774]
9. Duke E, Deng J, Ibrahim SM, et al. Agreement between competing imaging measures of response of hepatocellular carcinoma to yttrium-90 radioembolization. *J Vasc Interv Radiol*. 2010; 21:515–521. [PubMed: 20172741]
10. Lencioni R, Llovet JM. Modified RECIST (mRECIST) assessment for hepatocellular carcinoma. *Semin Liver Dis*. 2010; 30:52–60. [PubMed: 20175033]
11. Riaz A, Miller FH, Kulik LM, et al. Imaging response in the primary index lesion and clinical outcomes following transarterial locoregional therapy for hepatocellular carcinoma. *JAMA*. 2010; 303:1062–1069. [PubMed: 20233824]
12. Livraghi T, Goldberg SN, Lazzaroni S, et al. Small hepatocellular carcinoma: treatment with radio-frequency ablation versus ethanol injection. *Radiology*. 1999; 210:655–661. [PubMed: 10207464]
13. Lencioni RA, Allgaier HP, Cioni D, et al. Small hepatocellular carcinoma in cirrhosis: randomized comparison of radio-frequency thermal ablation versus percutaneous ethanol injection. *Radiology*. 2003; 228:235–240. [PubMed: 12759473]
14. Lin SM, Lin CJ, Lin CC, et al. Radiofrequency ablation improves prognosis compared with ethanol injection for hepatocellular carcinoma  $\leq$  4 cm. *Gastroenterology*. 2004; 127:1714–1723. [PubMed: 15578509]
15. Lin SM, Lin CJ, Lin CC, et al. Randomised controlled trial comparing percutaneous radiofrequency thermal ablation, percutaneous ethanol injection, and percutaneous acetic acid injection to treat hepatocellular carcinoma of 3 cm or less. *Gut*. 2005; 54:1151–1156. [PubMed: 16009687]
16. Shiina S, Teratani T, Obi S, et al. A randomized controlled trial of radiofrequency ablation with ethanol injection for small hepatocellular carcinoma. *Gastroenterology*. 2005; 129:122–130. [PubMed: 16012942]
17. Brunello F, Veltri A, Carucci P, et al. Radiofrequency ablation versus ethanol injection for early hepatocellular carcinoma: a randomized controlled trial. *Scand J Gastroenterol*. 2008; 43:727–735. [PubMed: 18569991]
18. Giorgio A, Di Sarno A, De Stefano G, et al. Percutaneous radiofrequency ablation of hepatocellular carcinoma compared to percutaneous ethanol injection in treatment of cirrhotic patients: an Italian randomized controlled trial. *Anticancer Res*. 2011; 31:2291–2295. [PubMed: 21737654]
19. Weis S, Franke A, Mossner J, et al. Radiofrequency (thermal) ablation versus no intervention or other interventions for hepatocellular carcinoma. *Cochrane Database Syst Rev*. 2013; (12) CD003046.
20. Cho YK, Kim JK, Kim MY, et al. Systematic review of randomized trials for hepatocellular carcinoma treated with percutaneous ablation therapies. *Hepatology*. 2009; 49:453–459. [PubMed: 19065676]
21. Orlando A, Leandro G, Olivo M, et al. Radiofrequency thermal ablation vs. percutaneous ethanol injection for small hepatocellular carcinoma in cirrhosis: meta-analysis of randomized controlled trials. *Am J Gastroenterol*. 2009; 104:514–524. [PubMed: 19174803]
22. Germani G, Pleguezuelo M, Gurusamy K, et al. Clinical outcomes of radiofrequency ablation, percutaneous alcohol and acetic acid injection for hepatocellular carcinoma: a meta-analysis. *J Hepatol*. 2010; 52:380–388. [PubMed: 20149473]
23. Peng ZW, Zhang YJ, Chen MS, et al. Radiofrequency ablation as first-line treatment for small solitary hepatocellular carcinoma: long-term results. *Eur J Surg Oncol*. 2010; 36:1054–1060. [PubMed: 20846819]
24. Shiina S, Tateishi R, Arano T, et al. Radiofrequency ablation for hepatocellular carcinoma: 10-year outcome and prognostic factors. *Am J Gastroenterol*. 2012; 107:569–577. [PubMed: 22158026]
25. Brunello F, Cantamessa A, Gaia S, et al. Radiofrequency ablation: technical and clinical long-term outcomes for single hepatocellular carcinoma up to 30 mm. *Eur J Gastroenterol Hepatol*. 2013; 25:842–849. [PubMed: 23442417]

26. Francica G, Saviano A, De Sio I, et al. Long-term effectiveness of radiofrequency ablation for solitary small hepatocellular carcinoma: a retrospective analysis of 363 patients. *Dig Liver Dis.* 2013; 45:336–341. [PubMed: 23245589]
27. Livraghi T, Meloni F, Di Stasi M, et al. Sustained complete response and complications rates after radiofrequency ablation of very early hepatocellular carcinoma in cirrhosis: is resection still the treatment of choice? *Hepatology.* 2008; 47:82–89. [PubMed: 18008357]
28. Peng ZW, Lin XJ, Zhang YJ, et al. Radiofrequency ablation versus hepatic resection for the treatment of hepatocellular carcinomas 2 cm or smaller: a retrospective comparative study. *Radiology.* 2012; 262:1022–1033. [PubMed: 22357902]
29. Wang C, Wang H, Yang W, et al. Multicenter randomized controlled trial of percutaneous cryoablation versus radiofrequency ablation in hepatocellular carcinoma. *Hepatology.* 2015; 61:1579–1590. [PubMed: 25284802]
30. Shibata T, Iimuro Y, Yamamoto Y, et al. Small hepatocellular carcinoma: comparison of radiofrequency ablation and percutaneous microwave coagulation therapy. *Radiology.* 2002; 223:331–337. [PubMed: 11997534]
31. Ding J, Jing X, Liu J, et al. Comparison of two different thermal techniques for the treatment of hepatocellular carcinoma. *Eur J Radiol.* 2013; 82:1379–1384. [PubMed: 23726122]
32. Groeschl RT, Pilgrim CH, Hanna EM, et al. Microwave ablation for hepatic malignancies: a multiinstitutional analysis. *Ann Surg.* 2014; 259:1195–1200. [PubMed: 24096760]
33. Zhang L, Wang N, Shen Q, et al. Therapeutic efficacy of percutaneous radiofrequency ablation versus microwave ablation for hepatocellular carcinoma. *PLoS One.* 2013; 8
34. Shi J, Sun Q, Wang Y, et al. Comparison of microwave ablation and surgical resection for treatment of hepatocellular carcinomas conforming to Milan criteria. *J Gastroenterol Hepatol.* 2014; 29:1500–1507. [PubMed: 24628534]
35. Chen MS, Li JQ, Zheng Y, et al. A prospective randomized trial comparing percutaneous local ablative therapy and partial hepatectomy for small hepatocellular carcinoma. *Ann Surg.* 2006; 243:321–328. [PubMed: 16495695]
36. Feng K, Yan J, Li X, et al. A randomized controlled trial of radiofrequency ablation and surgical resection in the treatment of small hepatocellular carcinoma. *J Hepatol.* 2012; 57:794–802. [PubMed: 22634125]
37. Llovet JM, Vilana R, Bru C, et al. Increased risk of tumor seeding after percutaneous radiofrequency ablation for single hepatocellular carcinoma. *Hepatology.* 2001; 33:1124–1129. [PubMed: 11343240]
38. Livraghi T, Solbiati L, Meloni MF, et al. Treatment of focal liver tumors with percutaneous radiofrequency ablation: complications encountered in a multicenter study. *Radiology.* 2003; 226:441–451. [PubMed: 12563138]
39. Lencioni R, Cioni D, Crocetti L, et al. Early-stage hepatocellular carcinoma in patients with cirrhosis: long-term results of percutaneous image-guided radiofrequency ablation. *Radiology.* 2005; 234:961–967. [PubMed: 15665226]
40. Facciorusso A, Serviddio G, Muscatiello N. Local ablative treatments for hepatocellular carcinoma: an updated review. *World J Gastrointest Pharmacol Ther.* 2016; 7:477–489. [PubMed: 27867681]
41. Hocquelet A, Balageas P, Frulio N, Trillaud H. Aggressive intrasegmental recurrence of periportal hepatocellular carcinoma after radiofrequency ablation: role of ablative technique and heat-sink effect? *Radiology.* 2015; 276:932–933. [PubMed: 26302397]
42. Liapi E, Geschwind JF. Intra-arterial therapies for hepatocellular carcinoma: where do we stand? *Ann Surg Oncol.* 2010; 17:1234–1246. [PubMed: 20405328]
43. Rand T, Loewe C, Schoder M, et al. Arterial embolization of unresectable hepatocellular carcinoma with use of microspheres, lipiodol, and cyanoacrylate. *Cardiovasc Intervent Radiol.* 2005; 28:313–318. [PubMed: 15886943]
44. Huang YH, Chen CH, Chang TT, et al. The role of transcatheter arterial embolization for patients with unresectable hepatocellular carcinoma: a nationwide, multicentre study evaluated by cancer stage. *Aliment Pharmacol Ther.* 2005; 21:687–694. [PubMed: 15771754]

45. Maluccio MA, Covey AM, Porat LB, et al. Transcatheter arterial embolization with only particles for the treatment of unresectable hepatocellular carcinoma. *J Vasc Interv Radiol.* 2008; 19:862–869. [PubMed: 18503900]
46. Bonomo G, Pedicini V, Monfardini L, et al. Bland embolization in patients with unresectable hepatocellular carcinoma using precise, tightly size-calibrated, anti-inflammatory microparticles: first clinical experience and one-year follow-up. *Cardiovasc Intervent Radiol.* 2010; 33:552–559. [PubMed: 19957182]
47. Ramsey DE, Kernagis LY, Soulen MC, Geschwind JF. Chemoembolization of hepatocellular carcinoma. *J Vasc Interv Radiol.* 2002; 13:211–221. [PubMed: 11830630]
48. Lo CM, Ngan H, Tso WK, et al. Randomized controlled trial of transarterial lipiodol chemoembolization for unresectable hepatocellular carcinoma. *Hepatology.* 2002; 35:1164–1171. [PubMed: 11981766]
49. Llovet JM, Real MI, Montana X, et al. Arterial embolisation or chemoembolisation versus symptomatic treatment in patients with unresectable hepatocellular carcinoma: a randomised controlled trial. *Lancet.* 2002; 359:1734–1739. [PubMed: 12049862]
50. Sergio A, Cristofori C, Cardin R, et al. Transcatheter arterial chemoembolization (TACE) in hepatocellular carcinoma (HCC): the role of angiogenesis and invasiveness. *Am J Gastroenterol.* 2008; 103:914–921. [PubMed: 18177453]
51. Xiong ZP, Yang SR, Liang ZY, et al. Association between vascular endothelial growth factor and metastasis after transcatheter arterial chemoembolization in patients with hepatocellular carcinoma. *Hepatobiliary Pancreat Dis Int.* 2004; 3:386–390. [PubMed: 15313674]
52. Song BC, Chung YH, Kim JA, et al. Association between insulin-like growth factor-2 and metastases after transcatheter arterial chemoembolization in patients with hepatocellular carcinoma: a prospective study. *Cancer.* 2001; 91:2386–2393. [PubMed: 11413529]
53. Kudo M, Imanaka K, Chida N, et al. Phase III study of sorafenib after transarterial chemoembolisation in Japanese and Korean patients with unresectable hepatocellular carcinoma. *Eur J Cancer.* 2011; 47:2117–2127. [PubMed: 21664811]
54. Erhardt A, Kolligs F, Dollinger M, et al. TACE plus sorafenib for the treatment of hepatocellular carcinoma: results of the multicenter, phase II SOCRATES trial. *Cancer Chemother Pharmacol.* 2014; 74:947–954. [PubMed: 25173458]
55. Pawlik TM, Reyes DK, Cosgrove D, et al. Phase II trial of sorafenib combined with concurrent transarterial chemoembolization with drug-eluting beads for hepatocellular carcinoma. *J Clin Oncol.* 2011; 29:3960–3967. [PubMed: 21911714]
56. Park JW, Koh YH, Kim HB, et al. Phase II study of concurrent transarterial chemoembolization and sorafenib in patients with unresectable hepatocellular carcinoma. *J Hepatol.* 2012; 56:1336–1342. [PubMed: 22314421]
57. Chung YH, Han G, Yoon JH, et al. Interim analysis of START: study in Asia of the combination of TACE (transcatheter arterial chemoembolization) with sorafenib in patients with hepatocellular carcinoma trial. *Int J Cancer.* 2013; 132:2448–2458. [PubMed: 23129123]
58. Zhu K, Chen J, Lai L, et al. Hepatocellular carcinoma with portal vein tumor thrombus: treatment with transarterial chemoembolization combined with sorafenib—a retrospective controlled study. *Radiology.* 2014; 272:284–293. [PubMed: 24708192]
59. Zhao Y, Wang WJ, Guan S, et al. Sorafenib combined with transarterial chemoembolization for the treatment of advanced hepatocellular carcinoma: a large-scale multicenter study of 222 patients. *Ann Oncol.* 2013; 24:1786–1792. [PubMed: 23508822]
60. Lencioni R, Llovet JM, Han G, et al. Sorafenib or placebo plus TACE with doxorubicin-eluting beads for intermediate-stage HCC: phase II, randomized, double-blind SPACE trial. *J Hepatol.* 2016; 64:1090–1098. [PubMed: 26809111]
61. Chao Y, Chung YH, Han G, et al. The combination of transcatheter arterial chemoembolization and sorafenib is well tolerated and effective in Asian patients with hepatocellular carcinoma: final results of the START trial. *Int J Cancer.* 2015; 136:1458–1467. [PubMed: 25099027]
62. Poon RT, Tso WK, Pang RW, et al. A phase I/II trial of chemoembolization for hepatocellular carcinoma using a novel intra-arterial drug-eluting bead. *Clin Gastroenterol Hepatol.* 2007; 5:1100–1108. [PubMed: 17627902]

63. Reyes DK, Vossen JA, Kamel IR, et al. Single-center phase II trial of transarterial chemoembolization with drug-eluting beads for patients with unresectable hepatocellular carcinoma: initial experience in the United States. *Cancer J*. 2009; 15:526–532. [PubMed: 20010173]
64. Lammer J, Malagari K, Vogl T, et al. Prospective randomized study of doxorubicin-eluting-bead embolization in the treatment of hepatocellular carcinoma: results of the PRECISION V study. *Cardiovasc Intervent Radiol*. 2010; 33:41–52. [PubMed: 19908093]
65. Malagari K, Pomoni M, Kelekis A, et al. Prospective randomized comparison of chemoembolization with doxorubicin-eluting beads and bland embolization with BeadBlock for hepatocellular carcinoma. *Cardiovasc Intervent Radiol*. 2010; 33:541–551. [PubMed: 19937027]
66. Dhanasekaran R, Kooby DA, Staley CA, et al. Comparison of conventional transarterial chemoembolization (TACE) and chemoembolization with doxorubicin drug eluting beads (DEB) for unresectable hepatocellular carcinoma (HCC). *J Surg Oncol*. 2010; 101:476–480. [PubMed: 20213741]
67. Malagari K, Pomoni M, Moschouris H, et al. Chemoembolization with doxorubicin-eluting beads for unresectable hepatocellular carcinoma: five-year survival analysis. *Cardiovasc Intervent Radiol*. 2012; 35:1119–1128. [PubMed: 22614031]
68. Song MJ, Chun HJ, Song DS, et al. Comparative study between doxorubicin-eluting beads and conventional transarterial chemoembolization for treatment of hepatocellular carcinoma. *J Hepatol*. 2012; 57:1244–1250. [PubMed: 22824821]
69. Golfieri R, Giampalma E, Renzulli M, et al. Randomised controlled trial of doxorubicin-eluting beads vs conventional chemoembolisation for hepatocellular carcinoma. *Br J Cancer*. 2014; 111:255–264. [PubMed: 24937669]
70. Brown KT, Do RK, Gonen M, et al. Randomized trial of hepatic artery embolization for hepatocellular carcinoma using doxorubicin-eluting microspheres compared with embolization with microspheres alone. *J Clin Oncol*. 2016; 34:2046–2053. [PubMed: 26834067]
71. Ibrahim SM, Lewandowski RJ, Sato KT, et al. Radioembolization for the treatment of unresectable hepatocellular carcinoma: a clinical review. *World J Gastroenterol*. 2008; 14:1664–1669. [PubMed: 18350597]
72. Kulik LM, Carr BI, Mulcahy MF, et al. Safety and efficacy of 90Y radiotherapy for hepatocellular carcinoma with and without portal vein thrombosis. *Hepatology*. 2008; 47:71–81. [PubMed: 18027884]
73. Woodall CE, Scoggins CR, Ellis SF, et al. Is selective internal radioembolization safe and effective for patients with inoperable hepatocellular carcinoma and venous thrombosis? *J Am Coll Surg*. 2009; 208:375–382. [PubMed: 19317999]
74. Salem R, Lewandowski RJ, Mulcahy MF, et al. Radioembolization for hepatocellular carcinoma using yttrium-90 microspheres: a comprehensive report of long-term outcomes. *Gastroenterology*. 2010; 138:52–64. [PubMed: 19766639]
75. Sangro B, Carpanese L, Cianni R, et al. Survival after yttrium-90 resin microsphere radioembolization of hepatocellular carcinoma across Barcelona Clinic Liver Cancer stages: a European evaluation. *Hepatology*. 2011; 54:868–878. [PubMed: 21618574]
76. Mazzaferro V, Sposito C, Bhoori S, et al. Yttrium-90 radioembolization for intermediate-advanced hepatocellular carcinoma: a phase 2 study. *Hepatology*. 2013; 57:1826–1837. [PubMed: 22911442]
77. Vouche M, Habib A, Ward TJ, et al. Unresectable solitary hepatocellular carcinoma not amenable to radiofrequency ablation: multicenter radiology-pathology correlation and survival of radiation segmentectomy. *Hepatology*. 2014; 60:192–201. [PubMed: 24691943]
78. Abdel-Rahman OM, Elsayed Z. Yttrium-90 microsphere radioembolisation for unresectable hepatocellular carcinoma. *Cochrane Database Syst Rev*. 2016; (2):CD011313. [PubMed: 26905230]
79. Atassi B, Bangash AK, Bahrani A, et al. Multimodality imaging following 90Y radioembolization: a comprehensive review and pictorial essay. *Radiographics*. 2008; 28:81–99. [PubMed: 18203932]

80. Maluccio M, Covey AM, Gandhi R, et al. Comparison of survival rates after bland arterial embolization and ablation versus surgical resection for treating solitary hepatocellular carcinoma up to 7 cm. *J Vasc Interv Radiol*. 2005; 16:955–961. [PubMed: 16002503]
81. El-Serag HB, Marrero JA, Rudolph L, Reddy KR. Diagnosis and treatment of hepatocellular carcinoma. *Gastroenterology*. 2008; 134:1752–1763. [PubMed: 18471552]
82. Molinari M, Kachura JR, Dixon E, et al. Transarterial chemoembolisation for advanced hepatocellular carcinoma: results from a North American cancer centre. *Clin Oncol (R Coll Radiol)*. 2006; 18:684–692. [PubMed: 17100154]
83. Llado L, Virgili J, Figueras J, et al. A prognostic index of the survival of patients with unresectable hepatocellular carcinoma after transcatheter arterial chemoembolization. *Cancer*. 2000; 88:50–57. [PubMed: 10618605]
84. Zhang YJ, Liang HH, Chen MS, et al. Hepatocellular carcinoma treated with radiofrequency ablation with or without ethanol injection: a prospective randomized trial. *Radiology*. 2007; 244:599–607. [PubMed: 17641378]
85. Kim JH, Won HJ, Shin YM, et al. Medium-sized (3.1–5.0 cm) hepatocellular carcinoma: transarterial chemoembolization plus radiofrequency ablation versus radiofrequency ablation alone. *Ann Surg Oncol*. 2011; 18:1624–1629. [PubMed: 21445671]
86. Peng ZW, Zhang YJ, Liang HH, et al. Recurrent hepatocellular carcinoma treated with sequential transcatheter arterial chemoembolization and RF ablation versus RF ablation alone: a prospective randomized trial. *Radiology*. 2012; 262:689–700. [PubMed: 22157201]
87. Toso C, Mentha G, Kneteman NM, Majno P. The place of downstaging for hepatocellular carcinoma. *J Hepatol*. 2010; 52:930–936. [PubMed: 20385428]
88. Fujiki M, Aucejo F, Kim R. General overview of neo-adjuvant therapy for hepatocellular carcinoma before liver transplantation: necessity or option? *Liver Int*. 2011; 31:1081–1089. [PubMed: 22008644]
89. Ravaioli M, Grazi GL, Piscaglia F, et al. Liver transplantation for hepatocellular carcinoma: results of down-staging in patients initially outside the Milan selection criteria. *Am J Transplant*. 2008; 8:2547–2557. [PubMed: 19032223]
90. Yao FY, Kerlan RK Jr, Hirose R, et al. Excellent outcome following down-staging of hepatocellular carcinoma prior to liver transplantation: an intention-to-treat analysis. *Hepatology*. 2008; 48:819–827. [PubMed: 18688876]
91. Chapman WC, Majella Doyle MB, Stuart JE, et al. Outcomes of neoadjuvant transarterial chemoembolization to downstage hepatocellular carcinoma before liver transplantation. *Ann Surg*. 2008; 248:617–625. [PubMed: 18936575]
92. Lewandowski RJ, Kulik LM, Riaz A, et al. A comparative analysis of transarterial downstaging for hepatocellular carcinoma: chemoembolization versus radioembolization. *Am J Transplant*. 2009; 9:1920–1928. [PubMed: 19552767]
93. De Luna W, Sze DY, Ahmed A, et al. Transarterial chemoinfusion for hepatocellular carcinoma as downstaging therapy and a bridge toward liver transplantation. *Am J Transplant*. 2009; 9:1158–1168. [PubMed: 19344435]
94. Hawkins MA, Dawson LA. Radiation therapy for hepatocellular carcinoma: from palliation to cure. *Cancer*. 2006; 106:1653–1663. [PubMed: 16541431]
95. Hoffs SE, Finkelstein SE, Russell MS, Shridhar R. Nonsurgical options for hepatocellular carcinoma: evolving role of external beam radiotherapy. *Cancer Control*. 2010; 17:100–110. [PubMed: 20404793]
96. Kwon JH, Bae SH, Kim JY, et al. Long-term effect of stereotactic body radiation therapy for primary hepatocellular carcinoma ineligible for local ablation therapy or surgical resection. Stereotactic radiotherapy for liver cancer. *BMC Cancer*. 2010; 10:475–475. [PubMed: 20813065]
97. Andolino DL, Johnson CS, Maluccio M, et al. Stereotactic body radiotherapy for primary hepatocellular carcinoma. *Int J Radiat Oncol Biol Phys*. 2011; 81:e447–453. [PubMed: 21645977]
98. Huang WY, Jen YM, Lee MS, et al. Stereotactic body radiation therapy in recurrent hepatocellular carcinoma. *Int J Radiat Oncol Biol Phys*. 2012; 84:355–361. [PubMed: 22342300]



99. Kang JK, Kim MS, Cho CK, et al. Stereotactic body radiation therapy for inoperable hepatocellular carcinoma as a local salvage treatment after incomplete transarterial chemoembolization. *Cancer*. 2012; 118:5424–5431. [PubMed: 22570179]
100. Bujold A, Massey CA, Kim JJ, et al. Sequential phase I and II trials of stereotactic body radiotherapy for locally advanced hepatocellular carcinoma. *J Clin Oncol*. 2013; 31:1631–1639. [PubMed: 23547075]
101. Wahl DR, Stenmark MH, Tao Y, et al. Outcomes after stereotactic body radiotherapy or radiofrequency ablation for hepatocellular carcinoma. *J Clin Oncol*. 2016; 34:452–459. [PubMed: 26628466]
102. Facciuto ME, Singh MK, Rochon C, et al. Stereotactic body radiation therapy in hepatocellular carcinoma and cirrhosis: evaluation of radiological and pathological response. *J Surg Oncol*. 2012; 105:692–698. [PubMed: 21960321]
103. Katz AW, Chawla S, Qu Z, et al. Stereotactic hypofractionated radiation therapy as a bridge to transplantation for hepatocellular carcinoma: clinical outcome and pathologic correlation. *Int J Radiat Oncol Biol Phys*. 2012; 83:895–900. [PubMed: 22172906]
104. O'Connor JK, Trotter J, Davis GL, et al. Long-term outcomes of stereotactic body radiation therapy in the treatment of hepatocellular cancer as a bridge to transplantation. *Liver Transpl*. 2012; 18:949–954. [PubMed: 22467602]
105. Tse RV, Hawkins M, Lockwood G, et al. Phase I study of individualized stereotactic body radiotherapy for hepatocellular carcinoma and intrahepatic cholangiocarcinoma. *J Clin Oncol*. 2008; 26:657–664. [PubMed: 18172187]
106. Cardenes HR, Price TR, Perkins SM, et al. Phase I feasibility trial of stereotactic body radiation therapy for primary hepatocellular carcinoma. *Clin Transl Oncol*. 2010; 12:218–225. [PubMed: 20231127]
107. Tanguturi SK, Wo JY, Zhu AX, et al. Radiation therapy for liver tumors: ready for inclusion in guidelines? *Oncologist*. 2014; 19:868–879. [PubMed: 25001265]
108. ASTRO Model Policies. Proton Beam Therapy. Available at: [http://www.astro.org/uploadedFiles/Main\\_Site/Practice\\_Management/Reimbursement/ASTRO%20PBT%20Model%20Policy%20FINAL.pdf](http://www.astro.org/uploadedFiles/Main_Site/Practice_Management/Reimbursement/ASTRO%20PBT%20Model%20Policy%20FINAL.pdf). Accessed March 27, 2017
109. Hong TS, Wo JY, Yeap BY, et al. Multi-institutional phase II study of high-dose hypofractionated proton beam therapy in patients with localized, unresectable hepatocellular carcinoma and intrahepatic cholangiocarcinoma. *J Clin Oncol*. 2016; 34:460–468. [PubMed: 26668346]
110. Qi WX, Fu S, Zhang Q, Guo XM. Charged particle therapy versus photon therapy for patients with hepatocellular carcinoma: a systematic review and meta-analysis. *Radiother Oncol*. 2015; 114:289–295. [PubMed: 25497556]
111. Bush DA, Smith JC, Slater JD, et al. Randomized clinical trial comparing proton beam radiation therapy with transarterial chemoembolization for hepatocellular carcinoma: results of an interim analysis. *Int J Radiat Oncol Biol Phys*. 2016; 95:477–482. [PubMed: 27084661]
112. Soliman H, Ringash J, Jiang H, et al. Phase II trial of palliative radiotherapy for hepatocellular carcinoma and liver metastases. *J Clin Oncol*. 2013; 31:3980–3986. [PubMed: 24062394]

## NCCN: Continuing Education

### Target Audience

This activity is designed to meet the educational needs of physicians, nurses, and pharmacists involved in the management of patients with cancer.

### Accreditation Statement

#### Physicians

National Comprehensive Cancer Network is accredited by the Accreditation Council for Continuing Medical Education (ACCME) to provide continuing medical education for physicians.

NCCN designates this journal-based CE activity for a maximum of 1.0 AMA PRA Category 1 Credit™. Physicians should claim only the credit commensurate with the extent of their participation in the activity.

#### Nurses

National Comprehensive Cancer Network is accredited as a provider of continuing nursing education by the American Nurses Credentialing Center's Commission on Accreditation.

NCCN designates this educational activity for a maximum of 1.0 contact hour.

#### Pharmacists

National Comprehensive Cancer Network is accredited by the Accreditation Council for Pharmacy Education as a provider of continuing pharmacy education.

NCCN designates this knowledge-based continuing education activity for 1.0 contact hour (0.1 CEUs) of continuing education credit. UAN: 0836-0000-17-005-H01-P

All clinicians completing this activity will be issued a certificate of participation. To participate in this journal CE activity: 1) review the educational content; 2) take the posttest with a 66% minimum passing score and complete the evaluation at <http://education.nccn.org/node/80708>; and 3) view/print certificate.

### Learning Objectives

Upon completion of this activity, participants will be able to:

- Integrate updates to the NCCN Guidelines for Hepatobiliary Cancers into the management of patients with hepatocellular carcinoma, with a focus on locoregional therapy
- Describe the rationale behind the decision-making process for developing the NCCN Guidelines for Hepatobiliary Cancers, with a focus on locoregional therapy for hepatocellular carcinoma

**NCCN Categories of Evidence and Consensus**

**Category 1:** Based upon high-level evidence, there is uniform NCCN consensus that the intervention is appropriate.

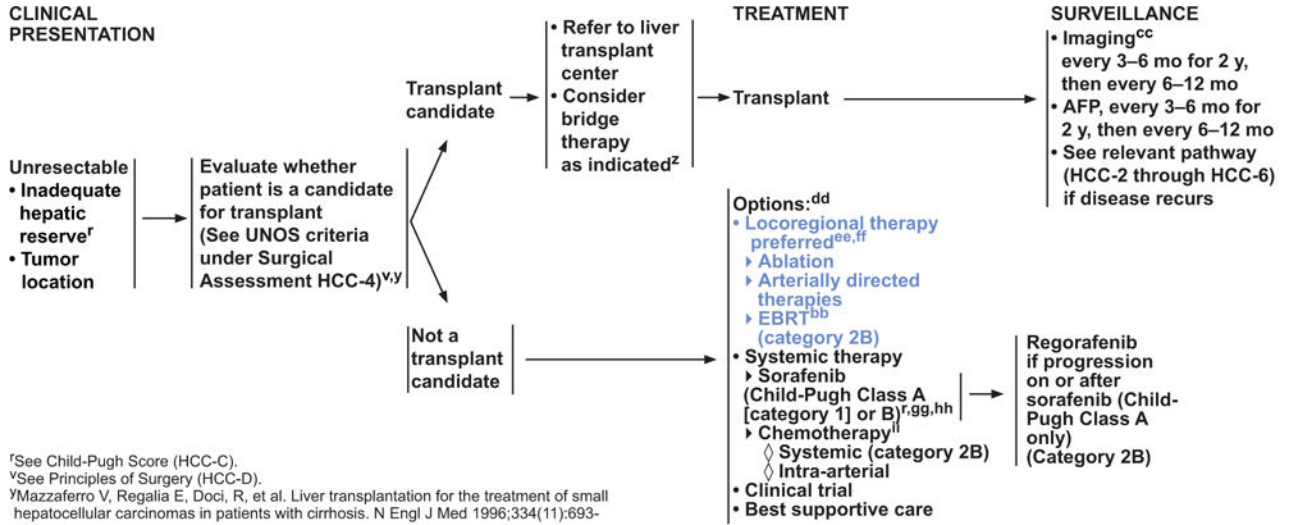
**Category 2A:** Based upon lower-level evidence, there is uniform NCCN consensus that the intervention is appropriate.

**Category 2B:** Based upon lower-level evidence, there is NCCN consensus that the intervention is appropriate.

**Category 3:** Based upon any level of evidence, there is major NCCN disagreement that the intervention is appropriate.

All recommendations are category 2A unless otherwise noted.

Clinical trials: NCCN believes that the best management for any cancer patient is in a clinical trial. Participation in clinical trials is especially encouraged.



<sup>f</sup>See Child-Pugh Score (HCC-C).

<sup>y</sup>See Principles of Surgery (HCC-D).

<sup>v</sup>Mazzaferro V, Regalia E, Doci, R, et al. Liver transplantation for the treatment of small hepatocellular carcinomas in patients with cirrhosis. N Engl J Med 1996;334(11):693-700.

<sup>z</sup>Many transplant centers consider bridge therapy for transplant candidates. (See Discussion).

<sup>bb</sup>Case series and single-arm studies suggest safety and possible efficacy of radiation therapy in selected cases. (See Principles of Locoregional Therapy (HCC-E).

<sup>cc</sup>Multiphasic abdominal MRI or multi-phase CT scans for liver assessment are recommended. Consider chest CT. See Principles of Imaging (HCC-A).

<sup>dd</sup>Order does not indicate preference. The choice of treatment modality may depend on extent/location of disease, hepatic reserve, and institutional capabilities.

<sup>ee</sup>See Principles of Locoregional Therapy (HCC-E).

<sup>ff</sup>Use of chemoembolization has also been supported by randomized controlled trials in selected populations over best supportive care. (Lo CM, Ngan H, Tso WK, et al. Randomized controlled trial of transarterial lipiodol chemoembolization for unresectable hepatocellular carcinoma. Hepatology 2002;35:1164-1171) and (Llovet JM, Real MI, Montaña X, et al. Arterial embolisation or chemoembolisation versus symptomatic treatment in patients with unresectable hepatocellular carcinoma: a randomized controlled trial. Lancet 2002;359:1734-1739).

<sup>gg</sup>For selected patients, two randomized phase 3 clinical trials have demonstrated survival benefits. (Llovet J, Ricci S, Mazzaferro V, et al. Sorafenib in advanced hepatocellular carcinoma. N Engl J Med 2008;359(4):378-390) and (Cheng A, Kang Y, Chen Z, et al. Efficacy and safety of sorafenib in patients in the Asia Pacific region with advanced hepatocellular carcinoma: a phase III randomized, double-blind, placebo-controlled trial. Lancet Oncol 2009;10:25-34).

<sup>hh</sup>Caution: There are limited safety data available for Child-Pugh Class B or C patients and dosing is uncertain. Use with extreme caution in patients with elevated bilirubin levels. (Miller AA, Murry K, Owzar DR, et al. Phase I and pharmacokinetic study of sorafenib in patients with hepatic or renal dysfunction: CALGB 60301. J Clin Oncol 2009;27:1800-1805). The impact of sorafenib on patients potentially eligible for transplant is unknown.

<sup>ii</sup>There are limited data supporting the use of chemotherapy, and its use in the context of a clinical trial is preferred.

Author Manuscript

Author Manuscript

Author Manuscript

Author Manuscript

**PRINCIPLES OF LOCOREGIONAL THERAPY\***

**External-Beam Radiation Therapy (EBRT)**

- EBRT is a treatment option (category 2B) for patients with unresectable disease, or for those who are medically inoperable due to comorbidity.
- All tumors irrespective of the location may be amenable to radiation therapy (3D conformal radiation therapy, intensity-modulated radiation therapy [IMRT], or stereotactic body radiation therapy [SBRT]).
- Hypofractionation with photons<sup>25</sup> or protons<sup>26,27</sup> is an acceptable option for intrahepatic tumors, though treatment at centers with experience is recommended.
- SBRT is an advanced technique of hypofractionated EBRT with photons that delivers large ablative doses of radiation.
- There is growing evidence for the usefulness of SBRT in the management of patients with HCC.<sup>18,19</sup> SBRT can be considered as an alternative to the ablation/embolization techniques mentioned above or when these therapies have failed or are contraindicated.
- SBRT (1–5 fractions) is often used for patients with 1 to 3 tumors. SBRT could be considered for larger lesions or more extensive disease, if there is sufficient uninvolved liver and liver radiation tolerance can be respected. There should be no extrahepatic disease or it should be minimal and addressed in a comprehensive management plan. The majority of data on radiation for HCC liver tumors arises from patients with Child-Pugh A liver disease; safety data are limited for patients with Child-Pugh B or poorer liver function. Those with Child-Pugh B cirrhosis can be safely treated, but they may require dose modifications and strict dose constraint adherence.<sup>20</sup> The safety of liver radiation for HCC in patients with Child-Pugh C cirrhosis has not been established, as there are not likely to be clinical trials available for Child-Pugh C patients.<sup>21,22</sup>
- Proton beam therapy (PBT) may be appropriate in specific situations.<sup>23,24</sup>
- Palliative EBRT is appropriate for symptom control and/or prevention of complications from metastatic HCC lesions, such as bone or brain.

\*All references appearing on HCC-E 2 of 3 can be accessed online, in these guidelines, at NCCN.org.

Author Manuscript

Author Manuscript

Author Manuscript

Author Manuscript